

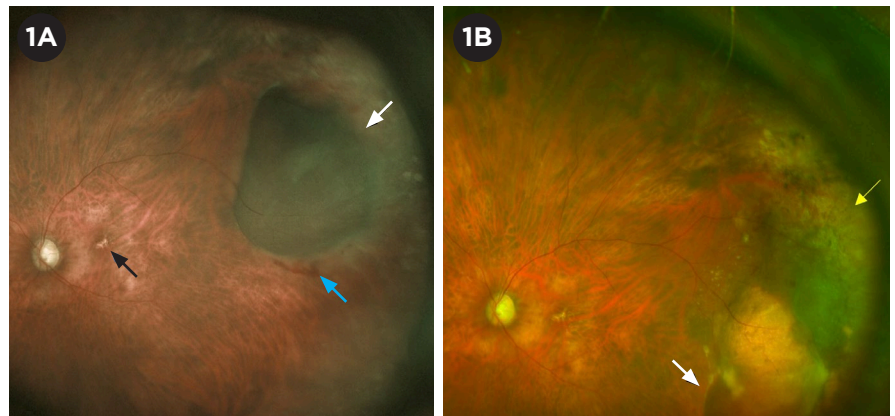
## Peripheral Exudative Hemorrhagic Chorioretinopathy

**P**eripheral exudative hemorrhagic chorioretinopathy (PEHCR) is an uncommon degenerative condition of the retina and choroid. This condition was first described by Reese and Jones in 1961 as peripheral hematomas under the retinal pigment epithelium (RPE), and the current name was subsequently coined by Annesley in 1980. Other terms that have been used to describe this entity include eccentric retinal degeneration, extramacular disciform, and peripheral age-related retinal degeneration.<sup>1,2</sup>

Even though PEHCR is a relatively rare entity, it is important for all ophthalmologists to understand the diagnosis and management of this condition because it can mimic several other diagnoses. In particular, PEHCR is frequently mistaken for choroidal melanoma, which has very different management and prognostic implications. Key aspects of the epidemiology, clinical presentation, and imaging findings can aid the ophthalmologist in the diagnosis, management, and, when warranted, timely referral to the appropriate subspecialist.

### Epidemiology

PEHCR has been described mostly in White patients, with a mean age at presentation between 70 and 80 years and a female predominance of 60% to 70%.<sup>1-5</sup> Almost all patients reported in large case series have been White.<sup>1-4</sup> However, the condition has



**PEHCR OVER TIME.** (1A) Widefield color fundus photograph of a temporal PEHCR lesion characterized by a hemorrhagic PED (white arrow) with adjacent intraretinal hemorrhage inferiorly (blue arrow). Concurrent macular RPE changes can be seen (black arrow). (1B) Same eye nine months later, showing inferior shifting of the PEHCR lesion (white arrow) leaving areas of RPE atrophy and hyperplasia (yellow arrow).

been reported uncommonly in African American and Asian patients, and some authors have suggested that the disease course may be more severe in non-White patients.<sup>6</sup> Possible risk factors for the exudation and/or hemorrhage include hypertension and use of systemic antiplatelet or anticoagulant drugs.<sup>1-3</sup>

### Pathophysiology

The pathophysiology of PEHCR is unclear. Initially, the condition was thought to be a peripheral variant of age-related macular degeneration (AMD), given the similar clinical characteristics of hemorrhage and exudation, as well as findings of macular drusen and RPE changes in a subset of cases.<sup>1,2</sup> Subsequently, the identification

of abnormal choroidal vascular networks and polyp-like telangiectasias on indocyanine green angiography (ICGA) raised the possibility that PEHCR may be related to polypoidal choroidal vasculopathy.<sup>7,8</sup> A recent study using enhanced-depth imaging OCT suggests that PEHCR may belong to the pachychoroid spectrum of diseases.<sup>9</sup>

### Clinical Presentation

Up to 60% of patients with PEHCR may be asymptomatic.<sup>4</sup> Those who are symptomatic most commonly present with decreased vision, floaters, or flashes. Less commonly, PEHCR may cause metamorphopsia, scotomas, visual field deficits, or pain. The mean BCVA at presentation ranges from 20/40 to 20/100, although around one-fifth of patients may present with BCVA worse than 20/200.<sup>1,2,5</sup> Causes of decreased

BY TIANYU LIU, MD, AND BENJAMIN J. KIM, MD. EDITED BY JEREMIAH TAO, MD.

vision at presentation include vitreous hemorrhage, subretinal hemorrhage, subretinal fluid, and lipid exudation involving the macula.<sup>1-5</sup>

On fundus examination, PEHCR lesions are typically found in the temporal periphery between the equator and the ora serrata, especially inferotemporally, and are bilateral in 9% to 43% of cases.<sup>1-5</sup> They most often appear as elevated subretinal hemorrhages or hemorrhagic pigment epithelial detachments (PEDs) mimicking tumorlike masses (Fig. 1A).<sup>1-5</sup> Associated findings include subretinal fluid, serous PEDs, lipid exudation, subretinal fibrosis, RPE hyperplasia or atrophy (Fig. 1B), and vitreous hemorrhage.<sup>1-5</sup> Macular findings consistent with those seen in AMD, including drusen and RPE changes, have been reported in up to two-thirds of cases.<sup>1-5</sup>

## Diagnosis

The diagnosis of PEHCR is based on clinical examination aided by multimodal imaging. On ultrasonography, PEHCR presents as a dome- or plateau-shaped lesion with variable echogenicity and internal reflectivity. It can be associated with a clot retraction cleft between the subretinal/sub-RPE blood and choroid but typically does not exhibit intrinsic vascular pulsations or choroidal excavation, both of which can be seen with choroidal melanoma.<sup>1-3</sup>

On fluorescein angiography (FA), PEHCR is characterized by blockage from subretinal/sub-RPE blood, hyper- or hypofluorescence in areas of RPE atrophy or hyperplasia, pooling in serous PEDs, and possible leakage from choroidal neovascularization (reported in 3%-26% of cases).<sup>1-4</sup> Findings on ICGA include polyps (0%-59%), a pathologic choroidal network (30%-84%), and late hypercyanescence or leakage of uncertain etiology (60%-62%).<sup>2-4</sup>

It may be difficult to directly image PEHCR lesions with OCT due to their peripheral location, but these lesions can be characterized by subretinal fluid or PEDs over Bruch's membrane, without infiltration into the underlying choroid. OCT of the macula may reveal macular extension of subretinal fluid,

**Table 1. Clinical Findings and Imaging Characteristics of PEHCR and Choroidal Melanoma**

	PEHCR	Choroidal Melanoma
Epidemiology	<ul style="list-style-type: none"> <li>Relatively older age (mean, 70-80)</li> <li>Slight female predominance</li> </ul>	<ul style="list-style-type: none"> <li>Variable age (mean, 50-60)</li> <li>Slight male predominance</li> </ul>
Clinical	<ul style="list-style-type: none"> <li>Located between equator and ora serrata</li> <li>Can be bilateral (9%-43%)</li> <li>Can be multifocal</li> <li>Can have associated macular or peripheral drusen or RPE changes</li> </ul>	<ul style="list-style-type: none"> <li>Located anywhere in uvea, including anterior to the ora serrata</li> <li>Rarely bilateral (&lt;1%)</li> <li>Unifocal</li> <li>Can have overlying drusen, orange pigment, sentinel vessels</li> </ul>
Ultrasound	<ul style="list-style-type: none"> <li>Dome- or plateau-shaped lesion</li> <li>Variable internal reflectivity</li> <li>Can have clot retraction cleft</li> </ul>	<ul style="list-style-type: none"> <li>Can be mushroom-shaped</li> <li>Low/intermediate internal reflectivity</li> <li>Can have intrinsic vascular pulsations or choroidal excavation</li> </ul>
FA	<ul style="list-style-type: none"> <li>Blockage from hemorrhage</li> <li>Hyper- or hypofluorescence in areas of RPE atrophy or hyperplasia</li> </ul>	<ul style="list-style-type: none"> <li>Intrinsic vascularity (double circulation)</li> </ul>
ICGA	<ul style="list-style-type: none"> <li>Polyps</li> <li>Pathologic choroidal network</li> </ul>	<ul style="list-style-type: none"> <li>Intrinsic vascularity (double circulation)</li> </ul>
OCT	<ul style="list-style-type: none"> <li>Subretinal fluid, PEDs, macular fibrosis</li> </ul>	<ul style="list-style-type: none"> <li>Subretinal fluid, subretinal lipofuscin deposits, shaggy photoreceptors</li> </ul>

exudates, or development of macular fibrosis.<sup>3-5</sup>

## Differential Diagnosis

The differential diagnosis of PEHCR includes chorioretinal mass lesions such as choroidal melanoma or hemangioma, as well as other causes of subretinal/sub-RPE hemorrhage such as macroaneurysm, Coats disease, and traumatic choroidal rupture. Choroidal melanoma was the most common referring diagnosis for PEHCR in multiple case series, and PEHCR was second only to choroidal nevi as a cause of "pseudomelanoma" seen at a large tertiary referral center, highlighting the importance of differentiating these two entities.<sup>1-3</sup>

**Choroidal melanoma.** Clinical findings and multimodal imaging characteristics can help differentiate

PEHCR from choroidal melanoma, although none of these features is pathognomonic for either condition (Table 1). PEHCR typically presents in older patients, with a slight female predominance, while choroidal melanoma presents over a wider age range and has a slight male predominance. PEHCR can present bilaterally, while choroidal melanoma is rarely bilateral (<1%).<sup>1</sup>

While PEHCR lesions are typically located between the equator and the ora serrata, choroidal melanoma can be located anywhere in the uvea, including anterior to the ora serrata. This can be appreciated clinically by transilluminating the globe; lesions whose shadow extends anterior to the ora serrata into the pars plana are more concerning for choroidal melanoma.<sup>1</sup>

On ultrasound, the choroid underlying a PEHCR lesion should be normal,

although there can be a clot retraction cleft separating the subretinal or sub-RPE clot from the underlying choroid. In contrast, a mushroom-shaped lesion or the presence of intrinsic vascular pulsations are both more suggestive of choroidal melanoma, as neither of these features was seen in any cases of PEHCR in a large series.<sup>1</sup> Similarly, intrinsic vascularity characterized by a “double circulation” pattern (fluorescence from vessels within the tumor as well as from the overlying intact retinal vasculature) is more characteristic of choroidal melanoma and has not been reported with PEHCR.<sup>1</sup>

### Management and Prognosis

No randomized trials have been conducted on the treatment of PEHCR, and management is based on case series and expert opinion. Observation is a reasonable option for stable peripheral lesions. Shields and colleagues reported a series of 90 patients with PEHCR managed with observation; over a mean follow-up period of 15 months, 89% of patients demonstrated stability or regression, and 11% showed progression.<sup>1</sup> However, aggressive lesions can cause significant peripheral vision loss and can extend into the macula.<sup>8</sup> Cases of PEHCR exhibiting rapidly progressive massive subretinal hemorrhage with acute loss of vision have been reported, including two of five cases in Asian patients, highlighting the importance of close surveillance and return precautions.<sup>6</sup>

Treatment options for PEHCR lesions that demonstrate progression include intravitreal anti-VEGF therapy, laser photocoagulation, photodynamic therapy, and cryotherapy. Of these, anti-VEGF therapy is the most commonly used and has shown favorable outcomes in small case series.<sup>5,10</sup> Vitrectomy is usually reserved for nonclearing vitreous hemorrhage.<sup>3,6,10</sup>

Mean final BCVA in large PEHCR series ranged from 20/40 to 20/200 at mean follow-up periods of more than two years.<sup>3-5</sup> Vitrectomy for nonclearing vitreous hemorrhage was the only treatment modality associated with statistically significant improvements in visual acuity.<sup>3</sup>

### Conclusion

PEHCR is an uncommon but potentially vision-threatening condition affecting older adults. It can mimic other causes of retinal hemorrhage or chorioretinal mass lesions, particularly choroidal melanoma, and accurate diagnosis requires careful clinical examination aided by multimodal imaging. Patients with an unclear diagnosis should be referred promptly (e.g., within one week) to a retina specialist, given the potential urgency associated with other entities in the differential diagnosis. Although most cases of PEHCR demonstrate stability or spontaneous regression, some severe cases can cause vision loss due to extensive peripheral hemorrhage, macular involvement, or vitreous hemorrhage. Thus, patients with PEHCR should be monitored carefully and given clear return precautions to reduce the risk of vision-threatening complications.

1 Shields CL et al. *Ophthalmology*. 2009;116(3):529-535.

2 Mantel I et al. *Am J Ophthalmol*. 2009;148(6):932-8.e1.

3 Vandefonteyne S et al. *Br J Ophthalmol*. 2020;104(6):874-878.

4 Zicarelli F et al. *Br J Ophthalmol*. 2021;105(10):1410-1414.

5 Safir M et al. *PLoS One*. 2022;17(9):e0275163.

6 Kim YT et al. *Jpn J Ophthalmol*. 2010;54(3):227-231.

7 Mantel I et al. *Am J Ophthalmol*. 2012;153(5):910-922.e2.

8 Goldman DR et al. *Retina*. 2013;33(1):48-55.

9 Shroff D et al. *Retina*. 2021;41(7):1518-1525.

10 Seibel I et al. *Graefes Arch Clin Exp Ophthalmol*. 2016;254(4):653-659.

Dr. Liu is an ophthalmology resident, and Dr. Kim is an assistant professor of ophthalmology; both are at the Scheie Eye Institute at the University of Pennsylvania in Philadelphia. *Relevant financial disclosures: None.*

For full disclosures, see this article at [aao.org/eyenet](https://aao.org/eyenet).

**GOT PEARLS?** Want to write about the diagnosis and medical and/or surgical management of a specific disease entity? Write for *EyeNet*! Get started at [aao.org/eyenet/write-for-us](https://aao.org/eyenet/write-for-us).

## Coming in the next EyeNet®

### Feature

**AI and Glaucoma** A look at the potential benefits of AI in the field of glaucoma—and the challenges that remain. Thoughts on data integration, workflow issues, legal quandaries, and more.

### Clinical Update

**Comprehensive** Late sequelae of retinopathy of prematurity.

**Cornea** Update on pterygium management.

### Pearls

**Ocular Syphilis** The incidence of syphilis in the United States is on the rise. Do you know how to diagnose this notorious mimic?

### Savvy Coder

**Retina Update** From biosimilars and dual inhibitors to the nuances of step therapy.

### Blink

Take a guess at the next issue's mystery image. Then find the article at [aao.org/eyenet](https://aao.org/eyenet) and report your diagnosis.

### For Your Convenience

These stories also will be available online at [aao.org/eyenet](https://aao.org/eyenet).

### FOR ADVERTISING INFORMATION

Mark Mrvica or Kelly Miller  
M. J. Mrvica Associates Inc.  
856-768-9360  
[mjmrvica@mrvica.com](mailto:mjmrvica@mrvica.com)