

## Infectious Uveitis, Part 2: Signs, Lab Tests, Imaging, and Treatments

Last month, in Part 1 of this two-part series about how to approach patients with intraocular inflammation, three experts—Janet L. Davis, MD, at the Bascom Palmer Eye Institute, in Miami, Phoebe Lin, MD, PhD, at the Cleveland Clinic Cole Eye Institute, and Ramana S. Moorthy, MD, at Associated Vitreoretinal and Uveitis Consultants, in Indianapolis—discussed the importance of being vigilant for cases of infectious uveitis and taking an incisive history.

This month, the experts discuss the examination and laboratory testing.

### Examine the Whole Eye

In patients with intraocular inflammation, said Dr. Lim, “You need to look at every single part of the eye, including a dilated fundus exam, to find clues on whether or not you have a potential infectious etiology.”

Dr. Davis added: “The first and worst mistake would be to not dilate a patient who has anterior inflammation—you really need to make sure that it is not something that’s coming from a posterior focus of infection. A very common example would be *Toxoplasma chorioretinitis*. You really need to know what you’re dealing with before you treat the superficial signs of inflammation.”

**Follow-up.** Dr. Davis also noted that follow-up is key, particularly for patients with severe disease. “You need

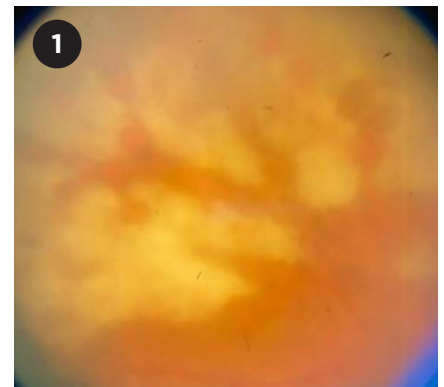
to examine the retina again. In a typical scenario for viral retinitis, the patient presents with a sudden-onset iritis and a red eye.” But even if the doctor does dilate the eye, she cautioned, there may not be signs of retinal infection on that visit. “It’s fairly common that people with ARN [acute retinal necrosis] are diagnosed around day 7 or 10 after the onset of symptoms because the telltale signs of retinal whitening are not really seen until then.”

### Look for Key Signs

What are some of the signs to help distinguish between infectious and noninfectious uveitis? “There’s not 100% specificity with any one sign, and the presentation may vary depending on the stage of disease,” said Dr. Lin. “So you have to be able to wrap your mind around multiple possibilities.”

**Anterior segment.** Drs. Davis, Lin, and Moorthy mentioned the following pointers for the anterior segment:

- **One or both eyes?** Unilateral involvement suggests an infectious cause.
- **IOP:** Elevated IOP generally points to a viral etiology, especially cytomegalovirus, rubella, varicella-zoster virus (VZV), and herpes simplex virus (HSV) types 1 and 2; but, it can also occur in toxoplasmosis.
- **Corneal signs in anterior uveitis:** With herpesvirus infections in particular, keratic precipitates appear scattered across the cornea, rather than just in



**NECROTIZING VIRAL RETINITIS.** Vitritis and broad areas of full-thickness retinal necrosis and perivascular clearing are evident in this eye with VZV infection.

the inferior third. Reduced corneal sensation is a sign of viral keratitis.

- **Iris changes.** Erosion or atonicity of the iris sphincter and transillumination defects in a sectoral pattern are characteristic of herpetic iridocyclitis or iritis.

**Fundus findings.** Infectious uveitis can produce a wide and sometimes puzzling variety of fundus manifestations. Following are just a few of the characteristic findings.

- **Toxoplasmosis.** A white spot or white area of retinal inflammation, often with overlying vitreous inflammation and haze, suggests toxoplasmosis. With dense vitreous inflammation, the fundus can take on the “headlight in a fog” appearance. Hyperpigmented chorioretinal scarring may also be present near the active lesion.<sup>1</sup>

- **Syphilis.** Patients with syphilis typically have panuveitis or a posterior uveitis with retinal involvement, Dr. Moorthy said, and a yellowish placoid

BY PEGGY DENNY, CONTRIBUTING WRITER, INTERVIEWING JANET L. DAVIS, MD, PHOEBE LIN, MD, PHD, AND RAMANA S. MOORTHY, MD.

chorioretinitis is a characteristic finding. Another distinct presentation is a punctate inner retinitis.<sup>1</sup>

- **Tuberculosis.** “TB uveitis can present in various ways as anterior, posterior, or panuveitis. It can even appear as a serpiginoid, multifocal choroiditis,” said Dr. Moorthy.

- **ARN.** Most commonly, ARN demonstrates a multifocal or confluent full-thickness necrotizing retinitis along with peripheral retinal whitening and occlusive retinal arteritis (Fig. 1).<sup>1</sup>

## Lab Tests and Imaging

**Labs.** In Dr. Moorthy’s practice, almost every uveitis patient is tested for syphilis, tuberculosis, and sarcoidosis. Dr. Davis also tests all patients for syphilis. Drs. Moorthy and Davis concur that the antitreponemal antibody tests are more useful than the nontreponemal VDRL and rapid plasma reagin tests for detecting syphilitic uveitis.

Dr. Lin said that her testing depends on the overall clinical impression from the history and review of systems, examination findings, and medication history. “After all that, I formulate the plan for blood testing and ancillary imaging like chest imaging based on my top differential candidates.”

In cases of fulminant viral retinitis, PCR analysis of intraocular fluid obtained through paracentesis can be very helpful, said Dr. Davis. Dr. Moorthy agreed: “We only need about 0.1 cc of aqueous, and most labs will be able to identify DNA evidence of HSV1, HSV2, VZV, or cytomegalovirus. It’s a very sensitive and specific test for that inflammatory process.”

**Imaging.** Dr. Davis said that imaging is generally not necessary for diagnosing infectious uveitis, although it can be helpful in certain cases. For example, she may use high-resolution ultrasound of the anterior segment for scleritis. “Sometimes you can see lesions that look nodular, or there’s a lot of fluid. That might tip you off that there is an intrascleral infection.”

In addition, OCT can be used to determine the location of what appears to be an infected spot, she said. “Is it in the choroid, is it clearly retinal, is it superficial? Is it an abscess, a choroidal

nodule, or a retinal infiltrate? These signs can be helpful.”

Dr. Lin said that “ultrasound is useful, especially in chronic uveitis, when the fundus cannot be visualized because of fibrin in the anterior chamber or vitreous haze and posterior synechia. In such cases, you can use ultrasound to make sure the retina is not detached or that there’s not a rare mass in the back of the eye.”

## Empiric Treatment

Ideally, treatment would be based upon the diagnosis, but, said Dr. Davis, “in many patients with a red, painful eye and severe inflammation, you really need to treat with steroids before a definitive diagnosis and may add empiric anti-infective coverage based on your clinical judgment regarding the most likely organism.” Moreover, in some cases, the response to empiric therapy can help to establish the diagnosis.<sup>2</sup>

If Dr. Lin suspects herpetic uveitis, she said that she would empirically treat with an oral antiviral such as valacyclovir and, possibly, an intravitreal antiviral such as foscarnet along with topical steroids. However, she noted, topical steroids are not as effective “behind the lens.” In that case, she considers an oral steroid a safer choice than a periocular or intravitreal steroid, because “it’s actually much more difficult to ‘take back’ a periocular steroid than an oral steroid, which you can just stop.” However, she continued, “Until an anti-infective agent is started, oral steroids should seldom be used when you suspect an infectious cause of uveitis, and the key is to be highly suspicious of an infectious agent.”

## Know When to Refer

For comprehensive ophthalmologists, the decision to refer to a uveitis subspecialist depends in part on the availability of such specialty care, as well as how comfortable they feel managing ocular inflammation. Dr. Davis said that “most comprehensive ophthalmologists are willing to follow non-sight-threatening iridocyclitis for up to three months. After that, if the patient is not responding as expected to treatment and there’s still no answer, then they’re usually referred

to a uveitis specialist if one is available.”

Dr. Lin recommends having a low threshold to suspect infectious uveitis, particularly in the presence of retinal necrosis or the anterior chamber findings listed above. If a comprehensive ophthalmologist suspects that the disease is viral, he or she “can empirically treat with oral antivirals, along with topical steroids as long as there’s not a keratitis component,” she said, adding, “And if they don’t feel comfortable with any of that, they should refer.”

However, said Dr. Moorthy, viral retinitis should be referred immediately to a uveitis or retina subspecialist because “these devastating illnesses move quickly and can cause irreversible destruction of the retina if they are not adequately treated with antiviral therapy.”

**Collaboration.** Other specialists may need to be involved, said Dr. Moorthy. For example, the management of ocular syphilis calls for an infectious disease specialist: “These patients are treated as tertiary syphilis or neurosyphilis, and often require lumbar puncture to assess extent of disease and guide treatment.” Moreover, the disease needs to be reported to local health officials for contact tracing and other measures.

Similarly, he said, an ophthalmologist can treat the ocular inflammation of TB. However, the systemic disease is a public health issue that requires reporting and involvement of public health and infectious disease specialists to manage the lengthy and complex multidrug therapy.

1 Lin P. *Curr Ophthalmol Rep.* 2015;3(3):170-183.

2 Davis JL. *Eye (Lond).* 2012;26(2):194-201.

**Dr. Davis** is professor of ophthalmology and the Leach Chair in Ophthalmology at Bascom Palmer Eye Institute at the University of Miami. *Relevant financial disclosures:* None.

**Dr. Lin** is full staff at Cole Eye Institute at the Cleveland Clinic. *Relevant financial disclosures:* Bausch + Lomb: C.

**Dr. Moorthy** is president and CEO of Associated Vitreoretinal and Uveitis Consultants and a clinical professor of ophthalmology at the Indiana University School of Medicine, in Indianapolis. *Relevant financial disclosures:* None.

See disclosure key, page 10. For full disclosures, view this article at [aao.org/eyenet](http://aao.org/eyenet).