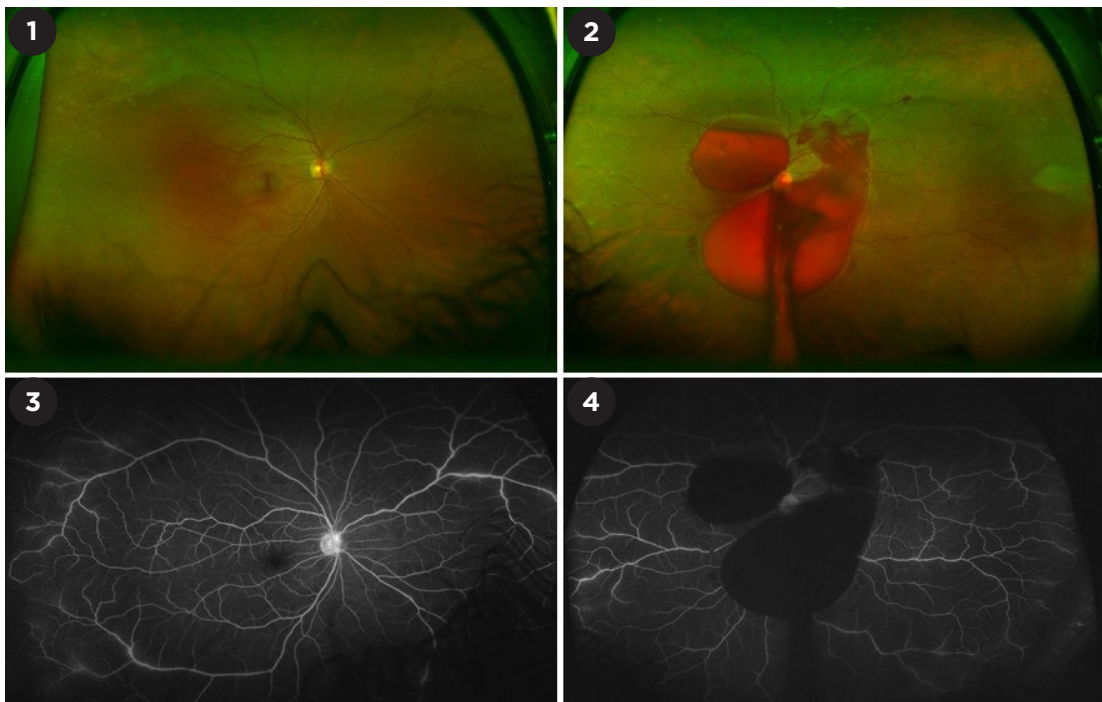


MYSTERY IMAGE  
**BLINK**



**WHAT IS THIS MONTH'S MYSTERY CONDITION?** Visit [aao.org/eyenet](http://aao.org/eyenet) to make your diagnosis in the comments.

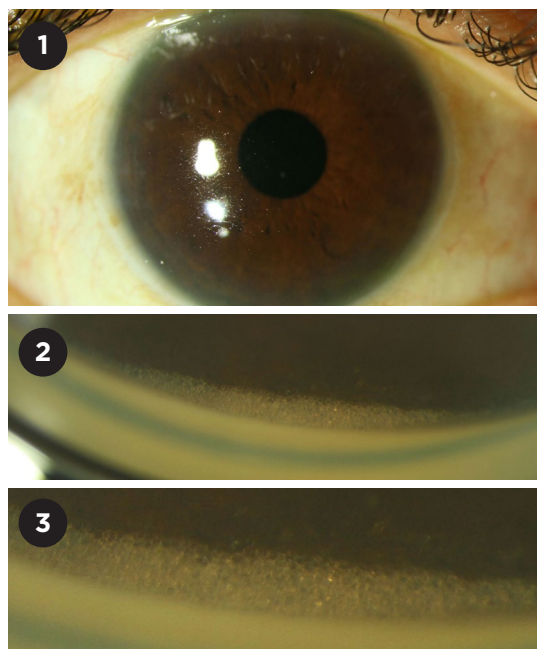
LAST MONTH'S BLINK

## Emulsified Silicone Oil Droplets

**A** 55-year-old man visiting from Saudi Arabia broke his glasses and presented to an optometrist for a new prescription and for mild pain in his right eye. He was found to have elevated intraocular pressure (IOP) of 52 mm Hg in that eye and was sent urgently to the ophthalmology department. The patient had a history of retinal detachment in the right eye, and silicone oil had been placed two years ago.

Slit-lamp examination showed normal anterior chamber depth without inflammation (Fig. 1), but silicone oil was seen in his vitreous cavity. Visual acuity in the patient's right eye was 20/60 with trace injection, and his IOP was 44 mm Hg. Gonioscopy was performed, revealing that the angle was open to the scleral spur in the temporal, nasal, and inferior quadrants. The superior quadrant (Fig. 2) was notable for small, emulsified silicone oil droplets (Fig. 3). The patient was started on topical antiglaucoma drops (Cosopt and brimonidine), and his IOP improved to 21 mm Hg after 90 minutes and two rounds of the drops. He was seen one week later for consideration of silicone oil removal; however, he elected to return to Saudi Arabia for this procedure.

WRITTEN BY **RUSSELL HUANG, MD, ALISA PRAGER,**



**MD, COLE ROJAS, MD, ALEX PLEET, MD, AND ANDREA BIRNBAUM, MD,** DEPARTMENT OF OPHTHALMOLOGY, FEINBERG SCHOOL OF MEDICINE, NORTHWESTERN UNIVERSITY. PHOTO BY **CASON MOORE,** DEPARTMENT OF OPHTHALMOLOGY, NORTHWESTERN UNIVERSITY.