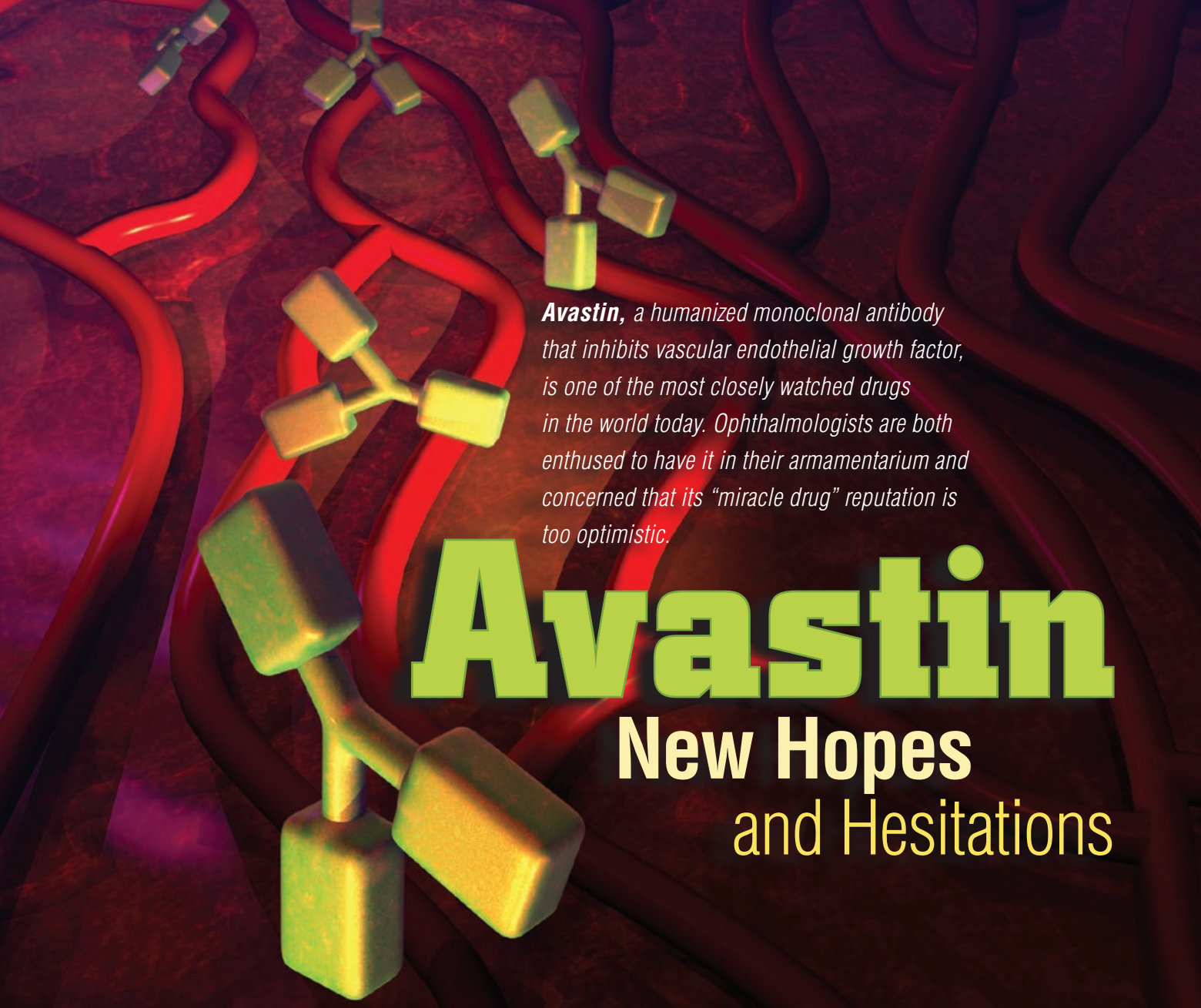

Avastin, a humanized monoclonal antibody that inhibits vascular endothelial growth factor, is one of the most closely watched drugs in the world today. Ophthalmologists are both enthused to have it in their armamentarium and concerned that its "miracle drug" reputation is too optimistic.

Avastin

New Hopes and Hesitations

Bevacizumab, marketed as Avastin, was the first angiogenesis inhibitor available in the United States. Since its original approval—to treat colorectal cancer—it has won additional indications to treat lung cancer, metastatic breast cancer, glioblastoma and metastatic renal cell carcinoma, and it is under study to treat liver, ovarian, pancreatic and prostate cancers. Its potential for ophthalmic medicine is no less impressive. A literature review by two University of Wisconsin researchers found that by August of 2008 Avastin had been used off-label to treat at least 51 ocular disease processes, beginning most famously with macular degeneration.[1] Ophthalmologists could be forgiven for wondering if there is anything this drug doesn't do.

But the early enthusiasm over Avastin has been tempered with questions. At a recent meeting on retinal vein occlusion, the assembled specialists reached an unusual consensus. "We all agreed," recalled Karl G. Csaky, MD, PhD, "that if someone with a CRVO responded to Avastin, it's both a good thing and a bad." The good thing: Patients initially respond well. The bad: What next? Dr. Csaky is director of the macular degeneration laboratory at the Retina Foundation of the Southwest in Dallas. "We don't know how to use Avastin, we don't know when to stop it, and we don't know if the dose is correct," Dr. Csaky said. "Who will respond? Do you give seven injections and then stop? It's all seat-of-the-pants. And it's made more complicated because we don't have guidelines. The problem with Avastin is it works phenomenally well but it wears off, and we don't know what to do after that."

What follows is an overview of this drug's history and some uses to which it is being put, as well as various qualms that might dampen the enthusiasm surrounding the drug.

BY MIRIAM KARMEL, CONTRIBUTING WRITER

ALFRED T. KAMAJIAN

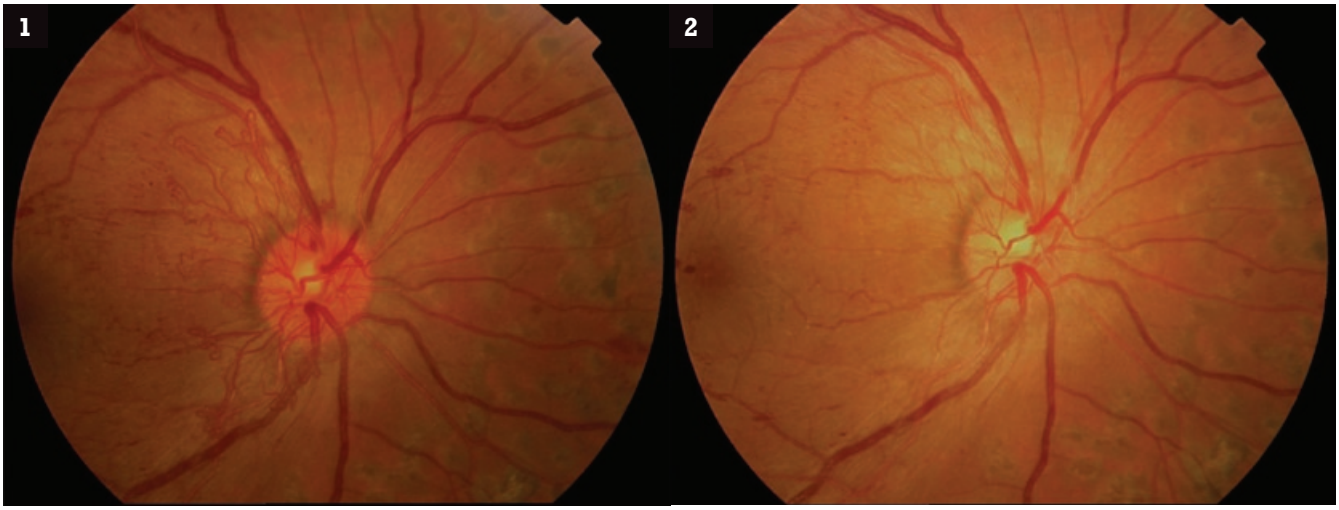

ANTI-VEGF VALUE. Retina of a 32-year-old diabetic male with persistent severe neovascularization of the disc despite panretinal laser therapy (1), and four days after treatment with intravitreal Avastin, showing significant regression (2).

To Wait, or Not to Wait, for Data

Avastin hasn't yet been proven effective for any ocular disease in a controlled clinical trial. One reason for that, of course, is that the developer, Genentech, intended another of its drugs, ranibizumab, to do what Avastin is doing. Ranibizumab won FDA approval for the treatment of AMD in 2006 and was launched as Lucentis. But by then, Philip J. Rosenfeld, MD, PhD, had already tried Avastin in one of his AMD patients, with great success. It quickly became common knowledge that Avastin was cheaper and possibly just as effective as its sister. (See "The Rest Is History.")

The government supports Avastin studies. The ophthalmic community, eager to compare the two drugs scientifically, set in motion two large-scale trials. One, sponsored by the National Eye Institute, is the Comparison of AMD Treatment Trials, or CATT, and is testing Avastin against Lucentis for the management of neovascular AMD. One-year results from the CATT trial are expected in 2011.

The other study, funded by the NEI but organized by the Diabetic Retinopathy Clinical Research Network (DRCR.net), is now in phase 3, comparing four different treatments for diabetic macular edema, including Lucentis. Phase 2 of that trial involved Avastin and showed that DME patients on Avastin enjoyed a larger reduction in central subfield thickness and one line better median visual acuity compared with patients treated with photocoagulation.[2]

Physicians and patients moving ahead with off-label treatment. Avastin, meanwhile, is being used off-label in the retina community to treat virtually everything associated with neovascularization, from AMD and DME to retinopathy of prematurity, branch retinal vein occlusion, uveitic macular edema and neovascular glaucoma. It also is being used as a presurgical adjunct treatment for diabetic vitreous hemorrhage to reduce bleeding and facilitate membrane peeling.

If Avastin could shrink abnormal blood vessels in AMD, clinicians reasoned, it could address other diseases characterized by unregulated angiogenesis, said Michael M. Altaweel, MD, coauthor of the Avastin literature review out of the University of Wisconsin, Madison, and associate professor of ophthalmology there. "If you're using it for angioid streaks, what you're really treating is the secondary CNV. Or if CNV occurred with myopia or histoplasmosis, there's still an abnormal blood vessel that can respond to Avastin treatment." Or in neovascular glaucoma, he added, where vessels are growing on the iris and into the angle, doctors have achieved rapid regression of the vessels.

Precedents for off-label use. Sunil K. Srivastava, MD, assistant professor of ophthalmology at Emory University in Atlanta, noted that off-label medicine is a common physician practice. He said that after photodynamic therapy was used to treat neovascular AMD, ophthalmologists applied it to ocular histoplasmosis and pathologic myopia because the CNV that occurs in neovascular AMD might be similar to the CNV in these other diseases. He added that the current large-scale anti-VEGF trials—CATT and the DRCR.net's DME study—could validate the use of Avastin for these diseases as well as provide treatment guidelines. If these trials show that VEGF inhibitors work for AMD or DME, he said, "We'll assume that it will work for other conditions with underlying CNV. That's the assumption we'll use."

Not So Fast!

"Avastin has absolutely revolutionized how we treat macular degeneration, for the good," said William E. Smiddy, MD, adding that it is a powerful, if temporary, treatment for retinal and iris neovascularization. But in the absence of trial data, Dr. Smiddy is concerned about Avastin's widespread use. "There's been a haste to use it, and it's even more rapid than is healthy or even indicated," given how little is known beyond the anecdotal, he said. "Almost everyone has a series of patients with macular edema or vascular leakage diag-

MICHAEL M. ALTAWEEL, MD

noses. We really don't have the kind of level-one evidence that we really crave to do this." Dr. Smiddy is professor of ophthalmology at the Bascom Palmer Eye Institute.

A cautionary example: triamcinolone. Dr. Altaweel, also mindful of the dearth of rigorous evidence, sees parallels in the Avastin story to the initial zeal for triamcinolone. "It was the same principle of taking something that started off pretty small with a few case reports," he said. Though triamcinolone wasn't applied to as vast a spectrum of disorders as bevacizumab, it was used off-label for a number of conditions, including AMD, by itself and in combination with PDT, diabetes and central vein occlusion. More important, many doctors abandoned laser, the standard of care at the time, as a first-line treatment.

In time, however, triamcinolone became associated with cataracts and pressure spikes that caused glaucoma. Ultimately, the DRCR.net group put triamcinolone to the test in a randomized, controlled clinical trial. Laser, the gold standard, prevailed. "Once you had a proper study, you found the opinion you had formed on the 10 cases you've taken care of may not be correct," Dr. Altaweel said.

Dr. Smiddy also hailed the DRCR.net study. "That's the kind of mature, measured scientific approach that I'm speaking of that we're lacking for most of these diseases being treated with Avastin," he said. "These things need to be studied outside of macular degeneration in a randomized, controlled kind of fashion."

Dr. Altaweel agreed. "Rather than relying on the outcome of the last 10 patients I treated, it's more important to compare the 10 that did and the 10 that did not get Avastin."

And yet there is a growing body of literature to guide clinicians: a PubMed search using key words "Avastin," "eye" and "diseases" yielded 754 articles. "There are a fair amount of data out there," said Dr. Srivastava. "From all the studies and meetings, it's clear that it works—but do we have one big study that proves it works for 'x' disease? No, we don't have that. We're still lacking the kind of solid information that the DRCR.net trial provided in the laser versus triamcinolone trial."

Watch for IOP spikes. Though long-term data have not yet emerged for Avastin, glaucoma specialists already have some concern about one possible side effect. They have been observing sustained intraocular pressure spikes in patients who received multiple injections of Avastin *or* Lucentis. The effect—in some cases a rise from 12 mmHg to 40 mmHg—was not transient due to a simple volume effect. "We're seeing increases that last days or weeks, and in some cases require multiple medications or surgery to lower IOP," said Malik Y. Kahook, MD. In some patients, these changes are occurring in the absence of any prior history of glaucoma. Dr. Kahook is associate professor of ophthalmology at the University of Colorado and director of the glaucoma service at the Rocky Mountain Lions Eye Institute in Denver.

Hylton R. Mayer, MD, assistant professor of ophthalmology at Yale University, has reported on patients with no prior diagnosis of glaucoma or ocular hypertension who experienced significant and persistent ocular hypertension after intravitreal anti-VEGF.[3] "I examined all the patients myself and am fairly convinced that the anti-VEGF injections were the causes of their ocular hypertension, but I cannot fully explain why we seem to have this anomaly occurring, especially when there were no reports of persistent ocular hypertension after thousands of injections in the clinical trials

WHEN AND HOW TO USE AVASTIN

DR. ALTAWEEL: Avastin is still not a panacea. Its role as a standard of care for many conditions is still being explored. I use Avastin as my primary treatment for exudative AMD. For retinal vascular diseases resulting in neovascularization or macular edema, I favor standard-of-care treatment with photocoagulation but find Avastin to be an excellent adjuvant treatment. One role of Avastin is as a temporizing measure, allowing initial control of a problem until a more definitive treatment can be applied. It is particularly helpful if standard treatment has not worked or if media opacity precludes laser.

DR. CSAKY: It's a wonder drug for rubeosis of any etiology—I've never seen it not work. The vessels just disappear. The typical dose is 1.25 in 0.05 ml. There is a concern of pressure increase following the Avastin in patients with already established rubeosis and elevated IOP at the time of presentation, so careful monitoring of IOP following injection is required. Also, Avastin injections may not be a long-term solution and therefore other treatments for this condition, including panretinal photocoagulation and/or glaucoma surgery, should be considered.

DR. KAHOOK: I use intravitreal Avastin in patients with neovascular glaucoma. In these cases, I inject only once, 1.00 to 1.25 mg in 0.04 to 0.05 ml, in the vitreous and then send the patient to my retina colleagues for laser. Using Avastin allows us to buy time until definitive surgery can be performed to lower pressure, if needed.

DR. SMIDDY: I have used Avastin in patients with DME, but only after laser and steroids have failed. Similarly I've used it for macular edema associated with BRVO or CRVO, but usually after laser or steroid has failed, or if there's a contraindication for steroids. I use it without compunction on patients with neovascularization of the iris—rubeosis, with the drug usually injected as 1.25 mg in 0.05 ml or 2.50 mg in 0.1 ml. With rubeosis, there's nothing that can hold a candle to Avastin.

DR. SRIVASTAVA: My number one disease is AMD. And I use it in proliferative diabetic retinopathy prior to retina surgery, to calm the eye, whereas in the past I wouldn't use anything. I use it in DME patients who haven't responded to laser alone, but I always use laser first. It's case by case for CRVO, but it is my primary therapy. For BRVO, I observe first. If they don't get better, I use it with laser.

looking at bevacizumab and ranibizumab."

Toxicity to the trabeculum? To understand why the pressures are spiking, Dr. Kahook and colleague David Ammar, PhD, have been growing trabecular meshwork cells in vitro to observe the effect of Avastin and Lucentis on the cells in culture. They found that high doses of Avastin decreased the cells' metabolism. In some cases, Avastin caused cell death. While spikes in IOP have been observed clinically for both Avastin and Lucentis, in the laboratory deleterious effects on meshwork cells occurred only with Avastin. The findings, Dr. Kahook said, "hint toward a possible toxic effect of Avastin on the trabecular meshwork cells." [4,5]

Others have hypothesized that Avastin may physically accumulate in the trabecular meshwork and block aqueous outflow, leading to increased IOP.[6]

Most of the pressure spikes observed by Dr. Kahook have been in glaucoma suspects or confirmed cases of glaucoma, patients whose drainage systems are already altered. The injections, he said, "may push them over the edge."

Go slow but don't stop. Despite his concerns, Dr. Kahook continues to treat patients with Avastin. He was on the team at the University of Pittsburgh that first reported treatment of neovascular glaucoma with Avastin, which is now, perhaps ironically, the standard of care for that problem. The same team was also first to use it as a wound modulator after trabeculectomy surgery, in lieu of 5-FU and mitomycin.

The effect has been most commonly observed in patients who had greater than five or six injections, which could explain why we're not seeing more of these yet, Dr. Kahook said. It may also be that the spikes are the result of an inflammatory effect that is only noted in the context of a genetic predisposition. "It may be that certain patient populations are prone to experience inflammation in the trabecular meshwork as anti-VEGF agents and their vehicle wash out of the eye. This could explain why we're only seeing this in a small subset of patients."

For now, Dr. Kahook advised doctors to watch more closely for IOP fluctuations—both in the acute and chronic phases—in any patient who has glaucoma and who is getting any type of intravitreal injection. "Anti-VEGF agents have revolutionized the treatment of wet AMD and other ocular neovascular diseases," he said. "The few cases of IOP elevation that we have seen to date should make physicians more cautious in checking IOP after injections but in no way constitutes a reason to stop using these medications."

"THE REST IS HISTORY"

Dr. Rosenfeld pioneered the off-label use of Avastin to treat the wet form of AMD while awaiting FDA approval of Lucentis.* EyeNet *asked Dr. Rosenfeld, professor of ophthalmology at the Bascom Palmer Eye Institute if he ever anticipated the fervor Avastin would create among eye surgeons. Here is his reply.

"Our primary motivation in using intravitreal Avastin was to prevent blindness. We initially used it as salvage therapy in patients who were failing standard-of-care therapies for neovascular AMD. We knew from our previous work with systemic Avastin that it was capable of producing the same, or even better, response than intravitreal Lucentis. Once we witnessed the success in treating neovascular AMD with intravitreal Avastin, the natural next step was to ask whether other diseases affecting the eye were also mediated by VEGF and whether intravitreal Avastin could prevent vision loss in these diseases. This step became known as the Avastin challenge.

"The low cost and apparent safety of Avastin allowed us to challenge these other diseases. We then used Avastin to treat macular edema due to CRVO that was refractory to standard therapy. With that success, we and others moved on to a long list of diseases, and the rest is history. We knew that many of these neovascular diseases were VEGF-mediated, but I never thought the benefits from Avastin would be so widespread, especially the durability of responses observed in some conditions, such as in retinopathy of prematurity."

Decisions Have Dollar Signs

Would the use of Avastin have spread like wildfire if Lucentis, the approved drug for wet AMD, wasn't 40 times more expensive? "Cost is driving Avastin," Dr. Smiddy said. "Most of us think its efficacy is probably equivalent to Lucentis," he said, regarding its use for AMD.

"People are using it off-label because it's so cheap," said Dr. Srivastava. "If it was a couple thousand dollars, I don't think patients would want to bear that financial responsibility. I think the low cost allows people to use it for different diseases." Dr. Altaweel agreed. "If you're going to try it for all these other conditions where there's no insurance coverage, Avastin was the natural choice."

Avastin's knockout blow to Lucentis was a quirk of history, according to Dr. Csaky. "Avastin met the perfect storm." Aside from its low cost, he said, "It was highly effective in its first ophthalmic application and it had a good safety profile. What's more, good medical therapies don't exist for diseases to which it has been applied. I don't think historically that confluence of events will occur again in any other specialty."

A Story Still in Progress

So is Avastin a wonder drug? "Wonder drug implies no faults," Dr. Csaky said. "And Avastin has lots of warts. There are lots of beautiful things about Avastin, but is it without faults? Absolutely not. Does it make the lives of patients better? Yes. Avastin is becoming standard of care for AMD, if you use the definition of what the community is doing. But it's not one shot and you're done. Sometimes you have to give more injections and supplement with laser, say for DME or vein occlusions. You're constantly tweaking. There

are all kinds of approaches and no data to say what's the right way to use this stuff. Avastin is a drug with an incomplete story."

1 Gunther, J. B. and M. M. Altaweel. *Surv Ophthalmol* 2009;54(3):372–400.
2 Scott, I. U. et al. *Ophthalmology* 2007;114(10):1860–1867.
3 Zheng, Q. et al. Persistent ocular hypertension following multiple intravitreal anti-VEGF Injections for AMD. Presented at *ARVO*, Sunday, May 03, 2009, Ft. Lauderdale, Fla.
4 Kahook, M. Y. et al. *Ophthalmic Surg Lasers Imaging* 2006;37(2):148–150.
5 Kahook, M. Y. et al. *Ophthalmic Surg Lasers Imaging* 2006;37(2):144–146.
6 Jalil, A. et al. *Eye* 2007;21(12):1541.

MEET THE EXPERTS



MICHAEL M. ALTAWEEL, MD Associate professor of ophthalmology at the University of Wisconsin in Madison. *Financial disclosure: Principal investigator at his site for Regeneron, a company that is developing a VEGF trap for neovascular AMD.*

KARL G. CSAKY, MD, PHD Senior scientist and director of the Harrington Macular Degeneration Laboratory of the Retina Foundation of the Southwest in Dallas, and on staff of Texas Retina Associates. *Financial disclosure: Consultant to Allergan, Genentech, Heidelberg Engineering and Novartis and equity holder with Potentia and Ophthotech.*

MALIK Y. KAHOOK, MD Associate professor of ophthalmology at the University of Colorado and director of the glaucoma service at the Rocky Mountain Lions Eye Institute in Denver. *Financial disclosure: Has received research support from Genentech.*

HYLTON R. MAYER, MD Assistant professor of ophthalmology at Yale University in New Haven. *Financial disclosure: None.*

WILLIAM E. SMIDDY, MD Professor of ophthalmology at Bascom Palmer Eye Institute of the University of Miami. *Financial disclosure: None.*

SUNIL K. SRIVASTAVA, MD Assistant professor of ophthalmology at Emory University in Atlanta. *Financial disclosure: Advisory board member for Allergan and Bausch & Lomb.*