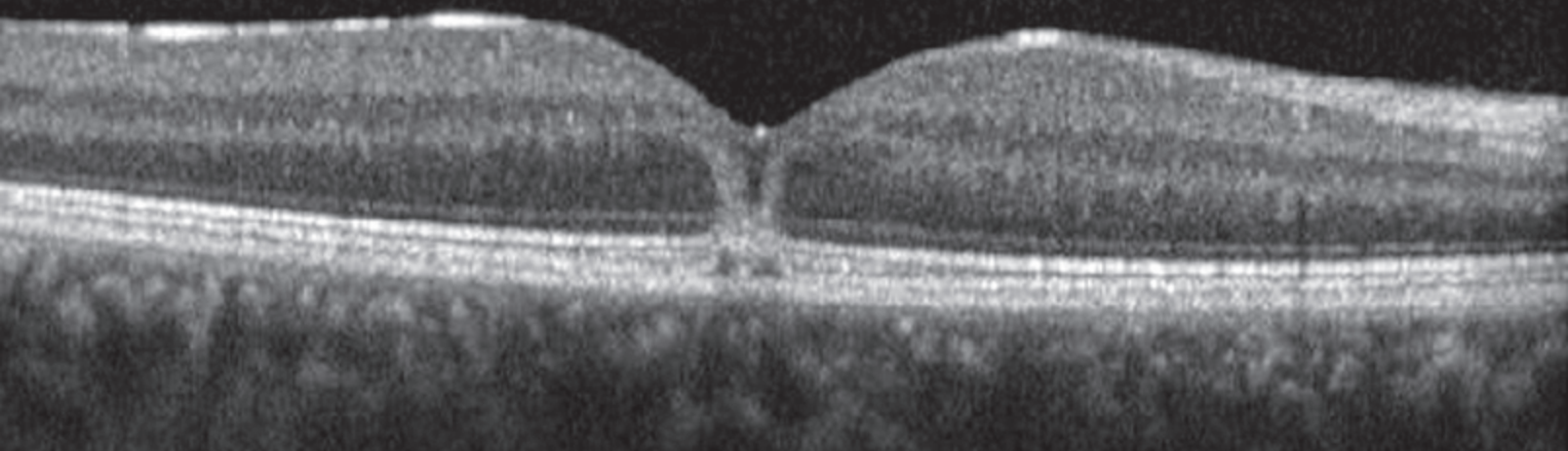
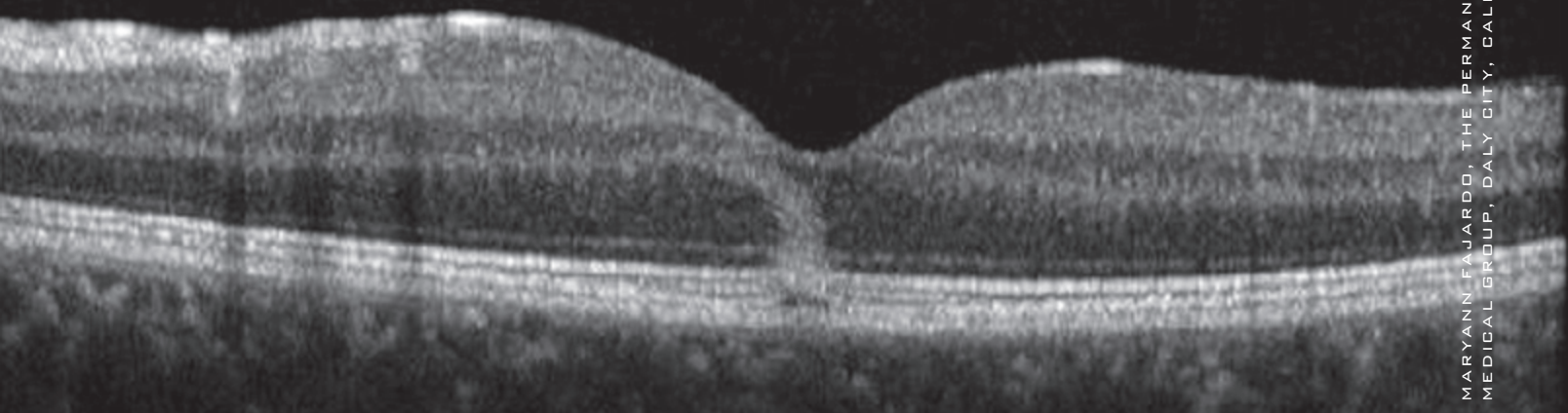


OD



OS



MARYANN FAJARDO, THE PERMANENTE MEDICAL GROUP, DALY CITY, CALIF.

WHAT IS THIS MONTH'S MYSTERY CONDITION? Find the answer in the next issue or post your comments online now at www.eyenet.org.

LAST MONTH'S BLINK

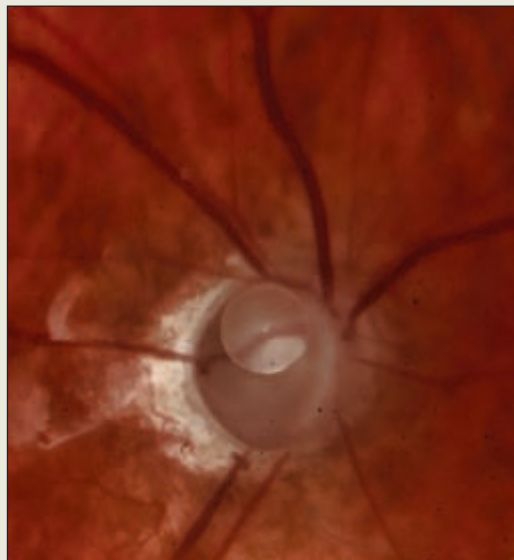
Total Cupping

A 63-year-old man presented for a cosmetic unilateral ptosis evaluation. His right lid had become symptomatic following a complicated history of retinal detachment procedures on that eye, including scleral buckle and lensectomy/vitrectomy with silicone oil injection. After the most recent surgery, visual acuity in the right eye was limited to light perception and later worsened to no light perception.

On examination, intraocular pressure was 40 mmHg. A color fundus photo showed a deep and total cup with a retained silicone oil bubble.

The eye was not painful, so no treatment was advised. The patient was referred to oculoplastics, where a lid repair was scheduled.

Written by Roshni Ranjit, BS, BA, Dilip Rathinasamy, MD, and Timothy Saunders, MD, at University of South Florida Morsani College of Medicine, Tampa, and Peter Reed Pavan, MD, USF Eye Institute, Tampa. Edited by Michael P. Kelly, FOPS.



Ken Albritton, USF Eye Institute, Tampa, Fla.