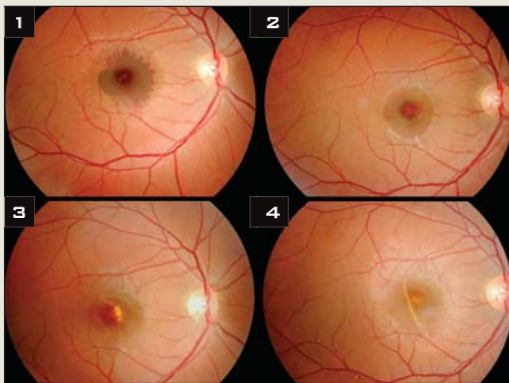


LAST MONTH'S BLINK

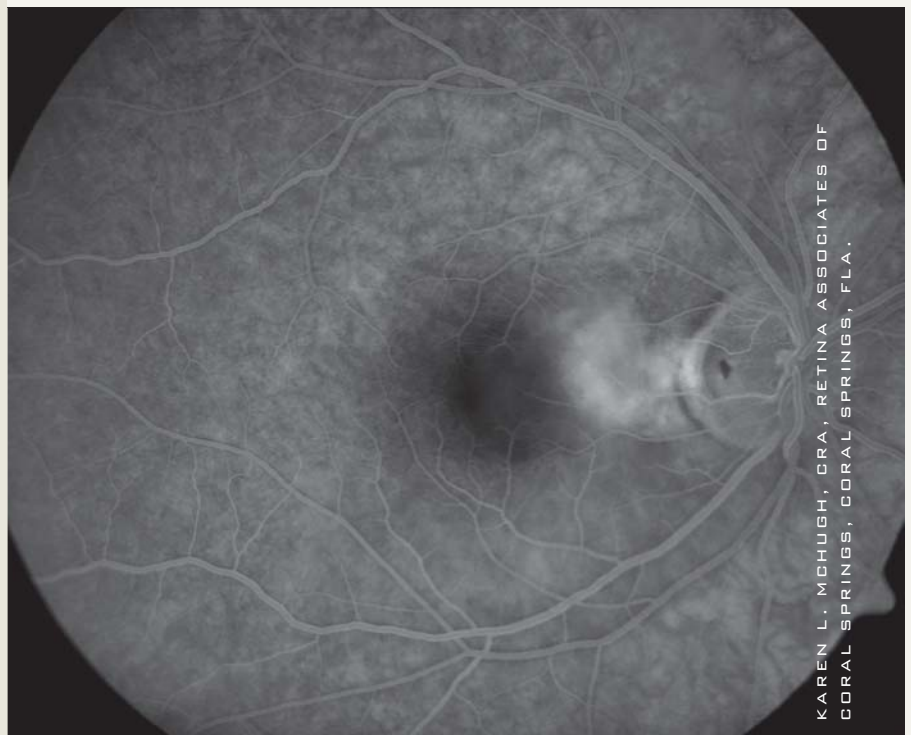
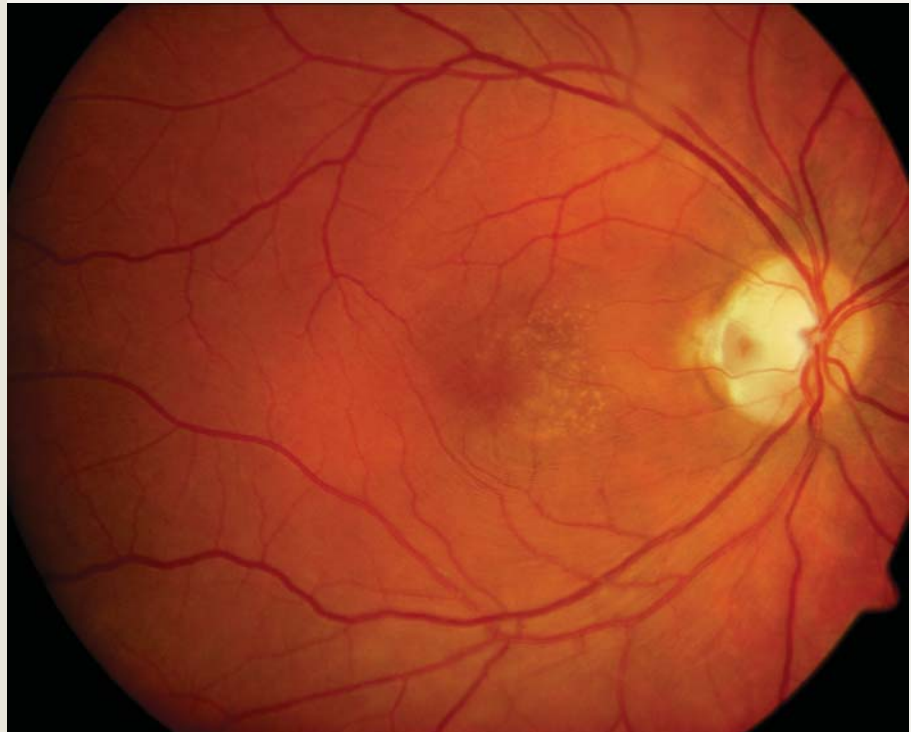
Initially Obscured Choroidal Rupture at the Macula



Wael M. El-Haig, MBBS, MD, Zagazig University, Zagazig, Egypt.

A 20-year-old woman sustained accidental blunt trauma to her right eye. She presented with macular hemorrhage and visual acuity of 20/320 (Fig. 1). Over a follow-up period of four months, the macular hematoma showed liquefaction (Fig. 2) and discoloration (Fig. 3), and then resorbed. Subsequently, a choroidal rupture was revealed (Fig. 4). It appeared as a white crescent that was concentric with the optic disc. Her final visual acuity was 20/120.

Written by Wael M. El-Haig, MBBS, MD, Zagazig University, Zagazig, Egypt.



KAREN L. MCHUGH, CRA, RETINA ASSOCIATES OF CORAL SPRINGS, CORAL SPRINGS, FLA.

WHAT IS THIS MONTH'S MYSTERY CONDITION? Find the answer in the next issue or go online now at www.eyenetmagazine.org.