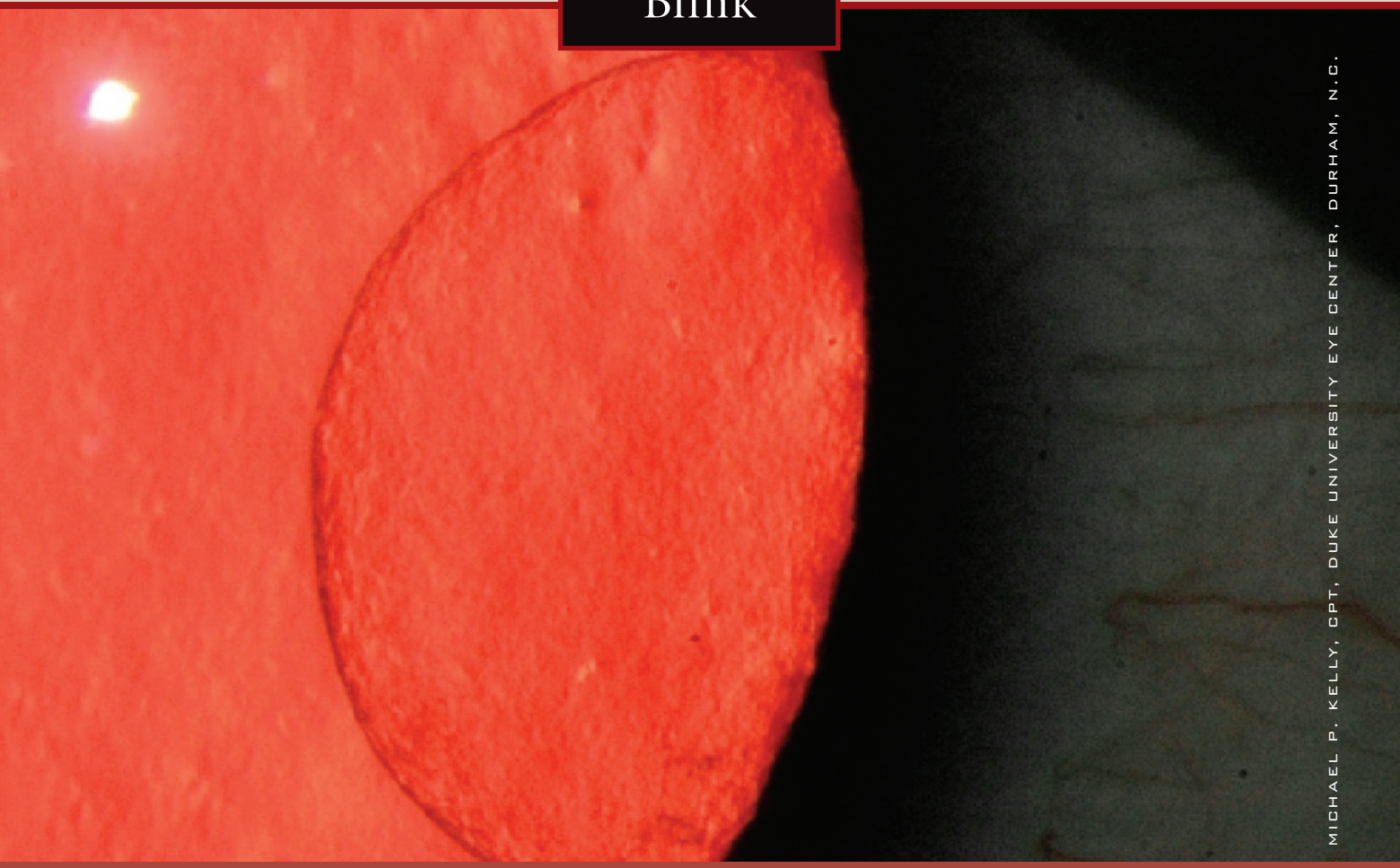

MICHAEL P. KELLY, CPT, DUKE UNIVERSITY EYE CENTER, DURHAM, N.C.

WHAT IS THIS MONTH'S MYSTERY CONDITION? Find the answer in the next issue or go online now at www.eyenetmagazine.org.

LAST MONTH'S BLINK

Familial Exudative Vitreoretinopathy

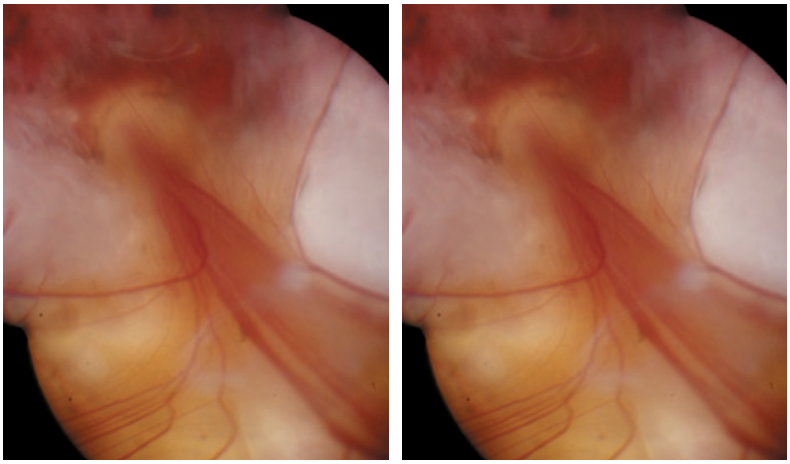

Christina M. Malik Consolo, CRA, COT, Vision Research Foundation, Royal Oak, Mich.

In June 1998, a 14-year-old Caucasian girl presented at a Detroit-area practice. Visual acuity was 20/400 in her right eye and 20/200 in the left. From the ages of 14 to 20, she had undergone multiple ocular procedures for familial exudative vitreoretinopathy (FEV) in both eyes. FEV is characterized by retinal zones that fail to develop normal vessels and consequently lead to proliferation of new vessels that may leak or break. Visual acuity varied from 20/60 to hand motion with a final acuity of hand motion in both eyes.

Interventions in her right eye included scleral buckle, vitrectomy and membrane peel, peripheral laser ablation, cyclocryotherapy and tube shunt placement for glaucoma, and lensectomy. Procedures in her left eye included scleral buckling, autologous plasmin-enzyme–assisted vitrectomy and membrane peeling, dense-pattern peripheral laser ablation, cyclocryotherapy, lensectomy and excimer laser phototherapeutic keratectomy with chelation.

The patient was stable and 24 years of age at the time of this photograph.

Written by Christina M. Malik Consolo, CRA, COT, Vision Research Foundation, Royal Oak, Mich. Edited by Michael P. Kelly, CPT.