Blink

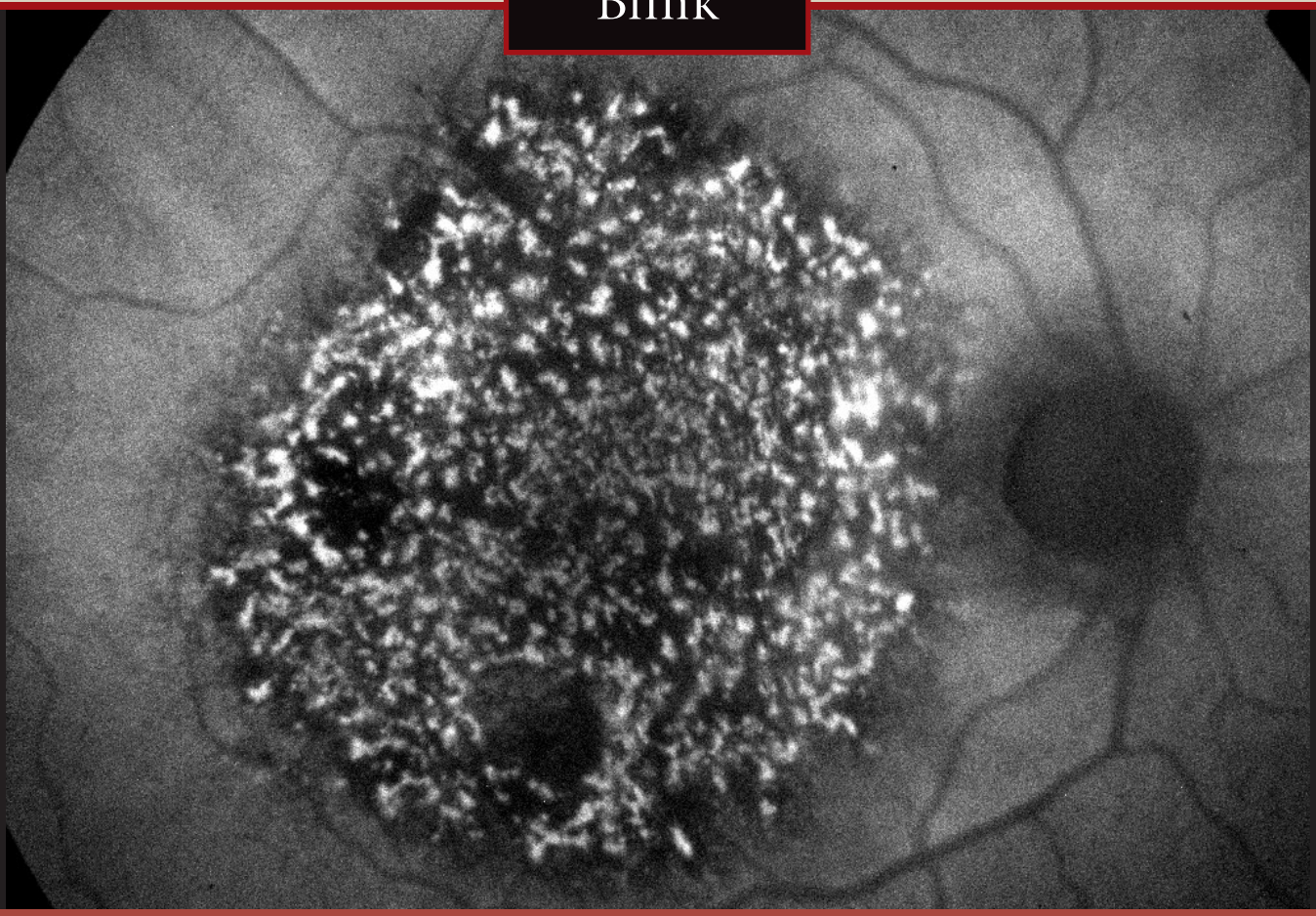

MARCELA HICKEY, CRA, BASCOM PALMER EYE INSTITUTE, MILLER SCHOOL OF MEDICINE, UNIVERSITY OF MIAMI

WHAT IS THIS MONTH'S MYSTERY CONDITION? Find the answer in the next issue or go online now at www.eyenetmagazine.org.

LAST MONTH'S BLINK

Foveal Schisis

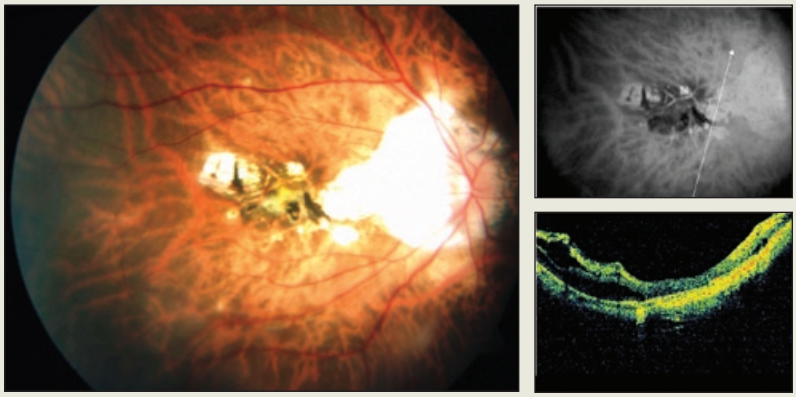

Alok Pratap Singh, MBBS, MS, Abitya Jyot Eye Hospital, Mumbai, India

A 49-year-old, highly myopic female presented with complaints of poor vision in the right eye and blurring of vision in the left eye for the past three years. She was phakic in both eyes and had a BCVA of count fingers at three feet in the right eye and 20/400 in the left.

Anterior segment slit-lamp exam was normal in both eyes. IOP with a noncontact tonometer was 15 mmHg in both eyes. Fundus exam revealed staphylomas at the posterior poles with peripapillary chorioretinal atrophy in both eyes and macular scarring in the right eye. Although no abnormality suggesting schisis or retinal detachment was noted in either eye, OCT images in the right eye revealed multilayered schisis at the macula.

The literature. In one case series, foveal schisis or detachment without macular hole was reported in 9 percent of eyes with high myopia and posterior staphyloma.[1] In some cases, foveal schisis or retinal detachment identified by OCT was not found during slit-lamp exam,[2] a fact for ophthalmologists to consider when examining patients with high myopia and posterior staphyloma.

1 Baba T. et al. *Am J Ophthalmol* 2003;135:338–342.
2 Ohji, M. et al. *Retina,* 4th ed. (Philadelphia: Mosby, 2006), ch. 124.

Written by Saumil Sheth, MBBS, MS, Sunita Mohan, MBBS, MS, and Alok Pratap Singh, MBBS, MS, Aditya Jyot Eye Hospital, Mumbai, India. Edited by Michael P. Kelly, CPT.