


# Apparent optic nerve head swelling in childhood




???????




*Three causes of apparent swelling of pediatric ONH*




???????



???????



# Apparent optic nerve head swelling in childhood




Optic Neuritis


*Three causes of apparent swelling of pediatric ONH*

Papilledema

Pseudopapilledema



# Apparent optic nerve head swelling in childhood



## Optic Neuritis


--Often follows... *non-ocular prodrome(s)*

*Three causes of apparent swelling of pediatric ONH*

## Papilledema

## Pseudopapilledema

# Apparent optic nerve head swelling in childhood



## Optic Neuritis


--Often follows...viral illness, immunization

*Three causes of apparent swelling of pediatric ONH*

## Papilledema

## Pseudopapilledema

# Apparent optic nerve head swelling in childhood



## Optic Neuritis

--Often follows...viral illness, immunization


*Which three viral illnesses in particular?*

*Three causes of apparent swelling of pediatric ONH*

Papilledema

Pseudopapilledema

# Apparent optic nerve head swelling in childhood



## Optic Neuritis

--Often follows...viral illness, immunization


*Which three viral illnesses in particular?  
Mumps, measles, chicken pox*

*Three causes of apparent swelling of pediatric ONH*

Papilledema

Pseudopapilledema

# Apparent optic nerve head swelling in childhood



## Optic Neuritis


- Often follows...viral illness, immunization
- HPI may be suggestive of CNS involvement w/ c/o... 3 HPI/ROS positives

*Three causes of apparent swelling of pediatric ONH*

## Papilledema

## Pseudopapilledema

# Apparent optic nerve head swelling in childhood



## Optic Neuritis

- Often follows...viral illness, immunization
- HPI may be suggestive of CNS involvement w/ c/o...HA, lethargy, N/V


*Three causes of apparent swelling of pediatric ONH*

## Papilledema

## Pseudopapilledema



# Apparent optic nerve head swelling in childhood



## Optic Neuritis


- Often follows...viral illness, immunization
- HPI may be suggestive of CNS involvement w/ c/o...HA, lethargy, N/V
- VA loss often... *how bad?*

*Three causes of apparent swelling of pediatric ONH*

## Papilledema

## Pseudopapilledema

# Apparent optic nerve head swelling in childhood




## Optic Neuritis


- Often follows...viral illness, immunization
- HPI may be suggestive of CNS involvement w/ c/o...HA, lethargy, N/V
- VA loss often...severe

*Three causes of apparent swelling of pediatric ONH*

## Papilledema

## Pseudopapilledema





# Apparent optic nerve head swelling in childhood


## Optic Neuritis


- Often follows...viral illness, immunization
- HPI may be suggestive of CNS involvement w/ c/o...HA, lethargy, N/V
- VA loss often...severe
- Frequently... *unilateral vs bilateral*

*Three causes of apparent swelling of pediatric ONH*

Papilledema

Pseudopapilledema





# Apparent optic nerve head swelling in childhood

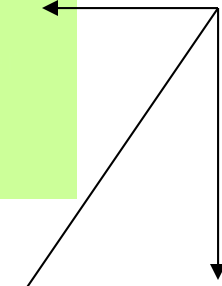
## Optic Neuritis

- Often follows...viral illness, immunization
- HPI may be suggestive of CNS involvement w/ c/o...HA, lethargy, N/V
- VA loss often...severe
- Frequently...bilateral

*Three causes of apparent swelling of pediatric ONH*

## Papilledema

## Pseudopapilledema



# Apparent optic nerve head swelling in childhood


## Optic Neuritis

- Often follows...viral illness, immunization
- HPI may be suggestive of CNS involvement w/ c/o...HA, lethargy, N/V
- VA loss often...severe
- Frequently...bilateral
- Disc swelling...*how common? How severe?*

*Three causes of apparent swelling of pediatric ONH*

Papilledema

Pseudopapilledema



# Apparent optic nerve head swelling in childhood

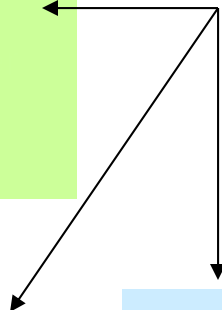
## Optic Neuritis

- Often follows...viral illness, immunization
- HPI may be suggestive of CNS involvement w/ c/o...HA, lethargy, N/V
- VA loss often...severe
- Frequently...bilateral
- Disc swelling...common, extensive

*Three causes of apparent swelling of pediatric ONH*

## Papilledema

## Pseudopapilledema



# Apparent optic nerve head swelling in childhood


## Optic Neuritis

- Often follows...viral illness, immunization
- HPI may be suggestive of CNS involvement w/ c/o...HA, lethargy, N/V
- VA loss often...severe
- Frequently...bilateral
- Disc swelling...common, extensive
- Relationship to MS...*how well established?*

*Three causes of apparent swelling of pediatric ONH*

Papilledema

Pseudopapilledema



# Apparent optic nerve head swelling in childhood

## Optic Neuritis


- Often follows...viral illness, immunization
- HPI may be suggestive of CNS involvement w/ c/o...HA, lethargy, N/V
- VA loss often...severe
- Frequently...bilateral
- Disc swelling...common, extensive
- Relationship to MS...unclear

*Three causes of apparent swelling of pediatric ONH*

Papilledema

Pseudopapilledema





# Apparent optic nerve head swelling in childhood

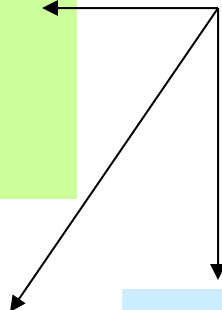
## Optic Neuritis

- Often follows...viral illness, immunization
- HPI may be suggestive of CNS involvement w/ c/o...HA, lethargy, N/V
- VA loss often...severe
- Frequently...bilateral
- Disc swelling...common, extensive
- Relationship to MS...unclear
- Treat with...

*Three causes of apparent swelling of pediatric ONH*

## Papilledema

## Pseudopapilledema



# Apparent optic nerve head swelling in childhood


## Optic Neuritis


- Often follows...viral illness, immunization
- HPI may be suggestive of CNS involvement w/ c/o...HA, lethargy, N/V
- VA loss often...severe
- Frequently...bilateral
- Disc swelling...common, extensive
- Relationship to MS...unclear
- Treat with...IV steroids

*Three causes of apparent swelling of pediatric ONH*

Papilledema

Pseudopapilledema



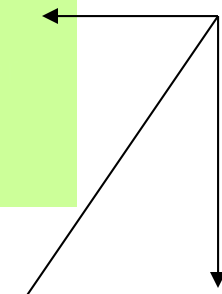


# Apparent optic nerve head swelling in childhood

## Optic Neuritis

- Often follows...viral illness, immunization
- HPI may be suggestive of CNS involvement w/ c/o...HA, lethargy, N/V
- VA loss often...severe
- Frequently...bilateral
- Disc swelling...common, extensive
- Relationship to MS...unclear
- Treat with...IV steroids
- Neuroretinitis**
  - DFE: Disc swelling +

*Three causes of apparent swelling of pediatric ONH*



## Papilledema

## Pseudopapilledema

# Apparent optic nerve head swelling in childhood

## Optic Neuritis

- Often follows...viral illness, immunization
- HPI may be suggestive of CNS involvement w/ c/o...HA, lethargy, N/V
- VA loss often...severe
- Frequently...bilateral
- Disc swelling...common, extensive
- Relationship to MS...unclear
- Treat with...IV steroids
- Neuroretinitis**
  - DFE: Disc swelling + macular star

*Three causes of apparent swelling of pediatric ONH*

Papilledema

Pseudopapilledema

# Apparent optic nerve head swelling in childhood

## Optic Neuritis

- Often follows...viral illness, immunization
- HPI may be suggestive of CNS involvement w/ c/o...HA, lethargy, N/V
- VA loss often...severe
- Frequently...bilateral
- Disc swelling...common, extensive
- Relationship to MS...unclear
- Treat with...IV steroids


## --Neuroretinitis

- DFE: Disc swelling + macular star
- Star is due to edema of...*(specific retinal layer)*

*Three causes of apparent swelling of pediatric ONH*

Papilledema

Pseudopapilledema



# Apparent optic nerve head swelling in childhood


## Optic Neuritis

- Often follows...viral illness, immunization
- HPI may be suggestive of CNS involvement w/ c/o...HA, lethargy, N/V
- VA loss often...severe
- Frequently...bilateral
- Disc swelling...common, extensive
- Relationship to MS...unclear
- Treat with...IV steroids
- Neuroretinitis**
  - DFE: Disc swelling + macular star
  - Star is due to edema of...Henle's layer

*Three causes of apparent swelling of pediatric ONH*

Papilledema

Pseudopapilledema



# Apparent optic nerve head swelling in childhood

## Optic Neuritis

- Often follows...viral illness, immunization
- HPI may be suggestive of CNS involvement w/ c/o...HA, lethargy, N/V
- VA loss often...severe
- Frequently...bilateral
- Disc swelling...common, extensive
- Relationship to MS...unclear
- Treat with...IV steroids

## --Neuroretinitis


- DFE: Disc swelling + macular star
- Star is due to edema of...**Henle's layer**


*Which retinal layer is aka Henle's layer?*

*Three causes of apparent swelling of pediatric ONH*

Papilledema

Pseudopapilledema





# Apparent optic nerve head swelling in childhood

## Optic Neuritis

- Often follows...viral illness, immunization
- HPI may be suggestive of CNS involvement w/ c/o...HA, lethargy, N/V
- VA loss often...severe
- Frequently...bilateral
- Disc swelling...common, extensive
- Relationship to MS...unclear
- Treat with...IV steroids

## --Neuroretinitis

- DFE: Disc swelling + macular star
- Star is due to edema of...**Henle's layer**

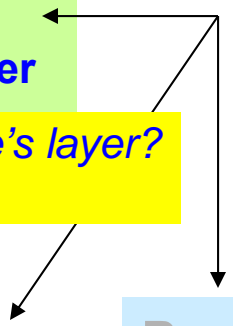
*Three causes of apparent swelling of pediatric ONH*

*Which retinal layer is aka Henle's layer?*

The outer vs inner **plexiform layer**

## Papilledema

## Pseudopapilledema





# Apparent optic nerve head swelling in childhood

## Optic Neuritis

- Often follows...viral illness, immunization
- HPI may be suggestive of CNS involvement w/ c/o...HA, lethargy, N/V
- VA loss often...severe
- Frequently...bilateral
- Disc swelling...common, extensive
- Relationship to MS...unclear
- Treat with...IV steroids

## --Neuroretinitis


- DFE: Disc swelling + macular star
- Star is due to edema of...**Henle's layer**

*Which retinal layer is aka Henle's layer?*  
The **outer plexiform layer**

*Three causes of apparent swelling of pediatric ONH*

Papilledema

Pseudopapilledema





# Apparent optic nerve head swelling in childhood

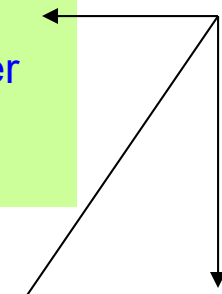
## Optic Neuritis

- Often follows...viral illness, immunization
- HPI may be suggestive of CNS involvement w/ c/o...HA, lethargy, N/V
- VA loss often...severe
- Frequently...bilateral
- Disc swelling...common, extensive
- Relationship to MS...unclear
- Treat with...IV steroids

## --Neuroretinitis

- DFE: Disc swelling + macular star
- Star is due to edema of...Henle's layer
- Associated with bug infection
- or noninfectious condition (three words)


*Three causes of apparent swelling of pediatric ONH*



## Papilledema

## Pseudopapilledema

# Apparent optic nerve head swelling in childhood



## Optic Neuritis

- Often follows...viral illness, immunization
- HPI may be suggestive of CNS involvement w/ c/o...HA, lethargy, N/V
- VA loss often...severe
- Frequently...bilateral
- Disc swelling...common, extensive
- Relationship to MS...unclear
- Treat with...IV steroids


## --Neuroretinitis

- DFE: Disc swelling + macular star
- Star is due to edema of...Henle's layer
- Associated with *B. henslae* infection or Leber's idiopathic neuroretinitis

*Three causes of apparent swelling of pediatric ONH*

Papilledema

Pseudopapilledema



# Apparent optic nerve head swelling in childhood

## Optic Neuritis

- Often follows...viral illness, immunization
- HPI may be suggestive of CNS involvement w/ c/o...HA, lethargy, N/V
- VA loss often...severe
- Frequently...bilateral
- Disc swelling...common, extensive
- Relationship to MS...unclear
- Treat with...IV steroids


*What other ocular disease is B. henslae commonly associated with?*

- Associated with **B. henslae** infection or Leber's idiopathic neuroretinitis


*Three causes of apparent swelling of pediatric ONH*

## Papilledema

## Pseudopapilledema



# Apparent optic nerve head swelling in childhood



## Optic Neuritis


- Often follows...viral illness, immunization
- HPI may be suggestive of CNS involvement w/ c/o...HA, lethargy, N/V
- VA loss often...severe
- Frequently...bilateral
- Disc swelling...common, extensive
- Relationship to MS...unclear
- Treat with...IV steroids
- What other ocular disease is B. henslae commonly associated with?*
- Parinaud's oculoglandular syndrome
- Associated with **B. henslae** infection or Leber's idiopathic neuroretinitis

*Three causes of apparent swelling of pediatric ONH*

## Papilledema

## Pseudopapilledema

# Apparent optic nerve head swelling in childhood



## Optic Neuritis

- Often follows...viral illness, immunization
- HPI may be suggestive of CNS involvement w/ c/o...HA, lethargy, N/V
- VA loss often...severe
- Frequently...bilateral
- Disc swelling...common, extensive
- Relationship to MS...unclear
- Treat with...IV steroids

## --Neuroretinitis


- DFE: Disc swelling + macular star
- Star is due to edema of...Henle's layer
- Associated with *B. henslae* infection or Leber's idiopathic neuroretinitis

*Three causes of apparent swelling of pediatric ONH*

## Papilledema

- By definition, 2° to...

## Pseudopapilledema



# Apparent optic nerve head swelling in childhood

## Optic Neuritis

- Often follows...viral illness, immunization
- HPI may be suggestive of CNS involvement w/ c/o...HA, lethargy, N/V
- VA loss often...severe
- Frequently...bilateral
- Disc swelling...common, extensive
- Relationship to MS...unclear
- Treat with...IV steroids

## --Neuroretinitis

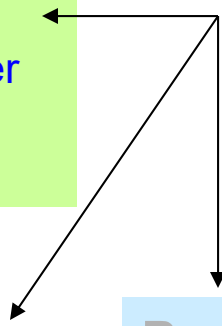
- DFE: Disc swelling + macular star
- Star is due to edema of...Henle's layer
- Associated with *B. henslae* infection or Leber's idiopathic neuroretinitis

*Three causes of apparent swelling of pediatric ONH*


## Papilledema

- By definition, 2° to...increased ICP

## Pseudopapilledema



# Apparent optic nerve head swelling in childhood



## Optic Neuritis

- Often follows...viral illness, immunization
- HPI may be suggestive of CNS involvement w/ c/o...HA, lethargy, N/V
- VA loss often...severe
- Frequently...bilateral
- Disc swelling...common, extensive
- Relationship to MS...unclear
- Treat with...IV steroids
- Neuroretinitis**
  - DFE: Disc swelling + macular star
  - Star is due to edema of...Henle's layer
  - Associated with *B. henslae* infection or Leber's idiopathic neuroretinitis

*Three causes of apparent swelling of pediatric ONH*


## Papilledema

- By definition, 2° to...increased ICP
- Common causes:
  - 
  - 
  -

## Pseudopapilledema



# Apparent optic nerve head swelling in childhood



## Optic Neuritis

- Often follows...viral illness, immunization
- HPI may be suggestive of CNS involvement w/ c/o...HA, lethargy, N/V
- VA loss often...severe
- Frequently...bilateral
- Disc swelling...common, extensive
- Relationship to MS...unclear
- Treat with...IV steroids
- Neuroretinitis**
  - DFE: Disc swelling + macular star
  - Star is due to edema of...Henle's layer
  - Associated with *B. henslae* infection or Leber's idiopathic neuroretinitis


*Three causes of apparent swelling of pediatric ONH*

## Papilledema

- By definition, 2° to...increased ICP
- Common causes:
  - Tumor
  - Hydrocephalus
  - Pseudotumor cerebri

## Pseudopapilledema

# Apparent optic nerve head swelling in childhood



## Optic Neuritis

- Often follows...viral illness, immunization
- HPI may be suggestive of CNS involvement w/ c/o...HA, lethargy, N/V
- VA loss often...severe
- Frequently...bilateral
- Disc swelling...common, extensive
- Relationship to MS...unclear
- Treat with...IV steroids
- Neuroretinitis**
  - DFE: Disc swelling + macular star
  - Star is due to edema of...Henle's layer
  - Associated with *B. henslae* infection or Leber's idiopathic neuroretinitis

*Three causes of apparent swelling of pediatric ONH*


## Papilledema

- By definition, 2° to...increased ICP
- Common causes:
  - Tumor
  - Hydrocephalus
  - Pseudotumor cerebri

## Pseudopapilledema

- Most common cause:

# Apparent optic nerve head swelling in childhood



## Optic Neuritis

- Often follows...viral illness, immunization
- HPI may be suggestive of CNS involvement w/ c/o...HA, lethargy, N/V
- VA loss often...severe
- Frequently...bilateral
- Disc swelling...common, extensive
- Relationship to MS...unclear
- Treat with...IV steroids

## --Neuroretinitis

- DFE: Disc swelling + macular star
- Star is due to edema of...Henle's layer
- Associated with *B. henslae* infection or Leber's idiopathic neuroretinitis

*Three causes of apparent swelling of pediatric ONH*


## Papilledema

- By definition, 2° to...increased ICP
- Common causes:
  - Tumor
  - Hydrocephalus
  - Pseudotumor cerebri

## Pseudopapilledema

- Most common cause: **Optic disc drusen**

# Apparent optic nerve head swelling in childhood



## Optic Neuritis

- Often follows...viral illness, immunization
- HPI may be suggestive of CNS involvement w/ c/o...HA, lethargy, N/V
- VA loss often...severe
- Frequently...bilateral
- Disc swelling...common, extensive
- Relationship to MS...unclear
- Treat with...IV steroids

## --Neuroretinitis

- DFE: Disc swelling + macular star
- Star is due to edema of...Henle's layer
- Associated with *B. henslae* infection or Leber's idiopathic neuroretinitis


*Three causes of apparent swelling of pediatric ONH*

## Papilledema

- By definition, 2° to...increased ICP
- Common causes:
  - Tumor
  - Hydrocephalus
  - Pseudotumor cerebri

## Pseudopapilledema

- Most common cause: **Optic disc drusen**
  - Inherited (check parents)



# Apparent optic nerve head swelling in childhood

## Optic Neuritis

- Often follows...viral illness, immunization
- HPI may be suggestive of CNS involvement w/ c/o...HA, lethargy, N/V
- VA loss often...severe
- Frequently...bilateral
- Disc swelling...common, extensive
- Relationship to MS...unclear
- Treat with...IV steroids

## Neuroretinitis

- DFE: Disc swelling + macular star
- Star is due to edema of...Henle's layer
- Associated with *B. henslae* infection or Leber's idiopathic neuroretinitis

*Three causes of apparent swelling of pediatric ONH*

## Papilledema

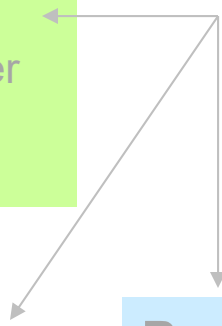
- By definition, 2° to...**increased ICP**
- Common causes:
  - Tumor
  - Hydrocephalus
  - Pseudotumor cerebri

## Pseudopapilledema


- Most common cause: **Optic disc drusen**
- Inherited (check parents)

*What tests can be used to confirm the presence of disc drusen?*

- 
- 



# Apparent optic nerve head swelling in childhood



## Optic Neuritis

- Often follows...viral illness, immunization
- HPI may be suggestive of CNS involvement w/ c/o...HA, lethargy, N/V
- VA loss often...severe
- Frequently...bilateral
- Disc swelling...common, extensive
- Relationship to MS...unclear
- Treat with...IV steroids

## --Neuroretinitis

- DFE: Disc swelling + macular star
- Star is due to edema of...Henle's layer
- Associated with *B. henslae* infection or Leber's idiopathic neuroretinitis

*Three causes of apparent swelling of pediatric ONH*

## Papilledema


- By definition, 2° to...**increased ICP**
- Common causes:
  - Tumor
  - Hydrocephalus
  - Pseudotumor cerebri

## Pseudopapilledema

- Most common cause: **Optic disc drusen**
- Inherited (check parents)

*What tests can be used to confirm the presence of disc drusen?*

- b-scan**
- CT**



# Apparent optic nerve head swelling in childhood

## Optic Neuritis

- Often follows...viral illness, immunization
- HPI may be suggestive of CNS involvement w/ c/o...HA, lethargy, N/V
- VA loss often...severe
- Frequently...bilateral
- Disc swelling...common, extensive
- Relationship to MS...unclear
- Treat with...IV steroids

## Neuroretinitis

- DFE: Disc swelling + macular star
- Star is due to edema of...Henle's layer
- Associated with *B. henslae* infection or Leber's idiopathic neuroretinitis

*Three causes of apparent swelling of pediatric ONH*

## Papilledema

- By definition, 2° to...**increased ICP**
- Common causes:
  - Tumor
  - Hydrocephalus
  - Pseudotumor cerebri

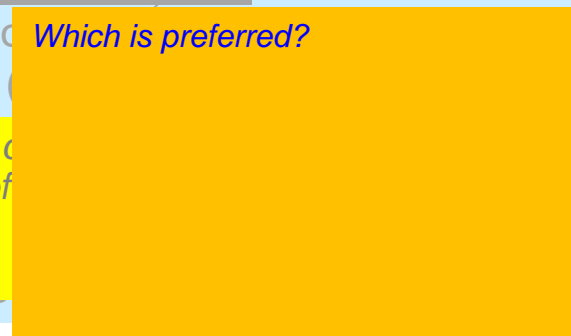
## Pseudopapilledema


--Most common *Which is preferred?*

--Inherited

What tests of presence of

- b-scan**
- CT**





# Apparent optic nerve head swelling in childhood

## Optic Neuritis

- Often follows...viral illness, immunization
- HPI may be suggestive of CNS involvement w/ c/o...HA, lethargy, N/V
- VA loss often...severe
- Frequently...bilateral
- Disc swelling...common, extensive
- Relationship to MS...unclear
- Treat with...IV steroids

## --Neuroretinitis

- DFE: Disc swelling + macular star
- Star is due to edema of...Henle's layer
- Associated with *B. henslae* infection or Leber's idiopathic neuroretinitis

*Three causes of apparent swelling of pediatric ONH*

## Papilledema

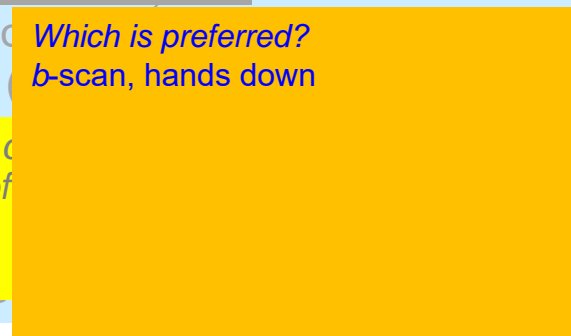
- By definition, 2° to...**increased ICP**
- Common causes:
  - Tumor
  - Hydrocephalus
  - Pseudotumor cerebri

## Pseudopapilledema


- Most common *Which is preferred?*
- Inherited *b-scan, hands down*

*What tests of presence of*

- b-scan**
- CT**







# Apparent optic nerve head swelling in childhood

## Optic Neuritis

- Often follows...viral illness, immunization
- HPI may be suggestive of CNS involvement w/ c/o...HA, lethargy, N/V
- VA loss often...severe
- Frequently...bilateral
- Disc swelling...common, extensive
- Relationship to MS...unclear
- Treat with...IV steroids
- Neuroretinitis**
  - DFE: Disc swelling + macular star
  - Star is due to edema of...Henle's layer
  - Associated with *B. henslae* infection or Leber's idiopathic neuroretinitis

*Three causes of apparent swelling of pediatric ONH*

## Papilledema

- By definition, 2° to...**increased ICP**
- Common causes:
  - Tumor
  - Hydrocephalus
  - Pseudotumor cerebri

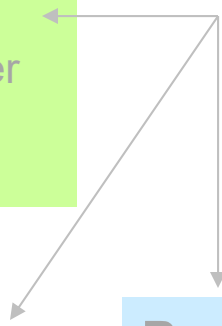
## Pseudopapilledema


- Most common *Which is preferred?*
- Inherited *b-scan, hands down*

*What tests of presence of*

- b-scan**
- CT**

*Why?*





# Apparent optic nerve head swelling in childhood

## Optic Neuritis

- Often follows...viral illness, immunization
- HPI may be suggestive of CNS involvement w/ c/o...HA, lethargy, N/V
- VA loss often...severe
- Frequently...bilateral
- Disc swelling...common, extensive
- Relationship to MS...unclear
- Treat with...IV steroids
- Neuroretinitis**
  - DFE: Disc swelling + macular star
  - Star is due to edema of...Henle's layer
  - Associated with *B. henslae* infection or Leber's idiopathic neuroretinitis

*Three causes of apparent swelling of pediatric ONH*

## Papilledema

- By definition, 2° to...**increased ICP**
- Common causes:
  - Tumor
  - Hydrocephalus
  - Pseudotumor cerebri

## Pseudopapilledema

- Most common
- Inherited


*Which is preferred?*  
**b-scan, hands down**

*What tests of presence of*

- b-scan**
- CT**

*Why?*  
Because CT involves giving a big dose of radiation to a developing child's head--something to be avoided whenever possible

# Apparent optic nerve head swelling in childhood



## Optic Neuritis

- Often follows...viral illness, immunization
- HPI may be suggestive of CNS involvement w/ c/o...HA, lethargy, N/V
- VA loss often...severe
- Frequently...bilateral
- Disc swelling...common, extensive
- Relationship to MS...unclear
- Treat with...IV steroids
- Neuroretinitis**
  - DFE: Disc swelling + macular star
  - Star is due to edema of...Henle's layer
  - Associated with *B. henslae* infection or Leber's idiopathic neuroretinitis


*Three causes of apparent swelling of pediatric ONH*

## Papilledema

- By definition, 2° to...increased ICP
- Common causes:
  - Tumor
  - Hydrocephalus
  - Pseudotumor cerebri

## Pseudopapilledema

- Most common cause: **Optic disc drusen**
  - Inherited (check parents)
  - DFE: Disc elevated with regular v irregular border;
  - vessels two words



# Apparent optic nerve head swelling in childhood

## Optic Neuritis

- Often follows...viral illness, immunization
- HPI may be suggestive of CNS involvement w/ c/o...HA, lethargy, N/V
- VA loss often...severe
- Frequently...bilateral
- Disc swelling...common, extensive
- Relationship to MS...unclear
- Treat with...IV steroids
- Neuroretinitis**
  - DFE: Disc swelling + macular star
  - Star is due to edema of...Henle's layer
  - Associated with *B. henslae* infection or Leber's idiopathic neuroretinitis

*Three causes of apparent swelling of pediatric ONH*


## Papilledema

- By definition, 2° to...increased ICP
- Common causes:
  - Tumor
  - Hydrocephalus
  - Pseudotumor cerebri

## Pseudopapilledema

- Most common cause: **Optic disc drusen**
  - Inherited (check parents)
  - DFE: Disc elevated with irregular border; vessels not obscured

# Apparent optic nerve head swelling in childhood



## Optic Neuritis

- Often follows...viral illness, immunization
- HPI may be suggestive of CNS involvement w/ c/o...HA, lethargy, N/V
- VA loss often...severe
- Frequently...bilateral
- Disc swelling...common, extensive
- Relationship to MS...unclear
- Treat with...IV steroids
- Neuroretinitis**
  - DFE: Disc swelling + macular star
  - Star is due to edema of...Henle's layer
  - Associated with *B. henslae* infection or Leber's idiopathic neuroretinitis


*Three causes of apparent swelling of pediatric ONH*

## Papilledema

- By definition, 2° to...increased ICP
- Common causes:
  - Tumor
  - Hydrocephalus
  - Pseudotumor cerebri

## Pseudopapilledema

- Most common cause: **Optic disc drusen**
  - Inherited (check parents)
  - DFE: Disc elevated with irregular border; vessels not obscured
  - VF defects... common vs uncommon



# Apparent optic nerve head swelling in childhood

## Optic Neuritis

- Often follows...viral illness, immunization
- HPI may be suggestive of CNS involvement w/ c/o...HA, lethargy, N/V
- VA loss often...severe
- Frequently...bilateral
- Disc swelling...common, extensive
- Relationship to MS...unclear
- Treat with...IV steroids
- Neuroretinitis**
  - DFE: Disc swelling + macular star
  - Star is due to edema of...Henle's layer
  - Associated with *B. henslae* infection or Leber's idiopathic neuroretinitis

*Three causes of apparent swelling of pediatric ONH*

## Papilledema

- By definition, 2° to...increased ICP
- Common causes:
  - Tumor
  - Hydrocephalus
  - Pseudotumor cerebri

## Pseudopapilledema

- Most common cause: **Optic disc drusen**
  - Inherited (check parents)
  - DFE: Disc elevated with irregular border; vessels not obscured
  - VF defects...common

# Apparent optic nerve head swelling in childhood



## Optic Neuritis

- Often follows...viral illness, immunization
- HPI may be suggestive of CNS involvement w/ c/o...HA, lethargy, N/V
- VA loss often...severe
- Frequently...bilateral
- Disc swelling...common, extensive
- Relationship to MS...unclear
- Treat with...IV steroids
- Neuroretinitis**
  - DFE: Disc swelling + macular star
  - Star is due to edema of...Henle's layer
  - Associated with *B. henslae* infection or Leber's idiopathic neuroretinitis

*Three causes of apparent swelling of pediatric ONH*


## Papilledema

- By definition, 2° to...increased ICP
- Common causes:
  - Tumor
  - Hydrocephalus
  - Pseudotumor cerebri

## Pseudopapilledema

- Most common cause: **Optic disc drusen**
  - Inherited (check parents)
  - DFE: Disc elevated with irregular border; vessels not obscured
  - VF defects...common
  - Decreased acuity...common vs uncommon

# Apparent optic nerve head swelling in childhood



## Optic Neuritis

- Often follows...viral illness, immunization
- HPI may be suggestive of CNS involvement w/ c/o...HA, lethargy, N/V
- VA loss often...severe
- Frequently...bilateral
- Disc swelling...common, extensive
- Relationship to MS...unclear
- Treat with...IV steroids
- Neuroretinitis**
  - DFE: Disc swelling + macular star
  - Star is due to edema of...Henle's layer
  - Associated with *B. henslae* infection or Leber's idiopathic neuroretinitis

*Three causes of apparent swelling of pediatric ONH*

## Papilledema

- By definition, 2° to...increased ICP
- Common causes:
  - Tumor
  - Hydrocephalus
  - Pseudotumor cerebri

## Pseudopapilledema

- Most common cause: **Optic disc drusen**
  - Inherited (check parents)
  - DFE: Disc elevated with irregular border; vessels not obscured
  - VF defects...common
  - Decreased acuity...uncommon