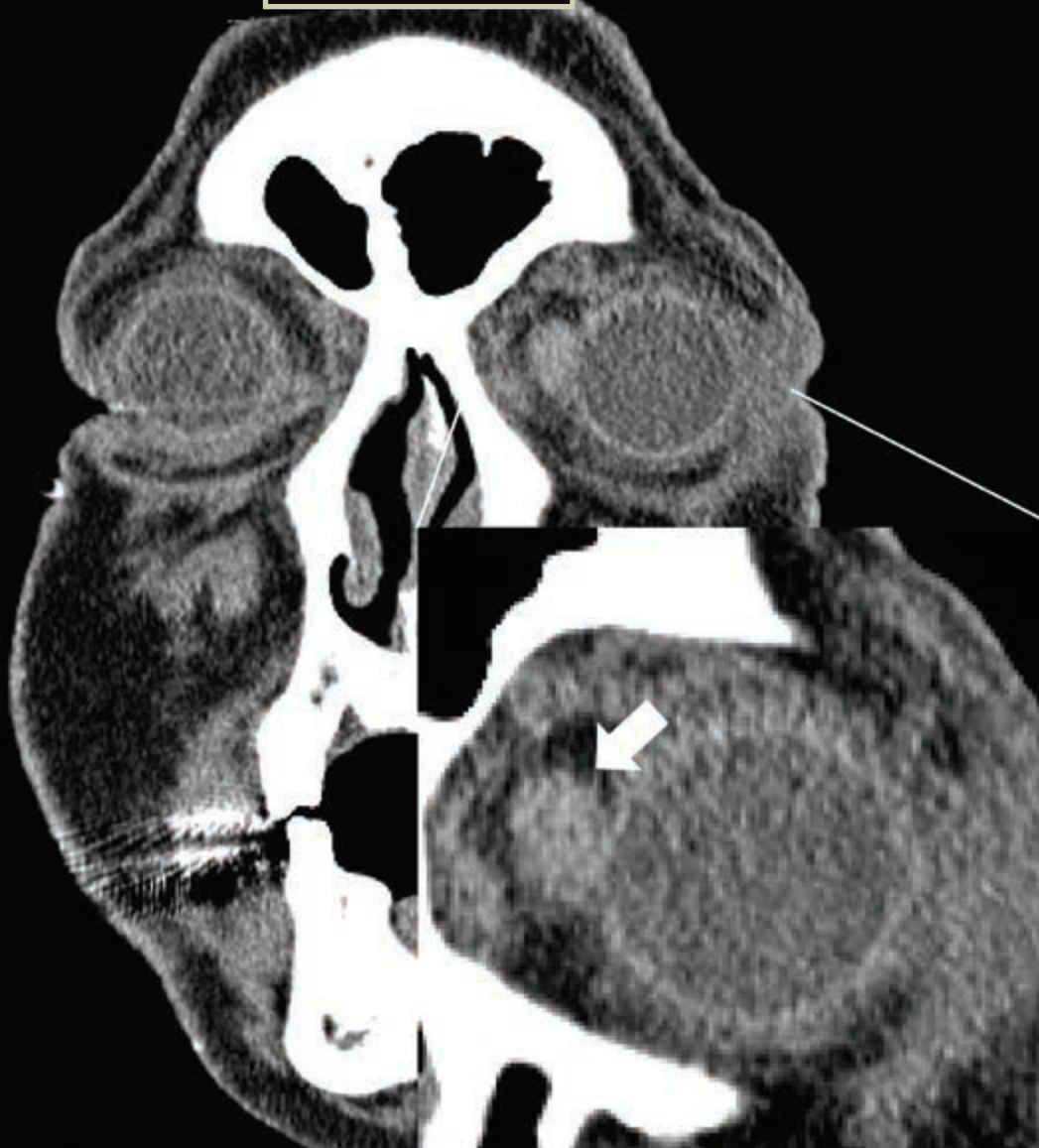

Blink



RICHARD Y. HWANG, MD, PHD, AND KAREN JOOS, MD, PHD, VANDERBILT EYE INSTITUTE, NASHVILLE, TENN.

WHAT IS THIS MONTH'S MYSTERY CONDITION? Join the conversation at www.eyenet.org, where you can post a comment on this image.

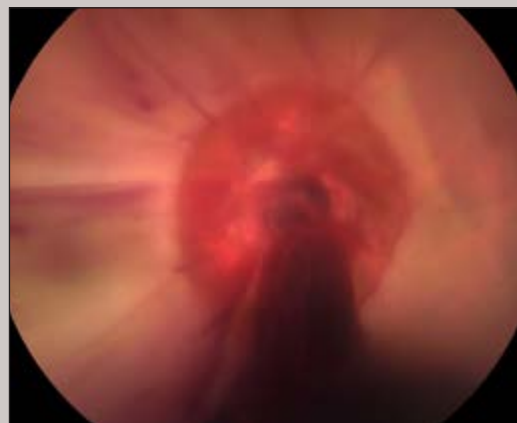
LAST MONTH'S BLINK

Optic Nerve Avulsion

A 25-year-old man presented with loss of vision in his right eye after falling off his bicycle the previous night. He admitted to intoxication at the time of injury. On examination, he had no light perception in the affected right eye. His right pupil was dilated and nonreactive.

Fundus examination revealed an avulsed optic nerve with venous blood emanating from the optic canal. Additionally, the retina was completely opacified, consistent with a concomitant retinal artery occlusion. No treatment was offered. At two-month follow-up, no vision had returned.

Written by Robin A. Vora, MD, The Permanente Medical Group, Oakland, Calif.



Apolonia Hilao-Bautista, The Permanente Medical Group, Oakland, Calif.