The Optic Nerve

In creating/revising this slide-set, I consulted the four *BCSC* books that have a lot to say on the subject: *Fundamentals*, *Neuro-Oph*, *Path* and *Glaucoma*. Unfortunately, all four differed from one another regarding many aspects of optic nerve anatomy. Some of these differences were trivial; others not so much.

As a comprehensive ophthalmologist, I have no familiarity with the primary literature concerning ophthalmic anatomy and histology. Thus, *I am in no position to declare which book is correct regarding points on which they differ.* The following slides represent my best attempt at compiling the disparate information in a manner that is reasonable and memorable. (As a matter of both interest and information, I have included some of the differing answers regarding certain aspects of the nerve.)

My main point: When answering questions regarding the optic nerve--whether such questions occur in a pimping session, on the OKAP or during the Boards--adopt and maintain a stance of flexibility.

The Optic Nerve

In creating/revising this slide-set, I consulted the four *BCSC* books that have a lot to say on the subject: *Fundamentals*, *Neuro-Oph*, *Path* and *Glaucoma*. Unfortunately, all four differed from one another regarding many aspects of

tl;dr:
--When asked an optic-nerve question requiring a numeric response, phrase your answer along these lines: 'Well, bearing in mind the considerable anatomic variability that characterizes the optic nerve, a reasonable estimate would be *x*.'
--When asked a question about optic-nerve vasculature, begin your response with 'Bearing in mind that there is not universal agreement regarding this, many experts believe…'

answers regarding certain aspects of the nerve.)

My main point: When answering questions regarding the optic nerve--whether such questions occur in a pimping session, on the OKAP or during the Boards--adopt and maintain a stance of flexibility.

Q

The Optic Nerve

The optic nerves are composed of what?

A

The Optic Nerve

The optic nerves are composed of what?

The axons of retinal ganglion cells

Q

The Optic Nerve

The optic nerves are composed of what?

The axons of retinal ganglion cells

How many fibers (axons) comprise an optic nerve?

A

The Optic Nerve

The optic nerves are composed of what?

The axons of retinal ganglion cells

How many fibers (axons) comprise an optic nerve?

Depends upon which book you ask, but the answer **1.2M** works

Glaucoma book: 1.2-1.5M
Neuro: 1-1.2M
Fundamentals: “more than a million”

Q

The Optic Nerve

The optic nerves are composed of what?
The axons of retinal ganglion cells

Do they synapse in the region of the optic nerve head?

A

The Optic Nerve

The optic nerves are composed of what?
The axons of retinal ganglion cells

Do they synapse in the region of the optic nerve head?
No

Q

The Optic Nerve

The optic nerves are composed of what?
The axons of retinal ganglion cells

Do they synapse in the region of the optic nerve head?
No

Where will they synapse?

A

The Optic Nerve

The optic nerves are composed of what?
The axons of retinal ganglion cells

Do they synapse in the region of the optic nerve head?
No

Where will they synapse?
Most will synapse in the lateral geniculate nucleus (LGN)

Q

The Optic Nerve

The optic nerves are composed of what?
The axons of retinal ganglion cells

Do they synapse in the region of the optic nerve head?
No

Where will they synapse?
Most will synapse in the lateral geniculate nucleus (LGN)

Most? Where will the others synapse, and what are they responsible for?

A

The Optic Nerve

The optic nerves are composed of what?
The axons of retinal ganglion cells

Do they synapse in the region of the optic nerve head?
No

Where will they synapse?
Most will synapse in the lateral geniculate nucleus (LGN)

Most? Where will the others synapse, and what are they responsible for?
Most of the others are involved in the pupillary light reflex; they peel off just prior to reaching the LGN, heading instead to the pretectum of the dorsal midbrain to synapse in the pretectal nuclei

Q

The Optic Nerve

The optic nerves are composed of what?
The axons of retinal ganglion cells

Do they synapse in the region of the optic nerve head?
No

Where will they synapse?
Most will synapse in the lateral geniculate nucleus (LGN)

'Most'? Where will the others synapse, and what are they responsible for?
Most of the others are involved in the pupillary light reflex; they peel off just prior to reaching the LGN, heading instead to the pretectum of the dorsal midbrain to synapse in the pretectal nuclei

'Most'? Where will the others synapse, and what are they responsible for?

A

The Optic Nerve

The optic nerves are composed of what?
The axons of retinal ganglion cells

Do they synapse in the region of the optic nerve head?
No

Where will they synapse?
Most will synapse in the lateral geniculate nucleus (LGN)

'Most'? Where will the others synapse, and what are they responsible for?
Most of the others are involved in the pupillary light reflex; they peel off just prior to reaching the LGN, heading instead to the pretectum of the dorsal midbrain to synapse in the pretectal nuclei

'Most'? Where will the others synapse, and what are they responsible for?
The hypothalamus, where they are involved in modulating circadian responses

Q

The Optic Nerve

The optic nerves are composed of what?
The axons of retinal ganglion cells

Do they synapse in the region of the optic nerve head?
No

Where will they synapse?
Most will synapse in the lateral geniculate nucleus (LGN)

Most? Where will the others synapse, and what are they responsible for?
Most of the others are **involved in the pupillary light reflex**; they peel off just prior to reaching the LGN, heading instead to **the pretectum** of the dorsal midbrain to synapse in the pretectal nuclei

'Most'? Where will the others synapse, and what are they responsible for?

There is an important clinical entity caused by damage to the pretectum. This entity has four classic findings, one of which involves the pupils. What is the eponymous name of this clinical entity?

A

The Optic Nerve

The optic nerves are composed of what?
The axons of retinal ganglion cells

Do they synapse in the region of the optic nerve head?
No

Where will they synapse?
Most will synapse in the lateral geniculate nucleus (LGN)

Most? Where will the others synapse, and what are they responsible for?
Most of the others are **involved in the pupillary light reflex**; they peel off just prior to reaching the LGN, heading instead to **the pretectum** of the dorsal midbrain to synapse in the pretectal nuclei

'Most'? Where will the others synapse, and what are they responsible for?

There is an important clinical entity caused by damage to the pretectum. This entity has four classic findings, one of which involves the pupils. What is the eponymous name of this clinical entity?
Parinaud syndrome

Q

The Optic Nerve

The optic nerves are composed of what?
The axons of retinal ganglion cells

Do they synapse in the region of the optic nerve head?
No

Where will they synapse?
Most will synapse in the lateral geniculate nucleus (LGN)

Most? Where will the others synapse, and what are they responsible for?
Most of the others are **involved in the pupillary light reflex**; they peel off just prior to reaching the LGN, heading instead to **the pretectum** of the dorsal midbrain to synapse in the pretectal nuclei

'Most'? Where will the others synapse, and what are they responsible for?

There is an important clinical entity caused by damage to the pretectum. This entity has four classic findings, one of which involves the pupils. What is the eponymous name of this clinical entity?
Parinaud syndrome

What is the classic pupil finding in Parinaud syndrome?

A

The Optic Nerve

The optic nerves are composed of what?
The axons of retinal ganglion cells

Do they synapse in the region of the optic nerve head?
No

Where will they synapse?
Most will synapse in the lateral geniculate nucleus (LGN)

Most? Where will the others synapse, and what are they responsible for?
Most of the others are **involved in the pupillary light reflex**; they peel off just prior to reaching the LGN, heading instead to **the pretectum** of the dorsal midbrain to synapse in the pretectal nuclei

'Most'? Where will the others synapse, and what are they responsible for?

There is an important clinical entity caused by damage to the pretectum. This entity has four classic findings, one of which involves the pupils. What is the eponymous name of this clinical entity?
Parinaud syndrome

What is the classic pupil finding in Parinaud syndrome?
Light-near dissociation

Q

The Optic Nerve

The optic nerves are composed of what?
The axons of retinal ganglion cells

Do they synapse in the region of the optic nerve head?
No

Where will they synapse?
Most will synapse in the lateral geniculate nucleus (LGN)

Most? Where will the others synapse, and what are they responsible for?
Most of the others are **involved in the pupillary light reflex**; they peel off just prior to reaching the LGN, heading instead to **the pretectum** of the dorsal midbrain to synapse in the pretectal nuclei

'Most'? Where will the others synapse, and what are they responsible for?

There is an important clinical entity caused by damage to the pretectum. This entity has four classic findings, one of which involves the pupils. What is the eponymous name of this clinical entity?
Parinaud syndrome

What is the classic pupil finding in Parinaud syndrome?
Light-near dissociation

What is light-near dissociation*?*

A

The Optic Nerve

The optic nerves are composed of what?
The axons of retinal ganglion cells

Do they synapse in the region of the optic nerve head?
No

Where will they synapse?
Most will synapse in the lateral geniculate nucleus (LGN)

Most? Where will the others synapse, and what are they responsible for?
Most of the others are **involved in the pupillary light reflex**; they peel off just prior to reaching the LGN, heading instead to **the pretectum** of the dorsal midbrain to synapse in the pretectal nuclei

'Most'? Where will the others synapse, and what are they responsible for?

There is an important clinical entity caused by damage to the pretectum. This entity has four classic findings, one of which involves the pupils. What is the eponymous name of this clinical entity?
Parinaud syndrome

What is the classic pupil finding in Parinaud syndrome?
Light-near dissociation

What is light-near dissociation*?*
A phenomena in which the pupils miose less robustly in response to light than they do as part of the near response

Q

The Optic Nerve

The optic nerves are composed of what?
The axons of retinal ganglion cells

Do they synapse in the region of the optic nerve head?
No

Where will they synapse?
Most will synapse in the lateral geniculate nucleus (LGN)

Most? Where will the others synapse, and what are they responsible for?
Most of the others are **involved in the pupillary light reflex**; they peel off just prior to reaching the LGN, heading instead to **the pretectum** of the dorsal midbrain to synapse in the pretectal nuclei

'Most'? Where will the others synapse, and what are they responsible for?

There is an important clinical entity caused by damage to the pretectum. This entity has four classic findings, ity?
Parinau

What is t
Light-ne

The near response is often referred to by what number-related name?

What is light-ne
A phenomena in which the pupils miose less robustly in response to light than they do as part of the **near response**

A

The Optic Nerve

The optic nerves are composed of what?
The axons of retinal ganglion cells

Do they synapse in the region of the optic nerve head?
No

Where will they synapse?
Most will synapse in the lateral geniculate nucleus (LGN)

Most? Where will the others synapse, and what are they responsible for?
Most of the others are **involved in the pupillary light reflex**; they peel off just prior to reaching the LGN, heading instead to **the pretectum** of the dorsal midbrain to synapse in the pretectal nuclei

'Most'? Where will the others synapse, and what are they responsible for?

There is an important clinical entity caused by damage to the pretectum. This entity has four classic findings, ity?
Parinau

What is t
Light-ne

The near response is often referred to by what number-related name?
The near triad

What is light-ne
A phenomena in which the pupils miose less robustly in response to light than they do as part of the **near response**

Q

The Optic Nerve

The optic nerves are composed of what?
The axons of retinal ganglion cells

Do they synapse in the region of the optic nerve head?
No

Where will they synapse?
Most will synapse in the lateral geniculate nucleus (LGN)

Most? Where will the others synapse, and what are they responsible for?
Most of the others are **involved in the pupillary light reflex**; they peel off just prior to reaching the LGN, heading instead to **the pretectum** of the dorsal midbrain to synapse in the pretectal nuclei

'Most'? Where will the others synapse, and what are they responsible for?

There is an important clinical entity caused by damage to the pretectum. This entity has four classic findings, ity?
Parinau

What is t
Light-ne

What is light-ne
A phenomena in which the pupils miose less robustly in response to light than they do as part of the **near response**

The near response is often referred to by what number-related name?
The near triad

Other than miosis, what are the other ocular responses of the near triad?
--Miosis
--
--

A

The Optic Nerve

The optic nerves are composed of what?
The axons of retinal ganglion cells

Do they synapse in the region of the optic nerve head?
No

Where will they synapse?
Most will synapse in the lateral geniculate nucleus (LGN)

Most? Where will the others synapse, and what are they responsible for?
Most of the others are **involved in the pupillary light reflex**; they peel off just prior to reaching the LGN, heading instead to **the pretectum** of the dorsal midbrain to synapse in the pretectal nuclei

'Most'? Where will the others synapse, and what are they responsible for?

There is an important clinical entity caused by damage to the pretectum. This entity has four classic findings, ity?
Parinau

What is t
Light-ne

What is light-ne
A phenomena in which the pupils miose less robustly in response to light than they do as part of the **near response**

The near response is often referred to by what number-related name?
The near triad

Other than miosis, what are the other ocular responses of the near triad?
--Miosis
--Convergence
--Accommodation

Q

The Optic Nerve

The optic nerves are composed of what?
The axons of retinal ganglion cells

Do they synapse in the region of the optic nerve head?
No

Where will they synapse?
Most will synapse in the lateral geniculate nucleus (LGN)

Most? Where will the others synapse, and what are they responsible for?
Most of the others are **involved in the pupillary light reflex**; they peel off just prior to reaching the LGN, heading instead to **the pretectum of the dorsal midbrain to synapse in the pretectal nuclei**

'Most'? Where will the others synapse, and what are they responsible for?

There is an important clinical entity caused by damage to the pretectum. This entity has four classic findings, one of which involves the pupils. What is the eponymous name of this clinical entity?
Parinaud syndrome

What is the classic pupil finding in Parinaud syndrome?
Light-near dissociation

What are the two noneponymous names for Parinaud syndrome?
1)
2)

A

The Optic Nerve

The optic nerves are composed of what?
The axons of retinal ganglion cells

Do they synapse in the region of the optic nerve head?
No

Where will they synapse?
Most will synapse in the lateral geniculate nucleus (LGN)

Most? Where will the others synapse, and what are they responsible for?
Most of the others are **involved in the pupillary light reflex**; they peel off just prior to reaching the LGN, heading instead to **the pretectum of the dorsal midbrain to synapse in the pretectal nuclei**

'Most'? Where will the others synapse, and what are they responsible for?

There is an important clinical entity caused by damage to the pretectum. This entity has four classic findings, one of which involves the pupils. What is the eponymous name of this clinical entity?
Parinaud syndrome

What is the classic pupil finding in Parinaud syndrome?
Light-near dissociation

What are the two noneponymous names for Parinaud syndrome?
1) Dorsal midbrain syndrome
2) Pretectal syndrome

Q

The Optic Nerve



Anatomically speaking, the optic nerve is considered to have four portions. What are they?

Q/A

The Optic Nerve

Portion
Intraocular
?

(anterior)

(posterior)

Anatomically speaking, the optic nerve is considered to have four portions. What are they?

Q/A

The Optic Nerve

Portion
Intraocular
Orbital
?

(anterior) → Intraocular

(posterior) → Intraocular

Anatomically speaking, the optic nerve is considered to have four portions. What are they?

Q/A

The Optic Nerve

	Portion
(anterior)	Intraocular
	Orbital
	Canalicular
(posterior)	***?***

Anatomically speaking, the optic nerve is considered to have four portions. What are they?

A

The Optic Nerve

Portion
Intraocular
Orbital
Canalicular
Intracranial

(anterior) → Intraocular

↕

(posterior) → Intracranial

Anatomically speaking, the optic nerve is considered to have four portions. What are they?

The Optic Nerve

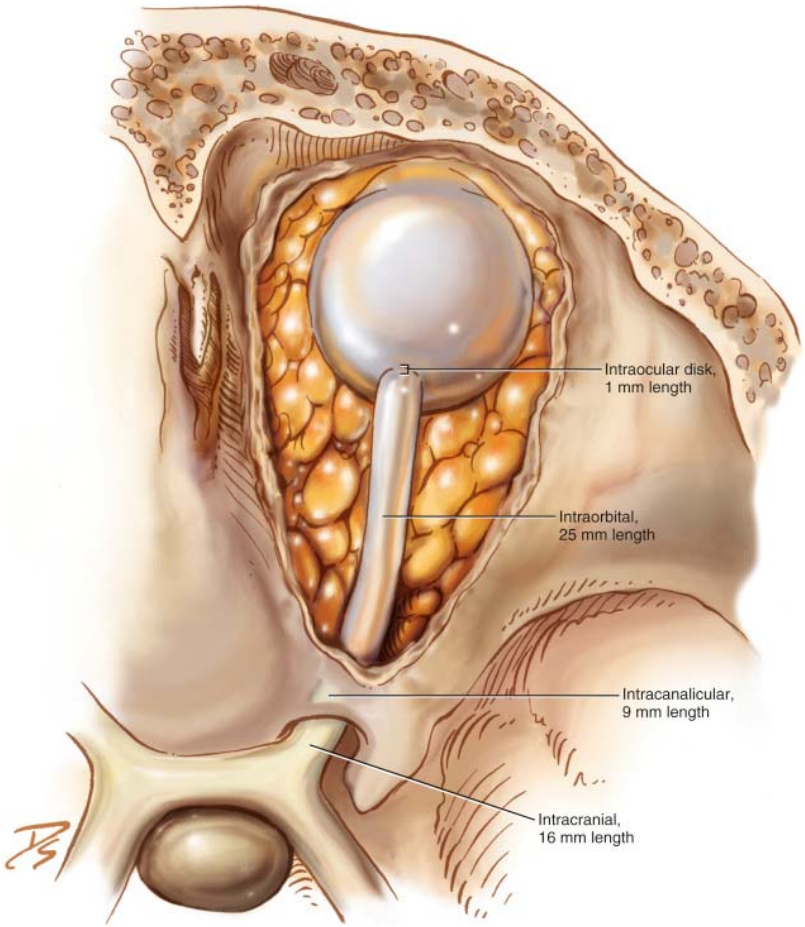

Optic nerve (don’t memorize the lengths)

Q

The Optic Nerve

Portion	***Length (mm)***
Intraocular	*?*
Orbital	
Canalicular	
Intracranial	

Anatomically speaking, the optic nerve is considered to have four portions. What are they?
How long is each?

Q/A

The Optic Nerve

Portion	***Length (mm)***
Intraocular	1
Orbital	*?*
Canalicular	
Intracranial	

Anatomically speaking, the optic nerve is considered to have four portions. What are they?
How long is each?

Q/A

The Optic Nerve

Portion	***Length (mm)***
Intraocular	1
Orbital	30 *Fundamentals*: 25 *Path*: 25-30 *Neuro*: 30
Canalicular	*?*
Intracranial	

Anatomically speaking, the optic nerve is considered to have four portions. What are they?
How long is each?

Q/A

The Optic Nerve

Portion	***Length (mm)***
Intraocular	1
Orbital	30
Canalicular	10 *Fundamentals*: 4-10 *Path*: 4-10 *Neuro*: 8-10
Intracranial	*?*

Anatomically speaking, the optic nerve is considered to have four portions. What are they?
How long is each?

A

The Optic Nerve

Portion	***Length (mm)***
Intraocular	1
Orbital	30
Canalicular	10
Intracranial	10 *Fundamentals*: 10 *Path*: 10 *Neuro*: 8-12

Anatomically speaking, the optic nerve is considered to have four portions. What are they?
How long is each?

Q

The Optic Nerve

Portion	***Length (mm)***
Intraocular	1
Orbital	**30**
Canalicular	10

How long is the distance between the back of the eye and the orbital apex?

Anatomically speaking, the optic nerve is considered to have four portions. What are they?

A

The Optic Nerve

Portion	***Length (mm)***
Intraocular	1
Orbital	**30**
Canalicular	10

How long is the distance between the back of the eye and the orbital apex?
About 18 mm

Anatomically speaking, the optic nerve is considered to have four portions. What are they?

Q

The Optic Nerve

Portion	***Length (mm)***
Intraocular	1
Orbital	30
Canalicular	10
Intracranial	10

Anatomically speaking, the optic nerve is considered to have four portions. What are they? How long is each?

The intraocular portion is also considered to have four portions. What are they?

	Portion
(innermost)	***?***
(outermost)	

Q/A

The Optic Nerve

Portion	***Length (mm)***
Intraocular	1
Orbital	30
Canalicular	10
Intracranial	10

Anatomically speaking, the optic nerve is considered to have four portions. What are they? How long is each?

The intraocular portion is also considered to have four portions. What are they?

	Portion
(innermost)	NFL portion
	?
(outermost)	

Q/A

The Optic Nerve

Portion	***Length (mm)***
Intraocular	1
Orbital	30
Canalicular	10
Intracranial	10

Anatomically speaking, the optic nerve is considered to have four portions. What are they? How long is each?

The intraocular portion is also considered to have four portions. What are they?

	Portion	
(innermost)	NFL portion	
	Pre-laminar	
	?	
(outermost)		

Q/A

The Optic Nerve

Portion	***Length (mm)***
Intraocular	1
Orbital	30
Canalicular	10
Intracranial	10

Anatomically speaking, the optic nerve is considered to have four portions. What are they? How long is each?

The intraocular portion is also considered to have four portions. What are they?

	Portion
(innermost) →	NFL portion
↕	Pre-laminar
	Laminar
(outermost) →	***?***

A

The Optic Nerve

Portion	***Length (mm)***
Intraocular	1
Orbital	30
Canalicular	10
Intracranial	10

Anatomically speaking, the optic nerve is considered to have four portions. What are they? How long is each?

The intraocular portion is also considered to have four portions. What are they?

	Portion
(innermost) →	NFL portion
↕	Pre-laminar
	Laminar
(outermost) →	Retrolaminar

The Optic Nerve

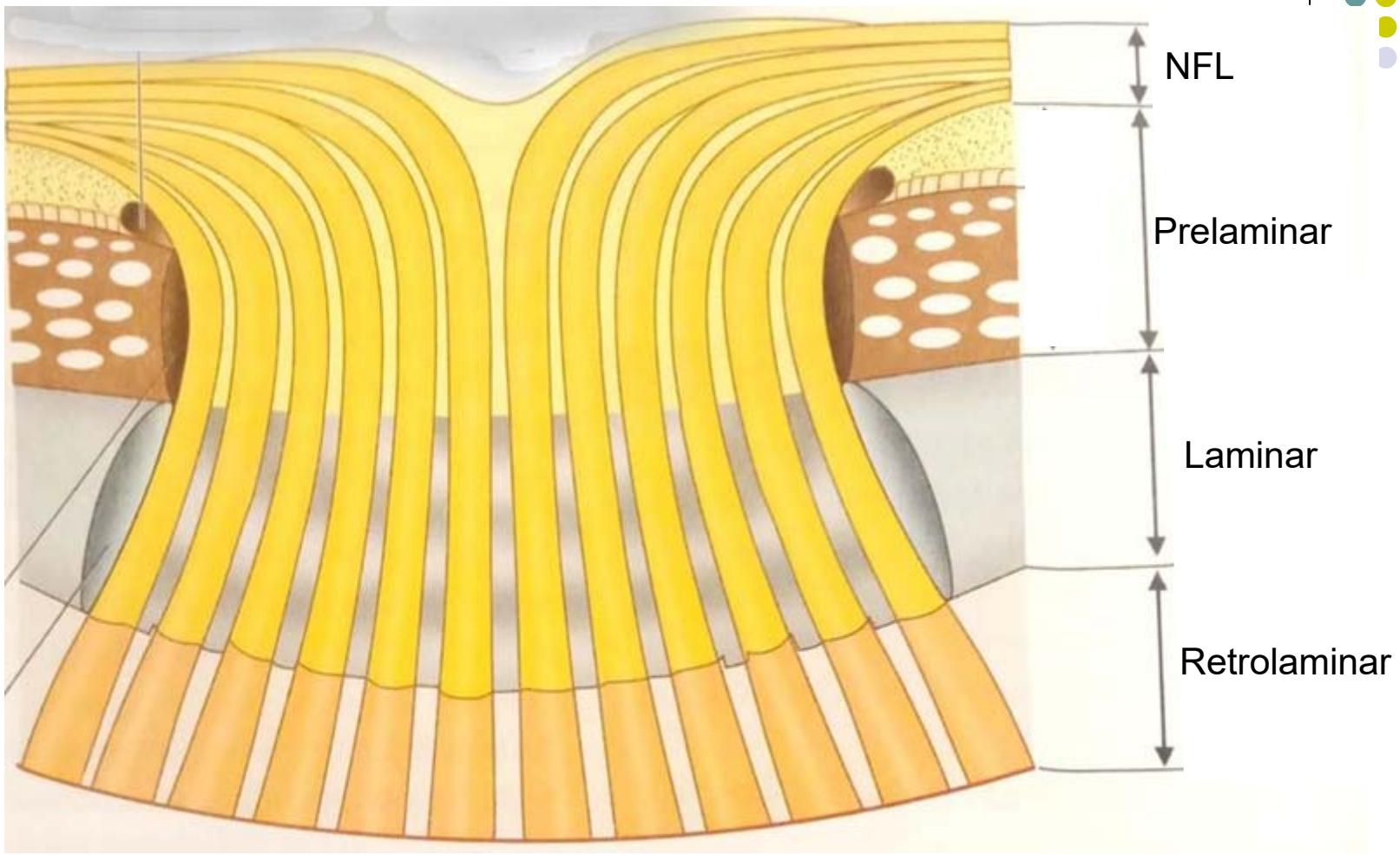

Optic nerve: Intraocular portion

Q

The Optic Nerve

Portion	***Length (mm)***
Intraocular	1
Orbital	30
Canalicular	10
Intracranial	10

Anaton
How lo
The int
What is

To what lamina is this referring?

y?

(innerm

(outermost)

Pre-laminar
Laminar
Retrolaminar

A

The Optic Nerve

Portion	***Length (mm)***
Intraocular	1
Orbital	30
Canalicular	10
Intracranial	10

Anaton
How lo
The int
What is

To what lamina is this referring?
The **lamina cribrosa**

y?

(innerm

(outermost)

Pre-laminar
Laminar
Retrolaminar

Q

The Optic Nerve

Portion	***Length (mm)***
Intraocular	1
Orbital	30
Canalicular	10
Intracranial	10

Anaton
How lo
The int
What is

To what lamina is this referring?

The **lamina cribrosa**

Lamina cribrosa? I thought that was the super-thin part of the medial orbital wall.

y?

(innerm

(outermost)

Pre-laminar
Laminar
Retrolaminar

A

The Optic Nerve

Portion	***Length (mm)***
Intraocular	1
Orbital	30
Canalicular	10
Intracranial	10

Anaton
How lo
The int
What is

To what lamina is this referring?

The **lamina cribrosa**

Lamina cribrosa? I thought that was the super-thin part of the medial orbital wall.
You're thinking of the *lamina papyracea*

(innerm

(outermost)

Pre-laminar	
Laminar	
Retrolaminar	

Q

The Optic Nerve

Portion	***Length (mm)***
Intraocular	1
Orbital	30
Canalicular	10
Intracranial	10

Anaton
How lo
The int
What is

To what lamina is this referring?
The **lamina cribrosa**

What is the lamina cribrosa?

y?

(innerm

(outermost)

Pre-laminar
Laminar
Retrolaminar

A

The Optic Nerve

Portion	***Length (mm)***
Intraocular	1
Orbital	30
Canalicular	10
Intracranial	10

Anaton
How lo
The int
What is

To what lamina is this referring?
The **lamina cribrosa**

What is the lamina cribrosa?
The fenestrated hole in the posterior sclera through which the optic nerve exits

(innerm

(outermost)

Pre-laminar
Laminar
Retrolaminar

Q

The Optic Nerve

Portion	***Length (mm)***
Intraocular	1
Orbital	30
Canalicular	10
Intracranial	10

Anaton
How lo
The int
What is

To what lamina is this referring?
The **lamina cribrosa**

What is the lamina cribrosa?
The **fenestrated** hole in the posterior sclera through which the optic nerve exits

How many fenestrations are there?

(innerm

(outermost)

Pre-laminar
Laminar
Retrolaminar

A

The Optic Nerve

Portion	***Length (mm)***
Intraocular	1
Orbital	30
Canalicular	10
Intracranial	10

Anaton
How lo
The int
What is

To what lamina is this referring?
The **lamina cribrosa**

What is the lamina cribrosa?
The **fenestrated** hole in the posterior sclera through which the optic nerve exits

How many fenestrations are there?
200-300

(innerm

(outermost)

Pre-laminar
Laminar
Retrolaminar

Q

The Optic Nerve

Portion	***Length (mm)***
Intraocular	1
Orbital	30
Canalicular	10
Intracranial	10

Anaton
How lo
The int
What is

To what lamina is this referring?
The **lamina cribrosa**

What is the lamina cribrosa?
The **fenestrated** hole in the posterior sclera through which the optic nerve exits

How many fen
200-300

Two fenestrations are ***much*** *larger than the others. What passes through the larger ones?*

(inner

Pre-laminar

Laminar

Retrolaminar

(outermost)

A

The Optic Nerve

Portion	***Length (mm)***
Intraocular	1
Orbital	30
Canalicular	10
Intracranial	10

Anaton
How lo
The int
What is

To what lamina is this referring?
The **lamina cribrosa**

What is the lamina cribrosa?
The **fenestrated** hole in the posterior sclera through which the optic nerve exits

How many fen
200-300

Two fenestrations are **much** *larger than the others. What passes through the larger ones?*
The central retinal artery and vein

(inner

Pre-laminar
Laminar
Retrolaminar

(outermost)

The Optic Nerve

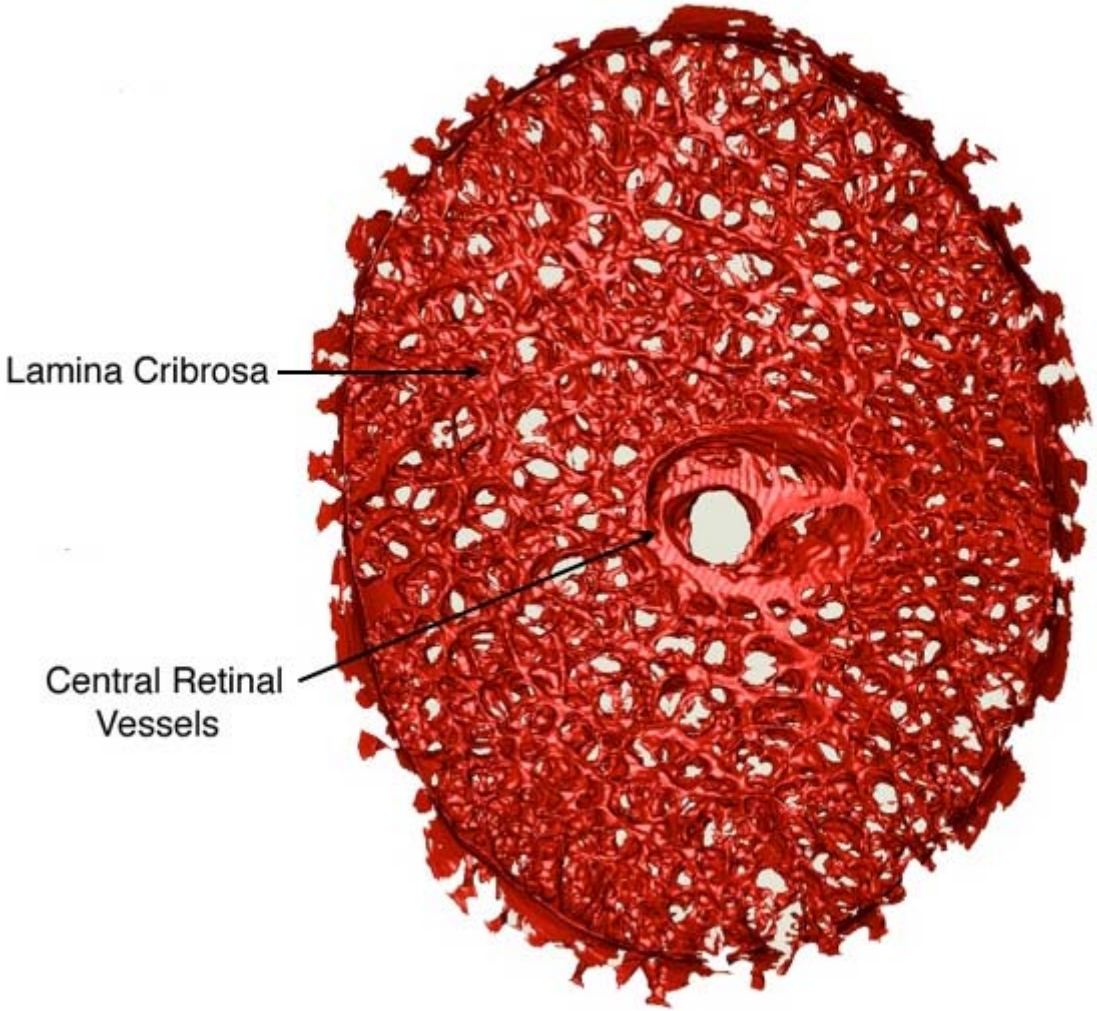

Lamina cribrosa

Q

The Optic Nerve

Portion	***Length (mm)***
Intraocular	1
Orbital	30
Canalicular	10
Intracranial	10

Anaton
How lo
The int
What is

To what lamina is this referring?
The **lamina cribrosa**

What is the lamina cribrosa?
The fenestrated hole in the posterior sclera through which the optic nerve exits

Does the lamina extend the entire thickness of the eye wall?

(innerm

(outermost)

Pre-laminar
Laminar
Retrolaminar

A

The Optic Nerve

Portion	***Length (mm)***
Intraocular	1
Orbital	30
Canalicular	10
Intracranial	10

Anaton
How lo
The int
What is

To what lamina is this referring?
The **lamina cribrosa**

What is the lamina cribrosa?
The fenestrated hole in the posterior sclera through which the optic nerve exits

Does the lamina extend the entire thickness of the eye wall?
No, it is about 1/3 the thickness of the adjacent sclera

(innerm

(outermost)

Pre-laminar
Laminar
Retrolaminar

Q

The Optic Nerve

Portion	***Length (mm)***
Intraocular	1
Orbital	30
Canalicular	10
Intracranial	10

Anaton
How lo
The int
What is

To what lamina is this referring?
The **lamina cribrosa**

What is the lamina cribrosa?
The fenestra ... optic nerve exits

With which portion of the eye wall is the lamina aligned; ie, is it the inner third, the middle third or the outer third?

Does the la
No, it is about **1/3 the thickness of the adjacent sclera**

(innerm

(outermost)

Pre-laminar
Laminar
Retrolaminar

A

The Optic Nerve

Portion	***Length (mm)***
Intraocular	1
Orbital	30
Canalicular	10
Intracranial	10

Anaton
How lo
The int
What is

To what lamina is this referring?
The **lamina cribrosa**

What is the lamina cribrosa?
The fenestra ... optic nerve exits

With which portion of the eye wall is the lamina aligned; ie, is it the inner third, the middle third or the outer third?
The inner third

Does the la
No, it is about **1/3 the thickness of the adjacent sclera**

(innerm

(outermost)

Pre-laminar
Laminar
Retrolaminar

Q

The Optic Nerve

Portion	***Length (mm)***
Intraocular	1
Orbital	30
Canalicular	10
Intracranial	10

Anatomically speaking, the optic nerve is considered to have four portions. What are they? How long is each?
The intraocular portion is also considered to have four portions. What are they?
What is the blood supply for each?

	Portion	***Blood supply***
(innermost) →	*NFL portion*	***?***
↕	Pre-laminar	
	Laminar	
(outermost) →	Retrolaminar	

Q/A

The Optic Nerve

Portion	***Length (mm)***
Intraocular	1
Orbital	30
Canalicular	10
Intracranial	10

Anatomically speaking, the optic nerve is considered to have four portions. What are they? How long is each?
The intraocular portion is also considered to have four portions. What are they?
What is the blood supply for each?

	Portion	***Blood supply***
(innermost) →	NFL portion	Central retinal artery (CRA)
↕	*Pre-laminar*	***?***
	Laminar	
(outermost) →	Retrolaminar	

Q/A

The Optic Nerve

Portion	***Length (mm)***
Intraocular	1
Orbital	30
Canalicular	10
Intracranial	10

Anatomically speaking, the optic nerve is considered to have four portions. What are they? How long is each?
The intraocular portion is also considered to have four portions. What are they?
What is the blood supply for each?

	Portion	***Blood supply***
(innermost) →	NFL portion	Central retinal artery (CRA)
↕	Pre-laminar	Short posterior ciliary arteries
	Laminar	***?***
(outermost) →	Retrolaminar	

Q/A

The Optic Nerve

Portion	Length (mm)
Intraocular	1
Orbital	30
Canalicular	10
Intracranial	10

Anatomically speaking, the optic nerve is considered to have four portions. What are they? How long is each?
The intraocular portion is also considered to have four portions. What are they?
What is the blood supply for each?

	Portion	Blood supply
(innermost) →	NFL portion	Central retinal artery (CRA)
↕	Pre-laminar	Short posterior ciliary arteries
	Laminar	Arterial circle of Zinn & Haller
(outermost) →	*Retrolaminar*	***?***

A

The Optic Nerve

Portion	***Length (mm)***
Intraocular	1
Orbital	30
Canalicular	10
Intracranial	10

Anatomically speaking, the optic nerve is considered to have four portions. What are they? How long is each?
The intraocular portion is also considered to have four portions. What are they?
What is the blood supply for each?

	Portion	***Blood supply***
(innermost) →	NFL portion	Central retinal artery (CRA)
↕	Pre-laminar	Short posterior ciliary arteries
	Laminar	Arterial circle of Zinn & Haller
(outermost) →	Retrolaminar	Centrifugal CRA branches, centripetal pial branches

The Optic Nerve

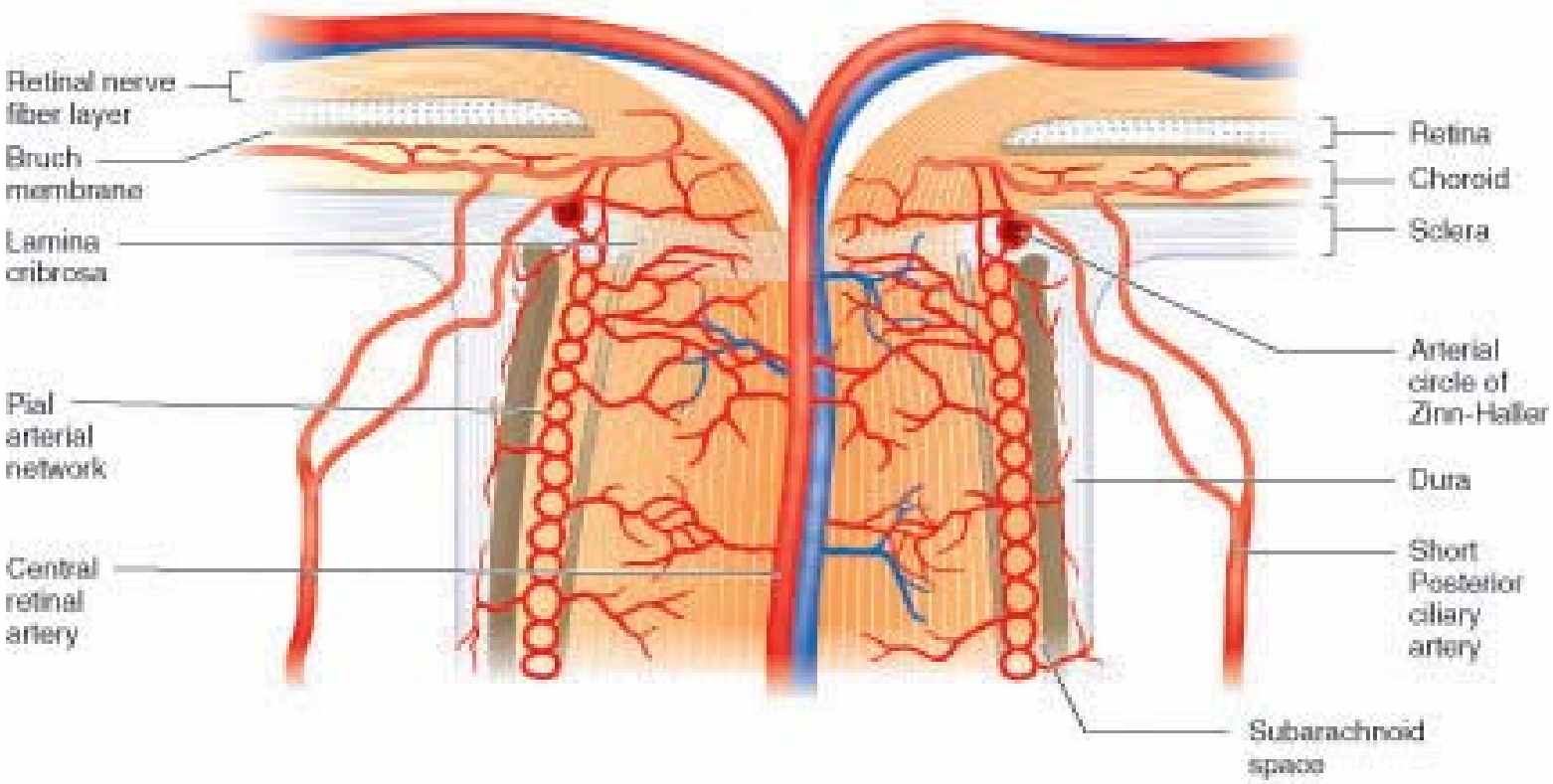

Intraocular optic nerve: Blood supply

Q

The Optic Nerve

Portion	***Length (mm)***
Intraocular	1
Orbital	30
Canalicular	10
Intracranial	10

Anatomically speaking, the optic nerve is considered to have four portions. What are they? How long is each?

The intr

What is

To which portion(s) of the intraocular nerve does the term optic disc *apply?*

Portion	***Blood supply***
NFL portion?	Central retinal artery (CRA)
Pre-laminar?	Short posterior ciliary arteries
Laminar?	Arterial circle of Zinn & Haller
Retrolaminar?	Centrifugal CRA branches, centripetal pial branches

(innermost) → NFL portion?

(outermost) → Retrolaminar?

A

The Optic Nerve

Portion	***Length (mm)***
Intraocular	1
Orbital	30
Canalicular	10
Intracranial	10

Anatomically speaking, the optic nerve is considered to have four portions. What are they?
How long is each?
The intr
What is

To which portion(s) of the intraocular nerve does the term optic disc *apply?*
The portion visible on ophthalmoscopy, ie, **the NFL**

	Portion	***Blood supply***
(innermost) →	**NFL portion**	Central retinal artery (CRA)
	Pre-laminar	Short posterior ciliary arteries
	Laminar	Arterial circle of Zinn & Haller
(outermost) →	Retrolaminar	Centrifugal CRA branches, centripetal pial branches

Q

The Optic Nerve

Portion	***Length (mm)***
Intraocular	1
Orbital	30
Canalicular	10
Intracranial	10

Anatomically speaking, the optic nerve is considered to have four portions. What are they?
How long is each?
The intr
What is

To which portion(s) of the intraocular nerve does the term **optic disc** *apply?*
The portion visible on ophthalmoscopy, ie, **the NFL**

What is the diameter of the optic disc?

Portion	
NFL portion	
Pre-laminar	Short posterior ciliary arteries
Laminar	Arterial circle of Zinn & Haller
Retrolaminar	Centrifugal CRA branches, centripetal pial branches

(innermost) → NFL portion

(outermost) → Retrolaminar

A

The Optic Nerve

Portion	*Length (mm)*
Intraocular	1
Orbital	30
Canalicular	10
Intracranial	10

Anatomically speaking, the optic nerve is considered to have four portions. What are they? How long is each?

The intr

What is

To which portion(s) of the intraocular nerve does the term **optic disc** *apply?*

The portion visible on ophthalmoscopy, ie, **the NFL**

What is the diameter of the optic disc?

Well, bearing in mind the considerable anatomic variability that characterizes the optic nerve, a reasonable estimate would be 1.6 mm, with the vertical diameter usually a little larger than the horizontal

Fundamentals: 1.76 x 1 92
Glaucoma: 1.5-1.7
Neuro: 1.5

	Portion	
(innermost)	**NFL portion**	
	Pre-laminar	Short posterior ciliary
	Laminar	Arterial circle of Zinn & Haller
(outermost)	Retrolaminar	Centrifugal CRA branches, centripetal pial branches

Q

The Optic Nerve

Portion	***Length (mm)***
Intraocular	1
Orbital	30
Canalicular	10
Intracranial	10

Anatomically speaking, the optic nerve is considered to have four portions. What are they? How long is each?

The intr

What is

To which portion(s) of the intraocular nerve does the term **optic disc** *apply?*
The portion visible on ophthalmoscopy, ie, **the NFL**

What is the diameter of the optic disc?
Well, bearing in mind the considerable anatomic variability that characterizes the optic nerve, a reasonable estimate would be 1.6 mm, with the vertical diameter usually a little

What is the diameter of the nerve after it passes through the lamina cribrosa?

Portion	
(innermost) → NFL portion	
	y arteries
	& Haller
(outermost) → **Retrolaminar**	Centrifugal CRA branches, centripetal pial branches

A

The Optic Nerve

Portion	*Length (mm)*
Intraocular	1
Orbital	30
Canalicular	10
Intracranial	10

Anatomically speaking, the optic nerve is considered to have four portions. What are they?
How long is each?
The intr
What is

To which portion(s) of the intraocular nerve does the term **optic disc** *apply?*
The portion visible on ophthalmoscopy, ie, **the NFL**

What is the diameter of the optic disc?
Well, bearing in mind the considerable anatomic variability that characterizes the optic nerve, a reasonable estimate would be 1.6 mm, with the vertical diameter usually a little

Portion	
(innermost) → NFL portion	
	y arteries
	& Haller
(outermost) → **Retrolaminar**	Centrifugal CRA branches, centripetal pial branches

What is the diameter of the nerve after it passes through the lamina cribrosa?
It doubles to 3-4 mm or so

Q

The Optic Nerve

Portion	***Length (mm)***
Intraocular	1
Orbital	30
Canalicular	10
Intracranial	10

Anatomically speaking, the optic nerve is considered to have four portions. What are they? How long is each?

The intr

What is

To which portion(s) of the intraocular nerve does the term **optic disc** *apply?*
The portion visible on ophthalmoscopy, ie, **the NFL**

What is the diameter of the optic disc?
Well, bearing in mind the considerable anatomic variability that characterizes the optic nerve, a reasonable estimate would be 1.6 mm, with the vertical diameter usually a little

Portion	
(innermost) → NFL portion	
	y arteries
	& Haller
(outermost) → **Retrolaminar**	Centrifugal CRA branches, centripetal pial branches

What is the diameter of the nerve after it passes through the lamina cribrosa?
It doubles to 3-4 mm or so

Why does it double in size?

Q/A

The Optic Nerve

Portion	*Length (mm)*
Intraocular	1
Orbital	30
Canalicular	10
Intracranial	10

Anatomically speaking, the optic nerve is considered to have four portions. What are they? How long is each?

The intr

What is

To which portion(s) of the intraocular nerve does the term **optic disc** *apply?*
The portion visible on ophthalmoscopy, ie, **the NFL**

What is the diameter of the optic disc?
Well, bearing in mind the considerable anatomic variability that characterizes the optic nerve, a reasonable estimate would be 1.6 mm, with the vertical diameter usually a little

Portion	
(innermost) → NFL portion	
	y arteries
	& Haller
(outermost) → **Retrolaminar**	Centrifugal CRA branches, centripetal pial branches

What is the diameter of the nerve after it passes through the lamina cribrosa?
It doubles to 3-4 mm or so

Why does it double in size?
Because it as at this point the fibers become

A

The Optic Nerve

Portion	***Length (mm)***
Intraocular	1
Orbital	30
Canalicular	10
Intracranial	10

Anatomically speaking, the optic nerve is considered to have four portions. What are they?
How long is each?
The intr
What is

To which portion(s) of the intraocular nerve does the term **optic disc** *apply?*
The portion visible on ophthalmoscopy, ie, **the NFL**

What is the diameter of the optic disc?
Well, bearing in mind the considerable anatomic variability that characterizes the optic nerve, a reasonable estimate would be 1.6 mm, with the vertical diameter usually a little

Portion	
(innermost) → NFL portion	
	y arteries
	& Haller
(outermost) → **Retrolaminar**	Centrifugal CRA branches, centripetal pial branches

What is the diameter of the nerve after it passes through the lamina cribrosa?
It doubles to 3-4 mm or so

Why does it double in size?
Because it as at this point the fibers become myelinated

Q

The Optic Nerve

Portion	***Length (mm)***
Intraocular	1
Orbital	30
Canalicular	10
Intracranial	10

Can myelin appear prior to this point?

ortions. What are they?

optic disc *apply?*

optic disc?
nsiderable anatomic variability
nerve, a reasonable estimate
ertical diameter usually a little

ry arteries

Zinn & Haller

Why does it double in size?
Because it as **at this point the fibers become myelinated**

(outermost)

Retrolaminar	Centrifugal CRA branches, centripetal pial branches

A

The Optic Nerve

Portion	*Length (mm)*
Intraocular	1
Orbital	30
Canalicular	10
Intracranial	10

Can myelin appear prior to this point?
Yes

ortions. What are they?

optic disc *apply?*

optic disc?
nsiderable anatomic variability
nerve, a reasonable estimate
ertical diameter usually a little

ry arteries

Zinn & Haller

Why does it double in size?
Because it as **at this point the fibers become myelinated**

(outermost)

Retrolaminar	Centrifugal CRA branches, centripetal pial branches

Q

The Optic Nerve

Portion	*Length (mm)*
Intraocular	1
Orbital	30
Canalicular	10
Intracranial	10

Can myelin appear prior to this point?
Yes

When myelinated retinal nerve fibers are present, what are they called?

ortions. What are they?

optic disc *apply?*

optic disc?
nsiderable anatomic variability
nerve, a reasonable estimate
ertical diameter usually a little

ry arteries

Zinn & Haller

Why does it double in size?
Because it **at this point the fibers become myelinated**

(outermost)

Retrolaminar	Centrifugal CRA branches, centripetal pial branches

A

The Optic Nerve

Portion	*Length (mm)*
Intraocular	1
Orbital	30
Canalicular	10
Intracranial	10
Retrolaminar	Centrifugal CRA branches, centripetal pial branches

Can myelin appear prior to this point?
Yes

When myelinated retinal nerve fibers are present, what are they called?
They are called 'myelinated retinal nerve fibers'

Why does it double in size?
Because it **at this point the fibers become myelinated**

(outermost)

ortions. *What are they?*

optic disc *apply?*

optic disc?
nsiderable anatomic variability
nerve, a reasonable estimate
ertical diameter usually a little

ry arteries

Zinn & Haller

Q

The Optic Nerve

Portion	*Length (mm)*
Intraocular	1
Orbital	30
Canalicular	10
Intracranial	10
Retrolaminar	Centrifugal CRA branches, centripetal pial branches

Can myelin appear prior to this point?
Yes

When myelinated retinal nerve fibers are present, what are they called?
They are called ~~'myelinated~~ ? retinal nerve fibers'

What word is sometimes used instead of myelinated*?*

Why does it double in size?
Because it as **at this point the fibers become myelinated**

(outermost)

ortions. What are they?

optic disc *apply?*

optic disc?
nsiderable anatomic variability
nerve, a reasonable estimate
ertical diameter usually a little

ry arteries

Zinn & Haller

A

The Optic Nerve

Portion	*Length (mm)*
Intraocular	1
Orbital	30
Canalicular	10
Intracranial	10
Retrolaminar	Centrifugal CRA branches, centripetal pial branches

Can myelin appear prior to this point?
Yes

When myelinated retinal nerve fibers are present, what are they called?
They are called ~~'myelinated~~ medullated retinal nerve fibers'

What word is sometimes used instead of myelinated*?*
Medullated retinal nerve fibers

Why does it double in size?
Because it **at this point the fibers become myelinated**

(outermost)

ortions. What are they?

optic disc *apply?*

optic disc?
nsiderable anatomic variability
nerve, a reasonable estimate
ertical diameter usually a little

ry arteries

Zinn & Haller

Q

The Optic Nerve

Portion	Length (mm)
Intraocular	1
Orbital	30
Canalicular	10
Intracranial	10

Can myelin appear prior to this point?
Yes

When myelinated retinal nerve fibers are present, what are they called?
They are called 'myelinated retinal nerve fibers'

What is the ophthalmoscopic appearance of myelinated retinal nerve fibers?

ortions. What are they?

optic disc *apply?*

optic disc?
nsiderable anatomic variability
nerve, a reasonable estimate
ertical diameter usually a little

ry arteries

Zinn & Haller

Why does it double in size?
Because it as **at this point the fibers become myelinated**

(outermost)

Retrolaminar	Centrifugal CRA branches, centripetal pial branches

A

The Optic Nerve

Portion	Length (mm)
Intraocular	1
Orbital	30
Canalicular	10
Intracranial	10

Can myelin appear prior to this point?
Yes

When myelinated retinal nerve fibers are present, what are they called?
They are called 'myelinated retinal nerve fibers'

What is the ophthalmoscopic appearance of myelinated retinal nerve fibers?
They appear as white patches usually near the optic disc

ortions. What are they?

optic disc *apply?*

optic disc?
nsiderable anatomic variability
nerve, a reasonable estimate
ertical diameter usually a little

Why does it double in size?
Because it as **at this point the fibers become myelinated**

(outermost)

	ry arteries
	Zinn & Haller
Retrolaminar	Centrifugal CRA branches, centripetal pial branches

The Optic Nerve

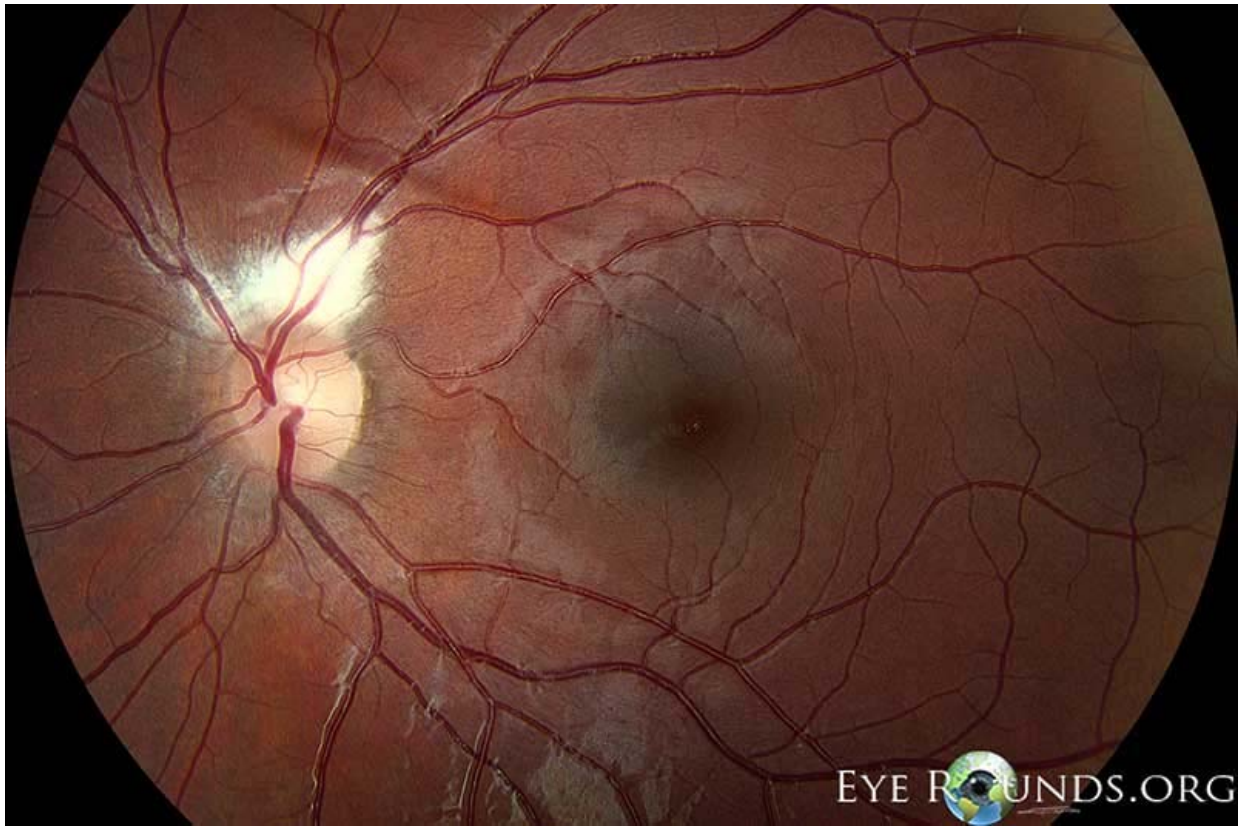

Myelinated retinal nerve fiber layer

Q

The Optic Nerve

Portion	Length (mm)
Intraocular	1
Orbital	30
Canalicular	10
Intracranial	10

Can myelin appear prior to this point?
Yes

When myelinated retinal nerve fibers are present, what are they called?
They are called 'myelinated retinal nerve fibers'

What is the ophthalmoscopic appearance of myelinated retinal nerve fibers?
They appear as white patches usually near the optic disc

How large are the patches?

ortions. What are they?

optic disc *apply?*

optic disc?
nsiderable anatomic variability
nerve, a reasonable estimate
ertical diameter usually a little

ry arteries

Zinn & Haller

Why does it double in size?
Because it as **at this point the fibers become myelinated**

(outermost)

Retrolaminar	Centrifugal CRA branches, centripetal pial branches

A

The Optic Nerve

Portion	Length (mm)
Intraocular	1
Orbital	30
Canalicular	10
Intracranial	10

Can myelin appear prior to this point?
Yes

When myelinated retinal nerve fibers are present, what are they called?
They are called 'myelinated retinal nerve fibers'

What is the ophthalmoscopic appearance of myelinated retinal nerve fibers?
They appear as white patches usually near the optic disc

How large are the patches?
It varies widely--they can be very big, or very small

ortions. What are they?

optic disc *apply?*

optic disc?
nsiderable anatomic variability
nerve, a reasonable estimate
ertical diameter usually a little

ry arteries

Zinn & Haller

Why does it double in size?
Because it as **at this point the fibers become myelinated**

(outermost)

Retrolaminar	Centrifugal CRA branches, centripetal pial branches

The Optic Nerve

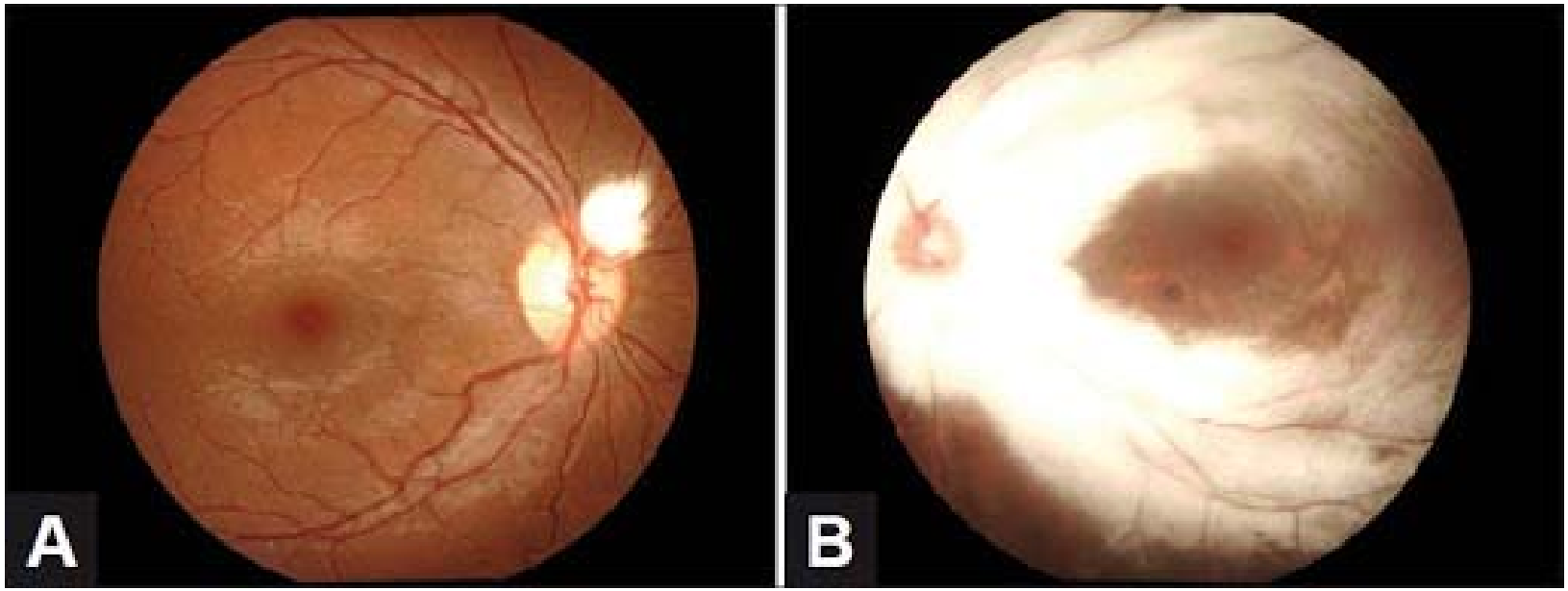

Myelinated retinal nerve fiber layer: Very big, and very small

Q

The Optic Nerve

Portion	Length (mm)
Intraocular	1
Orbital	30
Canalicular	10
Intracranial	10

Can myelin appear prior to this point?
Yes

When myelinated retinal nerve fibers are present, what are they called?
They are called 'myelinated retinal nerve fibers'

What is the ophthalmoscopic appearance of myelinated retinal nerve fibers?
They appear as white patches usually near the optic disc

How large are the patches?
It varies widely--they can be very big, or very small

Can multiple patches be present in the same eye?

Why does it double in size?
Because it **at this point the fibers become myelinated**

(outermost)

Retrolaminar	Centrifugal CRA branches, centripetal pial branches

ortions. What are they?

optic disc *apply?*

optic disc?
nsiderable anatomic variability
nerve, a reasonable estimate
ertical diameter usually a little

ry arteries

Zinn & Haller

A

The Optic Nerve

Portion	*Length (mm)*
Intraocular	1
Orbital	30
Canalicular	10
Intracranial	10

Can myelin appear prior to this point?
Yes

When myelinated retinal nerve fibers are present, what are they called?
They are called 'myelinated retinal nerve fibers'

What is the ophthalmoscopic appearance of myelinated retinal nerve fibers?
They appear as white patches usually near the optic disc

How large are the patches?
It varies widely--they can be very big, or very small

Can multiple patches be present in the same eye?
Yes

Why does it double in size?
Because it **at this point the fibers become myelinated**

(outermost)

Retrolaminar	Centrifugal CRA branches, centripetal pial branches

ortions. What are they?

optic disc *apply?*

optic disc?
nsiderable anatomic variability
nerve, a reasonable estimate
ertical diameter usually a little

ry arteries

Zinn & Haller

The Optic Nerve

Myelinated retinal nerve fiber layer: Multiple

Q

The Optic Nerve

Portion	Length (mm)
Intraocular	1

In addition to myelin, the retrolaminar optic nerve acquires something else of significance. What?

ney?

ariability
stimate
y a little

Can multiple patches be present in the same eye?
Yes

Why does it double in size?
Because it as **at this point the fibers become myelinated**

		ry arteries
		Zinn & Haller
(outermost)	**Retrolaminar**	Centrifugal CRA branches, centripetal pial branches

A

The Optic Nerve

Portion	Length (mm)
Intraocular	1
	ry arteries
	Zinn & Haller
Retrolaminar	Centrifugal CRA branches, centripetal pial branches

In addition to myelin, the retrolaminar optic nerve acquires something else of significance. What?
Its meningeal sheaths

ney?

ariability
stimate
y a little

Can multiple patches be present in the same eye?
Yes

Why does it double in size?
Because it as **at this point the fibers become myelinated**

(outermost)

Q

The Optic Nerve

Portion	Length (mm)
Intraocular	1
	ry arteries
	Zinn & Haller
Retrolaminar	Centrifugal CRA branches, centripetal pial branches

In addition to myelin, the retrolaminar optic nerve acquires something else of significance. What?
Its meningeal sheaths

Does it pick up all three meningeal layers?

ney?

ariability
stimate
y a little

Can multiple patches be present in the same eye?
Yes

Why does it double in size?
Because it as **at this point the fibers become myelinated**

(outermost)

A

The Optic Nerve

Portion	Length (mm)
Intraocular	1
	ry arteries
	Zinn & Haller
Retrolaminar	Centrifugal CRA branches, centripetal pial branches

In addition to myelin, the retrolaminar optic nerve acquires something else of significance. What?
Its meningeal sheaths

Does it pick up all three meningeal layers?
Yes

ney?

ariability
stimate
y a little

Can multiple patches be present in the same eye?
Yes

Why does it double in size?
Because it as **at this point the fibers become myelinated**

(outermost)

The Optic Nerve

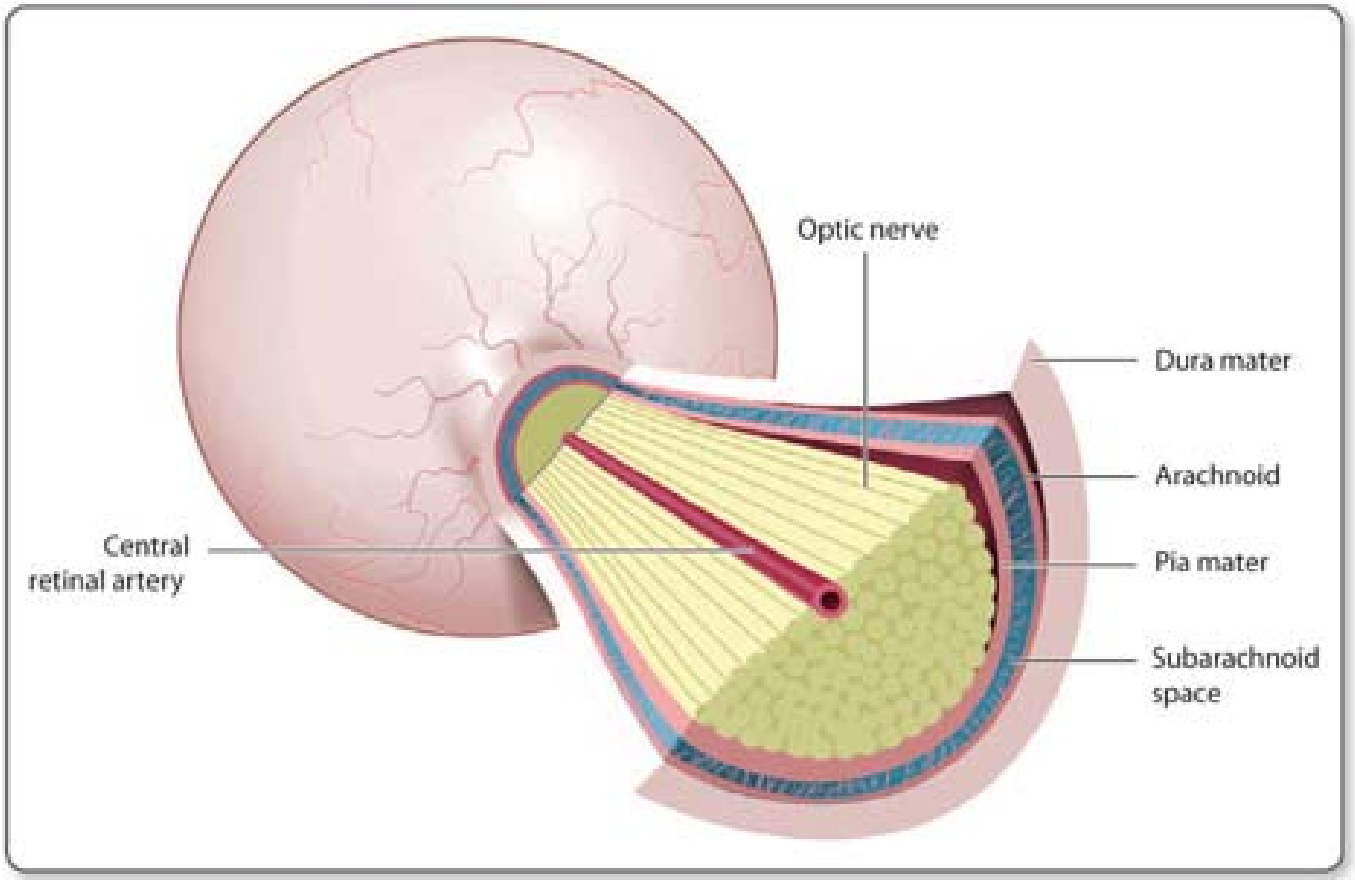

Retrolaminar optic nerve: Meninges

Q

The Optic Nerve

Portion	Length (mm)
Intraocular	1

In addition to myelin, the retrolaminar optic nerve acquires something else of significance. What?
Its meningeal sheaths

Does it pick up all three meningeal layers?
Yes

Does it have a subarachnoid space, and if so, is this space filled with CSF?

ney?

ariability
stimate
y a little

Can multiple patches be present in the same eye?
Yes

Why does it double in size?
Because it as **at this point the fibers become myelinated**

		ry arteries
		Zinn & Haller
(outermost)	**Retrolaminar**	Centrifugal CRA branches, centripetal pial branches

A

The Optic Nerve

Portion	Length (mm)
Intraocular	1
	ry arteries
	Zinn & Haller
Retrolaminar	Centrifugal CRA branches, centripetal pial branches

In addition to myelin, the retrolaminar optic nerve acquires something else of significance. What?
Its meningeal sheaths

Does it pick up all three meningeal layers?
Yes

Does it have a subarachnoid space, and if so, is this space filled with CSF?
Yes and yes

ney?

ariability
stimate
y a little

Can multiple patches be present in the same eye?
Yes

Why does it double in size?
Because it as **at this point the fibers become myelinated**

(outermost)

Q

The Optic Nerve

Portion	Length (mm)
Intraocular	1

In addition to myelin, the retrolaminar optic nerve acquires something else of significance. What?
Its meningeal sheaths

Does it pick up all three meningeal layers?
Yes

Does it have a subarachnoid space, and if so, is this space filled with CSF?
Yes and yes

Is the CSF-filled subarachnoid space of the retrolaminar optic nerve continuous with the CSF-filled subarachnoid space of the rest of the CNS?

ney?

ariability
stimate
y a little

Can multiple patches be present in the same eye?
Yes

Why does it double in size?
Because it was **at this point the fibers become myelinated**

(outermost)

	ry arteries
	Zinn & Haller
Retrolaminar	Centrifugal CRA branches, centripetal pial branches

A

The Optic Nerve

Portion	Length (mm)
Intraocular	1

In addition to myelin, the retrolaminar optic nerve acquires something else of significance. What?
Its meningeal sheaths

Does it pick up all three meningeal layers?
Yes

Does it have a subarachnoid space, and if so, is this space filled with CSF?
Yes and yes

Is the CSF-filled subarachnoid space of the retrolaminar optic nerve continuous with the CSF-filled subarachnoid space of the rest of the CNS?
Yes

ney?

ariability
stimate
y a little

Can multiple patches be present in the same eye?
Yes

ry arteries

Why does it double in size?
Because it as **at this point the fibers become myelinated**

Zinn & Haller

(outermost) →

Retrolaminar	Centrifugal CRA branches, centripetal pial branches

Q

The Optic Nerve

Portion	Length (mm)
Intraocular	1
	ry arteries
	Zinn & Haller
Retrolaminar	Centrifugal CRA branches, centripetal pial branches

In addition to myelin, the retrolaminar optic nerve acquires something else of significance. What?
Its meningeal sheaths

Does it pick up all three meningeal layers?
Yes

Does it have a subarachnoid space, and if so, is this space filled with CSF?
Yes and yes

Is the CSF-filled subarachnoid space of the retrolaminar optic nerve continuous with the CSF-filled subarachnoid space of the rest of the CNS?
Yes

How does the pressure in the CSF-filled subarachnoid space of the retrolaminar optic nerve compare to that of the CSF-filled subarachnoid space of the rest of the CNS (ie, compared to intracranial pressure, ICP)?

Can multiple patches be present in the same eye?
Yes

Why does it double in size?
Because it as **at this point the fibers become myelinated**

(outermost)

hey?

ariability
stimate
y a little

A

The Optic Nerve

Portion	Length (mm)
Intraocular	1
	ry arteries
	Zinn & Haller
Retrolaminar	Centrifugal CRA branches, centripetal pial branches

In addition to myelin, the retrolaminar optic nerve acquires something else of significance. What?
Its meningeal sheaths

Does it pick up all three meningeal layers?
Yes

Does it have a subarachnoid space, and if so, is this space filled with CSF?
Yes and yes

Is the CSF-filled subarachnoid space of the retrolaminar optic nerve continuous with the CSF-filled subarachnoid space of the rest of the CNS?
Yes

How does the pressure in the CSF-filled subarachnoid space of the retrolaminar optic nerve compare to that of the CSF-filled subarachnoid space of the rest of the CNS (ie, compared to intracranial pressure, ICP)?
They are exactly the same

Can multiple patches be present in the same eye?
Yes

Why does it double in size?
Because it **at this point the fibers become myelinated**

(outermost)

hey?

ariability
stimate
y a little

Q

The Optic Nerve

Portion	Length (mm)
Intraocular	1
	ry arteries
	Zinn & Haller
Retrolaminar	Centrifugal CRA branches, centripetal pial branches

In addition to myelin, the retrolaminar optic nerve acquires something else of significance. What?
Its meningeal sheaths

Does it pick up all three meningeal layers?
Yes

Does it have a subarachnoid space, and if so, is this space filled with CSF?

How far forward in the optic nerve does the CSF-filled space extend, ie, what structure provides the anterior limit to the space?

subarachnoid space of the rest of the CNS?
Yes

How does the pressure in the CSF-filled subarachnoid space of the retrolaminar optic nerve compare to that of the CSF-filled subarachnoid space of the rest of the CNS (ie, compared to intracranial pressure, ICP)?
They are exactly the same

Can multiple patches be present in the same eye?
Yes

Why does it double in size?
Because it as **at this point the fibers become myelinated**

(outermost)

ariability
stimate
y a little

A

The Optic Nerve

Portion	Length (mm)
Intraocular	1
	ry arteries
	Zinn & Haller
Retrolaminar	Centrifugal CRA branches, centripetal pial branches

In addition to myelin, the retrolaminar optic nerve acquires something else of significance. What?
Its meningeal sheaths

Does it pick up all three meningeal layers?
Yes

Does it have a subarachnoid space, and if so, is this space filled with CSF?

How far forward in the optic nerve does the CSF-filled space extend, ie, what structure provides the anterior limit to the space?
The lamina cribrosa (which also is the structure delimiting the anterior extent of the retrolaminar space)

subarachnoid space of the rest of the CNS?
Yes

How does the pressure in the CSF-filled subarachnoid space of the retrolaminar optic nerve compare to that of the CSF-filled subarachnoid space of the rest of the CNS (ie, compared to intracranial pressure, ICP)?
They are exactly the same

Can multiple patches be present in the same eye?
Yes

Why does it double in size?
Because it as **at this point the fibers become myelinated**

(outermost)

ariability
stimate
y a little

Q

The Optic Nerve

Portion	***Length (mm)***
Intraocular	1
Orbital	30
Canalicular	10
Intracranial	10

To which portion(s) of the intraocular nerve does the term optic nerve head *apply?*

Ana
How
The
Wha
y?

(innermost) →

(outermost) →

Portion	***Blood supply***
NFL portion?	Central retinal artery (CRA)
Pre-laminar?	Short posterior ciliary arteries
Laminar?	Arterial circle of Zinn & Haller
Retrolaminar?	Centrifugal CRA branches, centripetal pial branches

A

The Optic Nerve

Portion	***Length (mm)***
Intraocular	1
Orbital	30
Canalicular	10
Intracranial	10

To which portion(s) of the intraocular nerve does the term optic nerve head *apply?*
This one is tougher to answer. The *Glaucoma* book treats the terms optic nerve head and optic disc as synonyms. The *Fundamentals* book initially does as well…

	Portion	***Blood supply***
(innermost) →	**NFL portion** } *Glaucoma* *Fundamentals*	ntral retinal artery (CRA)
↕	Pre-laminar	Short posterior ciliary arteries
	Laminar	Arterial circle of Zinn & Haller
(outermost) →	Retrolaminar	Centrifugal CRA branches, centripetal pial branches

A

The Optic Nerve

Portion	Length (mm)
Intraocular } *Fundamentals*	1
Orbital	30
Canalicular	10
Intracranial	10

To which portion(s) of the intraocular nerve does the term optic nerve head *apply?*
This one is tougher to answer. The Glaucoma book treats the terms optic nerve head and optic disc as synonyms. The *Fundamentals* book initially does as well… but three pages later states that the nerve head is synonymous with the **entire** intraocular portion of the nerve.

	Portion	Blood supply
(innermost) →	**NFL portion**	Central retinal artery (CRA)
	Pre-laminar	Short posterior ciliary arteries
	Laminar	Arterial circle of Zinn & Haller
(outermost) →	**Retrolaminar**	Centrifugal CRA branches, centripetal pial branches

Fundamentals

Q

The Optic Nerve

Portion	***Length (mm)***
Intraocular	1
Orbital	30
Canalicular	10
Intracranial	10

Anatomically speaking, the optic nerve is considered to have four portions. What are they?
Ho
Th
Wh

One useful way to think about the layers of the intraocular portion of the optic nerve is to relate them to the tissue surrounding them. Obviously, the laminar layer is surrounded by the lamina cribrosa. What are the others surrounded by?

Portion	***Surrounded by…***
NFL portion	***?***
Pre-laminar	
Laminar	Lamina cribrosa
Retrolaminar	

(innermost) → NFL portion

↕

(outermost) → Retrolaminar

Q/A

The Optic Nerve

Portion	***Length (mm)***
Intraocular	1
Orbital	30
Canalicular	10
Intracranial	10

Anatomically speaking, the optic nerve is considered to have four portions. What are they?
Ho
Th
Wh

One useful way to think about the layers of the intraocular portion of the optic nerve is to relate them to the tissue surrounding them. Obviously, the laminar layer is surrounded by the lamina cribrosa. What are the others surrounded by?

(innermost) →
↕
(outermost) →

Portion	***Surrounded by…***
NFL portion	Retina
Pre-laminar	***?***
Laminar	Lamina cribrosa
Retrolaminar	

Q/A

The Optic Nerve

Portion	Length (mm)
Intraocular	1
Orbital	30
Canalicular	10
Intracranial	10

Anatomically speaking, the optic nerve is considered to have four portions. What are they?

One useful way to think about the layers of the intraocular portion of the optic nerve is to relate them to the tissue surrounding them. Obviously, the laminar layer is surrounded by the lamina cribrosa. What are the others surrounded by?

	Portion	Surrounded by…
(innermost) →	NFL portion	Retina
↕	Pre-laminar	Choroid
	Laminar	Lamina cribrosa
(outermost) →	*Retrolaminar*	?

A

The Optic Nerve

Portion	***Length (mm)***
Intraocular	1
Orbital	30
Canalicular	10
Intracranial	10

Anatomically speaking, the optic nerve is considered to have four portions. What are they?
Ho
Th
Wh

One useful way to think about the layers of the intraocular portion of the optic nerve is to relate them to the tissue surrounding them. Obviously, the laminar layer is surrounded by the lamina cribrosa. What are the others surrounded by?

	Portion	***Surrounded by…***
(innermost) →	NFL portion	Retina
↕	Pre-laminar	Choroid
	Laminar	Lamina cribrosa
(outermost) →	Retrolaminar	Sclera

The Optic Nerve

Q

Define papilledema.

The Optic Nerve

A

Define papilledema.

Disc edema secondary to increased ICP

Q

The Optic Nerve

Define papilledema.
Disc edema secondary to increased ICP

Where along the course of the optic nerve does ICP exert its nefarious influence?

A

The Optic Nerve

Define papilledema.
Disc edema secondary to increased ICP

Where along the course of the optic nerve does ICP exert its nefarious influence?
As anterior as it can go--the posterior aspect of the lamina cribrosa

Q

The Optic Nerve

Define papilledema.
Disc edema secondary to increased ICP

Where along the course of the optic nerve does ICP exert its nefarious influence?
As anterior as it can go--the posterior aspect of the lamina cribrosa

How does increased pressure at the lamina lead to edema of the optic disc?

A

The Optic Nerve

Define papilledema.
Disc edema secondary to increased ICP

Where along the course of the optic nerve does ICP exert its nefarious influence?
As anterior as it can go--the posterior aspect of the lamina cribrosa

How does increased pressure at the lamina lead to edema of the optic disc?
By interfering with anterograde axoplasmic flow. (Remember, the optic nerve fibers are simply the axons of retinal ganglion cells.) Axoplasmic stasis at the lamina cribrosa leads to swelling of the fibers in the pre-laminar and NFL portion of the nerve, which in the aggregate manifests as disc edema. Fiber swelling may also compromise blood flow to the pre-laminar/NFL portions of the nerve, which could lead to further axon compromise (and therefore further swelling) as well as fluid accumulation (ditto).

Q

The Optic Nerve

Define papilledema.
Disc edema secondary to increased ICP

Where along the course of the optic nerve does ICP exert its nefarious influence?
As anterior as it can go--the posterior aspect of the lamina cribrosa

How does increased pressure at the lamina lead to edema of the optic disc?
By interfering with anterograde axoplasmic flow. (Remember, the optic nerve fibers are simply the axons of retinal ganglion cells.) Axoplasmic stasis at the lamina cribrosa leads to swelling of the fibers in the pre-laminar and NFL portion of the nerve, which in the aggregate manifests as disc edema. Fiber swelling may also compromise blood flow to the pre-laminar/NFL portions of the nerve, which could lead to further axon compromise (and therefore further swelling) as well as fluid accumulation (ditto).

Is papilledema a unilateral, or bilateral condition?

A

The Optic Nerve

Define papilledema.
Disc edema secondary to increased ICP

Where along the course of the optic nerve does ICP exert its nefarious influence?
As anterior as it can go--the posterior aspect of the lamina cribrosa

How does increased pressure at the lamina lead to edema of the optic disc?
By interfering with anterograde axoplasmic flow. (Remember, the optic nerve fibers are simply the axons of retinal ganglion cells.) Axoplasmic stasis at the lamina cribrosa leads to swelling of the fibers in the pre-laminar and NFL portion of the nerve, which in the aggregate manifests as disc edema. Fiber swelling may also compromise blood flow to the pre-laminar/NFL portions of the nerve, which could lead to further axon compromise (and therefore further swelling) as well as fluid accumulation (ditto).

Is papilledema a unilateral, or bilateral condition?
Absent pre-existing damage to one nerve, it is *almost* always bilateral

The Optic Nerve

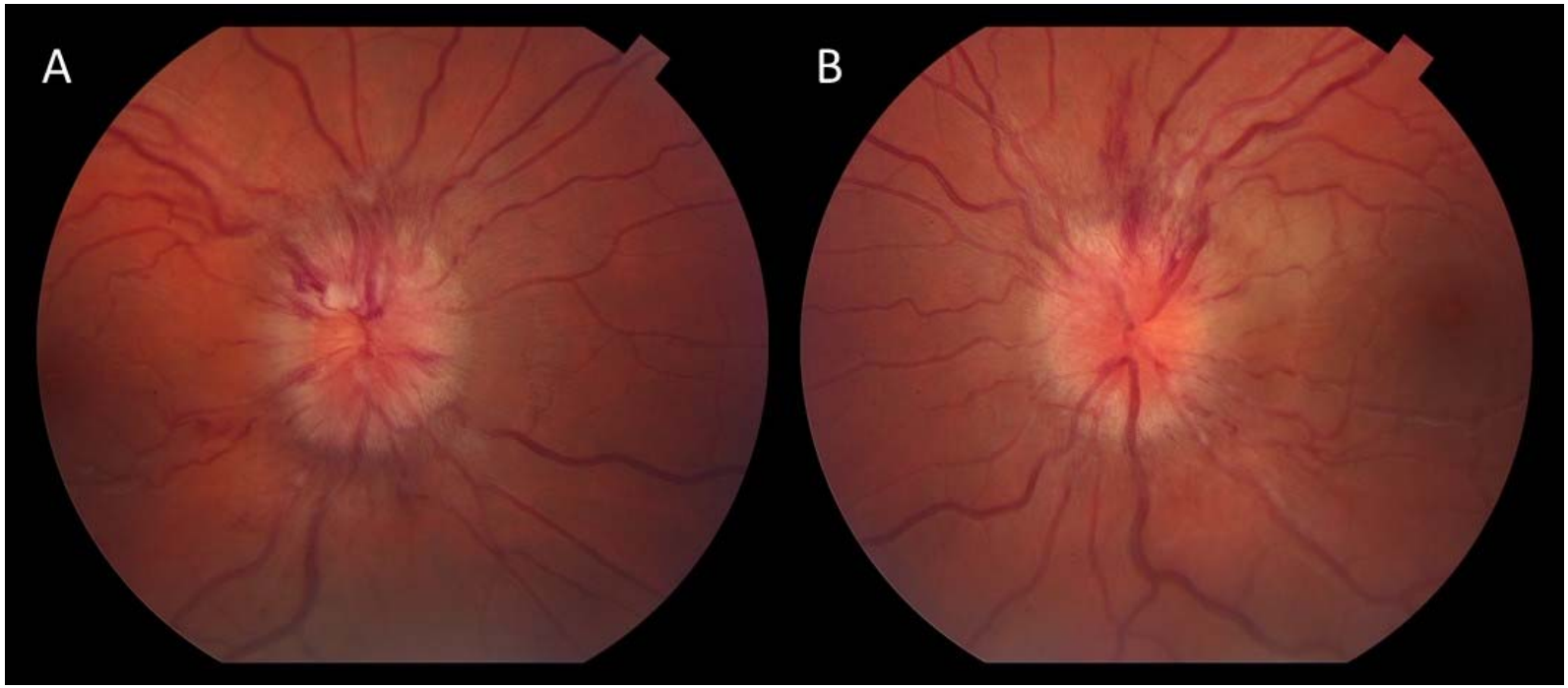

Papilledema

Q

The Optic Nerve

Define papilledema.
Disc edema secondary to increased ICP

Where along the course of the optic nerve does ICP exert its nefarious influence?
As anterior as it can go--the posterior aspect of the lamina cribrosa

How does increased pressure at the lamina lead to edema of the optic disc?
By interfering with anterograde axoplasmic flow. (Remember, the optic nerve fibers are simply the axons of retinal ganglion cells.) Axoplasmic stasis at the lamina cribrosa leads to swelling of the fibers in the pre-laminar and NFL portion of the nerve, which in the aggregate manifests as disc edema. Fiber swelling may also compromise blood flow to the pre-laminar/NFL portions of the nerve, which could lead to further axon compromise (and therefore further swelling) as well as fluid accumulation (ditto).

Is papilledema a unilateral, or bilateral condition?
Absent pre-existing damage to one nerve, **it is *almost* always bilateral**

There is a classic syndrome which presents with unilateral papilledema--what is it?

A

The Optic Nerve

Define papilledema.
Disc edema secondary to increased ICP

Where along the course of the optic nerve does ICP exert its nefarious influence?
As anterior as it can go--the posterior aspect of the lamina cribrosa

How does increased pressure at the lamina lead to edema of the optic disc?
By interfering with anterograde axoplasmic flow. (Remember, the optic nerve fibers are simply the axons of retinal ganglion cells.) Axoplasmic stasis at the lamina cribrosa leads to swelling of the fibers in the pre-laminar and NFL portion of the nerve, which in the aggregate manifests as disc edema. Fiber swelling may also compromise blood flow to the pre-laminar/NFL portions of the nerve, which could lead to further axon compromise (and therefore further swelling) as well as fluid accumulation (ditto).

Is papilledema a unilateral, or bilateral condition?
Absent pre-existing damage to one nerve, **it is *almost* always bilateral**

There is a classic syndrome which presents with unilateral papilledema--what is it?
Foster Kennedy syndrome (FKS)

Q

The Optic Nerve

Define papilledema.
Disc edema secondary to increased ICP

Where along the course of the optic nerve does ICP exert its nefarious influence?
As anterior as it can go--the posterior aspect of the lamina cribrosa

How does increased pressure at the lamina lead to edema of the optic disc?
By interfering with anterograde axoplasmic flow. (Remember, the optic nerve fibers are simply the axons of retinal ganglion cells.) Axoplasmic stasis at the lamina cribrosa leads to swelling of the fibers in the pre-laminar and NFL portion of the nerve, which in the aggregate manifests as disc edema. Fiber swelling may also compromise blood flow to the pre-laminar/NFL portions of the nerve, which could lead to further axon compromise (and therefore further swelling) as well as fluid accumulation (ditto).

Is papilledema a unilateral, or bilateral condition?
Absent pre-existing damage to one nerve, **it is *almost* always bilateral**

There is a classic syndrome which presents with unilateral papilledema--what is it?
Foster Kennedy syndrome (FKS)

What is the pathophysiology of FKS?

A

The Optic Nerve

Define papilledema.
Disc edema secondary to increased ICP

Where along the course of the optic nerve does ICP exert its nefarious influence?
As anterior as it can go--the posterior aspect of the lamina cribrosa

How does increased pressure at the lamina lead to edema of the optic disc?
By interfering with anterograde axoplasmic flow. (Remember, the optic nerve fibers are simply the axons of retinal ganglion cells.) Axoplasmic stasis at the lamina cribrosa leads to swelling of the fibers in the pre-laminar and NFL portion of the nerve, which in the aggregate manifests as disc edema. Fiber swelling may also compromise blood flow to the pre-laminar/NFL portions of the nerve, which could lead to further axon compromise (and therefore further swelling) as well as fluid accumulation (ditto).

Is papilledema a unilateral, or bilateral condition?
Absent pre-existing damage to one nerve, **it is *almost* always bilateral**

There is a classic syndrome which presents with unilateral papilledema--what is it?
Foster Kennedy syndrome (FKS)

What is the pathophysiology of FKS?
An intracranial mass is located such as to compress one optic nerve, thereby causing it to atrophy. By dint of its space-occupying capacity, the mass increases ICP enough to induce papilledema in the other, non-atrophied optic nerve. Ergo, unilateral papilledema.

The Optic Nerve

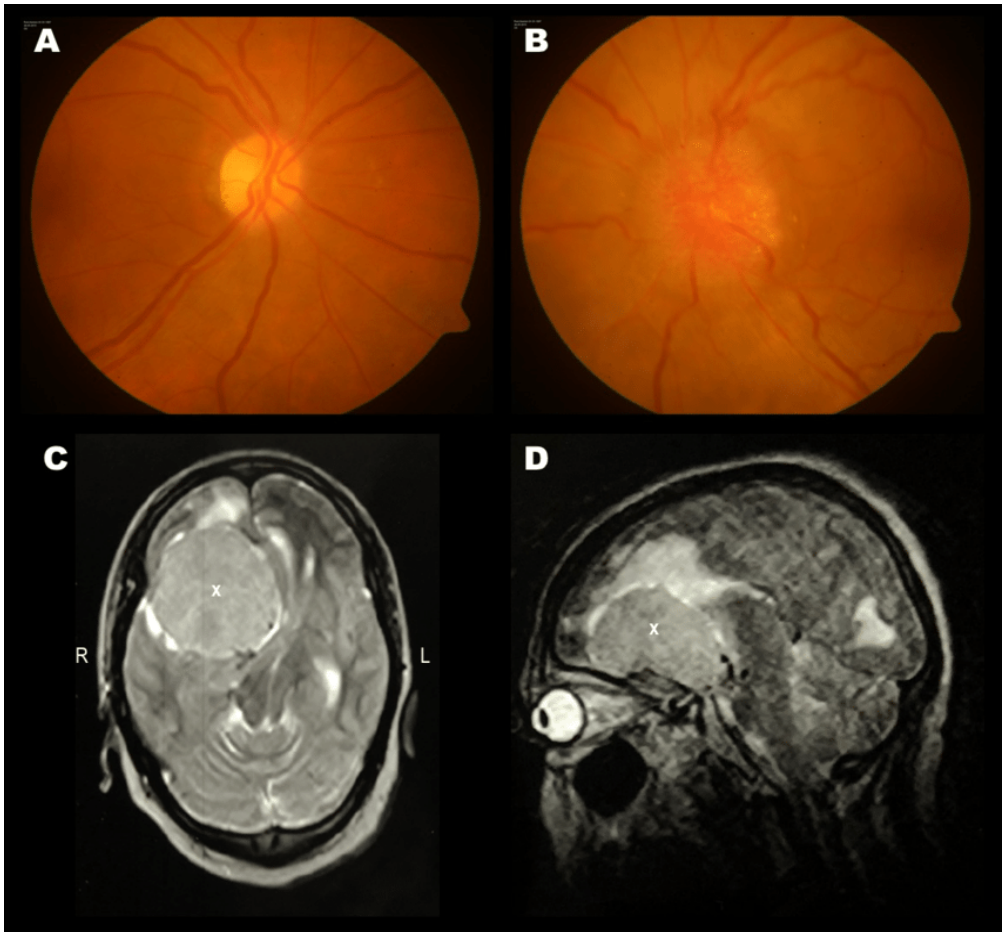

Foster Kennedy Syndrome in a 52-year-old woman (A) Fundus picture of the right eye showing optic disc pallor. (B) Fundus picture of the left eye showing disc edema with tortuosity of the peripapillary vessels. (C & D) T2 weighted MRI images in axial and sagittal view demonstrating a extra-axial, well circumscribed, homogenous, isointense mass lesion in the fronto-parietal cortex with broad based dural attachment and tenting with surrounding hyperintense cerebral oedema suggestive of meningioma.

Q

The Optic Nerve

Define papilledema.
Disc edema secondary to increased ICP

Where along the course of the optic nerve does ICP exert its nefarious influence?
As anterior as it can go--the posterior aspect of the lamina cribrosa

How does increased pressure at the lamina lead to edema of the optic disc?
By interfering with anterograde axoplasmic flow. (Remember, the optic nerve fibers are simply the axons of retinal ganglion cells.) Axoplasmic stasis at the lamina cribrosa leads to swelling of the fibers in the pre-laminar and NFL portion of the nerve, which in the aggregate manifests as disc edema. Fiber swelling may also compromise blood flow to the pre-laminar/NFL portions of the nerve, which could lead to further axon compromise (and therefore further swelling) as well as fluid accumulation (ditto).

Is papilledema a unilateral, or bilateral condition?
Absent pre-existing damage to one nerve, **it is *almost* always bilateral**

There is a classic syndrome which presents with unilateral papilledema--what is it?
Foster Kennedy syndrome (FKS)

What is tumor is the classic cause of FKS?

An intracranial mass is located such as to compress one optic nerve, thereby causing it to atrophy. By dint of its space-occupying capacity, the mass increases ICP enough to induce papilledema in the other, non-atrophied optic nerve. Ergo, unilateral papilledema.

A

The Optic Nerve

Define papilledema.
Disc edema secondary to increased ICP

Where along the course of the optic nerve does ICP exert its nefarious influence?
As anterior as it can go--the posterior aspect of the lamina cribrosa

How does increased pressure at the lamina lead to edema of the optic disc?
By interfering with anterograde axoplasmic flow. (Remember, the optic nerve fibers are simply the axons of retinal ganglion cells.) Axoplasmic stasis at the lamina cribrosa leads to swelling of the fibers in the pre-laminar and NFL portion of the nerve, which in the aggregate manifests as disc edema. Fiber swelling may also compromise blood flow to the pre-laminar/NFL portions of the nerve, which could lead to further axon compromise (and therefore further swelling) as well as fluid accumulation (ditto).

Is papilledema a unilateral, or bilateral condition?
Absent pre-existing damage to one nerve, **it is *almost* always bilateral**

There is a classic syndrome which presents with unilateral papilledema--what is it?
Foster Kennedy syndrome (FKS)

What is tumor is the classic cause of FKS?
An olfactory-groove meningioma

An intracranial mass is located such as to compress one optic nerve, thereby causing it to atrophy. By dint of its space-occupying capacity, the mass increases ICP enough to induce papilledema in the other, non-atrophied optic nerve. Ergo, unilateral papilledema.

Q

The Optic Nerve

Define papilledema.
Disc edema secondary to increased ICP

Where along the course of the optic nerve does ICP exert its nefarious influence?
As anterior as it can go--the posterior aspect of the lamina cribrosa

How does increased pressure at the lamina lead to edema of the optic disc?
By interfering with anterograde axoplasmic flow. (Remember, the optic nerve fibers are simply the axons of retinal ganglion cells.) Axoplasmic stasis at the lamina cribrosa leads to swelling of the fibers in the pre-laminar and NFL portion of the nerve, which in the aggregate manifests

Mark Twain once said a classic [book] is one that everyone talks about but nobody reads. Likewise, all ophthalmologists are aware of FKS, but no one (I know) has ever seen it.

(No question yet—keep going)

Absent pre-existing damage to one nerve, it is *almost* always bilateral

There is a ***classic syndrome*** *which presents with unilateral papilledema--what is it?*
Foster Kennedy syndrome (FKS)

What is the pathophysiology of FKS?
An intracranial mass is located such as to compress one optic nerve, thereby causing it to atrophy. By dint of its space-occupying capacity, the mass increases ICP enough to induce papilledema in the other, non-atrophied optic nerve. Ergo, unilateral papilledema.

Q

The Optic Nerve

Define papilledema.
Disc edema secondary to increased ICP

Where along the course of the optic nerve does ICP exert its nefarious influence?
As anterior as it can go--the posterior aspect of the lamina cribrosa

How does increased pressure at the lamina lead to edema of the optic disc?
By interfering with anterograde axoplasmic flow. (Remember, the optic nerve fibers are simply the axons of retinal ganglion cells.) Axoplasmic stasis at the lamina cribrosa leads to swelling of the fibers in the pre-laminar and NFL portion of the nerve, which in the aggregate manifests

Mark Twain once said a classic [book] is one that everyone talks about but nobody reads. Likewise, all ophthalmologists are aware of FKS, but no one (I know) has ever seen it. However, ***pseudo****-Foster Kennedy syndrome--disc edema in one eye + a pale atrophic nerve in the fellow eye--is a relatively common entity (at least a hundred times more common than FKS). What is the classic cause of pseudo-FKS?*

Absent pre-existing damage to one nerve, it is *almost* always bilateral

There is a ***classic syndrome*** *which presents with unilateral papilledema--what is it?*
Foster Kennedy syndrome (FKS)

What is the pathophysiology of FKS?
An intracranial mass is located such as to compress one optic nerve, thereby causing it to atrophy. By dint of its space-occupying capacity, the mass increases ICP enough to induce papilledema in the other, non-atrophied optic nerve. Ergo, unilateral papilledema.

A

The Optic Nerve

Define papilledema.
Disc edema secondary to increased ICP

Where along the course of the optic nerve does ICP exert its nefarious influence?
As anterior as it can go--the posterior aspect of the lamina cribrosa

How does increased pressure at the lamina lead to edema of the optic disc?
By interfering with anterograde axoplasmic flow. (Remember, the optic nerve fibers are simply the axons of retinal ganglion cells.) Axoplasmic stasis at the lamina cribrosa leads to swelling of the fibers in the pre-laminar and NFL portion of the nerve, which in the aggregate manifests

Mark Twain once said a classic [book] is one that everyone talks about but nobody reads. Likewise, all ophthalmologists are aware of FKS, but no one (I know) has ever seen it. However, **pseudo**-*Foster Kennedy syndrome--disc edema in one eye + a pale atrophic nerve in the fellow eye--is a relatively common entity (at least a hundred times more common than FKS). What is the classic cause of pseudo-FKS?*
A pt with a remote history of NAION in one eye (so that nerve is now pale and atrophic) with a recent NAION in the eye with disc edema

Absent pre-existing damage to one nerve, it is *almost* always bilateral

There is a ***classic syndrome*** *which presents with unilateral papilledema--what is it?*
Foster Kennedy syndrome (FKS)

What is the pathophysiology of FKS?
An intracranial mass is located such as to compress one optic nerve, thereby causing it to atrophy. By dint of its space-occupying capacity, the mass increases ICP enough to induce papilledema in the other, non-atrophied optic nerve. Ergo, unilateral papilledema.

The Optic Nerve

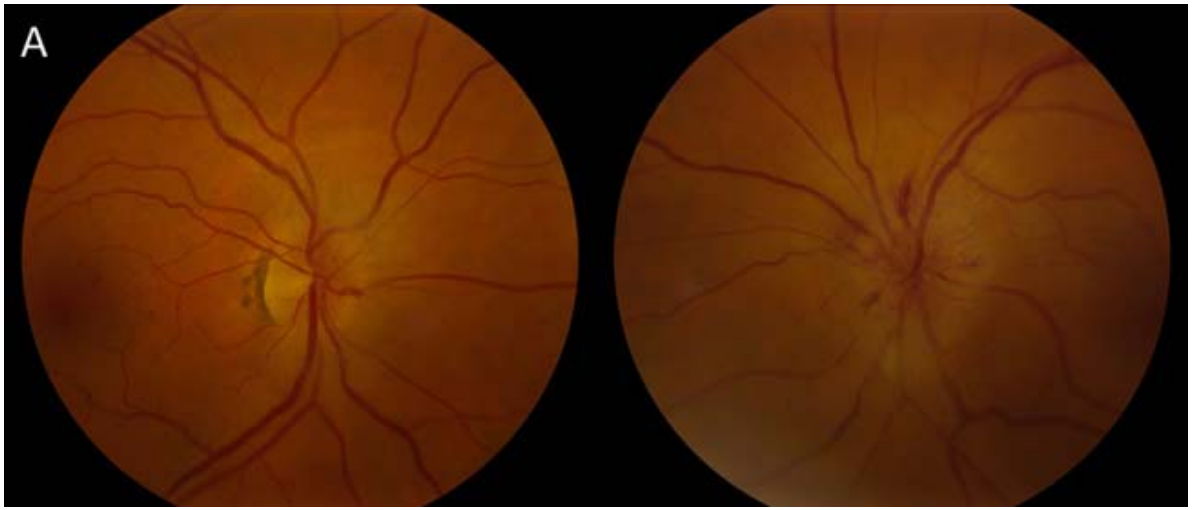

66-year-old vasculopathy with bilateral, sequential, acute painless vision loss from pseudo-Foster Kennedy syndrome. (A) He initially presented with acute vision loss OS and was noted to have disc edema with peripapillary hemorrhages OS from (NAION).

The Optic Nerve

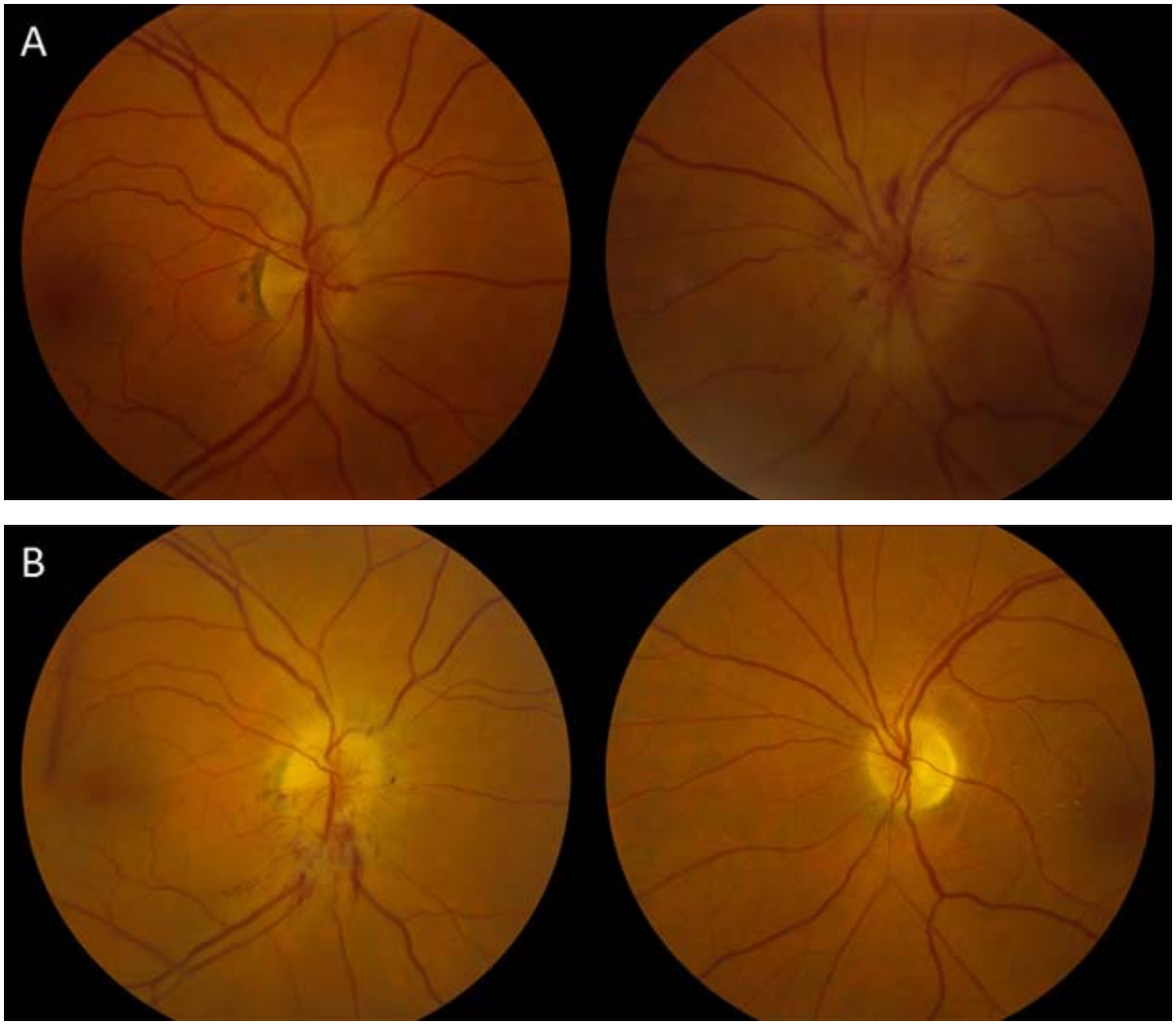

66-year-old vasculopathy with bilateral, sequential, acute painless vision loss from pseudo-Foster Kennedy syndrome. (A) He initially presented with acute vision loss OS and was noted to have disc edema with peripapillary hemorrhages OS from (NAION). (B) Three months later, he developed acute painless vision loss OD. Dilated fundus examination at that time showed diffuse pallor OS and hyperemic sectoral disc edema OD.

Q

The Optic Nerve

Compare and contrast acute vs chronic papilledema

	***Acute* papilledema**	***Chronic* papilledema**
Visual function	***?***	***?***
Disc appearance		
Shunt vessels present?		
Refractile bodies present?		
VF loss		

A

The Optic Nerve

Compare and contrast acute vs chronic papilledema

	***Acute* papilledema**	***Chronic* papilledema**
Visual function	**Largely intact**	**Affected**
Disc appearance		
Shunt vessels present?		
Refractile bodies present?		
VF loss		

Q

The Optic Nerve

Compare and contrast acute vs chronic papilledema

	Acute papilledema	*Chronic* papilledema
Visual function	Largely intact	Affected
Refractile bodies present?		
VF loss		

As a practical matter, visual functioning *refers to three specific exam findings. What are they?*
--
--
--

A

The Optic Nerve

Compare and contrast acute vs chronic papilledema

	Acute papilledema	*Chronic* papilledema
Visual function	Largely intact	Affected
Refractile bodies present?		
VF loss		

As a practical matter, visual functioning *refers to three specific exam findings. What are they?*
--Visual acuity
--Visual fields
--Color vision

Q

The Optic Nerve

Compare and contrast acute vs chronic papilledema

	***Acute* papilledema**	***Chronic* papilledema**
Visual function	Large impact	Affected

As a practical m
specific exam fi
--Visual acuity
--Visual fields
--Color vision

There is a specific clinical circumstance in which a pt with acute papilledema will manifest decreased visual function. What is it?

Q/A

The Optic Nerve

Compare and contrast acute vs chronic papilledema

	***Acute* papilledema**	***Chronic* papilledema**
Visual function	Large impact	Affected

As a practical m
specific exam fi
--Visual acuity
--Visual fields
--Color vision

There is a specific clinical circumstance in which a pt with acute papilledema will manifest decreased visual function. What is it?
It is when the papilledema is accompanied by

two words

A

The Optic Nerve

Compare and contrast acute vs chronic papilledema

	***Acute* papilledema**	***Chronic* papilledema**
Visual function	Large impact	Affected

As a practical m
specific exam fi
--Visual acuity
--Visual fields
--Color vision

There is a specific clinical circumstance in which a pt with acute papilledema will manifest decreased visual function. What is it?
It is when the papilledema is accompanied by macular edema

Q

The Optic Nerve

Compare and contrast acute vs chronic papilledema

	***Acute* papilledema**	***Chronic* papilledema**
Visual function	Large impact	Affected

As a practical m
specific exam fi
--Visual acuity
--Visual fields
--Color vision

There is a specific clinical circumstance in which a pt with acute papilledema will manifest decreased visual function. What is it?
It is when the papilledema is accompanied by macular edema

If this macular edema presents in a 'star' formation, what is the formal name for the condition, ie, for papilledema + a macular star?

A

The Optic Nerve

Compare and contrast acute vs chronic papilledema

	***Acute* papilledema**	***Chronic* papilledema**
Visual function	Large impact	Affected

As a practical m
specific exam fi
--Visual acuity
--Visual fields
--Color vision

There is a specific clinical circumstance in which a pt with acute papilledema will manifest decreased visual function. What is it?
It is when the papilledema is accompanied by macular edema

If this macular edema presents in a 'star' formation, what is the formal name for the condition, ie, for papilledema + a macular star?
It is called a **neuroretinitis**

The Optic Nerve

Neuroretinitis

Q

The Optic Nerve

Compare and contrast acute vs chronic papilledema

	***Acute* papilledema**	***Chronic* papilledema**
Visual function	Large impact	Affected

As a practical m
specific exam fi
--Visual acuity
--Visual fields
--Color vision

There is a specific clinical circumstance in which a pt with acute papilledema will manifest decreased visual function. What is it?
It is when the papilledema is accompanied by macular edema

If this macular edema presents in a 'star' formation, what is the formal name for the condition, ie, for papilledema + a macular star?
It is called a **neuroretinitis**

What is the classic cause of neuroretinitis?

A

The Optic Nerve

Compare and contrast acute vs chronic papilledema

	***Acute* papilledema**	***Chronic* papilledema**
Visual function	Large impact	Affected

As a practical m
specific exam fi
--Visual acuity
--Visual fields
--Color vision

There is a specific clinical circumstance in which a pt with acute papilledema will manifest decreased visual function. What is it?
It is when the papilledema is accompanied by macular edema

If this macular edema presents in a 'star' formation, what is the formal name for the condition, ie, for papilledema + a macular star?
It is called a **neuroretinitis**

What is the classic cause of neuroretinitis?
Bartonellosis, aka *cat-scratch dz*

The Optic Nerve

Compare and contrast acute vs chronic papilledema

	Acute papilledema	*Chronic* papilledema
Visual function	Largely intact	Affected

As a practical m
specific exam fi
--Visual acuity
--Visual fields
--Color vision

There is a specific clinical circumstance in which a pt with acute papilledema will manifest decreased visual function. What is it?
It is when the papilledema is accompanied by macular edema

If this macular edema presents in a 'star' formation, what is the

For more on Bartonellosis, see slide-set U25

What is the classic cause of neuroretinitis?
Bartonellosis, aka *cat-scratch dz*

Q

The Optic Nerve

Compare and contrast acute vs chronic papilledema

	***Acute* papilledema**	***Chronic* papilledema**
Visual function	**Largely intact**	**Affected**
Disc appearance	***?***	***?***
Shunt vessels present?		
Refractile bodies present?		
VF loss		

A

The Optic Nerve

Compare and contrast acute vs chronic papilledema

	***Acute* papilledema**	***Chronic* papilledema**
Visual function	Largely intact	Affected
Disc appearance	**Hyperemic**	**Pale**
Shunt vessels present?		
Refractile bodies present?		
VF loss		

The Optic Nerve

A

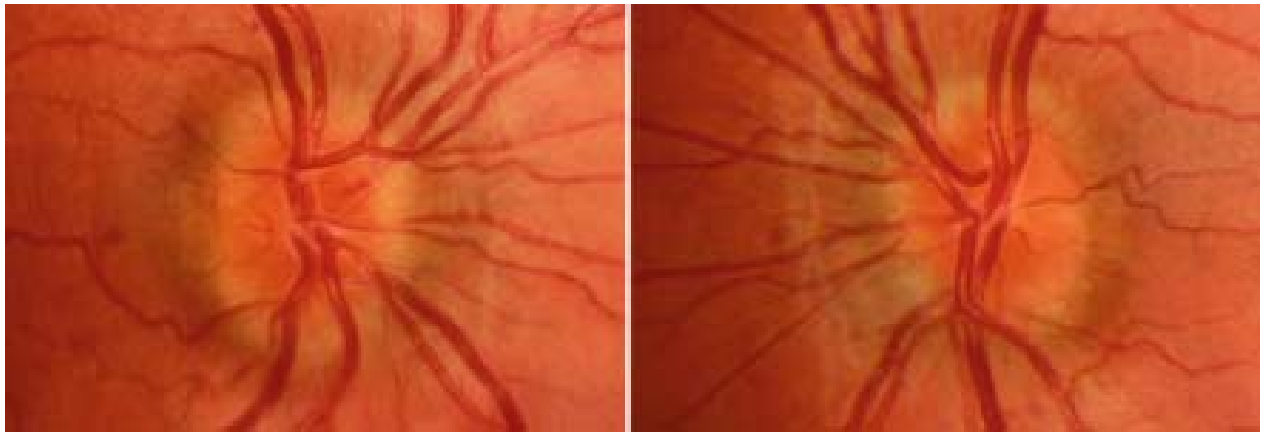

B

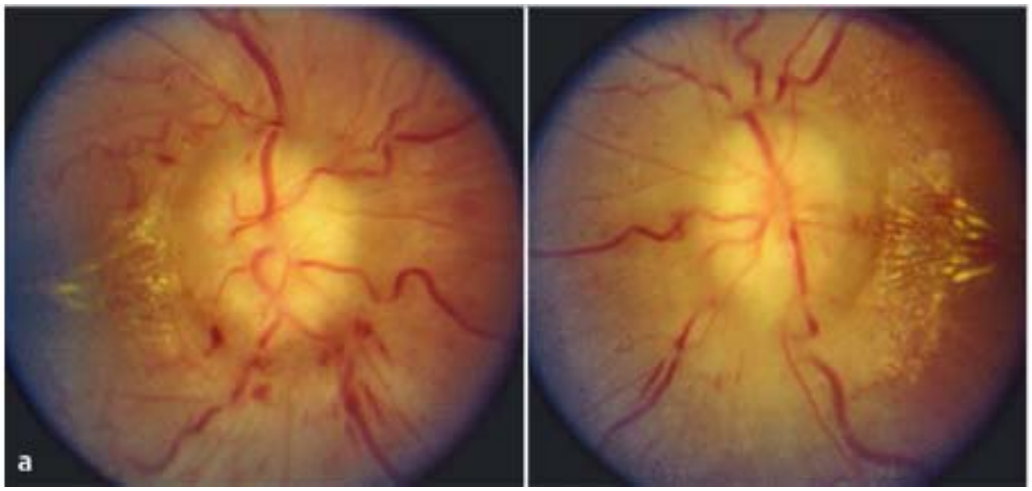

Papilledema. (A) Acute; (B) Chronic

Q

The Optic Nerve

Compare and contrast acute vs chronic papilledema

	***Acute* papilledema**	***Chronic* papilledema**
Visual function	Largely intact	Affected
Disc appearance	**Hyperemic**	**Pale**
Shunt vessels present?	***?***	***?***
Refractile bodies present?		
VF loss		

A

The Optic Nerve

Compare and contrast acute vs chronic papilledema

	***Acute* papilledema**	***Chronic* papilledema**
Visual function	Largely intact	Affected
Disc appearance	Hyperemic	Pale
Shunt vessels present?	**No**	**Yes**
Refractile bodies present?		
VF loss		

The Optic Nerve

Chronic papilledema: Shunt vessels (arrow)

Q

The Optic Nerve

Compare and contrast acute vs chronic papilledema

	Acute papilledema	*Chronic* papilledema
Visual function	Largely intact	Affected
Disc appearance	Hyperemic	Pale
Shunt vessels present?	No	**Yes**

Are shunt vessels 'new,' ie, do they represent neovascularization?

A

The Optic Nerve

Compare and contrast acute vs chronic papilledema

	Acute papilledema	*Chronic* papilledema
Visual function	Largely intact	Affected
Disc appearance	Hyperemic	Pale
Shunt vessels present?	No	**Yes**

Are shunt vessels 'new,' ie, do they represent neovascularization?
No

Q

The Optic Nerve

Compare and contrast acute vs chronic papilledema

	Acute papilledema	*Chronic* papilledema
Visual function	Largely intact	Affected
Disc appearance	Hyperemic	Pale
Shunt vessels present?	No	**Yes**

Are shunt vessels 'new,' ie, do they represent neovascularization?
No

What are they, then?

A

The Optic Nerve

Compare and contrast acute vs chronic papilledema

	Acute papilledema	*Chronic* papilledema
Visual function	Largely intact	Affected
Disc appearance	Hyperemic	Pale
Shunt vessels present?	No	**Yes**

Are shunt vessels 'new,' ie, do they represent neovascularization?
No

What are they, then?
They are pre-existing venules that, over time, have dilated in response to chronically elevated blood flow through them

Q

The Optic Nerve

Compare and contrast acute vs chronic papilledema

	Acute papilledema	***Chronic* papilledema**
Visual function	Largely intact	Affected
Disc appearance	Hyperemic	Pale
Shunt vessels present?	No	**Yes**

Are shunt vessels 'new,' ie, do they represent neovascularization?
No

What are they, then?
They are pre-existing venules that, over time, have dilated in response to chronically elevated blood flow through them

Why are these venules subject to chronic elevations in the amount of blood they must transmit?

A

The Optic Nerve

Compare and contrast acute vs chronic papilledema

	Acute papilledema	*Chronic* papilledema
Visual function	Largely intact	Affected
Disc appearance	Hyperemic	Pale
Shunt vessels present?	No	**Yes**

Are shunt vessels 'new,' ie, do they represent neovascularization?
No

What are they, then?
They are pre-existing venules that, over time, have dilated in response to chronically elevated blood flow through them

Why are these venules subject to chronic elevations in the amount of blood they must transmit?
Because the normal pathway of egress from the retina, ie, the central retinal vein, is partially obstructed in these eyes, and thus blood is forced to find alternate routes out of the eye

Q

The Optic Nerve

Compare and contrast acute vs chronic papilledema

	***Acute* papilledema**	***Chronic* papilledema**
Visual function	Largely intact	Affected
Disc appearance	Hyperemic	Pale
Shunt vessels present?	No	Yes
Refractile bodies present?	***?***	***?***
VF loss		

A

The Optic Nerve

Compare and contrast acute vs chronic papilledema

	***Acute* papilledema**	***Chronic* papilledema**
Visual function	Largely intact	Affected
Disc appearance	Hyperemic	Pale
Shunt vessels present?	No	Yes
Refractile bodies present?	**No**	**Yes**
VF loss		

Q

The Optic Nerve

'Refractile bodies'? Do you mean optic nerve drusen?

present?		
Refractile bodies present?	No	**Yes**
VF loss		

A

The Optic Nerve

'Refractile bodies'? Do you mean optic nerve drusen?
No, this is a completely different entity

present?		
Refractile bodies present?	No	**Yes**
VF loss		

Q

The Optic Nerve

'Refractile bodies'? Do you mean optic nerve drusen?
No, this is a completely different entity

OK, what are refractile bodies as seen in chronic papilledema?

present?		
Refractile bodies present?	No	**Yes**
VF loss		

A

The Optic Nerve

'Refractile bodies'? Do you mean optic nerve drusen?
No, this is a completely different entity

OK, what are refractile bodies as seen in chronic papilledema?
They are minute aggregations of lipid that leached into the optic disc interstitium

Refractile bodies present?	No	**Yes**
VF loss		

Q

The Optic Nerve

'Refractile bodies'? Do you mean optic nerve drusen?
No, this is a completely different entity

OK, what are refractile bodies as seen in chronic papilledema?
They are minute aggregations of lipid that leached into the optic disc interstitium

Where on (in?) the optic disc are they found?

Refractile bodies present?	No	**Yes**
VF loss		

A

The Optic Nerve

'Refractile bodies'? Do you mean optic nerve drusen?
No, this is a completely different entity

OK, what are refractile bodies as seen in chronic papilledema?
They are minute aggregations of lipid that leached into the optic disc interstitium

Where on (in?) the optic disc are they found?
On the surface, often near the margin

Refractile bodies present?	No	**Yes**
VF loss		

The Optic Nerve

Chronic papilledema: Refractile bodies (arrow)

Q

The Optic Nerve

'Refractile bodies'? Do you mean optic nerve drusen?
No, this is a completely different entity

OK, what are refractile bodies as seen in chronic papilledema?
They are minute aggregations of lipid that leached into the optic disc interstitium

Where on (in?) the optic disc are they found?
On the surface, often near the margin

Do they resolve along with resolution of the papilledema?

Refractile bodies present?	No	**Yes**
VF loss		

A

The Optic Nerve

'Refractile bodies'? Do you mean optic nerve drusen?
No, this is a completely different entity

OK, what are refractile bodies as seen in chronic papilledema?
They are minute aggregations of lipid that leached into the optic disc interstitium

Where on (in?) the optic disc are they found?
On the surface, often near the margin

Do they resolve along with resolution of the papilledema?
Yes

Refractile bodies present?	No	**Yes**
VF loss		

Q

The Optic Nerve

Compare and contrast acute vs chronic papilledema

	***Acute* papilledema**	***Chronic* papilledema**
Visual function	Largely intact	Affected
Disc appearance	Hyperemic	Pale
Shunt vessels present?	No	Yes
Refractile bodies present?	**No**	**Yes**
VF loss	***?***	***?***

A

The Optic Nerve

Compare and contrast acute vs chronic papilledema

	***Acute* papilledema**	***Chronic* papilledema**
Visual function	Largely intact	Affected
Disc appearance	Hyperemic	Pale
Shunt vessels present?	No	Yes
Refractile bodies present?	No	Yes
VF loss	**None, or enlarged blind spot**	**Varies, but often extensive**