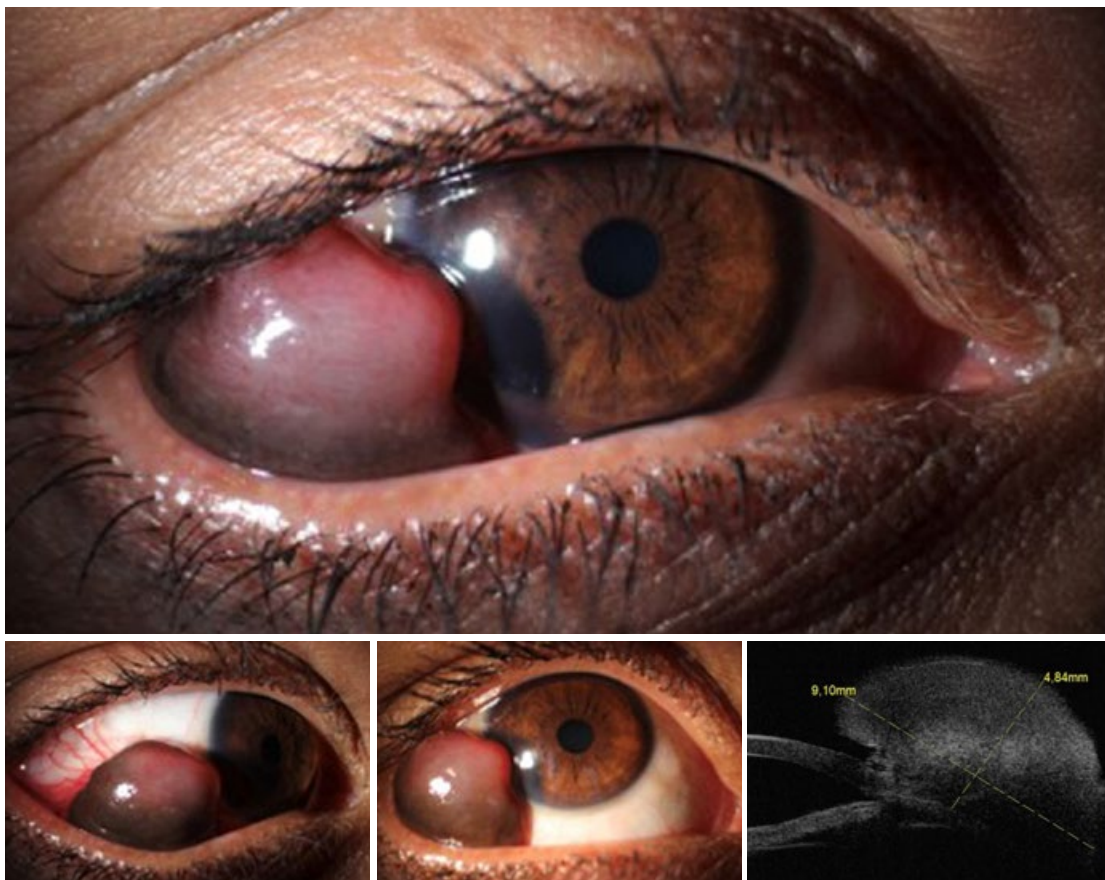

WHAT IS THIS MONTH'S MYSTERY CONDITION? Visit aao.org/eyenet to make your diagnosis in the comments and get the answer to last month's mystery.

LAST MONTH'S BLINK

Xerosis in Vitamin A Deficiency

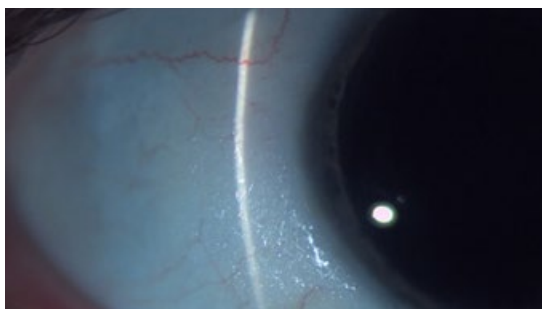
A 48-year-old woman who reported gradually worsening night vision for 1 year was referred to our clinic for possible retinal dystrophy. She also reported persistent burning and foreign body sensation associated with ocular surface dryness.

There was no family history of vision problems. Notable in her past medical history was gastric bypass surgery 13 years previously and a subsequent

100-pound weight loss. Her best-corrected visual acuity was 20/30 in her right eye and 20/40 in her left. Intraocular pressure was within normal limits. Slit-lamp examination of the anterior segment showed conjunctival xerosis in both eyes. Full-field electroretinogram demonstrated significant attenuation of waveform amplitudes under dark-adapted conditions. Serum vitamin A levels were severely diminished at $< 0.21 \mu\text{mol/L}$ (normal range is 1.05 to $2.80 \mu\text{mol/L}$).

She was started on high-dose vitamin A supplementation; this produced a dramatic improvement in her nyctalopia and ocular surface dryness within 6 months.

Nutritional malabsorption following bariatric surgery is an important and underreported cause of vitamin A deficiency in the developed world.



WRITTEN BY **SHRIJI PATEL, MD**, VANDERBILT EYE INSTITUTE, NASHVILLE, TENN.