

PEDIATRICS

Marfan Syndrome: Safer Surgeries in Subluxation Cases

BY LINDA ROACH, CONTRIBUTING WRITER
INTERVIEWING DENISE E. HIRASHIMA, MD, DAVID A. PLAGER, MD,
AND ABHAY R. VASAVADA, MS, FRCS

Marfan syndrome occurs in only 1 in 5,000 children, but its strong association with lens subluxation, a risk factor for amblyopia in children age 7 and under, raises the disorder's clinical importance for the ophthalmologist whose practice includes children.

Comprehensive ophthalmologists also might encounter this syndrome when Marfan patients, despite retaining good vision in childhood, present in their teen or young adult years with a reduction in best-corrected visual acuity (BCVA) caused by late lens subluxation.

For both types of patients, refinements in lens surgery over the last three decades have made it safer to improve their vision surgically, said David A. Plager, MD, at Indiana University Medical Center in Indianapolis.

"In the past, there were many serious complications associated with surgeries to remove subluxated lenses, things like retinal detachments and glaucoma, so for the most part surgery was discouraged. Today everything has changed and become much safer," Dr. Plager said.

Abhay R. Vasavada, MS, FRCS, who practices in Ahmedabad, India, and specializes in cataract surgical challenges, believes that the procedural improvements of recent years have lowered the threshold for surgery to protect children's developing visual system.

"It's been the standard teaching that

if we can see the border of a subluxated lens in an undilated pupil, we should operate," Dr. Vasavada said. "But now, with advanced-technology aberrometry, we can see that even a mild subluxation produces a lot of internal aberrations, degrading visual quality. In children, the development of vision really depends on the quality of vision, so I recommend that even a mild degree of subluxation should be treated surgically."

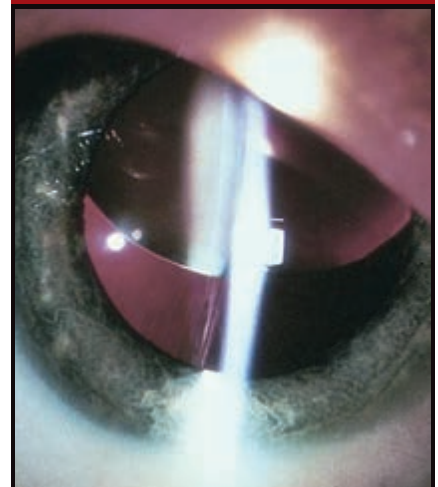
Nonsurgical Management

Loose zonules resulting from abnormal fibrillin in Marfan syndrome allow the crystalline lens to become more spherical and to decenter relative to the visual axis, Dr. Plager said. Typically, the resulting refractive error is myopic astigmatism. Refractive correction with eyeglasses or contact lenses can improve most children's acuity sufficiently to assure normal visual development and to prevent amblyopia without surgery, Dr. Plager said. "Not everybody with a subluxated lens has to have it removed. Sometimes we can achieve a reasonable refractive correction for them with glasses."

He said a corrective prescription based on a careful refraction along the phakic or aphakic pupillary axis can suffice in two situations:

- Mild decentration, with the edge of the lens outside of the visual axis
- Severe subluxation, in which the lens has migrated completely across the visual axis (in effect, the eye is aphakic)

Ectopia Lentis



Subluxated lens in a Marfan patient.

However, in some instances, optical correction might not be adequate or might not be tolerated by the patient. For example, the edge of a moderately to severely subluxated lens may bisect the visual axis, or uneven changes in lens shape and position may cause severe asymmetric refractive error.

Lenses to correct high myopic astigmatism can make life difficult for children at school, said Denise E. Hirashima, MD, in Piracicaba, São Paulo, Brazil. "In some cases you might be able to solve the problem with glasses, and this is always a good idea for kids. But we know from studies that sometimes—because of the disorienting spherical aberration from their corrective lenses—these kids cannot walk independently, and they might have social problems because of that," Dr.

Hirashima said. “If the corrected vision is less than 20/60, probably you’re going to do better for these kids with surgery.” (Dr. Hirashima coauthored a paper in *Ophthalmology* that evaluated the outcomes of replacing Marfan-associated subluxated lenses with iris-fixed intraocular lenses [IOLs].¹)

Which Surgery?

The intracapsular cataract extraction (ICCE) methods of yesteryear had a high risk of postoperative complications such as vitreous loss and retinal detachment. Today’s endocapsular surgeries are safer, although the challenges of subluxation surgery in an eye that has a very soft lens, an elastic capsule, and weak zonules remain. And the procedural details have not been settled. Said Dr. Hirashima: “The big challenge is deciding how to replace the lens because we don’t have a gold standard.” With some overlap, the techniques separate into two broad categories.

1. Endocapsular lensectomy with vitrectomy tools. This small-incision surgery uses an automated vitrector to aspirate the lens within the capsular bag, followed by removal of the empty capsular bag and an anterior vitrectomy.

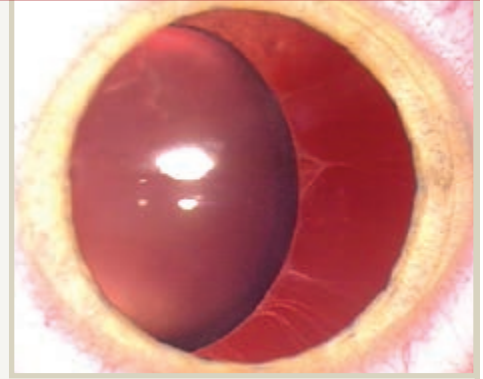
Dr. Plager said that this is his preferred surgical procedure in children with subluxation because it uses familiar instruments and has a record of reliability and safety.

Dr. Hirashima uses a modified version of this approach, employing capsulorrhexis and phaco-aspiration to extract the lens and performing a partial anterior vitrectomy while removing the bag. “The technique is not very difficult. The learning curve is not long, and we have had good outcomes. You also don’t have to manipulate the vitreous base too much,” she said.

2. Phaco-aspiration, bag preservation, and ring placement. The availability of capsular tension and scleral fixation rings in recent years has given rise to procedures intended to preserve the zonules and capsular bag while removing the lens. The surgeon recenters the bag on the visual axis, sometimes

The Basics About Marfan Syndrome

In 1991, scientists discovered that the autosomal dominant disorder known since 1896 as Marfan syndrome is caused by mutations in *FBNI*, a gene that encodes the extracellular matrix constituent fibrillin. The altered gene gives Marfan patients overly elastic connective tissues, characteristically long limbs and loose joints, and increased risk of developing an aneurysm or a thoracic aortic dissection.^{1,2}



Impact on vision. In the eye, the defective fibrillin weakens the zonules, leading to some degree of lens displacement (ectopia lentis) in more than 80 percent of Marfan cases. Most of these are subluxations, but in 3 percent to 7 percent of patients there is full dislocation, in which the crystalline lens is completely detached from the ciliary body. Some severely affected Marfan patients develop microspherophakia, which is characterized by bilaterally small, round lenses that are particularly prone to dislocation. Other secondary manifestations include early and severe myopia, retinal detachment, glaucoma, and early cataracts.

Typically in children with Marfan syndrome, visual loss due to a migrating lens does not occur until around the age of 3 or 4 years, Dr. Plager said. “It would be very unusual to have to do subluxated lens surgery in a child of under 2 or 3 years of age. It’s not like congenital cataracts. Subluxated lenses don’t show up that early,” he said.

Other etiologies. Although Marfan syndrome is the most common condition linked to childhood lens subluxation, this problem also is associated with rare conditions such as homocystinuria and Weill-Marchesani syndrome. And about 15 percent of Marfan cases are considered sporadic because they have no family history. However, Dr. Plager said he suspects these might just result from other gene mutations yet to be identified.

1 Hoffjan S. *Mol Syndromol*. 2012;3(2):47-58.

2 Neely DE, Plager DA. *Ophthalmol Clin North Am*. 2001;14(3):493-499.

inserting a capsular ring for support, and then sutures the bag to the sclera, Dr. Vasavada said. He follows this with in-the-bag implantation of an IOL.

Dr. Vasavada calls this approach “more physiological and more logical” because it avoids vitrectomy and its potential for postoperative complications, such as inflammation, glaucoma, and retinal tears. However, it pushes the procedure time to more than one hour, compared with 30 or 40 minutes for the vitrectomy-based procedure.

“The concept is to preserve the natural compartments of the capsular bag and zonules. And 99 percent of the time the vitreous face is not dis-

rupted, and therefore there is no need to perform anterior vitrectomy,” Dr. Vasavada said.

“Maintaining the compartment demands development of greater skill, and it takes a longer time to perform. But I believe that the time spent on the table is worth it for the sake of a young child, who has many years of life ahead,” he said.

IOL or Not?

Choosing aphakia. Dr. Plager said he follows the long-standing practice of leaving the child aphakic after lens subluxation surgery because the refractive power of spectacles or contact lenses can be adjusted as the eye grows.

Postponing IOL insertion also reduces the guesswork involved when deciding what power of IOL should be implanted in young children, Dr. Plager said.

“As their eye grows they’re going to become less farsighted with every passing year. The trick to picking the IOL power is to predict how much further the eye will grow, which is harder if the child is quite young,” he said. “It’s like looking at a 4-year-old and trying to predict what their shoe size will be when they’re an adult.”

Sutured IOLs. In the last decade, multiple authors have reported good visual outcomes after primary IOL implantation of open-loop anterior chamber lenses, scleral-sutured posterior chamber lenses, and iris-supported lenses in children. (See “Further Reading.”) A few surgeons fixate such implants with a glued IOL technique, in which the haptics are tucked under a scleral flap that is then sealed with fibrin glue.

But Dr. Plager is skeptical of sutured intraocular devices. In addition to reports of erosions and other adverse events at suture sites, there have been reports of late decentrations caused by deterioration of the 10.0 polypropylene (Prolene) sutures after several years, he said.^{2,3}

“I’m actually not a big fan of sutured lenses and capsular tension rings in children. We don’t know what the long-term problems are going to be with these sewn-in lenses. I don’t have faith that these sutures are going to last. We know that 10-0 sutures frequently start to break as early as five years postop. 9-0 sutures, which are now becoming popular, will last longer, but they are not going to survive as long as these children [will live]. Ten to 20 years is not going to be adequate for children with 80 years ahead of them,” he said.

But Dr. Vasavada said he is not concerned. “I have used 9.0 Prolene for 12 years, and it has never degraded,” he said. “For two years, I have used Gore-Tex sutures to scleral fixate the ring and the capsular bag, and this material is nondegradable.” He pointed out, however, that ophthalmic use of Gore-

Tex sutures remains off label in the United States.

Nor has Dr. Hirashima seen suture degradation. “We have some sutured lenses with nearly 10 years of follow-up, and the sutures are still good,” she said. In her earliest cases there were a few decentrations after a lens haptic slipped out of the suture, but this was easily remedied with a new suture, she said. She added that, at the suggestion of Walton Nose, MD, professor at the Federal University of São Paulo, she now prevents slipped sutures by fixating the haptics at the 12- and 6-o’clock positions.

The Iris-Claw Lens in the Future?

One type of lens now being studied for use in aphakic children is the Artisan iris-claw IOL (Ophtec). This modified plate-haptic lens is placed in front of the iris and does not require suturing to hold it in place. The surgeon fixates the IOL by separating the pre-halved, rounded haptics and trapping a small portion of the peripheral iris in the haptic “claws.”

In this prospective, open-label, nonrandomized clinical trial at 20 U.S. sites, the Artisan lens will be implanted in 300 patients, ages 2 through 21 years, whose eyes lack capsular support for a conventional IOL. The company hopes the trial will lead to approval of the Artisan by the FDA; it has been used internationally in adults for many years.

“This is a very exciting thing,” said Dr. Plager, who is an investigator in the trial. “The lens has never been approved for use in the United States. We have been encouraging the company for over a decade to do this trial in the U.S. and are very happy that they now are doing so.” ■

1 Hirashima D et al. *Ophthalmology*. 2010;

117(8):1479-1485.

2 Price MO et al. *J Cataract Refract Surg*.

2005;31(7):1320-1326.

3 Luk AS et al. *Br J Ophthalmol*. 2013;97

(10):1308-1311.

Denise E. Hirashima, MD, is a cornea, external disease, and cataract subspecialist in pri-

vate practice in Piracicaba, São Paulo, Brazil. Financial disclosure: None.

David A. Plager, MD, is professor and director of the Section of Pediatric Ophthalmology and Adult Strabismus for the Glick Eye Institute, at Indiana University Medical Center in Indianapolis. Financial disclosure: None.

Abhay R. Vasavada, MS, FRCS (England), heads the Raghudeep Eye Clinic and the Iladevi Cataract & IOL Research Centre, in Ahmedabad, India. Financial disclosure: Has received research grants and travel funding from Alcon.

Further Reading

For further reading about IOL placement in children (and adults) with Marfan syndrome, as well as several related articles, the following may be of interest.

Cionni RJ et al. Modified capsular tension ring for patients with congenital loss of zonular support. *J Cataract Refract Surg*. 2003;29(9):1668-1673.

Dureau P et al. Iris fixation of foldable intraocular lenses for ectopia lentis in children. *J Cataract Refract Surg*. 2006;32(7):1109-1114.

Lam DS et al. Scleral fixation of a capsular tension ring for severe ectopia lentis. *J Cataract Refract Surg*. 2000;26(4):609-612.

Morrison D et al. Anterior chamber intraocular lens (ACIOL) placement after pars plana lensectomy in pediatric Marfan syndrome. *J AAPOS*. 2005;9(3):240-242.

Tsai YY, Tseng SH. Transscleral fixation of foldable intraocular lens after pars plana lensectomy in eyes with a subluxated lens. *J Cataract Refract Surg*. 1999;25(5):722-724.

Wagoner MD et al. Intraocular lens implantation in the absence of capsular support; a report by the American Academy of Ophthalmology (Ophthalmic Technology Assessment). *Ophthalmology*. 2003;110(4):840-859.

Zetterström C et al. Sulcus fixation without capsular support in children. *J Cataract Refract Surg*. 1999;25(6):776-781.