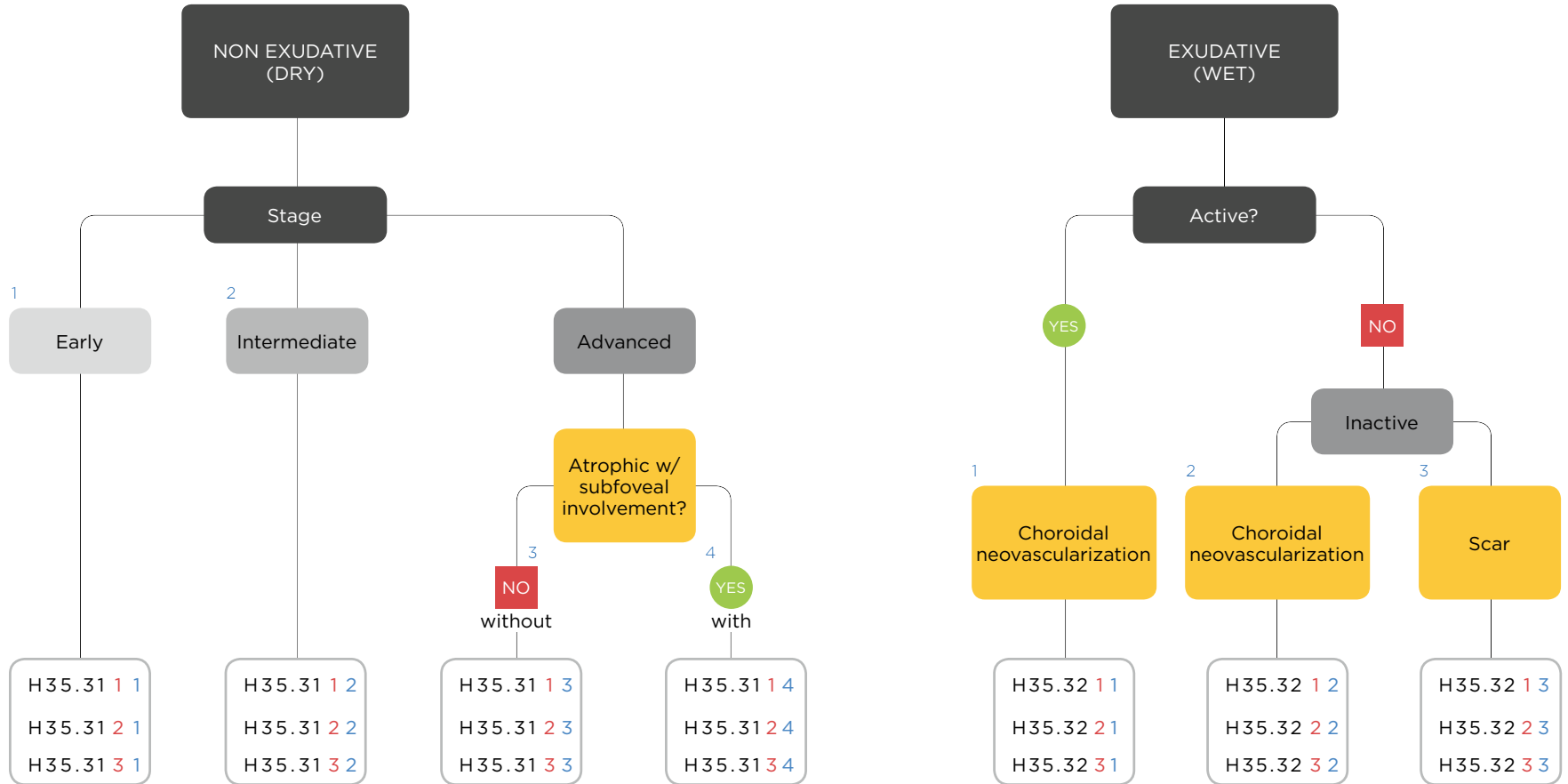


AGE-RELATED MACULAR DEGENERATION



**H35.31**

DRY ARMD	LATERALITY	STAGE
1	right	1 early
2	left	2 intermediate
3	bilateral	3 adv. atrophic w/o subfoveal involvement
		4 adv. atrophic w/subfoveal involvement

**H35.32**

WET ARMD	LATERALITY	STAGE
1	right	1 active neovascularization
2	left	2 inactive neovascularization
3	bilateral	3 inactive scar