

ACHIEVING SURGICAL SUCCESS AND PATIENT SATISFACTION WITH MIGS

International Perspectives



VISIT [HTTPS://TINYURL.COM/MIGSPERSPECTIVES](https://tinyurl.com/migsperspectives) FOR
ONLINE TESTING AND INSTANT CME CERTIFICATE.

Original Release: July 1, 2020

Expiration: July 31, 2021



FACULTY

Joseph F. Panarelli, MD (Chair)

Ike K. Ahmed, MD, FRCS

Keith Barton, MD, FRCP, FRCS

Anna T. Do, MD

Julian Garcia-Feijoo, MD, PhD

Marlene R. Moster, MD

This continuing medical education activity is provided by New York Eye and Ear Infirmary of Mount Sinai.
This educational activity was developed and implemented in collaboration with MedEdicus LLC.



MedEdicus

This continuing medical education activity is supported through an unrestricted educational grant from Santen Inc.

Distributed with EyeNet

LEARNING METHOD AND MEDIUM

This educational activity consists of a supplement and nine (9) study questions. The participant should, in order, read the learning objectives contained at the beginning of this supplement, read the supplement, answer all questions in the post test, and complete the Activity Evaluation/Credit Request form. To receive credit for this activity, please follow the instructions provided on the post test and Activity Evaluation/Credit Request form. This educational activity should take a maximum of 1.5 hours to complete.

ACTIVITY DESCRIPTION

More than 40% of patients with glaucoma require maximal medical treatment (MMT) to reach their target intraocular pressure (IOP). MMT can fail to achieve IOP targets, however, because of overt treatment failure or the presence of ocular surface disease, which can lead to a lack of adherence to medication schedules. For these patients, another strategy is needed to reach target IOP. Bleb-based minimally invasive glaucoma surgery (MIGS) procedures balance efficacy and safety and provide a viable option for patients with moderate to severe glaucoma who cannot achieve their IOP goal on MMT. As compared with tube-shunt surgery, subconjunctival bleb-based MIGS also provides favorable postsurgical quality of life outcomes. Optimization of bleb health is an important component of this strategy, and new data provide insight into best practices for antimetabolite treatment and follow-up examination. The desired results of this educational activity are for ophthalmologists to gain the knowledge and competence they need to ensure the best possible outcomes for their patients with glaucoma, now and as new therapies are approved.

TARGET AUDIENCE

This educational activity is intended for glaucoma specialists and other ophthalmologists caring for patients with glaucoma.

LEARNING OBJECTIVES

Upon completion of this activity, participants will be better able to:

- Discuss the safety and efficacy of MIGS devices for patients with moderate to severe glaucoma
- Describe clinically relevant quality of life outcomes associated with various MIGS procedures
- Choose appropriate MIGS procedures according to individual patient factors
- Integrate evidence-based best practices for prevention of bleb failure into practice

ACCREDITATION STATEMENT



The **New York Eye and Ear Infirmary of Mount Sinai** is accredited by the Accreditation Council for Continuing Medical Education (ACCME) to provide continuing medical education for physicians. This educational activity was developed and implemented in collaboration with **MedEdicus LLC**.

AMA CREDIT DESIGNATION STATEMENT

The **New York Eye and Ear Infirmary of Mount Sinai** designates this enduring material for a maximum of 1.5 **AMA PRA Category 1 Credits™**. Physicians should claim only the credit commensurate with the extent of their participation in the activity.

GRANTOR STATEMENT

This continuing medical education activity is supported through an unrestricted educational grant from Santen Inc.

DISCLOSURE POLICY STATEMENT

It is the policy of **New York Eye and Ear Infirmary of Mount Sinai** that the faculty and anyone in a position to control activity content disclose any real or apparent conflicts of interest relating to the topics of the educational activity in which they are participating. They are also required to disclose discussions of unlabeled/unapproved uses of drugs or devices during their presentations. **New York Eye and Ear Infirmary of Mount Sinai** is committed to providing its learners with quality CME activities and related materials that promote improvements in healthcare and not the proprietary interests of a commercial interest and, thus, has established policies and procedures in place that identify and resolve all conflicts of interest prior to the execution or release of its educational activities. Full disclosure of faculty/planners and their commercial relationships, if any, follows.

DISCLOSURES

Ike K. Ahmed, MD, had a financial agreement or affiliation during the past year with the following commercial interests in the form of *Consultant/Advisory Board*: Aequus BioPharma, Inc; Aerie Pharmaceuticals, Inc; Akorn, Inc; Alcon; Allergan; ArcScan, Inc; Bausch & Lomb Incorporated; Beaver-Visitec International; Beyonic Surgical Ltd; Camras Vision, Inc; Carl Zeiss Meditec, Inc; CorNeat Vision Ltd; Ellex; ELT Sight, Inc; ElutiMed; Equinox; Genentech, Inc; Glaukos Corporation; Injectsense, Inc; IRIDEX Corporation; iSTAR; Ivantis Inc; Johnson & Johnson Vision Care, Inc; Kelotec Inc; LayerBio, Inc; Leica Microsystems; MicroOptx; MicroSurgical Technology; Minosys Cellular Devices Inc; New World Medical, Inc; Ocular Instruments; Ocular Therapeutix, Inc; Omega Ophthalmics; Polyactiva Pty Ltd; Sanoculis Ltd; Santen Inc; ScienceBased Health; Sight Sciences; Ströma Medical Corporation; Thea Pharmaceuticals Limited; Vialase, Inc; Vizzario; and W. L. Gore & Associates, Inc; *Contracted Research*: Aerie Pharmaceuticals, Inc; Alcon; Allergan; Camras Vision, Inc; Glaukos Corporation; Ivantis Inc; Johnson & Johnson Vision Care, Inc; New World Medical, Inc; and Santen Inc; *Honoraria from promotional, advertising or non-CME services received directly from commercial interests or their Agents (eg, Speakers Bureaus)*: Alcon; Allergan; Carl Zeiss Meditec, Inc; Johnson & Johnson Vision Care, Inc; MicroSurgical Technology; and Mundipharma International.

Keith Barton, MD, had a financial agreement or affiliation during the past year with the following commercial interests in the form of *Consultant/Advisory Board*: Advanced Ophthalmic Implants Pte Ltd; Alcon; Allergan; Calpain Therapeutics; EyD Pharma SA; Eye Tech Care; Glaukos Corporation; iSTAR; Ivantis Inc; Laboratoires Théa; pH PHARMA; Radiance Therapeutics, Inc; Santen Pharmaceutical Co, Ltd; and Transcend Medical, Inc; *Contracted Research*: Allergan; Aquesys, Inc; Laboratoires Théa; and Merck & Co., Inc; *Honoraria from promotional, advertising or non-CME services received directly from commercial interests or their Agents (eg, Speakers Bureaus)*: Aquesys, Inc; and MedEther Ophthalmology Ltd.

Anna T. Do, MD, has no relevant commercial relationships to disclose.

Julian Garcia-Feijoo, MD, PhD, had a financial agreement or affiliation during the past year with the following commercial interests in the form of *Consultant/Advisory Board*: Alcon; Allergan; Glaukos Corporation; iSTAR; and Santen Pharmaceutical Co, Ltd; *Contracted Research*: Alcon; Allergan; Glaukos Corporation; iSTAR; Ivantis Inc; and Santen Pharmaceutical Co, Ltd; *Honoraria from promotional, advertising or non-CME services received directly from commercial interests or their Agents (eg, Speakers Bureaus)*: Alcon; Allergan; and Santen Pharmaceutical Co, Ltd.

Marlene R. Mosier, MD, had a financial agreement or affiliation during the past year with the following commercial interests in the form of *Consultant/Advisory Board*: Alcon; Allergan; Merck & Co., Inc; Qura Inc; and SOLX, Inc; *Contracted Research*: Aeon Astron Corporation; Aerie Pharmaceuticals, Inc; Alcon; Allergan; Bausch & Lomb Incorporated; Glaukos Corporation; InnFocus Inc; IOP Ophthalmics; IRIDEX Corporation; New World Medical, Inc; SOLX, Inc; and Valeant; *Honoraria from promotional, advertising or non-CME services received directly from commercial interests or their Agents (eg, Speakers Bureaus)*: Alcon; Allergan; Bausch & Lomb Incorporated; Merck & Co., Inc; New World Medical, Inc; and TBI.

Joseph F. Panarelli, MD, had a financial agreement or affiliation during the past year with the following commercial interests in the form of *Honoraria from promotional, advertising or non-CME services received directly from commercial interests or their Agents (eg, Speakers Bureaus)*: Aerie Pharmaceuticals, Inc; Allergan; CorneaGen; Glaukos Corporation; New World Medical, Inc; and Santen Inc.

NEW YORK EYE AND EAR INFIRMARY OF MOUNT SINAI PEER REVIEW DISCLOSURES

Tak Yee Tania Tai, MD, has no relevant commercial relationships to disclose.

Kateki Vinod, MD, has no relevant commercial relationships to disclose.

EDITORIAL SUPPORT DISCLOSURES

Erika Langsfeld, PhD; **Cynthia Tornallyay, RD, MBA, CHCP**; **Kimberly Corbin, CHCP**; **Barbara Aubel**; and **Michelle Ong** have no relevant commercial relationships to disclose.

Medical Writer: Tony Realini, MD, had a financial agreement or affiliation during the past year with the following commercial interests in the form of *Honoraria from promotional, advertising or non-CME services received directly from commercial interests or their Agents (eg, Speakers Bureaus)*: Aerie Pharmaceuticals, Inc; Allergan; CorneaGen; Glaukos Corporation; New World Medical, Inc; and Santen Inc.

DISCLOSURE ATTESTATION

The contributing physicians listed above have attested to the following:

- 1) that the relationships/affiliations noted will not bias or otherwise influence their involvement in this activity;
- 2) that practice recommendations given relevant to the companies with whom they have relationships/affiliations will be supported by the best available evidence or, absent evidence, will be consistent with generally accepted medical practice; and
- 3) that all reasonable clinical alternatives will be discussed when making practice recommendations.

OFF-LABEL DISCUSSION

This CME activity includes discussion of unlabeled and/or investigative uses of drugs. Please refer to the official prescribing information for each drug discussed in this activity for FDA-approved dosing, indications, and warnings.

NEW YORK EYE AND EAR INFIRMARY OF MOUNT SINAI PRIVACY & CONFIDENTIALITY POLICIES

<https://www.nyee.edu/education/cme>

CME PROVIDER CONTACT INFORMATION

For questions about this activity, call 212-870-8125.

TO OBTAIN AMA PRA CATEGORY 1 CREDIT™

To obtain **AMA PRA Category 1 Credit™** for this activity, read the material in its entirety and consult referenced sources as necessary. Please take this post test and evaluation online by going to <https://tinyurl.com/MIGSperspectives>. Upon passing, you will receive your certificate immediately. You must score 70% or higher to receive credit for this activity, and may take the test up to 2 times. Upon registering and successfully completing the post test, your certificate will be made available online and you can print it or file it.

DISCLAIMER

The views and opinions expressed in this educational activity are those of the faculty and do not necessarily represent the views of **New York Eye and Ear Infirmary of Mount Sinai**, **MedEdicus LLC**, Santen Inc, **EyeNet**, or the American Academy of Ophthalmology.

This CME activity is copyrighted to MedEdicus LLC ©2020. All rights reserved. 204

Cover image courtesy of Joseph F. Panarelli, MD

FACULTY

Joseph F. Panarelli, MD (Chair)

Associate Professor of Ophthalmology
Chief, Division of Glaucoma Services
Glaucoma Fellowship Director
NYU Langone Eye Center
New York, New York

Ike K. Ahmed, MD, FRCSC

Professor
University of Utah
Salt Lake City, Utah
Assistant Professor
Director, Glaucoma and Advanced Anterior Segment Surgery
(GAASS) Fellowship
Research Director, Kensington Eye Institute
University of Toronto
Toronto, Canada

Keith Barton, MD, FRCP, FRCS

Consultant Ophthalmologist
Moorfields Eye Hospital and London Claremont Clinic
Honorary Reader, UCL Institute of Ophthalmology
London, United Kingdom

Anna T. Do, MD

Clinical Glaucoma Fellow
Department of Ophthalmology
New York University Langone Health
New York, New York

Julian Garcia-Feijoo, MD, PhD

Professor and Chairman
Ophthalmology Department
Hospital Clinico San Carlos
Universidad Complutense de Madrid
Madrid, Spain

Marlene R. Moster, MD

Professor of Ophthalmology
Thomas Jefferson University School of Medicine
Attending Surgeon, Glaucoma Service
Wills Eye Institute
Philadelphia, Pennsylvania

CME REVIEWERS FOR NEW YORK EYE AND EAR INFIRMARY OF MOUNT SINAI

Tak Yee Tania Tai, MD

Associate Professor of Ophthalmology
Icahn School of Medicine at Mount Sinai
Director, Microsurgical Laboratory
Co-Director, Glaucoma Service
New York Eye and Ear Infirmary of Mount Sinai
New York, New York

Kateki Vinod, MD

Assistant Professor of Ophthalmology
Icahn School of Medicine at Mount Sinai
Associate Adjunct Surgeon
New York Eye and Ear Infirmary of Mount Sinai
New York, New York

ACHIEVING SURGICAL SUCCESS AND PATIENT SATISFACTION WITH MIGS

International Perspectives

GLAUCOMA SURGERY AND QUALITY OF LIFE

The advent of minimally invasive glaucoma surgery (MIGS) has broadened the indications for glaucoma surgery. Specifically, with safer operations for patients who may not require the intraocular pressure (IOP) reductions provided by trabeculectomy or tube shunts, surgery can be considered earlier in the treatment process than in the past, particularly among patients undergoing elective cataract surgery.^{1,2} MIGS procedures have been shown to effectively lower IOP and, equally importantly, to reduce the medication burden.^{1,2} Reducing the medication burden can improve or eliminate the need for daily adherence, minimize or eliminate topical therapy-related adverse effects, and reduce exposure to active and excipient ingredients in glaucoma medications. These attributes would be expected to improve patients' quality of life (QOL), although there are very little data to support this belief.³

In broad terms, QOL is defined as individuals' perception of their position in life in the context of the culture and value systems in which they live.³ This is a wide-ranging concept affected in a complex way by many different factors, including physical health, personal circumstances—such as living conditions—relationships, functional activities, and socioeconomic status.

Very little is known about the relationship between glaucoma surgery and QOL. A recent systematic review on the topic identified only a single study—CIGTS (Collaborative Initial Glaucoma Treatment Study)—to formally evaluate the effect of glaucoma surgery on QOL.³ In CIGTS, newly diagnosed patients with open-angle glaucoma (OAG) were randomly assigned to receive initial medical therapy or initial surgery (trabeculectomy).^{4,5} QOL was assessed using several validated instruments at baseline, at 3 and 6 months after initiating therapy, and every 6 months thereafter for at least 4 years.⁴ Investigators found that the effect of glaucoma surgery on eye symptoms was initially significant, but the magnitude of this effect decreased over time. Additionally, the fear of blindness was approximately 80% at baseline—the time of diagnosis of glaucoma—and decreased to approximately 50% over time.⁶ Glaucoma is also associated with significant rates of anxiety (13%) and depression (11%), attributable in part to the asymptomatic nature of this potentially blinding disease and patients' inability to assess or perceive their glaucoma status.⁷

In the absence of clear data defining the relationship and determinants of QOL after glaucoma surgery, it can be useful to consider the features of an ideal glaucoma procedure likely to minimally affect QOL. Ideally, the procedure would have minimal effect on visual acuity (VA) in the immediate postoperative period, with rapid visual rehabilitation to baseline. The need for secondary procedures—such as suture lysis or bleb needling—should be minimal, with consistent IOP control throughout the postoperative period. The need for eye drops—both for inflammation/infection control in the perioperative period and for IOP reduction postoperatively—should be minimized. The procedure should be minimally traumatic and cause minimal pain or discomfort.

Many of the new MIGS procedures offer these attributes, and for patients who require glaucoma surgery or who opt for combined surgery at the time of cataract extraction, MIGS is a viable option. The MIGS family is diverse and growing, with procedures that

Table 1. Family of Minimally Invasive Glaucoma Surgical Procedures

Site of Bypass (Type of Procedure)	Device	Maker	Approved in the United States	Approved in Canada	Approved in Europe	Standalone	Approach
Schlemm canal (internal MIGS)	Trabectome	NeoMedix Corporation	Yes	Yes	Yes	Yes	Interno
	iStent	Glaukos Corporation	Yes	Yes	Yes	Yes (Europe and Canada) No (United States)	Interno
	Hydrus	Ivantis Inc	Yes	Yes	Yes	No	Interno
	Kahook Dual Blade	New World Medical, Inc	Yes	Yes	Yes	Yes	Interno
	GATT	Ellex	Yes	Yes	Some countries	Yes	Interno
	Ab interno canaloplasty	Ellex	Yes	Yes	Some countries	Yes	Interno
	VISC0360	Sight Sciences	Yes	Yes	Yes	Yes	Interno
	iStent Supra	Glaukos Corporation	No	No	Yes	Yes	Interno
Subconjunctival space (external MIGS)	XEN Gel Stent	Allergan	Yes	Yes	Yes	Yes	Interno/ Externo
	PreserFlo MicroShunt	Santen Inc	No (in phase 3 trials)	No	Yes	Yes	Externo

Abbreviations: GATT, gonioscopy-assisted transluminal trabeculotomy; MIGS, minimally invasive glaucoma surgery.

shunt aqueous humor from the anterior chamber into Schlemm canal and the subconjunctival space (Table 1). These latter procedures rely on the formation of a filtering bleb, and thus offer the potential for greater IOP reductions in eyes with advanced glaucoma and/or those needing low target IOPs.

For patients with newly diagnosed glaucoma who may not yet be surgical candidates, selective laser trabeculoplasty (SLT) is a minimally invasive option that can be appropriately deployed earlier in the treatment process. A recent study has demonstrated the value of primary SLT for long-term IOP control. In the LiGHT (Laser in Glaucoma and Ocular Hypertension) study, 718 patients newly diagnosed with OAG or high-risk ocular hypertension received either primary SLT or medical therapy and were followed for 3 years.⁸ SLT could be repeated and medications could be added to attain disease- and severity-specific target IOP. Outcomes, including QOL, VA, IOP, and progression rates, were similar between the 2 groups. At 3 years, 78% of 419 SLT-treated eyes remained medication free and at target IOP; of these, 76% required just a single SLT treatment. SLT is a viable first-line alternative to medical therapy. For patients who wish to avoid drops and their attendant drawbacks from the time of diagnosis onward, SLT and MIGS together represent treatment options for every stage of glaucoma.

CASE 1: MODERATE GLAUCOMA

From the Files of Anna T. Do, MD

A 52-year-old woman with a 6-year history of OAG was referred to consider surgical options because of increasing intolerance of topical medical therapy. She was a busy attorney, and bothered by chronic hyperemia and symptoms of ocular surface disease (OSD). Her peak pretreatment IOP was 28 mm Hg OU. Over the past several visits, her IOP ranged from 16 to 20 mm Hg. Her central corneal thickness (CCT) was normal (540 μ m OD and 545 μ m OS). She was using a prostaglandin analogue and a beta blocker/alpha agonist fixed combination OU and reported good adherence. She had previously undergone bilateral SLT several times, with minimal response to the most recent treatment. A review of her visual fields and optical coherence tomography (OCT) images of the retinal nerve fiber layer (RNFL) demonstrated modest progression OD over the past 4 years and possibly mild progression OS (Figure 1). A week of home tonometry (iCare Home, iCare) revealed IOP ranging from 14 to 18 mm Hg OU, and an in-office water-drinking test demonstrated peak IOP of 28 mm Hg OD and 25 mm Hg OS at 15 minutes.

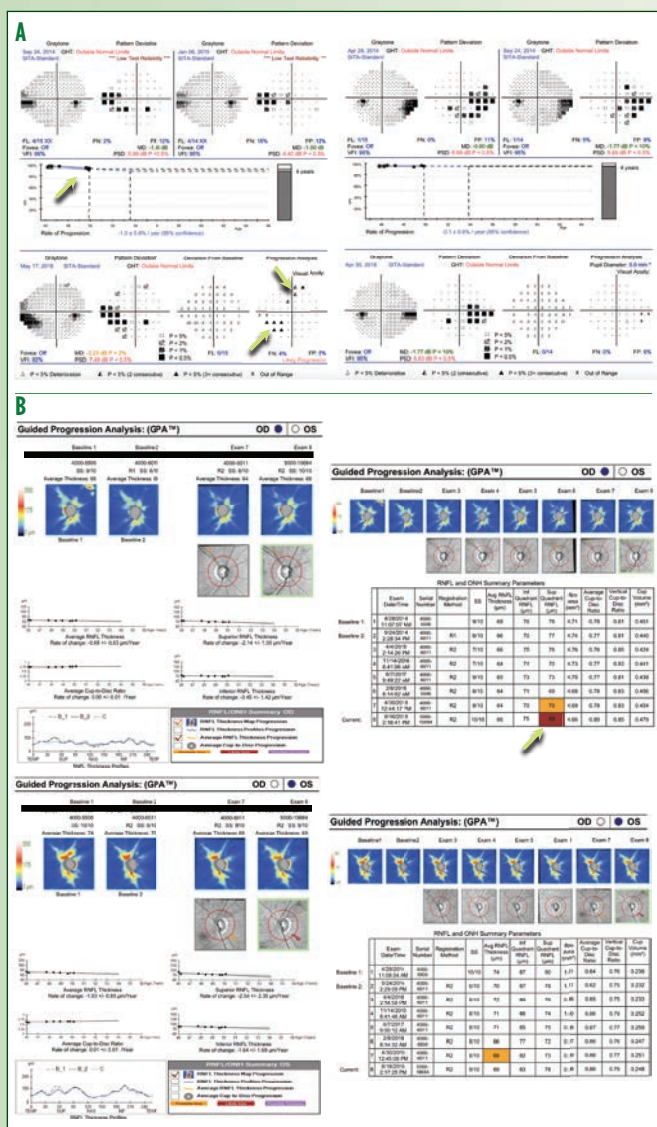


Figure 1. Visual fields (A) and retinal nerve fiber layer optical coherence tomography images (B) of the patient presented in Case 1. Note modest progression in the right eye (green arrows) and possible progression in the left eye.

Dr Barton: Her rate of progression is quite slow, manifesting over 4 years on the visual fields. The patient is rather young. She is bothered by adverse effects of her topical therapy. She had maximized the benefits of SLT. She is now a candidate for surgery; she would be an ideal patient for a MIGS procedure. In general, I tend to perform an external subconjunctival MIGS standalone procedure when the goal is IOP reduction, as it is for this patient.

Dr Panarelli: Her IOP variability—particularly with the water-drinking test—demonstrates that she has impaired ability to regulate her IOP. This suggests significant impairment of her outflow system, whether it is the trabecular meshwork (TM), Schlemm canal, collector channels, episcleral veins, or all the aforementioned.⁹ An internal MIGS procedure can address the TM obstruction, but will not address any post-TM outflow impairment in the canal or collector

channels.¹⁰ Therefore, I agree that an external MIGS procedure is best for this patient.

Dr Do: We also want to reduce her medication burden to improve her OSD symptoms. OSD affects 30% to 70% of patients on glaucoma therapy,¹¹⁻¹⁷ and chronic topical medication use can aggravate it even further.¹⁸

Dr Feijoo: The nonresponsiveness to repeat SLT may indicate that the distal outflow system is impaired, which also supports the use of an external MIGS procedure.

Dr Panarelli: It would not be unreasonable to consider a trabeculectomy or tube-shunt procedure, but I do not think this patient needs the low target IOP these procedures can deliver. A reasonable IOP goal for her is the midteens, with fewer medications to improve her symptoms, so I would lean toward an external MIGS procedure to balance the modest IOP requirement with the better safety profile of MIGS over traditional filtering surgery.¹

Dr Ahmed: Conversely, if she were a bit older and had less visual field damage, I would consider an internal MIGS procedure as a first step because the chief goal in that case would be medication reduction.

Dr Moster: Planning ahead, a superonasal subconjunctival MIGS procedure will leave you plenty of room, with untouched conjunctiva, for a future filtering surgery if needed. Given the patient's young age, this is a real possibility.

Dr Do: We performed a gel stent implantation in the right eye, augmented with mitomycin C (MMC) 0.4 mg/mL subconjunctivally, with the goal of reducing both IOP variability and medication burden so the patient would be less bothered by OSD symptoms. The gel stent is 6 mm in length, has a 45- μ m lumen, and is made out of porcine gelatin.¹⁹ In the gel stent's pivotal trial, 65 patients with refractory glaucoma (IOP uncontrolled on maximally tolerated medical therapy [MTMT] or after failed glaucoma surgery) underwent gel stent implantation via an ab interno approach with subconjunctival MMC 0.2 mg/mL augmentation.¹⁹ At 12 months, 75.4% of patients achieved a $\geq 20\%$ IOP reduction from baseline on the same or fewer medications, with mean IOP reductions of 9.1 mm Hg (35.6%) and mean medication reductions of 51.4%. Common adverse events included IOP elevations ≥ 10 mm Hg from baseline in 21.5% of patients and hypotony in 24.6% of patients. Needling of the bleb was required in 32.3% of patients.

In another study, 149 eyes with uncontrolled glaucoma on MTMT underwent gel stent implantation via the ab interno approach following subconjunctival injection of 0.1 mL of MMC 0.2 mg/mL, either standalone or combined with cataract surgery.²⁰ By 24 months, mean IOP reduction was 29.3%. Complete success (IOP ≤ 12 mm Hg and $\geq 20\%$ IOP reduction) was achieved in 18.2% of eyes; using a less stringent IOP threshold (≤ 15 mm Hg), the success rate was 44.4% at 24 months. Needling was required in 58 eyes (45%).

A third study retrospectively compared the outcomes of standalone gel stent implantation vs those of trabeculectomy in 354 eyes that included in-office interventions, bleb needling, number of postoperative visits, vision loss (> 2 lines), complete visual recovery (return to preoperative best-corrected VA [BCVA]), and incidence of surgically induced astigmatism.²¹ The median follow-up was approximately 19 to 20 months. Postoperative interventions were performed in 51.4% of 185 gel stent eyes and in 62.1% of 169 trabeculectomy eyes (56.7% and 63.9%, respectively, based on survival estimates [log-rank $P = .0004$]).

Table 2. Outcomes Related to the Postoperative Course of Gel Stent Implantation vs Trabeculectomy²¹

QOL Metric	Gel Stent (n = 185)	Trabeculectomy (n = 169)	P Value
In-clinic interventions	51.4% (56.7% based on survival estimates)	62.1% (63.9% based on survival estimates)	.0004 (log rank)
Needle revision with antifibrotic	42.2%	32.5%	.02
Visits within 1 month postoperation (average)	3.94	4.62	< .001 (adjusted for baseline differences)
Visits within 3 months postoperation (average)	5.94	6.70	< .001 (adjusted for baseline differences)
Postoperative vision loss ≥ 2 lines	12.4%	21.9%	.0383
Visual recovery at last follow-up	83.2%	74.0%	.025 (log rank)
> 0.5 D surgically induced astigmatism	22.3%	46.7%	Not significant

Abbreviation: QOL, quality of life.

Bleb needling was performed in 42.2% of gel stent eyes and in 32.5% of trabeculectomy eyes ($P = .02$). Gel stent eyes required fewer postoperative visits ($P < .001$), lost less VA ($P = .0383$), recovered BCVA more often ($P = .025$), and had less surgically induced astigmatism, but this difference did not reach statistical significance (Table 2).²¹ In this study, white ethnicity was associated with a lower bleb failure rate and diabetes with a higher failure rate.

Dr Moster: These outcomes are likely to impact our patients' QOL. Patients' satisfaction with surgery would be expected to be substantially better if they require fewer follow-up procedures and fewer office visits, and experience quicker visual recovery and less vision loss.

Dr Panarelli: One issue I always consider when reading studies is generalizability. How closely do the patients in the study match the patient in my chair? The patients in these studies were inadequately controlled on MTMT,¹⁹⁻²¹ which is very much like the case patient we are discussing here. So, I would expect the results of these studies to be predictive of the outcomes for this patient. If we were to

perform this surgery on patients with less severe or less refractory glaucoma, we might get different results. One key point with the pivotal study is that Grover et al¹⁹ took down the conjunctiva specifically to apply MMC, even though device implantation can be performed via an ab interno approach. Sub-Tenon injection of MMC has been shown to be comparable to application by sponges,²² which makes the ab interno implantation of this device possible without having to take down the conjunctiva.

Dr Moster: This procedure can significantly reduce the medication burden as well. In the pivotal trial, medication use was reduced by half at 12 months.¹⁹ This can improve symptoms of OSD, which in turn likely improves QOL.

Dr Ahmed: Success with this surgery begins with proper surgical technique. It is critically important to place the gel stent properly. With ab interno insertion, we have to make sure the distal tip is not caught up in Tenon capsule, but rests in the subconjunctival space.^{23,24} I test this intraoperatively by gently moving the proximal tip of the implant back and forth a bit. If the distal tip is free, the stent tends to stay where I move it, but if it is caught in Tenon capsule, it will spring back into its starting position. If I suspect engagement with Tenon capsule, I will intraoperatively sweep the subconjunctival space above and below the distal tip with a 30G needle to ensure it is free. I have also made 2 adjustments to MMC use: (1) I inject at the end of the procedure so I can assess the tip placement before hydrating the conjunctiva and Tenon capsule (as would happen if I injected MMC preoperatively); and (2) I have increased the concentration of MMC that I use, from 0.2 to 0.4 mg/mL. These adjustments during the learning curve have reduced our needling rate compared with the rate in the pivotal trial.¹⁹

Dr Panarelli: I place my gel stents under Tenon capsule entirely via an external approach (open conjunctiva). This technique allows me to be certain that the distal end of the gel stent is not obstructed, and I can make microadjustments to ensure the gel stent is ideally positioned. Another benefit to sub-Tenon gel stent placement is that there is a lower incidence of exposure/extrusion of the device (1.5%).¹⁹

Dr Ahmed: From a safety perspective, it makes sense to put the tip under Tenon capsule to minimize the risk of erosion, but with ab interno implantation, this is difficult to do consistently.

Dr Do: Despite our best efforts, bleb failure does still occur in some eyes after gel stent implantation. Risk factors for bleb failure include young age, aphakia, conjunctival inflammation, uveitis, chronic medication use, previously failed glaucoma surgery, and, most importantly and as has been pointed out, if the distal tip is caught in Tenon capsule.²³

Dr Ahmed: I believe one reason young age is a risk factor for failure is that as we get older, we have less Tenon tissue to potentially occlude the distal tip.

Dr Panarelli: Mitomycin C at the time of implantation is crucial to long-term success. Early studies without MMC had very high failure rates,^{24,25} which were reduced once we started using MMC.^{19,26}

Dr Ahmed: Also, needling procedures for bleb fibrosis tend to reestablish the IOP control achieved before bleb failure in eyes with gel stents.²⁷

Dr Do: We have heard Dr Ahmed's MMC routine. How do others use MMC when implanting gel stents?

Dr Panarelli: I inject approximately 0.15 to 0.2 mL of MMC 0.4 mg/mL, which is on the order of 60 to 80 μg total, and inject approximately 10 mm posterior to the limbus.

Dr Moster: I use MMC 0.4 mg/mL as well, and inject a mixture of 0.1 mL of MMC and 0.1 mL of unpreserved lidocaine as far posteriorly as I can.

Dr Do: The patient did well after gel stent implantation of the right eye. Her IOP was 11 mm Hg off all medications 12 months later.

CASE 2: MODERATE GLAUCOMA

From the Files of Julian Garcia Feijoo, MD, PhD

A 49-year-old woman was referred for possible newly diagnosed glaucoma. She had a history of systemic hypotension, with diastolic blood pressure in the range of 35 to 52 mm Hg at night. Her BCVA was 20/20 OU, with a myopic correction (-5 D OD and -4 D OS). Her untreated IOP was 22 to 26 mm Hg OD and 18 to 22 mm Hg OS, with CCT of 504 $\mu\text{m OD}$ and 500 $\mu\text{m OS}$. **Figure 2** shows her optic nerve photographs, RNFL OCT images, and visual fields. She had large optic nerves OU, and the photograph of the right eye revealed a notch in the inferior rim of the optic nerve, with an RNFL bundle defect at 7:00. The OCT images revealed superior and inferior RNFL loss in both eyes, and the visual fields demonstrated superonasal loss consistent with the RNFL defect.

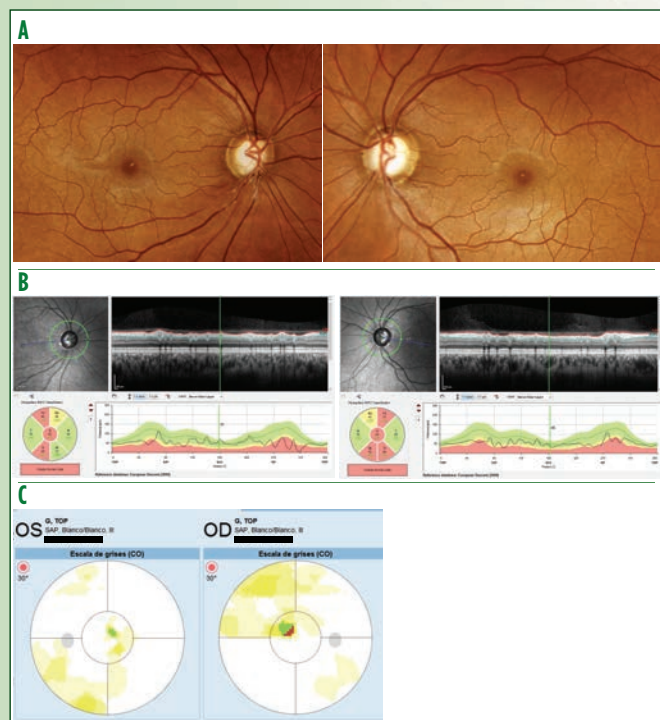


Figure 2. Posterior pole photographs (A), retinal nerve fiber layer optical coherence tomography images (B), and visual fields (C) of the patient presented in Case 2

The patient was diagnosed with primary OAG (POAG) and begun on daily prostaglandin analogue therapy in both eyes, resulting in an initial IOP of 15 to 17 mm Hg OD and 12 to 14 mm Hg OS. Over the next year, however, IOP OD crept up to 20 mm Hg and remained at 20 mm Hg despite the addition of a twice-daily brimonidine/brinzolamide fixed combination; the IOP OS remained stable at 14 mm Hg on prostaglandin analogue monotherapy.

Dr Panarelli: This is a young patient with a fixation-threatening field defect in the right eye. Her thin CCT also suggests that her true IOP may be higher than 20 mm Hg. The RNFL defect on the OCT images is also visible on the fundus photograph, and it is not a small or subtle defect. This is a patient at high risk of glaucoma-related vision loss, and someone in whom I would consider surgery earlier rather than later.

Dr Ahmed: So far there is no evidence of progression. Although her IOP is significantly higher in the right eye than in the left eye, there is a case to be made for accepting this IOP and maintaining the treatment course. In EMGT (Early Manifest Glaucoma Trial), patients with newly diagnosed OAG were assigned to treatment (a 25% IOP reduction by whatever means necessary) or observation.²⁸ Over 5 years, nearly 40% of untreated eyes did not progress. In CNTGS (Collaborative Normal-Tension Glaucoma Study), 65% of 79 eyes with normal-tension glaucoma assigned to observation without treatment remained stable without progression over 5 to 7 years.²⁹ My point is that glaucoma—be it high- or low-IOP OAG—often does not progress, or does so very slowly; so in many of these eyes, it is not unreasonable to observe them without treatment and reserve therapy for those who demonstrate true progression on our watch. In our present case, however, the patient is young and has fixation-threatening field loss. Because of the risk that even modest further progression could affect her central VA, I would treat this patient to a lower target—say, the low teens—rather than leaving her IOP at 20 mm Hg.

Dr Feijoo: Not only do many patients remain stable over time, but the prevalence of fast progressors—those with visual field mean deviation reductions > 1 and < 2 dB per year—is typically 8%, and the prevalence of catastrophic progressors—those losing > 2 dB per year—is approximately 3% or less.^{30,31}

Dr Barton: Significant numbers of patients do remain stable without treatment for 5 or even 7 years. But, in my experience, if observed for 10 or 20 years, most of them will eventually progress. As young as this patient is, she will live with the disease for a long time, and she will likely progress at some point. I agree with Dr Panarelli; I would pursue a lower target IOP now, before she progresses.

Dr Moster: This is a common scenario: a patient who is stable at an IOP that makes us uncomfortable. Our job is to figure out which patients will progress and lower their IOP, and which will not need any further intervention. We distinguish between these 2 groups according to both risk assessment and a careful appraisal of the consequences if we are wrong. Risk assessment includes examination elements, such as IOP level and CCT, and other issues, such as comorbid conditions or lifestyle issues. This patient has systemic hypotension, so she is at risk of poor ocular perfusion at night. Does she have evidence of vasculopathy, eg, Raynaud phenomenon, disc hemorrhages, cold hands or feet? Does she practice yoga with frequent headstands, lift weights, or play a brass or woodwind instrument? These can all raise IOP during the activity.³²⁻³⁴ Any of these might push me to lower her target IOP. We also have to consider the cost of being wrong. If we have a patient with ocular hypertension and full visual fields, the cost of a little progression—enough to convince us we need a lower IOP—is minimal. As will be shown in Case 3, the cost of a little progression could be split fixation, so we might err on the side of being too aggressive rather than not aggressive enough.

Dr Ahmed: A family history of glaucoma would also raise the patient's risk profile significantly. Was there glaucoma in her family?

Dr Feijoo: No. The discussion about waiting or not waiting for progression is at the heart of this case. MIGS has changed how I approach these patients.

Fifty years ago, if the only option was a trabeculectomy, I would have waited for progression before recommending surgery. But now with MIGS, we can offer a safer procedure, so we have a lower threshold for operating. Together, the patient and I decided that a lower IOP was prudent now, before she got worse. We opted for an external subconjunctival MIGS procedure. In Europe, we have the microshunt, which is implanted via an ab externo approach.³⁵ It is 8.5 mm long, with a 70- μ m lumen, and has 2 small fins to anchor it into sclera. It is inserted through a scleral tunnel fashioned by a 25G or 27G needle, with the fins resting in a shallow scleral pocket formed by a specialty blade provided with the implant. In a preliminary study, 23 eyes with uncontrolled IOP despite MTMT underwent either standalone surgery or surgery in combination with cataract extraction.³⁵ MMC 0.4 mg/mL was applied for 3 minutes intraoperatively. Mean IOP reductions at 1, 2, and 3 years postoperatively were 55%, 50%, and 55%, respectively, demonstrating endurance of the procedure's effect over time. Mean IOPs in the low teens (10 to 11 mm Hg) were achieved at 3 years postoperatively, and 82% of 22 eyes had IOP \leq 14 mm Hg. Medication reduction at 3 years was 70%, and 64% of eyes were medication free. Common adverse events included transient hypotony (13%), shallow or flat anterior chambers (13%), and hyphema (9%). Through 3 years of follow-up, only 1 eye developed subconjunctival fibrosis requiring needling.

In a prospective, multicenter study in Europe, 101 patients with mild to severe POAG underwent microshunt implantation with MMC 0.2 mg/mL for 2 minutes.³⁶ At 12 months, mean IOP reduction was 28% (mean IOP was 14.6 mm Hg) (**Figure 3**), and 74% of patients receiving microshunt were medication free. IOP elevation requiring additional medications or SLT occurred in 21% of patients, and keratitis was noted in 9% of patients.

In an additional study, 124 eyes with mild to severe POAG and baseline IOP \geq 18 mm Hg underwent microshunt implantation with MMC 0.2 mg/mL or 0.4 mg/mL.³⁷ Mean IOP reduction at 2 years was 34.8% in the group receiving MMC 0.2 mg/mL and 41.2% in the group receiving MMC 0.4 mg/mL. Medication reductions in the 2 groups were 67% and 90%, respectively. Common adverse events included need for IOP medications or SLT in 33% of the 58 eyes receiving MMC 0.2 mg/mL and in 18% of the 66 eyes receiving MMC 0.4 mg/mL, and hypotony in 12% and 14% of eyes, respectively.

A phase 3 multicenter study comparing the microshunt with trabeculectomy has been conducted but not yet published.³⁸ Both groups received MMC 0.2 mg/mL

for 2 minutes. At 12 months, mean diurnal IOP was reduced from 21.1 to 14.2 mm Hg in the microshunt group and from 21.1 to 11.2 mm Hg in the trabeculectomy group. Medications were reduced by 80% in the microshunt group and by 90% in the trabeculectomy group, and 71.6% and 84.8% of patients, respectively, were medication free at 12 months. Hypotony occurred in 30.6% of microshunt patients and in 51.1% of trabeculectomy patients; suture lysis was required in 52.3% of trabeculectomy patients (and not in any microshunt patients).

This patient underwent surgery with the microshunt with MMC 0.2 mg/mL for 3 minutes. There were no complications and no hypotony. IOP through the first 6 months was 10 to 13 mm Hg on no medications.

Dr Barton: This procedure has replaced trabeculectomy for all but my most severe patients, in whom we must succeed with surgery the first time around. You get a more posterior bleb with the microshunt than with the ab interno gel stent because opening the conjunctiva affords the opportunity to use more MMC than most of us are comfortable with via subconjunctival injection. If you implant the gel stent externally, as Dr Panarelli does, this is not an issue because a wider area of MMC application is also possible. Also, in my experience, there is less peritubular flow with the microshunt than with the gel stent, so I see less hypotony and less need for anterior chamber reformation. I leave a little cohesive viscoelastic in the anterior chamber with the gel stent because it will exit the eye via peritubular flow, but I do not leave any viscoelastic in the eye with the microshunt because there is no peritubular flow, it cannot exit through the shunt, and IOP will therefore spike dramatically.

CASE 3: MODERATE TO ADVANCED GLAUCOMA

From the Files of Marlene R. Moster, MD

A 48-year-old woman was referred for evaluation. She is a physician with a busy internal medicine practice. Seven months previously, she had developed blurred VA in both eyes and was found to have bilateral anterior uveitis. The uveitis workup result was negative. She was managed with topical and oral steroids; the oral steroids were eventually replaced with subcutaneous adalimumab. At the time of referral, she was using prednisolone acetate, 1%, 1 to 2 times daily for several months. Her BCVA was 20/20 OD and 20/40 OS with -8 D contact lenses. Her IOP was 55 mm Hg OD and 51 mm Hg OS despite bimatoprost, brimonidine, dorzolamide/timolol fixed combination, and oral acetazolamide 500 mg twice

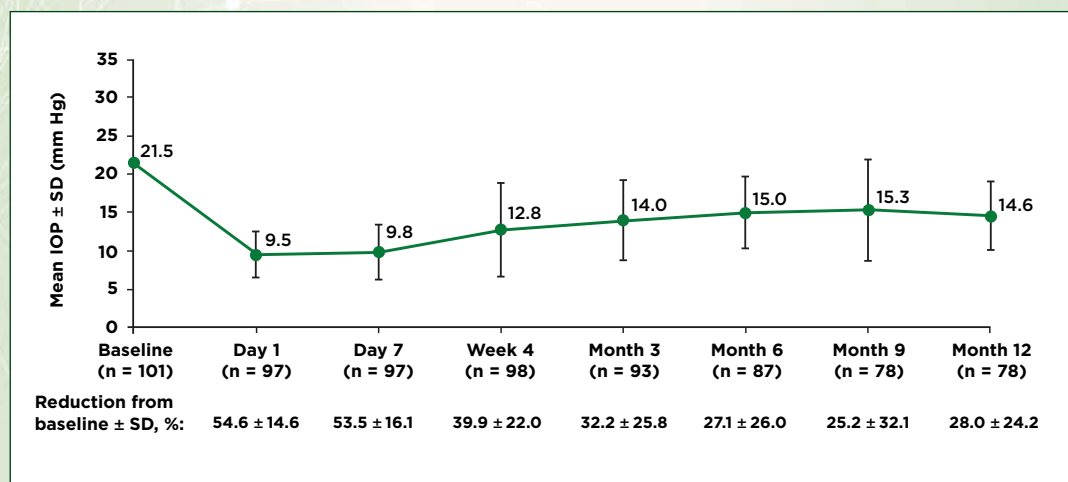


Figure 3. Mean intraocular pressure through 12 months of follow-up after microshunt implantation³⁶

Abbreviations: IOP, intraocular pressure; SD, standard deviation.

daily. Her corneas were clear. There was rare cell and 1+ flare in both eyes. Her angles were open. Her optic nerve examination result, RNFL OCT images, and visual fields were all completely normal in both eyes. She had mild macular edema OS, accounting for her reduced VA.

Dr Do: This patient has severe ocular hypertension secondary to steroid use or uveitis, fortunately with no glaucomatous damage to date. She needs significant IOP reduction, most likely with surgery, before she begins to acquire damage. How important is it to her that she continue using contact lenses?

Dr Mosier: She has never worn glasses and does not want to do anything that would prevent her from wearing contacts. The least invasive intervention would be SLT. Is it likely to help in this case?

Dr Barton: SLT is often used in steroid-related ocular hypertension, albeit with some, but not hard, evidence for efficacy.³⁹⁻⁴¹ It is unlikely to lower her IOP to a safe level from 55 mm Hg while also reducing her medication burden.

Dr Mosier: At the other end of the spectrum is trabeculectomy. She is young and has uveitis, 2 risk factors for failure of trabeculectomy.⁴² Also, contact lenses are a risk factor for bleb-related complications,⁴³ but trabeculectomy is a very effective procedure. A tube-shunt procedure is another option, but the likelihood of attaining a low IOP on no medications with no complications is only 8% to 14% with tube shunts.⁴⁴ I did not favor a subconjunctival MIGS procedure for this patient because of the contact lens issue. What about a TM or Schlemm canal stent?

Dr Panarelli: In the United States, these devices are approved for use only in combination with cataract surgery,^{45,46} and there is no indication for removing the patient's lenses. Second, I try to avoid the implantation of permanent devices in eyes with uveitis whenever possible.

Dr Feijoo: In steroid-induced ocular hypertension or glaucoma, I would consider a trabecular MIGS procedure.

Dr Mosier: My preference in these eyes is a TM procedure. I considered the various trabeculotomy and goniotomy procedures. Of these, we chose to perform

gonioscopy-assisted transluminal trabeculectomy (GATT). It offers 360° trabecular splitting while sparing the conjunctiva for future surgery if needed. GATT can be performed using a suture or an illuminated microcatheter. I prefer the microcatheter because it is easier to visualize the tip throughout the 360° pass. As a standalone procedure, GATT can lower IOP by 30% to 44% and number of medications by 28% to 70% in eyes with POAG.⁴⁷⁻⁵² In secondary glaucomas, even greater efficacy can be achieved.^{47,50} Drawbacks that we discussed include an 8% to 25% incidence of IOP spikes and a 9% to 40% 12-month reoperation rate.⁴⁷⁻⁵⁰ Also, intraoperative bleeding is universal, but typically clears in 1 to 3 weeks. We operated on both eyes 3 weeks apart. Now, 3 years later, her IOP is in the low teens OU using dorzolamide/timolol once daily, and her VA is 20/20 OD and 20/30 OS with her contact lenses.

CASE 4: ADVANCED GLAUCOMA

From the Files of Keith Barton, MD, FRCP, FRCS

A 57-year-old man with a history of LASIK (laser-assisted in situ keratomileusis) in 2006 was diagnosed with POAG in 2009. He was referred in 2014 for glaucoma care. At the time of referral, VA was 20/20 OU without correction (the magnitude of his myopia before LASIK was unknown), IOP was 16 mm Hg OD and 13 mm Hg OS using a preservative-free dorzolamide/timolol fixed combination, and CCT was 464 μ m OD and 454 μ m OS. Over the next 4 years, despite treatment escalation to 4 medications in each eye, the patient had demonstrable visual field progression (Figure 4), with IOP of 15 mm Hg OD and 13 mm Hg OS.

Dr Panarelli: The right eye was approaching split fixation in 2014, and has now progressed to a near-altitudinal defect. The left eye has a paracentral scotoma inferiorly that does not yet encroach on fixation, but it is close. Assuming this has occurred with IOP of 15 mm Hg or less over the past 4 years, a very low target IOP is needed.

Dr Feijoo: SLT is an option, and has been shown to be effective in eyes with low baseline IOP.^{53,54} Given the stage of disease and the current use of 4 medications, however, surgery would be more appropriate.

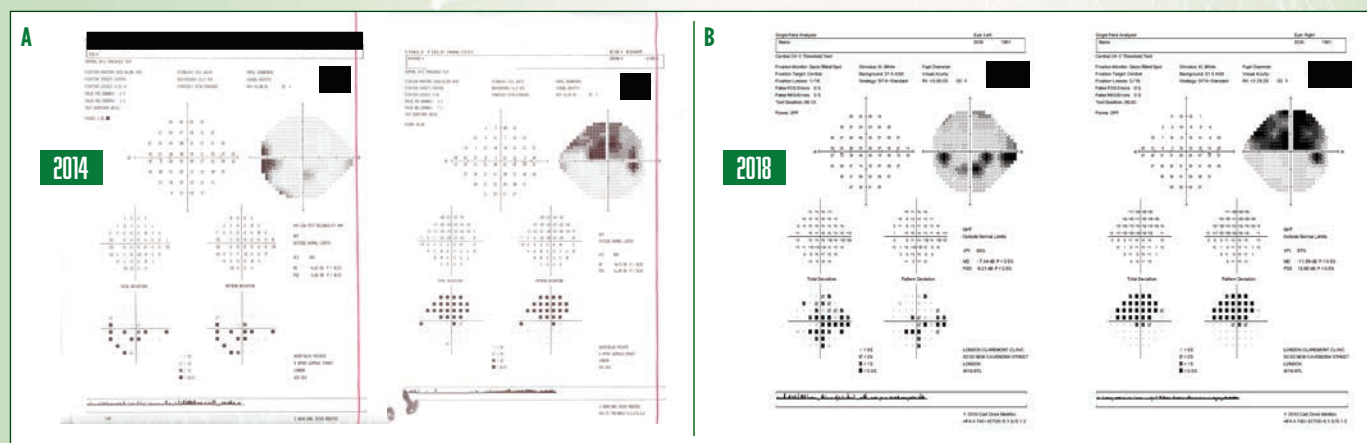


Figure 4. Visual fields in 2014 (A) and 2018 (B) of the patient presented in Case 4

Dr Do: In patients progressing at low IOP, achieving very low—single digit—IOP with surgery effectively halts progression in most cases.⁵⁵ This patient may not really have such low IOP. The history of LASIK and the thin corneas suggest that his true IOP is likely higher than in the low-mid teens.

Dr Panarelli: Regardless of what the “true” IOP is, we would all agree that a significant reduction is needed. The history of myopia is a concern in this case because it is associated with an increased risk of hypotony with trabeculectomy or tube-shunt surgery.⁵⁶ Balancing efficacy and safety is a challenge in cases such as this one.

Dr Barton: We discussed the pros and cons of trabeculectomy vs a subconjunctival MIGS procedure, and the patient opted for the latter on the basis of safety and more rapid visual rehabilitation. We performed an ab externo microshunt implantation using MMC 0.4 mg/mL for 2 minutes in the left eye, and followed that shortly thereafter with a similar procedure in the right eye, but with MMC exposure extended to 3 minutes. One month later, IOP was 10 mm Hg OU on no medications. Over the next 6 months, we added 2 medications back to the right eye to maintain an IOP that was consistently 10 mm Hg or less; the left eye maintained an IOP of less than 10 mm Hg without additional medications.

TAKE-HOME POINTS

- MIGS procedures have expanded the role of surgery in glaucoma management. Advantages over medications include fewer chronic medication-related adverse effects and reduced medication burden. Advantages over filtering surgery include faster recovery time and fewer postoperative procedures. These benefits are determinants of QOL.
- Trabecular meshwork and Schlemm canal MIGS procedures provide modest reductions of IOP and medications, whereas subconjunctival MIGS procedures offer IOP and medication reductions consistent with those associated with trabeculectomy.
- Selection of the right MIGS procedure for a given patient is made on the basis of surgical goals (IOP vs medication reduction, target IOP), glaucoma type and severity, age of the patient, need for rapid visual recovery, and patient-specific needs, such as desire to wear contact lenses.
- Subconjunctival MIGS procedures require augmentation with MMC to prevent fibrosis and the need for needling.

REFERENCES

1. Richter GM, Coleman AL. Minimally invasive glaucoma surgery: current status and future prospects. *Clin Ophthalmol*. 2016;10:189–206.
2. Lavia C, Dallorto L, Maule M, Ceccarelli M, Fea AM. Minimally-invasive glaucoma surgeries (MIGS) for open angle glaucoma: a systematic review and meta-analysis. *PLoS One*. 2017;12(8):e0183142.
3. Quaranta L, Riva I, Gerardi C, Oddone F, Floriani I, Konstas AG. Quality of life in glaucoma: a review of the literature. *Adv Ther*. 2016;33(6):959–981.
4. Janz NK, Wren PA, Lichter PR, et al; CIGTS Study Group. The Collaborative Initial Glaucoma Treatment Study: interim quality of life findings after initial medical or surgical treatment of glaucoma. *Ophthalmology*. 2001;108(11):1954–1965.
5. Lichter PR, Musch DC, Gillespie BW, et al; CIGTS Study Group. Interim clinical outcomes in the Collaborative Initial Glaucoma Treatment Study comparing initial treatment randomized to medications or surgery. *Ophthalmology*. 2001;108(11):1943–1953.
6. Janz NK, Wren PA, Guire KE, Musch DC, Gillespie BW, Lichter PR; Collaborative Initial Glaucoma Treatment Study. Fear of blindness in the Collaborative Initial Glaucoma Treatment Study: patterns and correlates over time. *Ophthalmology*. 2007;114(12):2213–2220.
7. Mabuchi F, Yoshimura K, Kashigawa K, et al. High prevalence of anxiety and depression in patients with primary open-angle glaucoma. *J Glaucoma*. 2008;17(7):552–557.
8. Gazzard G, Konstantakopoulou E, Garway-Heath D, et al; LiGHT Trial Study Group. Selective laser trabeculoplasty versus eye drops for first-line treatment of ocular hypertension and glaucoma (LiGHT): a multicentre randomised controlled trial. *Lancet*. 2019;393(10180):1505–1516.
9. Carreon T, van der Merwe E, Fellman RL, Johnstone M, Bhattacharya SK. Aqueous outflow – a continuum from trabecular meshwork to episcleral veins. *Prog Retin Eye Res*. 2017;57:108–133.
10. Sheheitli H, Tirpack AR, Parrish RK 2nd. Which patients would most likely to benefit: MIGS or MEGS, which one is it? *Asia Pac J Ophthalmol (Phila)*. 2019;8(6):436–440.
11. Labbé A, Terry O, Brasnu E, Van Went C, Baudouin C. Tear film osmolarity in patients treated for glaucoma or ocular hypertension. *Cornea*. 2012;31(9):994–999.
12. Ghosh S, O'Hare F, Lamoureux E, Vajpayee RB, Crowston JG. Prevalence of signs and symptoms of ocular surface disease in individuals treated and not treated with glaucoma medication. *Clin Exp Ophthalmol*. 2012;40(7):675–681.
13. Valente C, Lester M, Corsi E, Rolando M. Symptoms and signs of tear film dysfunction in glaucomatous patients. *J Ocul Pharmacol Ther*. 2011;27(3):281–285.
14. Leung EW, Medeiros FA, Weinreb RN. Prevalence of ocular surface disease in glaucoma patients. *J Glaucoma*. 2008;17(5):350–355.
15. Fechtner RD, Godfrey DG, Budenz D, Stewart JA, Stewart WC, Jasek MC. Prevalence of ocular surface complaints in patients with glaucoma using topical intraocular pressure-lowering medications. *Cornea*. 2010;29(6):618–621.
16. Rossi GC, Pasinetti GM, Scudeller L, Raimondi M, Lanteri S, Bianchi PE. Risk factors to develop ocular surface disease in treated glaucoma or ocular hypertension patients. *Eur J Ophthalmol*. 2013;23(3):296–302.
17. Skaliky SE, Goldberg I, McCluskey P. Ocular surface disease and quality of life in patients with glaucoma. *Am J Ophthalmol*. 2012;153(1):1–9.e2.
18. Baudouin C, Labbé A, Liang H, Pauly A, Brignole-Baudouin F. Preservatives in eyedrops: the good, the bad and the ugly. *Prog Retin Eye Res*. 2010;29(4):312–334.
19. Grover DS, Flynn WJ, Bashford KP, et al. Performance and safety of a new ab interno gelatin stent in refractory glaucoma at 12 months. *Am J Ophthalmol*. 2017;183:25–36.
20. Mansouri K, Bravetti GE, Gillmann K, Rao HL, Ch'ng TW, Mermoud A. Two-year outcomes of XEN gel stent surgery in patients with open-angle glaucoma. *Ophthalmol Glaucoma*. 2019;2(5):309–318.

REFERENCES (CONTINUED)

21. Schlenker MB, Gulamhusein H, Conrad-Hengerer I, et al. Standalone ab interno gelatin stent versus trabeculectomy: postoperative interventions, visual outcomes, and visits. *Ophthalmol Glaucoma*. 2018;1(3):189-196.
22. Pakravan M, Esfandiari H, Yazdani S, et al. Mitomycin C-augmented trabeculectomy: subtenon injection versus soaked sponges: a randomised clinical trial. *Br J Ophthalmol*. 2017;101(9):1275-1280.
23. Vera V, Sheybani A, Lindfield D, Stalmans I, Ahmed IK. Recommendations for the management of elevated intraocular pressure due to bleb fibrosis after XEN gel stent implantation. *Clin Ophthalmol*. 2019;13:685-694.
24. Lenzhof M, Strohmaier C, Sperl P, et al. Effect of the outer stent position on efficacy after minimally invasive transscleral glaucoma gel stent implantation. *Acta Ophthalmol*. 2019;97(8):e1105-e1111.
25. Sheybani A, Dick HB, Ahmed II. Early clinical results of a novel ab interno gel stent for the surgical treatment of open-angle glaucoma. *J Glaucoma*. 2016;25(7):e691-e696.
26. Sheybani A, Lenzhof M, Hohensinn M, Reitsamer H, Ahmed II. Phacoemulsification combined with a new ab interno gel stent to treat open-angle glaucoma: pilot study. *J Cataract Refract Surg*. 2015;41(9):1905-1909.
27. Midha N, Gillmann K, Chaudhary A, Mermoud A, Mansouri K. Efficacy of needling revision after XEN gel stent implantation: a prospective study. *J Glaucoma*. 2020;29(1):11-14.
28. Heijl A, Leske MC, Bengtsson B, Hyman L, Bengtsson B, Hussein M; Early Manifest Glaucoma Trial Group. Reduction of intraocular pressure and glaucoma progression: results from the Early Manifest Glaucoma Trial. *Arch Ophthalmol*. 2002;120(10):1268-1279.
29. Collaborative Normal-Tension Glaucoma Study Group. Comparison of glaucomatous progression between untreated patients with normal-tension glaucoma and patients with therapeutically reduced intraocular pressures. *Am J Ophthalmol*. 1998;126(4):487-497.
30. Chauhan BC, Malik R, Shuba LM, Rafuse PE, Nicoleta MT, Artes PH. Rates of glaucomatous visual field change in a large clinical population. *Invest Ophthalmol Vis Sci*. 2014;55(7):4135-4143.
31. Kirwan JF, Hustler A, Bobat H, Toms L, Crabb DP, McNaught AI. Portsmouth visual field database: an audit of glaucoma progression. *Eye (Lond)*. 2014;28(8):974-979.
32. Jasien JV, Jonas JB, de Moraes CG, Ritch R. Intraocular pressure rise in subjects with and without glaucoma during four common yoga positions. *PLoS One*. 2015;10(12):e0144505.
33. Dickerman RD, Smith GL, Langham-Roof L, McConathy WJ, East JW, Smith AB. Intra-ocular pressure changes during maximal isometric contraction: does this reflect intra-cranial pressure or retinal venous pressure? *Neurol Res*. 1999;21(3):243-246.
34. Schmidtman G, Jahnke S, Seidel EJ, Sickenberger W, Grein HJ. Intraocular pressure fluctuations in professional brass and woodwind musicians during common playing conditions. *Graefes Arch Clin Exp Ophthalmol*. 2011;249(6):895-901.
35. Battle JF, Fantes F, Riss I, et al. Three-year follow-up of a novel aqueous humor MicroShunt. *J Glaucoma*. 2016;25(2):e58-e65.
36. Aptel F, Beckers HJ, Webers CAB, et al. Two-year results of the InnFocus Microshunt glaucoma drainage system in patients with POAG. Poster presented at: 2018 Annual Meeting of the American Academy of Ophthalmology; October 27-30, 2018; Chicago, IL. Poster P0109.
37. Garcia-Feijoo J, Battle J, Riss I, et al. A 2-year pooled analysis of the MicroShunt in patients with primary open-angle glaucoma (POAG): 0.2 versus 0.4 mg/mL mitomycin C (MMC) outcomes. Paper presented at: 2019 World Glaucoma Congress; March 27-30, 2019; Melbourne, Australia. Abstract P-FS-133.
38. Eyewire. Santen announces topline pivotal data for DE-128 (MicroShunt) demonstrating reductions in intraocular pressure and medication use in patients with mild, moderate and severe primary open-angle glaucoma. News release. August 30, 2019. Accessed April 2, 2020. <https://eyewire.news/articles/santen-announces-topline-data-for-de-128-microshunt-demonstrating-reductions-in-iop-and-medication-use-in-patients-with-glaucoma/>
39. Yuki K, Inoue M, Shiba D, Kawamura R, Ishida S, Ohtake Y. Selective laser trabeculoplasty for elevated intraocular pressure following subtenon injection of triamcinolone acetate. *Clin Ophthalmol*. 2010;4:247-249.
40. Rubin B, Taglienti A, Rothman RF, Marcus CH, Serle JB. The effect of selective laser trabeculoplasty on intraocular pressure in patients with intravitreal steroid-induced elevated intraocular pressure. *J Glaucoma*. 2008;17(4):287-292.
41. Pizzimenti JJ, Nickerson MM, Pizzimenti CE, Kasten-Aker AG. Selective laser trabeculoplasty for intraocular pressure elevation after intravitreal triamcinolone acetate injection. *Optom Vis Sci*. 2006;83(7):421-425.
42. Landers J, Martin K, Sarkies N, Bourne R, Watson P. A twenty-year follow-up study of trabeculectomy: risk factors and outcomes. *Ophthalmology*. 2012;119(4):694-702.
43. Bellows AR, McCulley JP. Endophthalmitis in aphakic patients with unplanned filtering blebs wearing contact lenses. *Ophthalmology*. 1981;88:839-843.
44. Budenz DL, Barton K, Gedde SJ, et al; Ahmed Baerveldt Comparison Study Group. Five-year treatment outcomes in the Ahmed Baerveldt comparison study. *Ophthalmology*. 2015;122(2):308-316.
45. US Food and Drug Administration. Hydrus® Microstent - P170034. Updated September 14, 2018. Accessed April 2, 2020. <https://www.fda.gov/MedicalDevices/ProductsandMedicalProcedures/DeviceApprovalsandClearances/Recently-ApprovedDevices/ucm620440.htm>
46. US Food and Drug Administration. iStent inject trabecular micro-bypass system (model G2-M-IS) - P170043. Updated July 13, 2018. Accessed April 2, 2020. <https://www.fda.gov/medical-devices/recently-approved-devices/istent-inject-trabecular-micro-bypass-system-model-g2-m-p170043>
47. Grover DS, Godfrey DG, Smith O, Feuer WJ, Montes de Oca I, Fellman RL. Gonioscopy-assisted transluminal trabeculectomy, ab interno trabeculectomy: technique report and preliminary results. *Ophthalmology*. 2014;121(4):855-861.
48. Grover DS, Godfrey DG, Smith O, Shi W, Feuer WJ, Fellman RL. Outcomes of gonioscopy-assisted transluminal trabeculectomy (GATT) in eyes with prior incisional glaucoma surgery. *J Glaucoma*. 2017;26(1):41-45.
49. Rahmatnejad K, Pruzan NL, Amanullah S, et al. Surgical outcomes of gonioscopy-assisted transluminal trabeculectomy (GATT) in patients with open-angle glaucoma. *J Glaucoma*. 2017;26(12):1137-1143.
50. Grover DS, Smith O, Fellman RL, et al. Gonioscopy-assisted transluminal trabeculectomy: an ab interno circumferential trabeculectomy: 24 months follow-up. *J Glaucoma*. 2018;27(5):393-401.
51. Aktas Z, Ozmen MC, Atalay HT, Ucgul AY. Evaluation of episcleral venous fluid wave during gonioscopy assisted transluminal trabeculectomy in patients with advanced glaucoma. *Eye (Lond)*. 2019;33(4):668-673.
52. Olgun A, Aktas Z, Ucgul AY. XEN gel implant versus gonioscopy-assisted transluminal trabeculectomy for the treatment of open-angle glaucoma. *Int Ophthalmol*. 2020;40(5):1085-1093.
53. Tojo N, Oka M, Miyakoshi A, Ozaki H, Hayashi A. Comparison of fluctuations of intraocular pressure before and after selective laser trabeculoplasty in normal-tension glaucoma patients. *J Glaucoma*. 2014;23(8):e138-e143.
54. El Mallah MK, Walsh MM, Stinnett SS, Asrani SG. Selective laser trabeculoplasty reduces mean IOP and IOP variation in normal tension glaucoma patients. *Clin Ophthalmol*. 2010;4:889-893.
55. Iverson SM, Schultz SK, Shi W, Feuer WJ, Greenfield DS. Effectiveness of single-digit IOP targets on decreasing global and localized visual field progression after filtration surgery in eyes with progressive normal-tension glaucoma. *J Glaucoma*. 2016;25(5):408-414.
56. Fannin LA, Schiffman JC, Budenz DL. Risk factors for hypotony maculopathy. *Ophthalmology*. 2003;110(6):1185-1191.

INSTANT CME CERTIFICATE AVAILABLE WITH ONLINE TESTING AND COURSE EVALUATION: [HTTPS://TINYURL.COM/MIGSPERSPECTIVES](https://tinyurl.com/MIGSPERSPECTIVES)



CME POST TEST QUESTIONS

To obtain *AMA PRA Category 1 Credit™* for this activity, complete the CME Post Test and course evaluation **online** at <https://tinyurl.com/MIGSPerspectives>. (Paper submissions cannot be processed.) Upon successful completion of the post test and evaluation, you will be able to generate an instant certificate of credit.

See detailed instructions at **To Obtain *AMA PRA Category 1 Credit™*** on page 2.

1. In the gel stent pivotal trial, medication use was reduced by _____ at 12 months.
 - a. 25%
 - b. 50%
 - c. 75%
 - d. 100%
2. In the prospective multicenter study conducted in Europe, which of the following best summarizes the outcomes at 12 months in eyes receiving the microshunt?
 - a. IOP was reduced from 21.5 to 14.6 mm Hg, and 70% of patients were medication free
 - b. IOP was reduced from 20.0 to 10.0 mm Hg, and 80% of patients were medication free
 - c. IOP was reduced from 21.5 to 9.0 mm Hg, and 25% of patients were medication free
 - d. IOP was reduced from 19.5 to 16.5 mm Hg, and 50% of patients were medication free
3. According to clinical studies, an IOP reduction of _____ would be reasonable after GATT.
 - a. 10% to 15%
 - b. 30% to 45%
 - c. 50% to 65%
 - d. 75% to 85%
4. QOL is a complex descriptor of individuals' perception of their position in life and is determined in part by:
 - a. Physical health
 - b. Interpersonal relationships
 - c. Living conditions
 - d. All the above
5. According to CIGTS, which of the following describes the fear of blindness due to glaucoma?
 - a. It affects 50% of people at diagnosis and increases with time
 - b. It affects 25% of people at diagnosis and increases with time
 - c. It affects 50% of people at diagnosis and decreases with time
 - d. It affects 25% of people at diagnosis and decreases with time
6. Which outcome was reported in the LiGHT study comparing SLT with medical therapy in newly diagnosed patients with OAG or high-risk ocular hypertension?
 - a. QOL was better in SLT-treated patients because they did not have to use eye drops
 - b. Medications lowered IOP better than did SLT
 - c. 78% of SLT-treated patients were medication free and at target IOP at 3 years
 - d. More medication-treated eyes than SLT-treated eyes progressed over time
7. A 66-year-old female with a history of uveitic glaucoma in the left eye presents with an IOP of 43 mm Hg on maximally tolerated medical therapy. Visual acuity is 20/20 in the affected eye, the optic disc is healthy on OCT, and the VF is within normal limits. The angle appears open on gonioscopy. What is the best treatment option for this patient?
 - a. SLT
 - b. Phacoemulsification/iStent
 - c. Phacoemulsification/Hydrus
 - d. GATT
 - e. Subconjunctival MIGS
 - f. Trabeculectomy
8. A 71-year-old female with pseudoexfoliative glaucoma presents with an IOP of 29 mm Hg in her right eye on 3 topical agents. She is a high myope (-7D OU), but refracts to 20/20. The optic disc has extensive cupping with a dense superior arcuate scotoma on VF. The left eye appears healthy. What is the best treatment option for this patient?
 - a. SLT
 - b. Phacoemulsification/iStent
 - c. Phacoemulsification/Hydrus
 - d. Ab interno canaloplasty
 - e. Subconjunctival MIGS
9. Which of the following is true regarding bleb failure after subconjunctival MIGS procedures?
 - a. MMC does not reduce the risk of bleb failure
 - b. The needling rate in the gel stent pivotal study was higher than that in the microshunt pivotal study
 - c. Needling failed blebs is ineffective at reestablishing IOP control
 - d. Patients with diabetes are less likely to experience bleb failure than those without diabetes