


PREFERRED PRACTICE PATTERN®



Idiopathic Epiretinal Membrane and Vitreomacular Traction

 **AMERICAN ACADEMY®
OF OPHTHALMOLOGY**
The Eye M.D. Association

Secretary for Quality of Care
Stephen D. McLeod, MD

Academy Staff
Nicholas P. Emptage, MAE
Doris Mizuiri
Laurie Bagley, MLS
Flora C. Lum, MD

Medical Editor: Susan Garratt
Design: Socorro Soberano

Approved by: Board of Trustees
September 18, 2015

Copyright © 2015 American Academy of Ophthalmology®
All rights reserved

AMERICAN ACADEMY OF OPHTHALMOLOGY and PREFERRED PRACTICE PATTERN are registered trademarks of the American Academy of Ophthalmology. All other trademarks are the property of their respective owners.

Preferred Practice Pattern® guidelines are developed by the Academy's H. Dunbar Hoskins Jr., M.D. Center for Quality Eye Care without any external financial support. Authors and reviewers of the guidelines are volunteers and do not receive any financial compensation for their contributions to the documents. The guidelines are externally reviewed by experts and stakeholders before publication.



RETINA/VITREOUS PREFERRED PRACTICE PATTERN® DEVELOPMENT PROCESS AND PARTICIPANTS

The **Retina/Vitreous Preferred Practice Pattern® Panel** members wrote the Idiopathic Epiretinal Membrane and Vitreomacular Traction Preferred Practice Pattern® guidelines (“PPP”). The PPP Panel members discussed and reviewed successive drafts of the document, meeting in person once and conducting other review by e-mail discussion, to develop a consensus over the final version of the document.

Retina/Vitreous Preferred Practice Pattern Panel 2014–2015

James C. Folk, MD, American Society of Retina Specialists Representative
 Ron A. Adelman, MD, MPH, MBA, FACS, Retina Society Representative
 Christina J. Flaxel, MD
 Leslie Hyman, PhD, Methodologist
 Jose S. Pulido, MD, MS, MPH, Macula Society Representative
 Timothy W. Olsen, MD, Chair

The **Preferred Practice Patterns Committee** members reviewed and discussed the document during a meeting in April 2015. The document was edited in response to the discussion and comments.

Preferred Practice Patterns Committee 2015

Robert S. Feder, MD, Chair
 Timothy W. Olsen, MD
 Randall J. Olson, MD
 Bruce E. Prum, Jr., MD
 C. Gail Summers, MD
 Ruth D. Williams, MD
 David C. Musch, PhD, MPH, Methodologist

The Idiopathic Epiretinal Membrane and Vitreomacular Traction PPP was then sent for review to additional internal and external groups and individuals in July 2015. All those who returned comments were required to provide disclosure of relevant relationships with industry to have their comments considered (indicated with an asterisk below). Members of the PPP Panel reviewed and discussed these comments and determined revisions to the document.

Academy Reviewers

Board of Trustees and Committee of Secretaries*
 Council*
 General Counsel*
 Basic and Clinical Science Course Section 12
 Subcommittee
 Ophthalmic Technology Assessment Committee
 Retina/Vitreous Panel*
 Practicing Ophthalmologists Advisory Committee
 for Education*

Invited Reviewers

American Society of Retina Specialists*
 Canadian Ophthalmological Society
 Central American Retina and Vitreous Society
 Consumer Reports Health Choices
 European Society of Retina Specialists
 Macula Society*
 National Eye Institute
 National Medical Association
 National Partnership of Women and Families
 Retina Research Foundation
 Retina Society*
 Thai Retina Society
 H. Culver Boldt, MD
 Thomas B. Connor, Jr., MD



FINANCIAL DISCLOSURES

In compliance with the Council of Medical Specialty Societies' Code for Interactions with Companies (available at www.cmss.org/codeforinteractions.aspx), relevant relationships with industry are listed. The Academy has Relationship with Industry Procedures to comply with the Code (available at www.aaopt.org/about-preferred-practice-patterns). A majority (100%) of the members of the Retina/Vitreous Preferred Practice Pattern Panel 2014–2015 had no financial relationship to disclose.

Retina/Vitreous Preferred Practice Pattern Panel 2014–2015

Ron A. Adelman, MD, MPH, MBA, FACS: No financial relationships to disclose

Christina J. Flaxel, MD: No financial relationships to disclose

James C. Folk, MD: No financial relationships to disclose

Leslie Hyman, PhD: No financial relationships to disclose

Timothy W. Olsen, MD: No financial relationships to disclose

Jose S. Pulido, MD, MS, MPH: No financial relationships to disclose

Preferred Practice Patterns Committee 2015

Robert S. Feder, MD: No financial relationships to disclose

David C. Musch, PhD, MPH: No financial relationships to disclose

Timothy W. Olsen, MD: No financial relationships to disclose

Randall J. Olson, MD: No financial relationships to disclose

Bruce E. Prum, Jr., MD: No financial relationships to disclose

C. Gail Summers, MD: No financial relationships to disclose

Ruth D. Williams, MD: Allergan – Consultant/Advisor

Secretary for Quality of Care

Stephen D. McLeod, MD: No financial relationships to disclose

Academy Staff

Laurie Bagley, MLS: No financial relationships to disclose

Nicholas P. Emptage, MAE: No financial relationships to disclose

Susan Garratt: No financial relationships to disclose

Flora C. Lum, MD: No financial relationships to disclose

Doris Mizuiri: No financial relationships to disclose

The disclosures of relevant relationships to industry of other reviewers of the document from January to August 2015 are available online at www.aaopt.org/ppp.



TABLE OF CONTENTS

OBJECTIVES OF PREFERRED PRACTICE PATTERN GUIDELINES	P157
METHODS AND KEY TO RATINGS	P158
HIGHLIGHTED FINDINGS AND RECOMMENDATIONS FOR CARE	P159
INTRODUCTION	P160
Disease Definition	P160
Patient Population	P160
Clinical Objectives	P160
BACKGROUND	P160
Prevalence	P161
Risk Factors	P161
Pathogenesis of Epiretinal Membrane and Vitreomacular Traction	P161
Epiretinal Membrane	P161
Vitreomacular Traction	P162
CARE PROCESS	P162
Patient Outcome Criteria	P162
Symptoms	P162
Diagnosis	P163
Clinical Examination	P163
Diagnostic Tests	P163
Management	P166
Discussion with Patient	P166
Observation without Treatment – Natural History	P166
Surgery	P167
Provider and Setting	P171
Counseling and Referral	P172
Socioeconomic Considerations	P172
APPENDIX 1. QUALITY OF OPHTHALMIC CARE CORE CRITERIA	P173
APPENDIX 2. INTERNATIONAL STATISTICAL CLASSIFICATION OF DISEASES AND RELATED HEALTH PROBLEMS (ICD) CODES	P175
APPENDIX 3. LITERATURE SEARCHES FOR THIS PPP	P175
RELATED ACADEMY MATERIALS	P176
REFERENCES	P176



OBJECTIVES OF PREFERRED PRACTICE PATTERN® GUIDELINES

As a service to its members and the public, the American Academy of Ophthalmology has developed a series of Preferred Practice Pattern® guidelines that **identify characteristics and components of quality eye care**. Appendix 1 describes the core criteria of quality eye care.

The Preferred Practice Pattern® guidelines are based on the best available scientific data as interpreted by panels of knowledgeable health professionals. In some instances, such as when results of carefully conducted clinical trials are available, the data are particularly persuasive and provide clear guidance. In other instances, the panels have to rely on their collective judgment and evaluation of available evidence.

These documents provide guidance for the pattern of practice, not for the care of a particular individual. While they should generally meet the needs of most patients, they cannot possibly best meet the needs of all patients. Adherence to these PPPs will not ensure a successful outcome in every situation. These practice patterns should not be deemed inclusive of all proper methods of care or exclusive of other methods of care reasonably directed at obtaining the best results. It may be necessary to approach different patients' needs in different ways. The physician must make the ultimate judgment about the propriety of the care of a particular patient in light of all of the circumstances presented by that patient. The American Academy of Ophthalmology is available to assist members in resolving ethical dilemmas that arise in the course of ophthalmic practice.

Preferred Practice Pattern® guidelines are not medical standards to be adhered to in all individual situations. The Academy specifically disclaims any and all liability for injury or other damages of any kind, from negligence or otherwise, for any and all claims that may arise out of the use of any recommendations or other information contained herein.

References to certain drugs, instruments, and other products are made for illustrative purposes only and are not intended to constitute an endorsement of such. Such material may include information on applications that are not considered community standard, that reflect indications not included in approved U.S. Food and Drug Administration (FDA) labeling, or that are approved for use only in restricted research settings. The FDA has stated that it is the responsibility of the physician to determine the FDA status of each drug or device he or she wishes to use, and to use them with appropriate patient consent in compliance with applicable law.

Innovation in medicine is essential to ensure the future health of the American public, and the Academy encourages the development of new diagnostic and therapeutic methods that will improve eye care. It is essential to recognize that true medical excellence is achieved only when the patients' needs are the foremost consideration.

All Preferred Practice Pattern® guidelines are reviewed by their parent panel annually or earlier if developments warrant and updated accordingly. To ensure that all PPPs are current, each is valid for 5 years from the "approved by" date unless superseded by a revision. Preferred Practice Pattern guidelines are funded by the Academy without commercial support. Authors and reviewers of PPPs are volunteers and do not receive any financial compensation for their contributions to the documents. The PPPs are externally reviewed by experts and stakeholders, including consumer representatives, before publication. The PPPs are developed in compliance with the Council of Medical Specialty Societies' Code for Interactions with Companies. The Academy has Relationship with Industry Procedures (available at www.aao.org/about-preferred-practice-patterns) to comply with the Code.

Appendix 2 contains the International Statistical Classification of Diseases and Related Health Problems (ICD) codes for the disease entities that this PPP covers. The intended users of the Idiopathic Epiretinal Membrane and Vitreomacular Traction PPP are ophthalmologists.



METHODS AND KEY TO RATINGS

Preferred Practice Pattern® guidelines should be clinically relevant and specific enough to provide useful information to practitioners. Where evidence exists to support a recommendation for care, the recommendation should be given an explicit rating that shows the strength of evidence. To accomplish these aims, methods from the Scottish Intercollegiate Guideline Network¹ (SIGN) and the Grading of Recommendations Assessment, Development and Evaluation² (GRADE) group are used. GRADE is a systematic approach to grading the strength of the total body of evidence that is available to support recommendations on a specific clinical management issue. Organizations that have adopted GRADE include SIGN, the World Health Organization, the Agency for Healthcare Research and Policy, and the American College of Physicians.³

- ◆ All studies used to form a recommendation for care are graded for strength of evidence individually, and that grade is listed with the study citation.
- ◆ To rate individual studies, a scale based on SIGN¹ is used. The definitions and levels of evidence to rate individual studies are as follows:

I++	High-quality meta-analyses, systematic reviews of randomized controlled trials (RCTs), or RCTs with a very low risk of bias
I+	Well-conducted meta-analyses, systematic reviews of RCTs, or RCTs with a low risk of bias
I-	Meta-analyses, systematic reviews of RCTs, or RCTs with a high risk of bias
II++	High-quality systematic reviews of case-control or cohort studies High-quality case-control or cohort studies with a very low risk of confounding or bias and a high probability that the relationship is causal
II+	Well-conducted case-control or cohort studies with a low risk of confounding or bias and a moderate probability that the relationship is causal
II-	Case-control or cohort studies with a high risk of confounding or bias and a significant risk that the relationship is not causal
III	Nonanalytic studies (e.g., case reports, case series)

- ◆ Recommendations for care are formed based on the body of the evidence. The body of evidence quality ratings are defined by GRADE² as follows:

Good quality	Further research is very unlikely to change our confidence in the estimate of effect
Moderate quality	Further research is likely to have an important impact on our confidence in the estimate of effect and may change the estimate
Insufficient quality	Further research is very likely to have an important impact on our confidence in the estimate of effect and is likely to change the estimate Any estimate of effect is very uncertain

- ◆ Key recommendations for care are defined by GRADE² as follows:

Strong recommendation	Used when the desirable effects of an intervention clearly outweigh the undesirable effects or clearly do not
Discretionary recommendation	Used when the trade-offs are less certain—either because of low-quality evidence or because evidence suggests that desirable and undesirable effects are closely balanced

- ◆ The Highlighted Findings and Recommendations for Care section lists points determined by the PPP Panel to be of particular importance to vision and quality of life outcomes.
- ◆ All recommendations for care in this PPP were rated using the system described above. Ratings are embedded throughout the PPP main text in italics.
- ◆ Literature searches to update the PPP were undertaken on October 14, 2014 in the PubMed database. Complete details of the literature searches are available in Appendix 3.



HIGHLIGHTED FINDINGS AND RECOMMENDATIONS FOR CARE

Epiretinal membranes (ERMs) are sheet-like structures that develop on the inner surface of the neurosensory retina. Vitreomacular traction (VMT) occurs when the posterior cortical vitreous partially separates from the retina yet some tractional areas remain adherent to portions of the macula and cause retinal pathology. Epiretinal membranes and VMT often occur together in the same eye. Spectral domain optical coherence tomography (SD-OCT) is a highly sensitive and routine methodology used to diagnose and characterize ERM, VMT, and associated retinal changes.

Increasing age and other retinal pathologies (e.g., posterior vitreous detachment (PVD), uveitis, retinal breaks, retinal vein occlusions, proliferative diabetic retinopathy, and ocular inflammatory diseases) have been identified as consistent risk factors for ERM. The prevalence of ERM appears to vary by ethnicity, but the variations are not consistent across studies.

The majority of ERMs will remain relatively stable and do not require therapy. In patients who have areas of VMT of 1500 μm or less, the incidence of spontaneous release of traction from the macula occurs in approximately 30% to 40% of eyes over a follow-up of 1 to 2 years.

Vitrectomy surgery is often indicated in patients who are affected with a decrease in visual acuity, metamorphopsia, double vision, or difficulty using their eyes together. Vitrectomy surgery for ERM or VMT usually leads to improvement of the metamorphopsia and visual acuity. On average, approximately 80% of patients with ERM or VMT will improve by at least two lines of visual acuity following vitrectomy surgery.

Ocriplasmin is a recombinant proteolytic enzyme that has been approved by the FDA for intravitreal injection for the treatment of symptomatic vitreomacular adhesion (VMA). It works best to release vitreous traction in younger patients (<65 years), eyes without an ERM, eyes with a full-thickness macular hole and associated VMA, phakic eyes, and eyes with a focal VMA of 1500 μm or less.⁴ Side effects of ocriplasmin are described in this PPP.



INTRODUCTION

DISEASE DEFINITION

Epiretinal membranes (ERMs) are sheet-like structures that develop on the inner surface of the neurosensory retina. Vitreomacular adhesion (VMA) is an attachment of the posterior cortical vitreous to the macula. Vitreomacular traction (VMT) occurs when the posterior cortical vitreous partially separates from the retina yet some tractional areas remain adherent to portions of the macula. Thickening, distortion, intraretinal cystoid changes, and even subretinal fluid in the macula can result from the VMT.⁵ The macular changes that result from either ERM or VMT lead to similar symptoms: reduced visual acuity, metamorphopsia, difficulty using both eyes together, and even diplopia.

PATIENT POPULATION

The patient population is predominately adults.

CLINICAL OBJECTIVES

- ◆ Describe the pathogenesis of ERM/VMT
- ◆ Describe symptoms and diagnosis of ERM/VMT
- ◆ Describe the natural history without treatment
- ◆ Propose a treatment strategy
- ◆ Educate the patient about treatment options
- ◆ Optimize visual function and/or relief of symptoms



BACKGROUND

Idiopathic ERMs do not have a clearly identifiable cause. They present as transparent membranes located on the surface of the neurosensory retina and comprise of reactive cellular elements, vitreous structures, and fibrotic components.

Secondary ERMs may occur after retinal breaks, tears, or detachments, or following intraocular surgery, trauma, or retinal laser treatment. An ERM is likely due to reactive wound healing and is associated with a proliferation of either reactive retinal pigment epithelial cells (RPE) and/or retinal glial cells. Epiretinal membranes are also common in eyes with retinal vascular disease (e.g., diabetic retinopathy and venous occlusions) and/or inflammation.

The vitreous is most firmly attached at the vitreous base, the optic nerve head, and the macula.^{6,7} A posterior vitreous detachment (PVD) evolves and progresses over years.⁵ Initially, the posterior vitreous will partially detach yet will remain partially attached within the macular region. Eventually, the vitreous detaches from the macula and finally from the optic nerve head when a more complete PVD occurs. When the vitreous detaches from the nerve head, the patient may see the acute onset of floaters or even flashes or photopsia. Combined, these represent the classic symptoms for the onset of an acute PVD. On fundus examination, a Weiss ring represents the glial remnant from the attachment at the optic nerve on the posterior cortical vitreous and is typically seen on the posterior vitreous face anterior to the optic nerve.

During the evolution of a PVD, vitreous may remain adherent to the macula. Vitreomacular adhesion, the attachment of the posterior cortical vitreous to the neurosensory retina, may represent the normal evolution of a PVD. Vitreomacular traction occurs when the perimacular vitreous continues to separate from the posterior retina yet remains adherent to a region or area near the center of the macula.^{5,7} The pathologic mechanism responsible for such an abnormal adhesion within the macula that leads to VMT is unclear. The combination of attachment at the macula with surrounding vitreous separation creates traction and may lead to thickening, distortion, intraretinal cystoid changes and even subretinal fluid or tractional detachment at the macula.⁵ Epiretinal membranes can also lead to macular traction and similar visual symptoms. Both ERM and VMT may lead to loss in visual acuity, metamorphopsia, difficulty in using both eyes together, and even diplopia.

PREVALENCE

Epiretinal membrane and VMT are relatively common retinal conditions that have variable presentations. Patients may be asymptomatic or report mild, moderate, or severe visual dysfunction. Epiretinal membrane or VMT may have multiple etiologies. Idiopathic ERM is a common condition, estimated to occur in approximately 30 million adults in the United States 43 to 86 years old.⁸ Epiretinal membranes may be bilateral in up to 20% to 35% of cases.⁹⁻¹² The prevalence of ERMs is based on several population-based studies conducted in various ethnic groups worldwide over the past 20 years. Prevalence rates¹³ range from a low of 2.2% and 3.4% in Beijing¹⁴ and in the Handan Eye Study in rural China, respectively,¹¹ to moderate (7% and 8.9%) in two Australian populations^{9,15} to a high of 18.8% and even 28.9% among Latinos in Los Angeles¹⁶ and in a multi-ethnic study conducted in six communities in the United States (Multi-Ethnic Study of Atherosclerosis [MESA]).¹² The presence or absence of ERM in most studies was based on the use of nonmydriatic retinal photography.^{8-10,12,14-18} More recently, at the 20-year follow-up examinations of the Beaver Dam Eye Study population (mean age of 74.1 years), spectral domain optical coherence tomography (SD-OCT) was used and documented a higher prevalence of 34.1%.¹⁹ The same study also documented the prevalence of VMT to be 1% to 2%. The reasons for the differences in prevalence observed across studies are unclear. They are likely due to the sensitivity of the specific testing or imaging modality used, differences in classification of ERM, or differences in the populations (e.g., age, ethnicity).

In most populations studied, cellophane maculopathy, the early asymptomatic form of ERM, occurred more frequently than thicker or more opaque preretinal macular fibrosis (a term used for a more severe form of ERM).^{10-12,16} The prevalence of cellophane maculopathy varied from 1.8% and 2.2% in urban and rural China^{11,14} to as high as 16.3% among Los Angeles Latinos¹⁶ and 25.1% in MESA.¹² Preretinal macular fibrosis prevalence was more consistent across studies, with rates ranging from 0.7% in rural China¹¹ to 3.5% among Asian Indians,¹⁷ 3.8% in MESA,¹² and 3.9% in Melbourne, Australia.¹⁵

RISK FACTORS

Increasing age was consistently identified as a risk factor for ERM in all studies.¹³ Prevalence varies by ethnicity, but patterns are not consistent across studies. For example, in the United States, MESA data suggest that the prevalence of any ERM was highest in persons of Chinese ancestry (39.0%), intermediate in Hispanics (29.3%) and whites (27.5%), and lowest in blacks (26.2%),¹² whereas the data from China suggested that the ERM prevalence rates were much lower (2.2% and 3.4%).^{11,14} Epiretinal membrane occurs more frequently in persons with retinal pathology (e.g., uveitis,²⁰ retinal breaks,²¹ retinal vein occlusions,^{8,12,19} proliferative diabetic retinopathy,^{13,19} and ocular inflammatory diseases) and cataract surgery.^{13,19} It may be associated with impaired visual acuity or visual field loss,^{14,19} particularly for those eyes with more severe ERMs.¹⁶ A number of other more speculative risk factors have been suggested but have not been confirmed. These include gender,¹³ refractive error (myopia and hyperopia),^{13,14} smoking,^{11,15} higher education,¹³ diabetes,¹³ hypercholesterolemia,¹³ narrow retinal arteriolar diameter,¹³ body mass index,¹⁵ and stroke.¹⁵

PATHOGENESIS OF EPIRETINAL MEMBRANE AND VITREOMACULAR TRACTION

Epiretinal Membrane

A longstanding hypothesis was that ERMs develop when a PVD results in microbreaks of the internal limiting membrane (ILM) that, in turn, allow for the migration of retinal glial or possibly RPE cells onto the anterior retinal surface, where they proliferate.^{22,23} The hypothesis was supported when RPE cells, fibrous astrocytes, astrocytes, and fibrocytes were observed in ERMs of eyes that had no apparent retinal breaks, laser or cryopexy, or eye surgery.²⁴ Epiretinal membranes have also been observed in eyes without an obvious PVD.²⁵ Vitreous remnants have been documented on the surface of the retina after a PVD.^{7,26} The presence of a Weiss ring does not always indicate that there has been a complete separation of the posterior hyaloid membrane from the entire posterior retinal surface.²⁷ Vitreous remnants may serve as a scaffold for ERM development.

Laminocytes, vitreous cells from the posterior hyaloid membrane (hyalocytes), have been shown to represent a major cellular component of idiopathic ERMs.²⁸ Hyalocytes, however, are not native to the vitreous but originate from bone-marrow-derived cells and are continuously renewed.²⁹ Extracellular matrix material has also been consistently detected in specimens of ERMs from eye bank eyes or from surgically removed membranes.^{13,24,28} Retinal glial cells, hyalocytes, their transdifferentiation into fibroblasts and myofibroblasts, along with the development of extracellular matrix and fibrosis, together lead to ERM formation.¹³ In summary, these and other studies show that the formation of an ERM includes some combination of vitreous collagen, several different potential cellular origins, differentiation of these cells, and the formation of new collagen and an extracellular matrix material. The constitution of ERMs varies and, therefore, ERMs are likely have a variety of possible origins and causes.

Vitreomacular Traction

As mentioned, the process of a PVD may be a prolonged one and portions of the posterior cortical face may remain adherent to the macula and lead to tractional changes. Investigators have broadly separated VMT, based on OCT, into small and large areas of adherence. A localized vitreomacular attachment of about 500 μm causes elevation, traction, and subsequent intraretinal cystoid spaces in the foveal neurosensory retina. A broad attachment measuring about 1500 μm (approximately one disc diameter) can cause more elevation of the macula, even to the point of a macular retinal detachment, yet this configuration is less likely to have intraretinal cystoid spaces.^{26,30} Of course, there is a continuum of areas of attachment from pinpoint to over 1500 μm in diameter. The vitreous attachment may release spontaneously over time, especially in eyes with more focal areas of adherence.³¹

Epiretinal membranes may evolve between the neurosensory retina and a vitreous attachment.³⁰ Perhaps the ERMs are due to a wound-healing response. They adhere tightly to the ILM, and may play a role in VMT by binding the remaining attachment of the vitreous to the macula.^{30,32,33} Epiretinal membranes often contain native vitreous collagen on histopathology specimens.



CARE PROCESS

PATIENT OUTCOME CRITERIA

Patient outcome criteria include the following:

- ◆ Prevent vision loss and functional impairment
- ◆ Optimize visual function
- ◆ Minimize metamorphopsia and/or diplopia
- ◆ Maintain or improve quality of life

SYMPTOMS

Many people with ERM have stable vision with few symptoms, whereas others are more symptomatic and have progressive loss of visual function. Patients are often especially bothered by metamorphopsia or diplopia and may experience difficulties in reading, driving, or even being able to use their eyes together.³⁴⁻³⁷ Commonly, patients report that they close one eye while reading in order to eliminate the distortion from the affected eye.

Patients with VMT have similar symptoms of impaired visual function and metamorphopsia that may be acute or chronic depending on the severity of the traction and the resulting distortion or detachment of the macula. Frequently, the visual acuity of patients with either VMT or ERM does not change dramatically during short-term follow-up.³⁸⁻⁴⁰

DIAGNOSIS

Clinical Examination

The most common type of ERM appears as a thin, translucent cellophane-like membrane on the surface of the retina.^{13,22} An ERM may not lead to tractional changes, and the underlying neurosensory retina may often appear normal. Epiretinal membranes can contract, however, leading to folds in the retina, distortion of the inner and even the outer macula, traction on retinal vessels, and even displacement of the macula or ectopia. The normal foveal depression is often absent and the macula may develop cystoid spaces, lamellar macular hole, or even a full-thickness hole.

Epiretinal membranes that have a thicker, white, fibrotic appearance that obscures the underlying retina, are more likely to become symptomatic and displace the macula than the thinner, more translucent ERMs.^{13,38}

The macular changes that evolve in VMT are often similar to the changes of the retina that result from an ERM. In VMT, raised edges of adherent vitreous may be seen in a peripapillary distribution around the optic nerve head and is referred to as vitreopapillary traction. This condition can be confused with optic nerve disorders such as papilledema.⁴¹ There is some recent suspicion that vitreopapillary traction might be associated with decreased vision and even ischemic optic neuropathy.⁴² Further studies are required to verify this.

Diagnostic Tests

Optical Coherence Tomography

Spectral domain OCT is a highly sensitive and routine method used to diagnose and characterize VMA (see Figure 1), ERM, VMT (see Figure 2), and the associated retinal changes.^{5,30,31,39,43-46} (III, good quality, strong recommendation) Comparing the OCT images in the abnormal eye with images of a normal eye (see Figure 3) is a very helpful educational tool to help patients better understand their eye problem. An ERM on OCT appears as a hyper-reflective layer on the inner surface of the retina (see Figure 4), usually adherent across the surface of the retina. It frequently attached by pegs emanating from the inner retinal surface with intervening hyporeflexive spaces of ERM separation that gives a corrugated appearance in cross section. Optical coherence tomography commonly demonstrates that the traction from the ERM leads to elevation of the normal foveal depression. The inner retina is typically thrown into folds, with thickening of the macula and associated cystoid spaces in various retinal layers.⁴⁷ Using OCT imaging, lamellar macular holes (see Figure 5) may have variable degrees of inner-retinal tissue loss, often with well-delineated edges that are affected by tractional elements from the ERM.⁴⁸⁻⁵¹

The OCT findings of VMT are similar, except that the posterior hyaloid remains partially attached to the macula and is separated in the perimacular region.^{52,53} Cystoid spaces may be present in the entire macular region in VMT. Presumably, these changes are due to anterior-posterior vitreous traction associated with VMT as opposed to a more tangential traction from an ERM. The extent of the VMT varies from a small focal adhesion to a large, broad adhesion that extends over the entire macula.^{31,54} Both ERM and VMT often occur together; thus, the features are commonly combined.³⁰ In 60 eyes with ERM, the vitreous was noted to be adherent to the macula in 57%.⁵⁵ Similarly, 13/20 eyes (65%) with VMT were noted to also have an ERM.⁵⁶

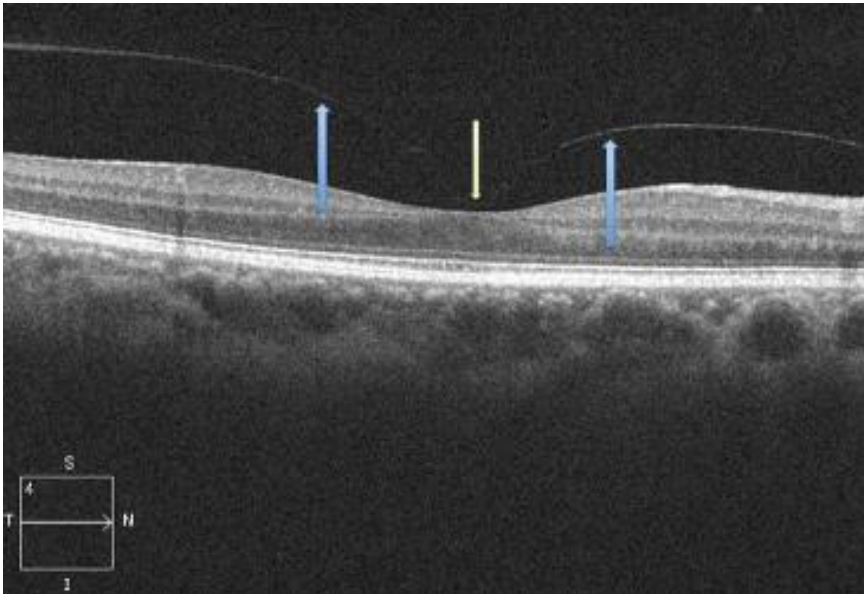


FIGURE 1. Vitreomacular adhesion (VMA). The posterior vitreous face (blue arrows) is separated from the neurosensory retina and a foveal attachment (yellow arrow) or VMA remains. Note that there is no secondary retinal pathology from this attachment site. (Courtesy of Timothy W. Olsen, MD)

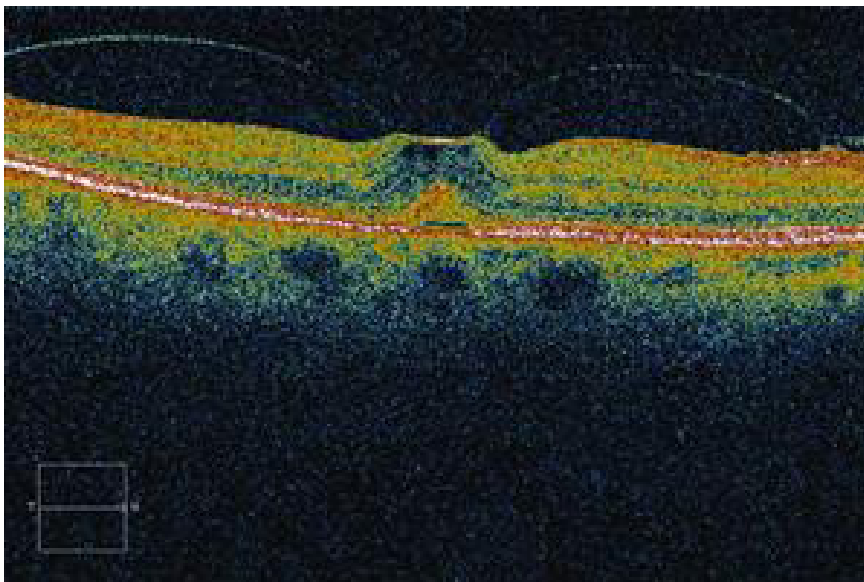


FIGURE 2. Vitreomacular traction. (Copyright © 2015 American Academy of Ophthalmology®)

**Idiopathic ERM and VMT PPP:
Diagnostic Tests**

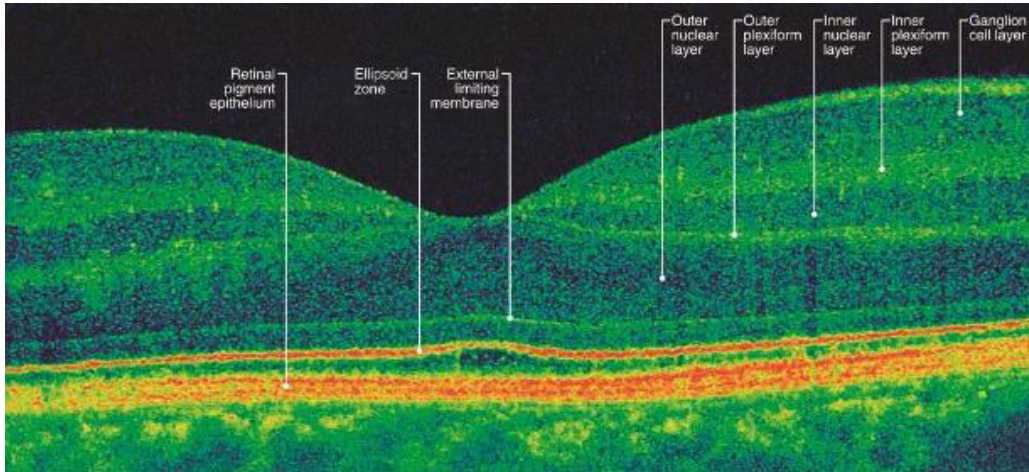


FIGURE 3. Normal retina. The various layers of the retina are easily visualized using spectral domain optical coherence tomography (SD-OCT) imaging through the fovea. (Copyright © 2015 American Academy of Ophthalmology®)

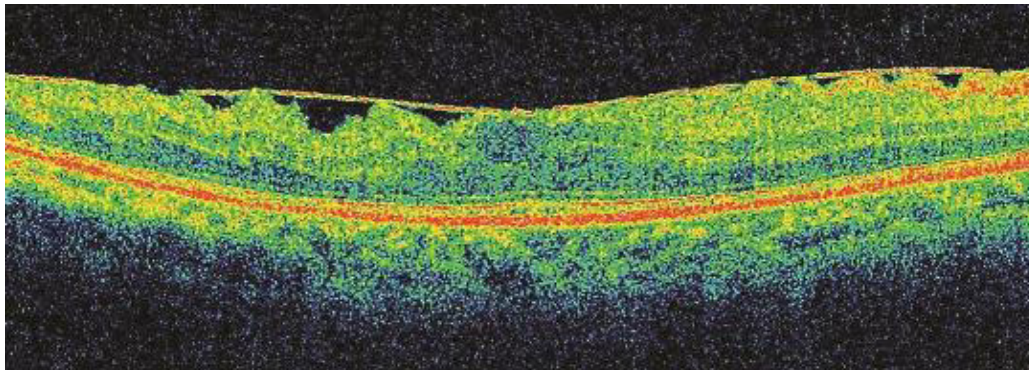


FIGURE 4. Epiretinal membrane. Optical coherence tomography reveals a fine, moderately reflective membrane variably attached to the inner retinal surface. There is associated retinal edema. (Copyright © 2015 American Academy of Ophthalmology®)

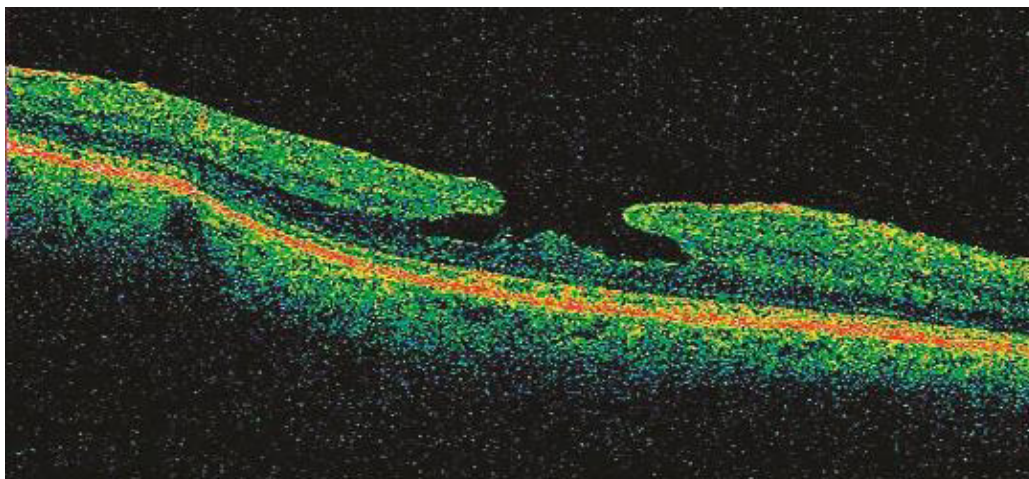


FIGURE 5. Lamellar hole. Optical coherence tomography demonstrates an intraretinal split, with separation of the inner and outer foveal retinal layers and the absence of a full-thickness foveal defect. (Copyright © 2015 American Academy of Ophthalmology®)

Ancillary Tests

A fluorescein angiogram (FA) may be helpful to evaluate ERMs and/or VMT. The FA may be useful to detect other retinal pathologies that can be associated with ERMs, such as a branch retinal vein occlusion, diabetic retinopathy, macular telangiectasia, choroidal neovascularization, and other inflammatory conditions. The FA may be relatively normal in eyes with early ERM. As ERM contraction increases, the macular vessels may become tortuous near the epicenter of traction or straightened around the epicenter of traction. Some retinal vessels, especially the capillaries that are under tractional forces, may demonstrate a leakage pattern, best detected by comparing the early stages of the angiogram with the later stages. The dye may pool in cystoid spaces, especially in the recirculation phase. However, the staining and leakage in the fovea is usually not as uniformly circular as typically seen in pseudophakic cystoid macular edema (which is often accompanied by a hyperfluorescent optic nerve in the later phase of the angiogram). Retinal vascular changes, such as capillary dropout, telangiectasia, collateral vessels, and microaneurysm formation that are more widespread, suggest diabetic retinopathy or central vein occlusion.

MANAGEMENT

Discussion with Patient

Patients should be informed that the majority of ERMs will remain relatively stable and do not require therapy. (*good quality, strong recommendation*) Patients should also be reassured that there is a very successful surgical procedure that could address worsening symptoms or decreasing visual acuity. (*good quality, strong recommendation*) Furthermore, patients should be encouraged to periodically test their central vision monocularly in order to detect changes that may occur over time, such as increasing metamorphopsia and/or development of a small, central scotoma. (*good quality, strong recommendation*) Educating patients about the signs and symptoms of progression and regular monocular Amsler grid testing are both important. Although the visual acuity rarely improves spontaneously, it may worsen. If patients' symptoms worsen, a vitrectomy could be considered. Patients do not typically improve without vitrectomy surgery when the area of VMT is broad (>1500 μm), when there is an accompanying pathologic detachment of the macula, or when the presenting visual acuity is poor.³⁰ (*III, insufficient quality, discretionary recommendation*) Appropriate intervention should be made with careful informed consent and a discussion of the risk-benefit ratio of surgery.

The decision to intervene surgically in patients with ERM/VMT usually depends upon the severity of the patient's symptoms, especially the impact on their activities of daily living. Patients should be asked how much they are bothered and/or impaired by their visual dysfunction; asking about impairments of reading or driving ability is usually very important. The surgery is elective rather than urgent. Earlier surgical intervention for ERM may result in better long-term visual acuity recovery than delayed surgery, yet the time frame of the delay is considered in months rather than in days.⁵⁷ Overall, the recommendation to observe or perform surgery is mainly based on patients' discomfort with their vision, along with their understanding of the associated risks (e.g., cataract).

Observation without Treatment – Natural History

Using fundus photography, a population-based study of 3654 persons showed that only 29% of ERMs progressed over 5 years; 26% regressed and 39% remained approximately the same. Only 20% of eyes with cellophane maculopathy progressed over the same time period.³⁸ A clinic-based study of 34 eyes with ERM showed that the vision did not change over a mean follow-up of 18 months, although two eyes progressed to a full-thickness macular hole.³⁹ A prospective study of 47 eyes with ERM found that the visual acuity and clinical appearance did not change over a mean of 38 months.⁴⁰ A study using SD-OCT images found that the ERM separated from the retina in only 16 of 1091 (1.5%) eyes with a pre-existing PVD but in 21/157 (13.6%) of eyes that did not have an apparent PVD over a mean follow-up of 33 months.⁵⁸ The separation of the ERM led to improved visual acuity in both groups.

Idiopathic ERM and VMT PPP: Surgery

In eyes with VMT of 1500 μm or less, patients often have stable visual acuity, and the incidence of spontaneous release of traction from the macula occurs in approximately 30% to 40% of eyes over a follow-up of 1 to 2 years.^{31,46,53,54,59-61} Usually the release of traction results in an improvement in visual acuity and less severe symptoms. An earlier study, however, found that the visual acuity in 34 of 53 eyes (64%) with VMT decreased two Snellen lines or more over 60 months of follow-up.⁶¹ However, 43/53 (81%) of the eyes reported in this study had cystoid macular spaces detected at baseline. Thus, eyes with cystoid spaces at baseline may represent a cohort of patients with a more guarded prognosis.⁶²

Surgery

Vitreopharmacolysis – Ocriplasmin

Ocriplasmin is a recombinant proteolytic enzyme that was approved by the FDA for intravitreal injection for the treatment of symptomatic VMA (VMT) in 2012.⁶³ The phase 3 ocriplasmin studies did not evaluate the use of ocriplasmin in people specifically with ERM; however, a small number of subjects with ERM and VMT was included in the study. The ERM/VMT in this combination group released in 8.7% subjects receiving the drug compared with 1.5% in the placebo group.⁶³ Given this small and uncertain effect, the patient with an ERM should be informed that it is unlikely that intravitreal ocriplasmin will lead to an effective treatment of the ERM.^{64,65} *(III, good quality, strong recommendation)*

The inclusion criteria in the phase 3 studies of ocriplasmin included all eyes with vitreous traction on the macula, including a subset of eyes with stage 2 macular holes. Overall, 27% of eyes in the ocriplasmin group reached the primary end point (resolution of VMA), compared with 10% of placebo-injected eyes ($P < 0.001$). A subgroup analysis of multiple covariates in the study suggested that resolution of the VMA may be achieved more often in younger patients (< 65 years), eyes without an ERM, eyes with a full-thickness macular hole and associated VMA, phakic eyes, and eyes with a focal VMA of 1500 μm or less.⁴ *(III, good quality, strong recommendation)* The treating physician should discuss the option of treating patients who have VMT with ocriplasmin and compare the treatment with observation, a gas bubble injected into the vitreous, or vitrectomy surgery. *(good quality, strong recommendation)* The discussion should include the relevant risks versus benefits for each of these options. *(good quality, strong recommendation)*

Complications of Ocriplasmin

A review of the adverse effects in the two phase 3 ocriplasmin studies was performed and included 465 eyes treated with ocriplasmin and 187 eyes treated with placebo. During the first week after injection, the ocriplasmin group had about a 10% risk of developing vitreous floaters and photopsia, eye pain, and a combination of either blurred vision or decreased vision. Most of these early symptoms resolved.⁶⁶

The greatest concern about potential toxicity was with acute severe vision loss, electroretinographic abnormalities, dyschromatopsia, and disruption of the photoreceptor layers. A review of the two phase 3 trials reported that only 10 subjects had electroretinography changes and 8 had resolution of the measured dysfunction. Sixteen subjects reported dyschromatopsia and these symptoms resolved in 14. Follow-up was not possible in the other two subjects, since one subject died and the other did not return for further evaluation.⁶⁶ The FDA concluded that the most severe complications, which include dyschromatopsia, electroretinographic changes, and visual field changes, are rare and usually reversible.⁶⁷ Nevertheless, the use of ocriplasmin remains controversial.⁶⁸⁻⁷⁰

An analysis of postmarketing data found a lower rate of adverse events than were reported from the trials.⁷¹ The authors hypothesized that the lower rates in the postmarketing survey may have been due to a reluctance to report adverse events by the treating physician. Clinicians should give careful consideration to all options when considering the use of ocriplasmin.⁷² The use of ocriplasmin for the management of idiopathic macular hole or VMA associated macular hole is presented in the Idiopathic Macular Hole PPP.⁷³

Known side effects of ocriplasmin include:

- ◆ Decreased visual acuity
- ◆ Retinal tears
- ◆ Floaters
- ◆ Blue-yellow vision, dyschromatopsia, or dark vision
- ◆ Photopsias
- ◆ Disruption of the photoreceptor layers
- ◆ Visual field abnormalities
- ◆ Electroretinography changes
- ◆ Weakening of zonular fibers and possible lens subluxation

Gas Injection for Vitreomacular Traction

The injection of intravitreal perfluorocarbon gas has been reported to also induce release of VMT and is the subject of ongoing clinical trials.⁷⁴

Vitreotomy Surgery

Preoperative Discussion for Vitrectomy

The preoperative discussion should include the risks (e.g., cataract, retinal tears, retinal detachment, endophthalmitis) versus the benefits of vitrectomy surgery. Discussion should also cover the following aspects of vitrectomy surgery:

- ◆ The risk of cataract progression following pars plana vitrectomy in phakic eyes is high. Such progression occurs at variable rates, and may be age-dependent.
- ◆ If a cataract is present, cataract surgery may be deferred, recommended prior to vitrectomy surgery, or at the same time as vitrectomy surgery.
- ◆ The type of anesthesia used is typically monitored anesthesia care with local anesthesia. General anesthesia may also be used, especially for anxious or claustrophobic patients.
- ◆ Usually the visual acuity and symptoms of distortion will improve but not necessarily resolve completely.
- ◆ There is a risk of increase or decrease in postoperative intraocular pressure (IOP), especially in patients with glaucoma.
- ◆ The surgeon is also responsible for postoperative care planning and communication of instructions.^{64,65}

Technique

Epiretinal membranes and VMT are often present in the same eye. During surgery, both the VMT and ERM must be removed from the retina surface in order to release the traction on the macula.³⁰ Furthermore, some suggest that removal of the ILM around the macula releases the traction even more completely and reduces the rate of recurrence.⁷²

Surgical removal of ERM/VMT is usually performed using a 23-, 25-, or, more recently, 27-gauge vitrectomy system combined with local, monitored anesthesia care. The core vitreous is removed, and the surgeon induces a detachment of the posterior hyaloid from the optic nerve and macula. Triamcinolone or indocyanine green dye may be used during surgery to highlight ILM and remaining vitreous. The vitreous is commonly separated from the retina using aspiration, an illuminated pick, or forceps. The vitreous is separated from the retinal surface at least anteriorly to the equator, and then removed. Next, the ERM and frequently the ILM are removed with intraocular forceps. Typically, a forceps, microvitrectoretinal blade, diamond-dusted silicone tip, loop, or a needle may be used to elevate an edge of either the ERM, ILM, or both together, which is then peeled and removed with a forceps.⁷¹ Regardless of the technique, the surgical objectives are to free the macula of tractional elements.

Histopathology of the peeled membrane demonstrates variable amounts of ILM. However, often there are patches of ERM and large areas of ILM left on the retinal surface after the initial peel. These remnants can be difficult to visualize. Many surgeons choose to use agents such as indocyanine green dye, brilliant blue dye, or triamcinolone in an off-label fashion to help visualize the ILM and facilitate the peel. The safety of these dyes remains somewhat controversial, yet many surgeons agree that very low concentrations of dyes

**Idiopathic ERM and VMT PPP:
Surgery**

appear safe and may minimize trauma to the retina because the ILM is more easily visualized. Minimizing excessive intraoperative exposure of the macula to light is important. An ERM typically is thicker and has a shaggy or irregular configuration, whereas the ILM is thin, homogenous, and scrolls following removal from the retinal surface.

Once the ERM, ILM, or VMT has been removed, the peripheral vitreous is trimmed and the retina can then be examined for retinal breaks or detachment. A small intraocular air bubble may be used to help seal non-sutured sclerotomies. When a surgeon suspects a full thickness or deep lamellar hole, a more complete fluid-gas exchange using a non-expansile or minimally-expansile concentration of C3F8 or SF6 gas is performed.

Removal of the Internal Limiting Membrane

Table 1 lists seven studies that compare the results of removing the ERM alone with removing both the ERM and ILM. Five of the studies found that peeling the ILM with the ERM led to a lower incidence of recurrent ERM. Two studies showed no difference between peeling or not peeling the ILM. No article reported better results for peeling the ERM alone.

TABLE 1 RESULTS OF NO ILM PEEL VS. ILM PEEL IN ERM AND VMT

Study	No. of Eyes with ERM	Results	Follow-up (mos)	ERM Removal with or without ILM Peel Was Not Favored	Removal of Both ILM and ERM Was Favored
Bovey et al, 2004 ⁷⁵	71	ERMs peeled with no attempt to peel ILM but ERM then studied by histopathology. 55 of 71 eyes had long segments of ILM and 16 did not; the 55, which had ILM, had three lines of vision gain compared to one line in non-ILM group; recurrence rate of ERM was 9% in ILM group and 56% in non-ILM group.	Range 6–59; mean 21.7		•
Kwok et al, 2005 ⁷⁶	42	17 ERMs removed with no ILM peel, and in 25 eyes both ERM and ILM were peeled. Postop VA was logMAR 0.65 in the non-ILM peel group and 0.46 in the peel group. ERM recurred in 3/17 non-ILM peel group and 0/25 of ILM peel group.	Mean 32.8		•
Oh et al, 2013 ⁷⁷	43	23 eyes ERM only; 20 eyes ERM and ILM peeled. ILM peel group was not favored at 3 mos. No difference between two groups at 12 months for VA, central retinal thickness, and mfERG.	12	•	
Park et al, 2003 ⁷⁸	44	24 eyes no ILM peel (Group A); 20 eyes with ILM peel (Group B). Average increase in logMAR was 0.33 in Group A and 0.41 in Group B. Recurrence rate of ERM was 21% in Group A and none in Group B.	At least 3		•
Sandali et al, 2013 ⁷⁹	440	174 eyes no ILM peel; 266 eyes had ILM peel. VA improvement postop was the same between two groups; VA same with dye-assisted ILM peel compared with none. Recurrence rate of ERM was in 8.6% in non-ILM peel group and 2.6% in ILM peel.	At least 12	•	
Shimada et al, 2009 ⁸⁰	246	104 eyes ERM removed only; 142 eyes ERM and ILM removed. Recurrence rate of ERM was 17/104 (16.3%) in ERM-only group and 0/142 eyes in ERM/ILM group. Postop VA did not differ between the groups.	12		•
Koestinger and Bovey, 2005 ⁸¹	75	ERM removed in only 55 eyes and ILM also peeled in 20 eyes using ICG to stain. No difference in VA between groups.	Mean 20	•	

ERM = epiretinal membrane; ILM = internal limiting membrane; mfERG = multifocal electroretinography; Postop = postoperative; VA = visual acuity; VMT = vitreomacular traction

Outcome

Vitrectomy surgery is often indicated in patients who are affected with a decrease in visual acuity, metamorphopsia, double vision, or difficulty using their eyes together. (*II, moderate quality, discretionary recommendation*) Table 2 lists outcomes for ERM and VMT following vitrectomy. On average, the visual acuity improves by two lines or more after surgery. The visual results are highly variable, however; some patients have more visual acuity gain, yet 10% to 20% of them will have unchanged or worse vision following surgery. Although results are variable, scores on the NEI Vision Function Questionnaire-25, on average, improve postoperatively.⁸² Most metamorphopsia improves and may normalize. Thus, even in the absence of visual acuity gain, some patients are pleased with the relief from some or all of the metamorphopsia.

In 50 eyes that had ERM along with cystoid macular changes, lamellar holes, or pseudoholes, the mean visual acuity improved postoperatively by two or more lines and over 70% had a visual acuity of 20/50 or better.⁸³ Of 30 eyes that had a lamellar macular hole secondary to an ERM, the preoperative acuity improved a mean of 3.4 lines after 17 months.⁵⁰

TABLE 2 RESULTS OF VITRECTOMY FOR EPIRETINAL MEMBRANE AND VITREOMACULAR TRACTION

Study	No. of Patients	Diagnosis	Results	Follow-up (mos)
Bouwens et al, 2008 ⁸⁴	107	ERM	Mean postop gain two lines; 83% had less metamorphopsia	Results at 12
Dawson et al, 2014 ⁸⁵	237	ERM	Mean preop 20/120; mean postop 20/40	6
Ghazi-Nouri et al, 2006 ⁸⁶		ERM	No postop gain in mean VA; 40% gained two lines or better; metamorphopsia decreased significantly ($P=0.02$); VFQ-25 improved significantly ($P=0.03$)	4
Koerner and Garweg, 1999 ⁵⁵	60	ERM	73% improved vision; 57% better than preop; 61% 20/50 or better; 57% final VA better than preop	Mean 24.7
Koerner and Garweg, 1999 ⁵⁵	50	VMT	73% improved vision; 60% better vision than preop; 66% 20/50 or better; 60% final VA better than preop	Mean 10
Matsuoka et al, 2012 ⁸⁷	26	ERM	LogMAR VA 0.41 preop, 0.17 at 3 mos, 0.10 at 12 mos; metamorphopsia score (base, 3, and 12 mos was 202, 137, and 108; VFQ-25 scores significantly better at 3 and 12 mos	12
Okamoto et al, 2009 ⁸⁸	28	ERM	LogMAR improved from 0.49 preop to 0.24 postop; 11 (39%) had no change in logMAR; VFQ-25 scores significantly improved	3
Garcia-Fernandez et al, 2013 ⁸⁹	88	ERM	82% had better vision but 10% worse postop	12
Arndt et al, 2007 ³⁵	85	ERM	56% of patients had metamorphopsia preop and 13% postop	12
Wong et al, 2005 ⁹⁰	125	ERM	VA improved by a mean of 0.31 log units or three lines of vision; 16% had unchanged acuity postop	10.3
Witkin et al, 2010 ⁵⁶	20	VMT	Mean VA preop was 20/122 and postop was 20/68	28.6
Jackson et al, 2013 ⁹¹	Meta-analysis 259 eyes from 17 articles	VMT	Mean preop logMAR 0.67; mean postop 0.42; 33% gained two or more lines; 21% of eyes had same or decreased VA postop	Variable; range 6–35

ERM = epiretinal membrane; logMAR = logarithm of the minimum angle of resolution; Postop = postoperative; Preop = preoperative; VA = visual acuity; VFQ-25 = National Eye Institute Visual Function Questionnaire; VMT = vitreomacular traction

Idiopathic ERM and VMT PPP: Provider and Setting

Predictors of Visual Results after Surgery

A study of 43 eyes showed that an intact inner photoreceptor and ellipsoid zone (EZ), also referred to as the inner segment/outer segment junction (IS/OS), was associated preoperatively with better visual acuity after a vitrectomy for ERM using OCT.⁹² A similar study showed that the integrity of the ellipsoid and the cone outer segment tips line was also correlated with better visual acuity.⁹³ The outer retina, the EZ, and the photoreceptors' outer segment length may improve or even normalize after vitrectomy, and each feature is correlated with improved visual acuity.^{92,94} (*III, insufficient quality, discretionary recommendation*)

Complications

The majority of phakic patients develop a progressive nuclear cataract following vitrectomy for ERM.⁹⁵⁻⁹⁹

Retinal breaks and detachments are less common with current vitrectomy surgery, likely due to smaller-gauge instruments, cannulated sclerotomies, and management of the peripheral vitreous, including treatment of retinal breaks and or localized detachments. There may also be less vitreous incarceration leading to retinal traction with smaller-gauge sclerotomies. Retinal breaks have been reported to occur in approximately 1% of cases (8/548) during vitrectomies performed using a 23-gauge cannula system.¹⁰⁰ Another study also found that retinal detachments occur in 1% (2/166) of consecutive 23-gauge vitrectomies.¹⁰¹ A third study reported that in a total of 349 eyes retinal detachments occurred in 1% of eyes undergoing a 23-gauge vitrectomy and in 3.5% of eyes undergoing 20-gauge vitrectomy.¹⁰² Endophthalmitis has been reported in less than 0.05% of vitrectomies.^{103,104}

Follow-up Evaluation after Surgery

Patients who have surgery should be examined on postoperative day 1 and again 1 to 2 weeks following surgery or sooner, depending upon the development of new symptoms or new findings during early postoperative examination. (*good quality, strong recommendation*) The primary reasons for an earlier follow-up visit or more frequent follow-up visits are high or low IOP, a wound leak, pain, worsening vision, or other concern of a retinal complication. Components of the follow-up examination should include the following:

- ◆ Interval history, including new symptoms
- ◆ Measurement of IOP
- ◆ Slit-lamp biomicroscopy of the anterior segment, including the wound sites and central retina, if possible
- ◆ Indirect binocular ophthalmoscopy of the peripheral retina
- ◆ Counseling on the use of postoperative medications
- ◆ Counseling on the signs and symptoms of retinal detachment
- ◆ Precautions about intraocular gas precautions, if it has been used

PROVIDER AND SETTING

Diagnosis and management of ERM, VMT, or VMA requires special expertise, surgical skills, and specialized equipment to detect alterations in the retina in order to select, perform, implement, and monitor appropriate management or treatment. (*good quality, strong recommendation*) Referral to an ophthalmologist who has expertise or experience in managing this condition is recommended. The performance of diagnostic procedures is often delegated to appropriately trained and supervised personnel. However, the interpretation of the results of the diagnostic procedures, as well as the medical and surgical management of ERM, requires the medical training, clinical and surgical judgment, and experience of an ophthalmologist who is also trained in vitreoretinal surgery and disease.

COUNSELING AND REFERRAL

Patients should be informed to notify their ophthalmologist promptly if they have symptoms such as an increase in floaters, a loss of visual field, metamorphopsia, or a decrease in visual acuity.¹⁰⁵⁻¹⁰⁷ *(III, good quality, strong recommendation)* Because vision rehabilitation (as described in the Vision Rehabilitation PPP) helps restore some functional ability, patients with functionally limiting postoperative visual impairment should be referred for vision rehabilitation and social services.¹⁰⁸⁻¹¹⁰ Such a referral is particularly important when there is a residual central or paracentral scotoma. More information on vision rehabilitation, including materials for patients, is available at www.aao.org/smart-sight-low-vision.

SOCIOECONOMIC CONSIDERATIONS

A cost-utility analysis of ERM surgery in the better-seeing eye compared with observation resulted in a mean gain of 0.755 discounted quality-adjusted life years (QALYs) (3% annual rate) per patient treated. This model resulted in \$4680 per QALY for this procedure. When sensitivity analysis was performed, utility values ranged from \$6245 to \$3746/QALY gained, and medical costs varied from \$3510 to \$5850/QALY gained.¹¹¹ Epiretinal membrane surgery in the worse-seeing eye compared with observation resulted in a mean gain of 0.27 discounted QALYs per patient treated. The \$/QALY was \$16,146, with a range of \$12,110 to \$20,183 based on sensitivity analyses. Utility values ranged from \$12,916 to \$21,520/QALY.

A study compared the costs of surgery versus ocriplasmin for the treatment of VMT using data from multiple surgical papers and the MIVI-TRUST study.⁶³ When pars plana vitrectomy was selected as the primary procedure, the overall imputed cost ranged from \$5802 to \$7931. The cost per line was \$2368 to \$3237, the cost per line-year saved was \$163 to \$233, and the cost per QALY was \$5444 to \$7442. If intravitreal injection of ocriplasmin was the primary procedure, the overall imputed cost was \$8767 to \$10,977. The cost per line ranged from \$3549 to \$4456, the cost per line-year saved was \$245 to \$307, and the cost per QALY was between \$8159 and \$10,244. If intravitreal saline injection was used as a primary procedure, the overall imputed cost was \$5828 to \$8098. The cost per line was \$2374 to \$3299, the cost per line-year saved was \$164 to \$227, and the cost per QALY was \$5458 to \$7583. The conclusion was that vitrectomy surgery was more cost-effective than ocriplasmin for the primary treatment of VMT.¹¹² Overall, the results of these calculations suggest that ERM surgery is a very cost-effective procedure when compared with other interventions across medical subspecialties.



APPENDIX 1. QUALITY OF OPHTHALMIC CARE CORE CRITERIA

*Providing quality care
is the physician's foremost ethical obligation, and is
the basis of public trust in physicians.*

AMA Board of Trustees, 1986

Quality ophthalmic care is provided in a manner and with the skill that is consistent with the best interests of the patient. The discussion that follows characterizes the core elements of such care.

The ophthalmologist is first and foremost a physician. As such, the ophthalmologist demonstrates compassion and concern for the individual, and utilizes the science and art of medicine to help alleviate patient fear and suffering. The ophthalmologist strives to develop and maintain clinical skills at the highest feasible level, consistent with the needs of patients, through training and continuing education. The ophthalmologist evaluates those skills and medical knowledge in relation to the needs of the patient and responds accordingly. The ophthalmologist also ensures that needy patients receive necessary care directly or through referral to appropriate persons and facilities that will provide such care, and he or she supports activities that promote health and prevent disease and disability.

The ophthalmologist recognizes that disease places patients in a disadvantaged, dependent state. The ophthalmologist respects the dignity and integrity of his or her patients, and does not exploit their vulnerability.

Quality ophthalmic care has the following optimal attributes, among others.

- ◆ The essence of quality care is a meaningful partnership relationship between patient and physician. The ophthalmologist strives to communicate effectively with his or her patients, listening carefully to their needs and concerns. In turn, the ophthalmologist educates his or her patients about the nature and prognosis of their condition and about proper and appropriate therapeutic modalities. This is to ensure their meaningful participation (appropriate to their unique physical, intellectual and emotional state) in decisions affecting their management and care, to improve their motivation and compliance with the agreed plan of treatment, and to help alleviate their fears and concerns.
- ◆ The ophthalmologist uses his or her best judgment in choosing and timing appropriate diagnostic and therapeutic modalities as well as the frequency of evaluation and follow-up, with due regard to the urgency and nature of the patient's condition and unique needs and desires.
- ◆ The ophthalmologist carries out only those procedures for which he or she is adequately trained, experienced and competent, or, when necessary, is assisted by someone who is, depending on the urgency of the problem and availability and accessibility of alternative providers.
- ◆ Patients are assured access to, and continuity of, needed and appropriate ophthalmic care, which can be described as follows.
 - ◆ The ophthalmologist treats patients with due regard to timeliness, appropriateness, and his or her own ability to provide such care.
 - ◆ The operating ophthalmologist makes adequate provision for appropriate pre- and postoperative patient care.
 - ◆ When the ophthalmologist is unavailable for his or her patient, he or she provides appropriate alternate ophthalmic care, with adequate mechanisms for informing patients of the existence of such care and procedures for obtaining it.
 - ◆ The ophthalmologist refers patients to other ophthalmologists and eye care providers based on the timeliness and appropriateness of such referral, the patient's needs, the competence and qualifications of the person to whom the referral is made, and access and availability.

- ◆ The ophthalmologist seeks appropriate consultation with due regard to the nature of the ocular or other medical or surgical problem. Consultants are suggested for their skill, competence, and accessibility. They receive as complete and accurate an accounting of the problem as necessary to provide efficient and effective advice or intervention, and in turn respond in an adequate and timely manner.
- ◆ The ophthalmologist maintains complete and accurate medical records.
- ◆ On appropriate request, the ophthalmologist provides a full and accurate rendering of the patient's records in his or her possession.
- ◆ The ophthalmologist reviews the results of consultations and laboratory tests in a timely and effective manner and takes appropriate actions.
- ◆ The ophthalmologist and those who assist in providing care identify themselves and their profession.
- ◆ For patients whose conditions fail to respond to treatment and for whom further treatment is unavailable, the ophthalmologist provides proper professional support, counseling, rehabilitative and social services, and referral as appropriate and accessible.
- ◆ Prior to therapeutic or invasive diagnostic procedures, the ophthalmologist becomes appropriately conversant with the patient's condition by collecting pertinent historical information and performing relevant preoperative examinations. Additionally, he or she enables the patient to reach a fully informed decision by providing an accurate and truthful explanation of the diagnosis; the nature, purpose, risks, benefits, and probability of success of the proposed treatment and of alternative treatment; and the risks and benefits of no treatment.
- ◆ The ophthalmologist adopts new technology (e.g., drugs, devices, surgical techniques) in judicious fashion, appropriate to the cost and potential benefit relative to existing alternatives and to its demonstrated safety and efficacy.
- ◆ The ophthalmologist enhances the quality of care he or she provides by periodically reviewing and assessing his or her personal performance in relation to established standards, and by revising or altering his or her practices and techniques appropriately.
- ◆ The ophthalmologist improves ophthalmic care by communicating to colleagues, through appropriate professional channels, knowledge gained through clinical research and practice. This includes alerting colleagues of instances of unusual or unexpected rates of complications and problems related to new drugs, devices or procedures.
- ◆ The ophthalmologist provides care in suitably staffed and equipped facilities adequate to deal with potential ocular and systemic complications requiring immediate attention.
- ◆ The ophthalmologist also provides ophthalmic care in a manner that is cost effective without unacceptably compromising accepted standards of quality.

Reviewed by: Council
Approved by: Board of Trustees
October 12, 1988

2nd Printing: January 1991

3rd Printing: August 2001

4th Printing: July 2005



APPENDIX 2. INTERNATIONAL STATISTICAL CLASSIFICATION OF DISEASES AND RELATED HEALTH PROBLEMS (ICD) CODES

Epiretinal membrane and vitreomacular traction, which include entities with the following ICD-9 and ICD-10 classifications:

	ICD-9 CM	ICD-10 CM
Epiretinal membrane	362.56	H35.371
		H35.372
		H35.373
Vitreomacular traction, adhesion	379.27	H43.821
		H43.822
		H43.823

ICD = International Classification of Diseases; CM = Clinical Modification used in the United States

Additional information for ICD-10 codes:

- For bilateral sites, the final character of the codes in the ICD-10 CM indicates laterality. If no bilateral code is provided and the condition is bilateral, separate codes for both the left and right side should be assigned. Unspecified codes should be used only when there is no other code option available.
- When the diagnosis code specifies laterality, regardless of which digit it is found in (i.e., 4th digit, 5th digit, or 6th digit):
 - Right is always 1
 - Left is always 2
 - Bilateral is always 3



APPENDIX 3. LITERATURE SEARCHES FOR THIS PPP

Literature searches of the PubMed database were conducted on October 14, 2014; the search strategies were as follows. Specific limited update searches were conducted after October 2014.

(epiretinal membrane/pathology[majr] OR epiretinal membrane/physiology[majr] OR epiretinal membrane/physiopathology[majr]). Limits: English, Publication Date from 2005/01/01, Humans. Retrieved 124 citations.

(epiretinal membrane/surgery[mh] OR epiretinal membrane/therapy[mh] OR epiretinal membrane/drug therapy[mh]). Limits: English, Publication Date from 2005/01/01, Humans. Retrieved 451 citations.

epiretinal membrane/diagnosis[MeSH Major Topic]. Limits: English, Publication Date from 2005/01/01, Humans. Retrieved 131 citations.



RELATED ACADEMY MATERIALS

Basic and Clinical Science Course

Retina and Vitreous (Section 12, 2015–2016)

Patient Education

Vitrectomy Surgery Brochure (2014)

Retina Patient Education Video Collection (2014)

Preferred Practice Pattern® Guidelines – Free download available at www.aao.org/ppp.

Comprehensive Adult Medical Eye Evaluation (2015)

To order any of these products, except for the free materials, please contact the Academy's Customer Service at 866.561.8558 (U.S. only) or 415.561.8540 or www.aao.org/store.



REFERENCES

1. Scottish Intercollegiate Guidelines Network. Annex B: key to evidence statements and grades of recommendations. In: SIGN 50: A Guideline Developer's Handbook. 2008 edition, revised 2011. Edinburgh, Scotland: Scottish Intercollegiate Guidelines Network. Available at: www.sign.ac.uk/guidelines/fulltext/50/index.html. Accessed June 26, 2015.
2. Guyatt GH, Oxman AD, Vist GE, et al. GRADE: an emerging consensus on rating quality of evidence and strength of recommendations. *BMJ* 2008;336:924-6.
3. GRADE Working Group. Organizations that have endorsed or that are using GRADE. Available at: www.gradeworkinggroup.org/society/index.htm. Accessed January 9, 2015.
4. Haller JA, Stalmans P, Benz MS, et al. Efficacy of intravitreal ocriplasmin for treatment of vitreomacular adhesion: subgroup analyses from two randomized trials. *Ophthalmology* 2015;122:117-22.
5. Johnson MW. Perifoveal vitreous detachment and its macular complications. *Trans Am Ophthalmol Soc* 2005;103:537-67.
6. Sebag J. Anatomy and pathology of the vitreo-retinal interface. *Eye (Lond)* 1992;6 (Pt 6):541-52.
7. Sebag J. Anomalous posterior vitreous detachment: a unifying concept in vitreo-retinal disease. *Graefes Arch Clin Exp Ophthalmol* 2004;242:690-8.
8. Klein R, Klein BE, Wang Q, Moss SE. The epidemiology of epiretinal membranes. *Trans Am Ophthalmol Soc* 1994;92:403-25; discussion 25-30.
9. Mitchell P, Smith W, Chey T, et al. Prevalence and associations of epiretinal membranes. The Blue Mountains Eye Study, Australia. *Ophthalmology* 1997;104:1033-40.
10. McCarty DJ, Mukesh BN, Chikani V, et al. Prevalence and associations of epiretinal membranes in the visual impairment project. *Am J Ophthalmol* 2005;140:288-94.
11. Duan XR, Liang YB, Friedman DS, et al. Prevalence and associations of epiretinal membranes in a rural Chinese adult population: the Handan Eye Study. *Invest Ophthalmol Vis Sci* 2009;50:2018-23.
12. Ng CH, Cheung N, Wang JJ, et al. Prevalence and risk factors for epiretinal membranes in a multi-ethnic United States population. *Ophthalmology* 2011;118:694-9.
13. Bu SC, Kuijer R, Li XR, et al. Idiopathic epiretinal membrane. *Retina* 2014;34:2317-35.
14. You Q, Xu L, Jonas JB. Prevalence and associations of epiretinal membranes in adult Chinese: the Beijing eye study. *Eye (Lond)* 2008;22:874-9.
15. Aung KZ, Makeyeva G, Adams MK, et al. The prevalence and risk factors of epiretinal membranes: the Melbourne Collaborative Cohort Study. *Retina* 2013;33:1026-34.

**Idiopathic ERM and VMT PPP:
References**

16. Fraser-Bell S, Ying-Lai M, Klein R, Varma R, Los Angeles Latino Eye Study. Prevalence and associations of epiretinal membranes in Latinos: the Los Angeles Latino Eye Study. *Invest Ophthalmol Vis Sci* 2004;45:1732-6.
17. Koh V, Cheung CY, Wong WL, et al. Prevalence and risk factors of epiretinal membrane in Asian Indians. *Invest Ophthalmol Vis Sci* 2012;53:1018-22.
18. Kawasaki R, Wang JJ, Mitchell P, et al. Racial difference in the prevalence of epiretinal membrane between Caucasians and Asians. *Br J Ophthalmol* 2008;92:1320-4.
19. Meuer SM, Myers CE, Klein BE, et al. The epidemiology of vitreoretinal interface abnormalities as detected by spectral-domain optical coherence tomography: The Beaver Dam Eye Study. *Ophthalmology* 2015;122:787-95.
20. Nicholson BP, Zhou M, Rostamizadeh M, et al. Epidemiology of epiretinal membrane in a large cohort of patients with uveitis. *Ophthalmology* 2014;121:2393-8.
21. Cheng L, Freeman WR, Ozerdem U, et al, Vitrectomy for Macular Hole Study Group. Prevalence, correlates, and natural history of epiretinal membranes surrounding idiopathic macular holes. *Ophthalmology* 2000;107:853-9.
22. Wise GN. Clinical features of idiopathic preretinal macular fibrosis. Schoenberg Lecture. *Am J Ophthalmol* 1975;79:349-7.
23. Foos RY. Vitreoretinal juncture; epiretinal membranes and vitreous. *Invest Ophthalmol Vis Sci* 1977;16:416-22.
24. Smiddy WE, Michels RG, Glaser BM, deBustros S. Vitrectomy for macular traction caused by incomplete vitreous separation. *Arch Ophthalmol* 1988;106:624-8.
25. Heilskov TW, Massicotte SJ, Folk JC. Epiretinal macular membranes in eyes with attached posterior cortical vitreous. *Retina* 1996;16:279-84.
26. Kishi S, Demaria C, Shimizu K. Vitreous cortex remnants at the fovea after spontaneous vitreous detachment. *Int Ophthalmol* 1986;9:253-60.
27. Snead MP, Snead DR, James S, Richards AJ. Clinicopathological changes at the vitreoretinal junction: posterior vitreous detachment. *Eye (Lond)* 2008;22:1257-62.
28. Snead DR, James S, Snead MP. Pathological changes in the vitreoretinal junction 1: epiretinal membrane formation. *Eye (Lond)* 2008;22:1310-7.
29. Qiao H, Hisatomi T, Sonoda KH, et al. The characterisation of hyalocytes: the origin, phenotype, and turnover. *Br J Ophthalmol* 2005;89:513-7.
30. Spaide RF. Vitreomacular traction syndrome. *Retina* 2012;32 (suppl):S187-90; discussion S190-3.
31. Theodossiadis GP, Grigoropoulos VG, Theodoropoulou S, et al. Spontaneous resolution of vitreomacular traction demonstrated by spectral-domain optical coherence tomography. *Am J Ophthalmol* 2014;157:842-51.
32. Shinoda K, Hirakata A, Hida T, et al. Ultrastructural and immunohistochemical findings in five patients with vitreomacular traction syndrome. *Retina* 2000;20:289-93.
33. Gandorfer A, Rohleder M, Kampik A. Epiretinal pathology of vitreomacular traction syndrome. *Br J Ophthalmol* 2002;86:902-9.
34. Arimura E, Matsumoto C, Okuyama S, et al. Retinal contraction and metamorphopsia scores in eyes with idiopathic epiretinal membrane. *Invest Ophthalmol Vis Sci* 2005;46:2961-6.
35. Arndt C, Rebollo O, Seguinat S, et al. Quantification of metamorphopsia in patients with epiretinal membranes before and after surgery. *Graefes Arch Clin Exp Ophthalmol* 2007;245:1123-9.
36. Watanabe A, Arimoto S, Nishi O. Correlation between metamorphopsia and epiretinal membrane optical coherence tomography findings. *Ophthalmology* 2009;116:1788-93.
37. Kim JS, Chhablani J, Chan CK, et al. Retinal adherence and fibrillary surface changes correlate with surgical difficulty of epiretinal membrane removal. *Am J Ophthalmol* 2012;153:692-7.
38. Fraser-Bell S, Guzowski M, Rohtchina E, et al. Five-year cumulative incidence and progression of epiretinal membranes: the Blue Mountains Eye Study. *Ophthalmology* 2003;110:34-40.
39. Bottoni F, Deiro AP, Giani A, et al. The natural history of lamellar macular holes: a spectral domain optical coherence tomography study. *Graefes Arch Clin Exp Ophthalmol* 2013;251:467-75.
40. Wiznia RA. Natural history of idiopathic preretinal macular fibrosis. *Ann Ophthalmol* 1982;14:876-8.
41. Kim YW, Jeoung JW, Yu HG. Vitreopapillary traction in eyes with idiopathic epiretinal membrane: a spectral-domain optical coherence tomography study. *Ophthalmology* 2014;121:1976-82.

42. Parsa CF, Hoyt WF. Nonarteritic anterior ischemic optic neuropathy (NAION): a misnomer. Rearranging pieces of a puzzle to reveal a nonischemic papillopathy caused by vitreous separation. *Ophthalmology* 2015;122:439-42.
43. Do DV, Cho M, Nguyen QD, et al. Impact of optical coherence tomography on surgical decision making for epiretinal membranes and vitreomacular traction. *Retina* 2007;27:552-6.
44. Konidaris V, Androudi S, Alexandridis A, et al. Optical coherence tomography-guided classification of epiretinal membranes. *Int Ophthalmol* 2015;35:495-501.
45. Watanabe K, Tsunoda K, Mizuno Y, et al. Outer retinal morphology and visual function in patients with idiopathic epiretinal membrane. *JAMA Ophthalmol* 2013;131:172-7.
46. Theodosiadis GP, Chatziralli IP, Sergentanis TN, et al. Evolution of vitreomacular adhesion to acute vitreofoveal separation with special emphasis on a traction-induced foveal pathology: a prospective study of spectral-domain optical coherence tomography. *Graefes Arch Clin Exp Ophthalmol* 2015;253:1425-35.
47. Inoue M, Morita S, Watanabe Y, et al. Inner segment/outer segment junction assessed by spectral-domain optical coherence tomography in patients with idiopathic epiretinal membrane. *Am J Ophthalmol* 2010;150:834-9.
48. Gaudric A, Aloulou Y, Tadayoni R, Massin P. Macular pseudoholes with lamellar cleavage of their edge remain pseudoholes. *Am J Ophthalmol* 2013;155:733-42, 42 e1-4.
49. Kinoshita T, Kovacs KD, Wagley S, Arroyo JG. Morphologic differences in epiretinal membranes on ocular coherence tomography as a predictive factor for surgical outcome. *Retina* 2011;31:1692-8.
50. Sun JP, Chen SN, Chuang CC, et al. Surgical treatment of lamellar macular hole secondary to epiretinal membrane. *Graefes Arch Clin Exp Ophthalmol* 2013;251:2681-8.
51. Casparis H, Bovey EH. Surgical treatment of lamellar macular hole associated with epimacular membrane. *Retina* 2011;31:1783-90.
52. Bottos J, Elizalde J, Rodrigues EB, et al. Classifications of vitreomacular traction syndrome: diameter vs morphology. *Eye (Lond)* 2014;28:1107-12.
53. Codenotti M, Iuliano L, Fogliato G, et al. A novel spectral-domain optical coherence tomography model to estimate changes in vitreomacular traction syndrome. *Graefes Arch Clin Exp Ophthalmol* 2014;252:1729-35.
54. Odrobina D, Michalewska Z, Michalewski J, et al. Long-term evaluation of vitreomacular traction disorder in spectral-domain optical coherence tomography. *Retina* 2011;31:324-31.
55. Koerner F, Garweg J. Vitrectomy for macular pucker and vitreomacular traction syndrome. *Doc Ophthalmol* 1999;97:449-58.
56. Witkin AJ, Patron ME, Castro LC, et al. Anatomic and visual outcomes of vitrectomy for vitreomacular traction syndrome. *Ophthalmic Surg Lasers Imaging* 2010;41:425-31.
57. Rahman R, Stephenson J. Early surgery for epiretinal membrane preserves more vision for patients. *Eye (Lond)* 2014;28:410-4.
58. Yang HS, Hong JW, Kim YJ, et al. Characteristics of spontaneous idiopathic epiretinal membrane separation in spectral domain optical coherence tomography. *Retina* 2014;34:2079-87.
59. John VJ, Flynn HW Jr, Smiddy WE, et al. Clinical course of vitreomacular adhesion managed by initial observation. *Retina* 2014;34:442-6.
60. Dimopoulos S, Bartz-Schmidt KU, Gelissen F, et al. Rate and timing of spontaneous resolution in a vitreomacular traction group: Should the role of watchful waiting be re-evaluated as an alternative to Ocriplasmin therapy? *Br J Ophthalmol* 2014.
61. Almeida DR, Chin EK, Rahim K, et al. Factors associated with spontaneous release of vitreomacular traction. *Retina* 2015;35:492-7.
62. Hikichi T, Yoshida A, Trempe CL. Course of vitreomacular traction syndrome. *Am J Ophthalmol* 1995;119:55-61.
63. Stalmans P, Benz MS, Gandorfer A, et al. Enzymatic vitreolysis with ocriplasmin for vitreomacular traction and macular holes. *N Engl J Med* 2012;367:606-15.
64. American Academy of Ophthalmology. Policy Statement. Preoperative Assessment: Responsibilities of the Ophthalmologist. San Francisco, CA: American Academy of Ophthalmology; 2012. Available at: www.aao.org/guidelines-browse?filter=clinicalstatement. Accessed January 9, 2015.

**Idiopathic ERM and VMT PPP:
References**

65. American Academy of Ophthalmology. Policy Statement. An Ophthalmologist's Duties Concerning Postoperative Care. San Francisco, CA: American Academy of Ophthalmology; 2012. Available at: www.aao.org/guidelines-browse?filter=clinicalstatement. Accessed January 9, 2015.
66. Kaiser PK, Kampik A, Kuppermann BD, et al. Safety profile of ocriplasmin for the pharmacologic treatment of symptomatic vitreomacular adhesion/traction. *Retina* 2015;35:1111-27.
67. U.S. Food and Drug Administration Center for Drug Evaluation and Research. Risk Assessment and Risk Mitigation Review(s). Application number: 125422Orig1s00. Jetrea (ocriplasmin) intravitreal injection. 2012. Available at: www.accessdata.fda.gov/drugsatfda_docs/nda/2012/125422Orig1s000RiskR.pdf. Accessed January 29, 2015.
68. Fahim AT, Khan NW, Johnson MW. Acute panretinal structural and functional abnormalities after intravitreal ocriplasmin injection. *JAMA Ophthalmol* 2014;132:484-6.
69. Kim JE. Safety and complications of ocriplasmin: ocriplasmin, ocriplasmin; oh, how safe art thou? *JAMA Ophthalmol* 2014;132:379-80.
70. Tibbetts MD, Reichel E, Witkin AJ. Vision loss after intravitreal ocriplasmin: correlation of spectral-domain optical coherence tomography and electroretinography. *JAMA Ophthalmol* 2014;132:487-90.
71. Hahn P, Chung MM, Flynn HW, et al, American Society of Retina Specialists Therapeutic Surveillance Committee. Safety profile of ocriplasmin for symptomatic vitreomacular adhesion - a comprehensive analysis of pre- and post-marketing experiences. *Invest Ophthalmol Vis Sci* 2014;55:E-Abstract 2209.
72. Johnson MW. How should we release vitreomacular traction: surgically, pharmacologically, or pneumatically? *Am J Ophthalmol* 2013;155:203-5.
73. American Academy of Ophthalmology Retina/Vitreous Panel. Preferred Practice Pattern[®] Guidelines. Idiopathic Macular Hole. San Francisco, CA: American Academy of Ophthalmology; 2014. Available at: www.aao.org/ppp.
74. U.S. National Institutes of Health. Study Record Detail. Intravitreal gas for vitreomacular adhesion (release). Available at: <https://clinicaltrials.gov/ct2/show/NCT02001701>. Accessed March 31, 2015.
75. Bovey EH, Uffer S, Achache F. Surgery for epimacular membrane: impact of retinal internal limiting membrane removal on functional outcome. *Retina* 2004;24:728-35.
76. Kwok A, Lai TY, Yuen KS. Epiretinal membrane surgery with or without internal limiting membrane peeling. *Clin Experiment Ophthalmol* 2005;33:379-85.
77. Oh HN, Lee JE, Kim HW, Yun IH. Clinical outcomes of double staining and additional ILM peeling during ERM surgery. *Korean J Ophthalmol* 2013;27:256-60.
78. Park DW, Dugel PU, Garda J, et al. Macular pucker removal with and without internal limiting membrane peeling: pilot study. *Ophthalmology* 2003;110:62-4.
79. Sandali O, El Sanharawi M, Basli E, et al. Epiretinal membrane recurrence: incidence, characteristics, evolution, and preventive and risk factors. *Retina* 2013;33:2032-8.
80. Shimada H, Nakashizuka H, Hattori T, et al. Double staining with brilliant blue G and double peeling for epiretinal membranes. *Ophthalmology* 2009;116:1370-6.
81. Koestinger A, Bovey EH. Visual acuity after vitrectomy and epiretinal membrane peeling with or without premacular indocyanine green injection. *Eur J Ophthalmol* 2005;15:795-9.
82. Pearce IA, Branley M, Groenewald C, et al. Visual function and patient satisfaction after macular hole surgery. *Eye (Lond)* 1998;12 (Pt 4):651-8.
83. Massin P, Paques M, Masri H, et al. Visual outcome of surgery for epiretinal membranes with macular pseudoholes. *Ophthalmology* 1999;106:580-5.
84. Bouwens MD, de Jong F, Mulder P, van Meurs JC. Results of macular pucker surgery: 1- and 5-year follow-up. *Graefes Arch Clin Exp Ophthalmol* 2008;246:1693-7.
85. Dawson SR, Shunmugam M, Williamson TH. Visual acuity outcomes following surgery for idiopathic epiretinal membrane: an analysis of data from 2001 to 2011. *Eye (Lond)* 2014;28:219-24.
86. Ghazi-Nouri SM, Tranos PG, Rubin GS, et al. Visual function and quality of life following vitrectomy and epiretinal membrane peel surgery. *Br J Ophthalmol* 2006;90:559-62.
87. Matsuoka Y, Tanito M, Takai Y, et al. Visual function and vision-related quality of life after vitrectomy for epiretinal membranes: a 12-month follow-up study. *Invest Ophthalmol Vis Sci* 2012;53:3054-8.
88. Okamoto F, Okamoto Y, Hiraoka T, Oshika T. Effect of vitrectomy for epiretinal membrane on visual function and vision-related quality of life. *Am J Ophthalmol* 2009;147:869-74.

89. Garcia-Fernandez M, Castro Navarro J, Gonzalez Castano C, et al. Epiretinal membrane surgery: anatomic and functional outcomes. *Arch Soc Esp Ophthalmol* 2013;88:139-44.
90. Wong JG, Sachdev N, Beaumont PE, Chang AA. Visual outcomes following vitrectomy and peeling of epiretinal membrane. *Clin Experiment Ophthalmol* 2005;33:373-8.
91. Jackson TL, Nicod E, Angelis A, et al. Pars plana vitrectomy for vitreomacular traction syndrome: a systematic review and metaanalysis of safety and efficacy. *Retina* 2013;33:2012-7.
92. Kim HJ, Kang JW, Chung H, Kim HC. Correlation of foveal photoreceptor integrity with visual outcome in idiopathic epiretinal membrane. *Curr Eye Res* 2014;39:626-33.
93. Shimozone M, Oishi A, Hata M, et al. The significance of cone outer segment tips as a prognostic factor in epiretinal membrane surgery. *Am J Ophthalmol* 2012;153:698-704.
94. Hashimoto Y, Saito W, Saito M, et al. Retinal outer layer thickness increases after vitrectomy for epiretinal membrane, and visual improvement positively correlates with photoreceptor outer segment length. *Graefes Arch Clin Exp Ophthalmol* 2014;252:219-26.
95. de Bustros S, Thompson JT, Michels RG, et al. Nuclear sclerosis after vitrectomy for idiopathic epiretinal membranes. *Am J Ophthalmol* 1988;105:160-4.
96. McDonald HR, Verre WP, Aaberg TM. Surgical management of idiopathic epiretinal membranes. *Ophthalmology* 1986;93:978-83.
97. de Bustros S, Thompson JT, Michels RG, et al. Vitrectomy for idiopathic epiretinal membranes causing macular pucker. *Br J Ophthalmol* 1988;72:692-5.
98. Margherio RR, Cox MS Jr, Trese MT, et al. Removal of epimacular membranes. *Ophthalmology* 1985;92:1075-83.
99. Dugas B, Ouled-Moussa R, Lafontaine PO, et al. Idiopathic epiretinal macular membrane and cataract extraction: combined versus consecutive surgery. *Am J Ophthalmol* 2010;149:302-6.
100. Tarantola RM, Tsui JY, Graff JM, et al. Intraoperative sclerotomy-related retinal breaks during 23-gauge pars plana vitrectomy. *Retina* 2013;33:136-42.
101. Grosso A, Panico C. Incidence of retinal detachment following 23-gauge vitrectomy in idiopathic epiretinal membrane surgery. *Acta Ophthalmol* 2011;89:e98.
102. Le Rouic JF, Becquet F, Ducournau D. Does 23-gauge sutureless vitrectomy modify the risk of postoperative retinal detachment after macular surgery? A comparison with 20-gauge vitrectomy. *Retina* 2011;31:902-8.
103. Banker AS, Freeman WR, Kim JW, et al, Vitrectomy for Macular Hole Study Group. Vision-threatening complications of surgery for full-thickness macular holes. *Ophthalmology* 1997;104:1442-52; discussion 1452-3.
104. Park SS, Marcus DM, Duker JS, et al. Posterior segment complications after vitrectomy for macular hole. *Ophthalmology* 1995;102:775-81.
105. Dayan MR, Jayamanne DG, Andrews RM, Griffiths PG. Flashes and floaters as predictors of vitreoretinal pathology: is follow-up necessary for posterior vitreous detachment? *Eye* 1996;10:456-8.
106. Byer NE. Natural history of posterior vitreous detachment with early management as the premier line of defense against retinal detachment. *Ophthalmology* 1994;101:1503-14.
107. Smiddy WE, Michels RG, de Bustros S, et al. Histopathology of tissue removed during vitrectomy for impending idiopathic macular holes. *Am J Ophthalmol* 1989;108:360-4.
108. Hirata A, Yonemura N, Hasumura T, et al. Effect of infusion air pressure on visual field defects after macular hole surgery. *Am J Ophthalmol* 2000;130:611-6.
109. American Academy of Ophthalmology Vision Rehabilitation Committee. Preferred Practice Pattern[®] Guidelines. Vision Rehabilitation. San Francisco, CA: American Academy of Ophthalmology; 2013. Available at: www.aao.org/ppp.
110. Stelmack JA, Tang XC, Reda DJ, et al, LOVIT Study Group. Outcomes of the Veterans Affairs Low Vision Intervention Trial (LOVIT). *Arch Ophthalmol* 2008;126:608-17.
111. Gupta OP, Brown GC, Brown MM. A value-based medicine cost-utility analysis of idiopathic epiretinal membrane surgery. *Am J Ophthalmol* 2008;145:923-8.
112. Chang JS, Smiddy WE. Cost evaluation of surgical and pharmaceutical options in treatment for vitreomacular adhesions and macular holes. *Ophthalmology* 2014;121:1720-6.



P.O. Box 7424
San Francisco,
California 94120-7424
415.561.8500

Idiopathic Epiretinal Membrane
and Vitreomacular Traction
2015