Before you begin: This is a big topic, and big topics beget big slide-sets. There's a few natural breaks (around slides 173, 246, and 411); *break time!* slides have been placed at those spots.

Q

Open-angle Glaucoma: *Secondary*

Define glaucoma.

A

Open-angle Glaucoma: *Secondary*

Define glaucoma.
A group of optic neuropathies that present with progressive ONH damage and characteristic VF loss

Q

Open-angle Glaucoma: *Secondary*

Define glaucoma.
A group of optic neuropathies that present with progressive ONH damage and characteristic VF loss

Why isn't elevated IOP mentioned above?

A

Open-angle Glaucoma: *Secondary*

Define glaucoma.
A group of optic neuropathies that present with progressive ONH damage and characteristic VF loss

Why isn't elevated IOP mentioned above?
Elevated IOP is a strong risk factor for glaucoma, but it need not be present—IOP can be normal, or even low

Q

Open-angle Glaucoma: *Secondary*

Define glaucoma.
A group of optic neuropathies that present with progressive ONH damage and characteristic VF loss

Why isn't elevated IOP mentioned above?
Elevated IOP is a strong risk factor for glaucoma, but it need not be present—IOP can be normal, or even low

In addition to being the strongest risk factor for glaucoma, IOP has another quality that renders it unique—what is it?

A

Open-angle Glaucoma: *Secondary*

Define glaucoma.
A group of optic neuropathies that present with progressive ONH damage and characteristic VF loss

Why isn't elevated IOP mentioned above?
Elevated IOP is a strong risk factor for glaucoma, but it need not be present—IOP can be normal, or even low

In addition to being the strongest risk factor for glaucoma, IOP has another quality that renders it unique—what is it?
It is the only risk factor that is modifiable in a manner proven to influence the risk of glaucoma progression

Open-angle Glaucoma: *Secondary*

Define glaucoma.
A group of optic neuropathies that present with progressive ONH damage and characteristic VF loss

Why isn't elevated IOP mentioned above?
Elevated IOP is a strong risk factor for glaucoma, but it need not be present—IOP can be normal, or even low

In addition to being the strongest risk factor for glaucoma, IOP has another quality that renders it unique—what is it?
It is the only risk factor that is **modifiable** in a manner proven to influence the risk of glaucoma progression

That's why glaucoma management concerns nothing but IOP-lowering maneuvers!

Q

Open-angle Glaucoma: *Secondary*

Glaucoma

?

The first thought you should have when encountering a pt you suspect has glaucoma is…

A

Open-angle Glaucoma: *Secondary*

Glaucoma

Open-angle ? *Closed-* or *narrow-angle*

The first thought you should have when encountering a pt you suspect has glaucoma is…
What is the status of the angle?

Q

Open-angle Glaucoma: *Secondary*

Glaucoma

Open-angle

Closed- or *narrow-angle*

The first thought you should have when encountering a pt you suspect has glaucoma is…

What is the status of the angle?

How does one determine the status of the angle?

A

Open-angle Glaucoma: *Secondary*

Glaucoma

Open-angle

Closed- or *narrow-angle*

The first thought you should have when encountering a pt you suspect has glaucoma is…

What is the status of the angle?

How does one determine the status of the angle?

Gonioscopy. Don't assume your glaucoma pt has open angles—**prove** it by gonioing them!

Open-angle Glaucoma: *Secondary*

Glaucoma

Open-angle

Closed-* or *narrow-angle

The first thought you should have when encountering a pt you suspect has glaucoma is…
What is the status of the angle?

How does one determine the status of the angle?
Gonioscop[illegible]ioing them!

Angle-closure glaucoma *is covered in multiple slide-sets; see the* Table of Contents

Q

Open-angle Glaucoma: *Secondary*

OAG

?

Once you have determined a pt has open-angle glaucoma,
the next ‘first thought’ is to ask…

A

Open-angle Glaucoma: *Secondary*

OAG

↑*IOP*

Normal-tension glaucoma (NTG)

<u>Once you have determined a pt has open-angle glaucoma,</u>
the next 'first thought' is to ask…
Is it high-pressure OAG, or low (aka* normal*) tension OAG?

Q

Open-angle Glaucoma: *Secondary*

OAG

↑*IOP*

Normal-tension glaucoma (NTG)

Untreated IOP consistently *above* # mmHg

Untreated IOP consistently *below* # mmHg

A

Open-angle Glaucoma: *Secondary*

OAG

↑*IOP*

Untreated IOP consistently *above* 22 mmHg

Normal-tension glaucoma (NTG)

Untreated IOP consistently *below* 22 mmHg

*(Note that this distinction is somewhat controversial, as some glaucomalogists contend NTG is **not** a separate condition.)*

Open-angle Glaucoma: *Secondary*

OAG

↑*IOP*

Normal-tension glaucoma (NTG)

Untreated IOP consistently *above* 22 mmHg

Untreated IOP consistently *below* 22 mmHg

(Note that this di *comalogists contend NTG is*

Normal-tension glaucoma *is covered in its own slide-set (*G21*)*

Q

Open-angle Glaucoma: *Secondary*

↑ IOP OAG

?

<u>Once you have determined a pt has high-pressure open-angle glaucoma,</u>
the next ‘first thought’ is to ask…

A

Open-angle Glaucoma: *Secondary*

↑ IOP OAG

Primary ? *Secondary*

<u>Once you have determined a pt has high-pressure open-angle glaucoma,</u>
the next 'first thought' is to ask…
Is it primary open-angle glaucoma (POAG), or secondary OAG?

Q

Open-angle Glaucoma: *Secondary*

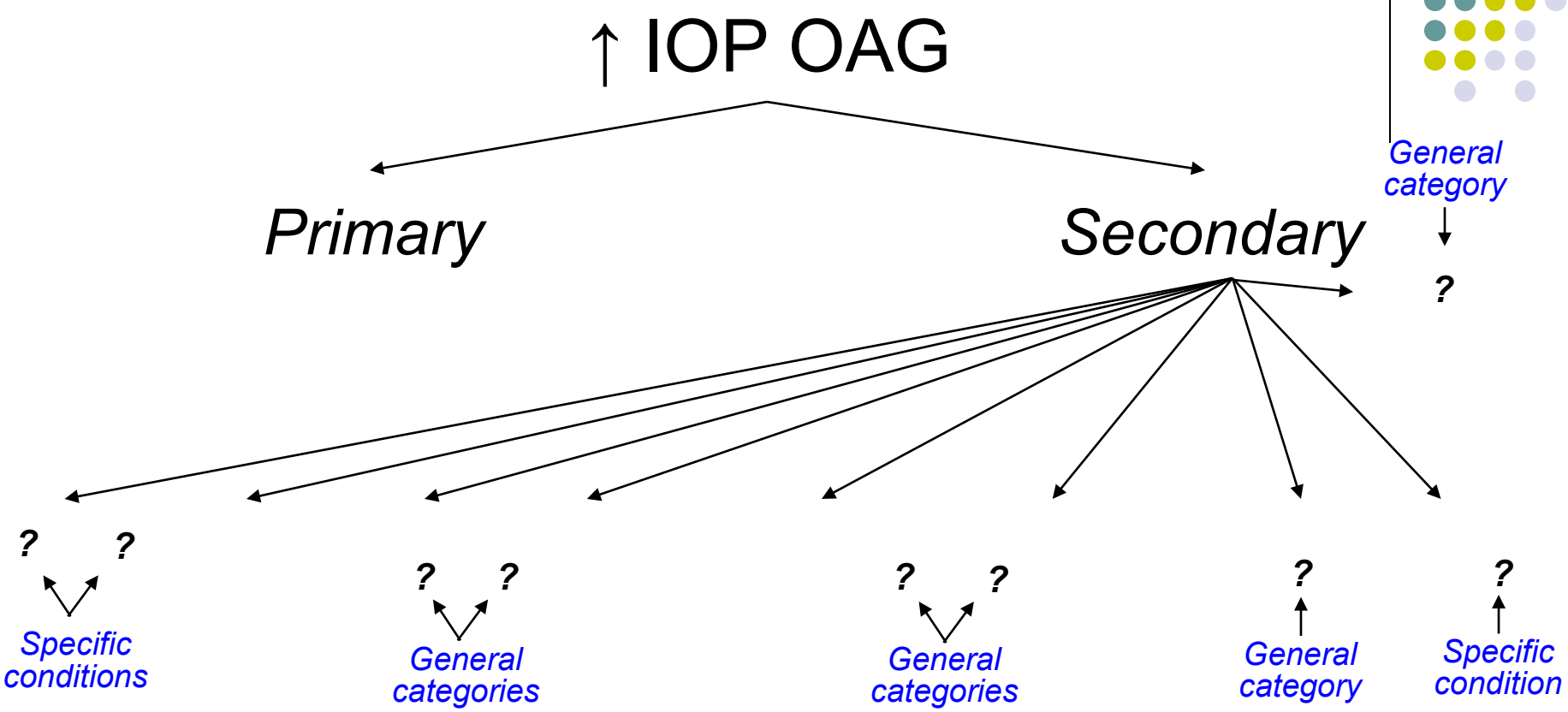

*There are **many** forms of secondary open-angle glaucoma!*

A

Open-angle Glaucoma: *Secondary*

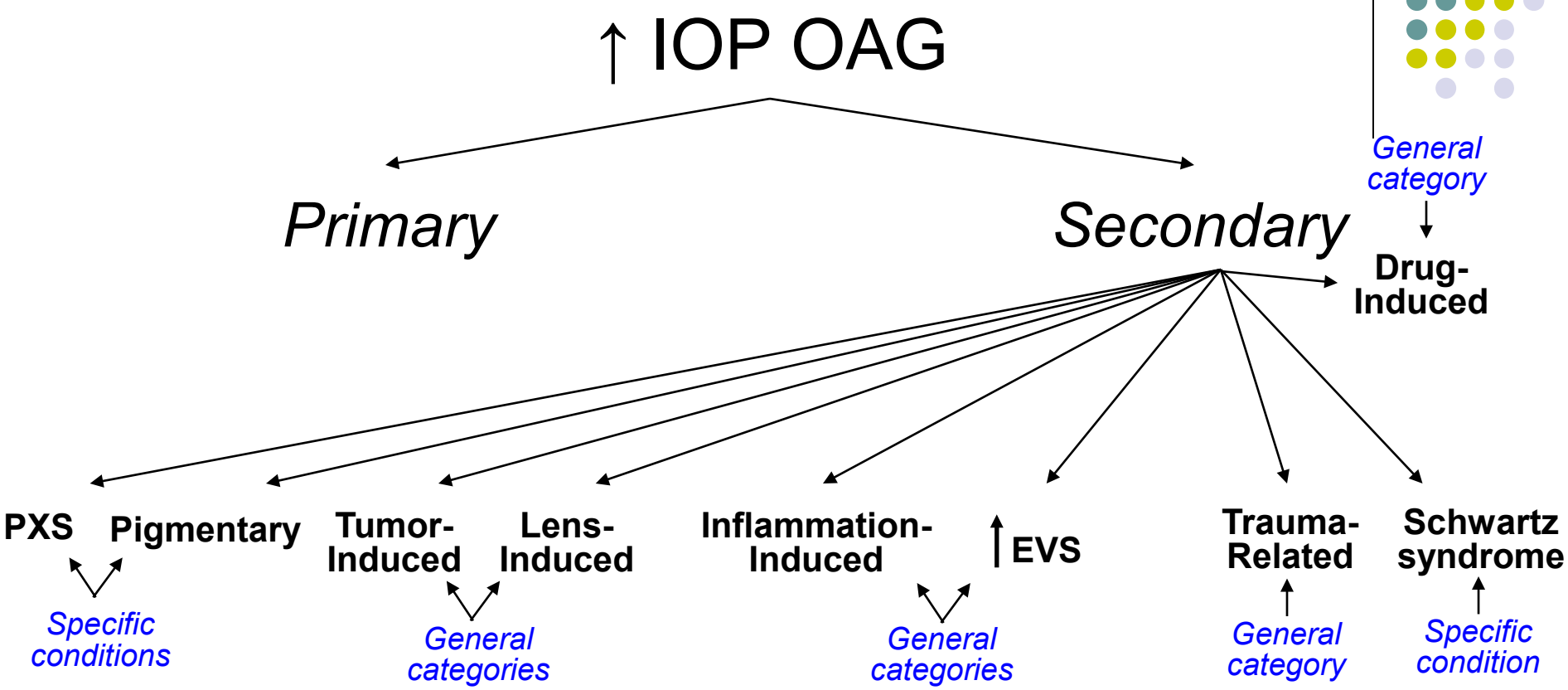

*There are **many** forms of secondary open-angle glaucoma!*

Open-angle Glaucoma: *Secondary*

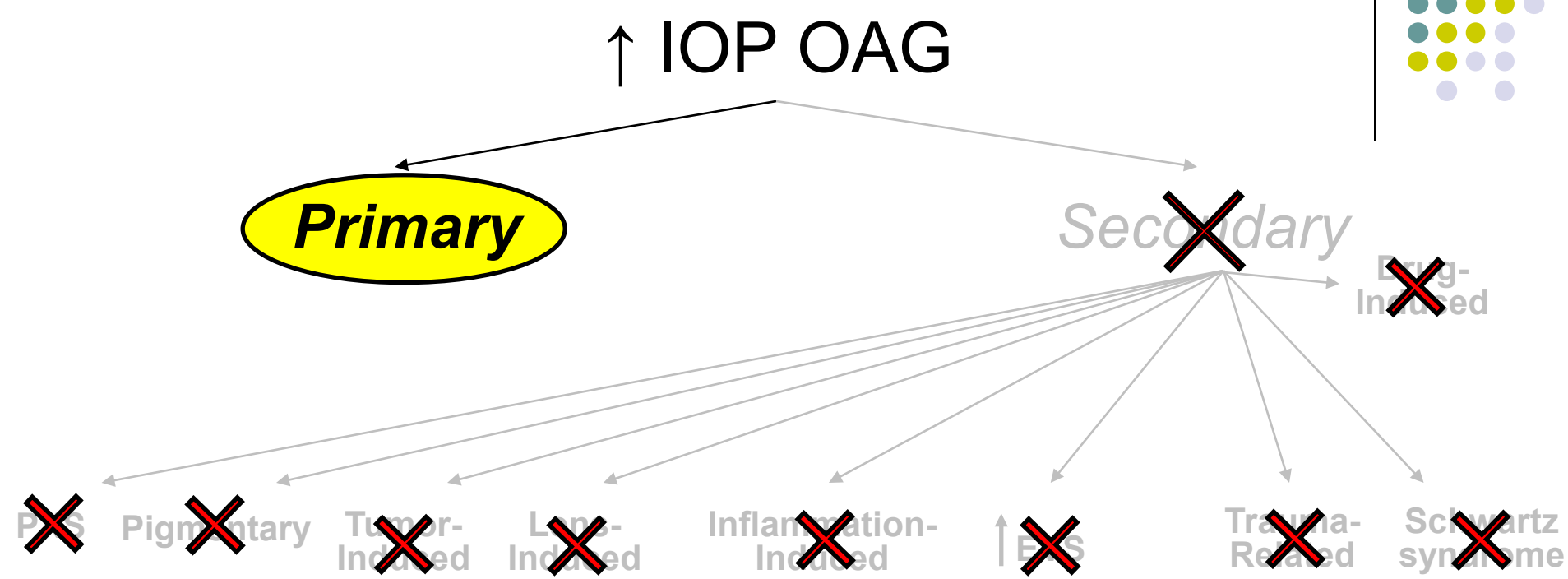

Note that primary open-angle glaucoma (POAG) is a diagnosis of exclusion—*it can only be made by first determining that the angle is open, and then ruling out the myriad causes of* ***secondary*** *OAG*

Open-angle Glaucoma: *Secondary*

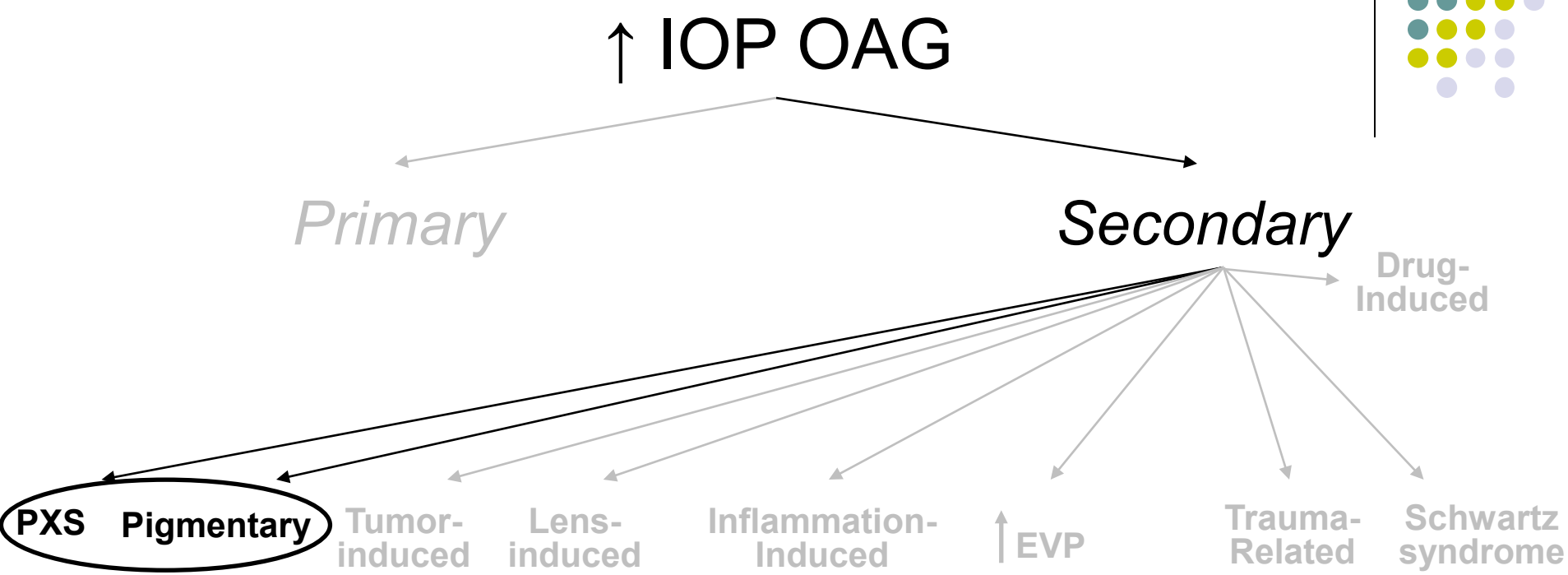

PXS *and* pigmentary glaucoma *are addressed in slide-set* G4

Open-angle Glaucoma: *Secondary*

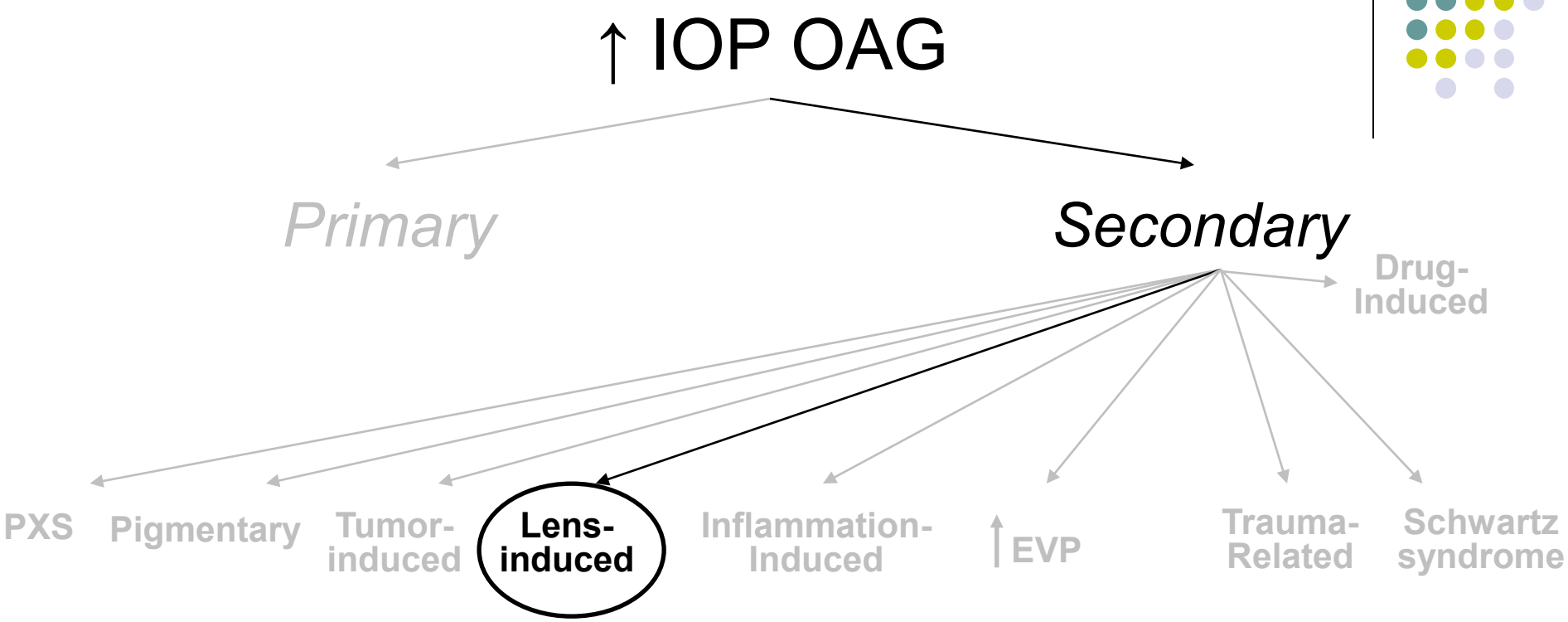

Let's take a look at secondary OAG owing to the lens

Q

For each statement, identify the **lens-related secondary OAG** with which it is associated (some have more than one answer)

Phacolytic glaucoma **Phacoantigenic glaucoma** **Lens-particle glaucoma**

- The only one described in the *Glaucoma* book as ‘rare’:

A

For each statement, identify the **lens-related secondary OAG** with which it is associated (some have more than one answer)

Phacolytic glaucoma **Phacoantigenic glaucoma** **Lens-particle glaucoma**

- The only one described in the *Glaucoma* book as ‘rare’: Phacoantigenic

Q

For each statement, identify the **lens-related secondary OAG** with which it is associated (some have more than one answer)

Phacolytic glaucoma **Phacoantigenic glaucoma** **Lens-particle glaucoma**

- The only one described in the *Glaucoma* book as ‘rare’: Phacoantigenic
- Mediated by inflammatory response to lens proteins in AC:

A

For each statement, identify the **lens-related secondary OAG** with which it is associated (some have more than one answer)

Phacolytic glaucoma **Phacoantigenic glaucoma** **Lens-particle glaucoma**

- The only one described in the *Glaucoma* book as ‘rare’: Phacoantigenic
- Mediated by inflammatory response to lens proteins in AC: Phacoantigenic; phacolytic

Q

For each statement, identify the **lens-related secondary OAG** with which it is associated (some have more than one answer)

Phacolytic glaucoma **Phacoantigenic glaucoma** **Lens-particle glaucoma**

- The only one described in the *Glaucoma* book as ‘rare’: Phacoantigenic
- Mediated by inflammatory response to lens proteins in AC: Phacoantigenic; phacolytic
- Mediated by IgG antibodies:

A

For each statement, identify the **lens-related secondary OAG** with which it is associated (some have more than one answer)

Phacolytic glaucoma **Phacoantigenic glaucoma** **Lens-particle glaucoma**

- The only one described in the *Glaucoma* book as ‘rare’: Phacoantigenic
- Mediated by inflammatory response to lens proteins in AC: Phacoantigenic; phacolytic
- Mediated by IgG antibodies: Phacoantigenic

Q

For each statement, identify the **lens-related secondary OAG** with which it is associated (some have more than one answer)

Phacolytic glaucoma **Phacoantigenic glaucoma** **Lens-particle glaucoma**

- The only one described in the *Glaucoma* book as ‘rare’: Phacoantigenic
- Mediated by inflammatory response to lens proteins in AC: Phacoantigenic; phacolytic
- Mediated by IgG antibodies: Phacoantigenic
- TM is clogged with macrophages:

A

For each statement, identify the **lens-related secondary OAG** with which it is associated (some have more than one answer)

Phacolytic glaucoma **Phacoantigenic glaucoma** **Lens-particle glaucoma**

- The only one described in the *Glaucoma* book as ‘rare’: Phacoantigenic
- Mediated by inflammatory response to lens proteins in AC: Phacoantigenic; phacolytic
- Mediated by IgG antibodies: Phacoantigenic
- TM is clogged with macrophages: Phacolytic

Q

For each statement, identify the **lens-related secondary OAG** with which it is associated (some have more than one answer)

Phacolytic glaucoma **Phacoantigenic glaucoma** **Lens-particle glaucoma**

- The only one described in the *Glaucoma* book as 'rare': Phacoantigenic
- Mediated by inflammatory response to lens proteins in AC: Phacoantigenic; phacolytic
- Mediated by IgG antibodies: Phacoantigenic
- **TM is clogged with macrophages**: Phacolytic

'TM clogged with macrophages' applies also to another form of secondary OAG—which one?

A

For each statement, identify the **lens-related secondary OAG** with which it is associated (some have more than one answer)

Phacolytic glaucoma **Phacoantigenic glaucoma** **Lens-particle glaucoma**

- The only one described in the *Glaucoma* book as 'rare': Phacoantigenic
- Mediated by inflammatory response to lens proteins in AC: Phacoantigenic; phacolytic
- Mediated by IgG antibodies: Phacoantigenic
- **TM is clogged with macrophages**: Phacolytic

'TM clogged with macrophages' applies also to another form of secondary OAG—which one?
Hemolytic glaucoma

Q

For each statement, identify the **lens-related secondary OAG** with which it is associated (some have more than one answer)

Phacolytic glaucoma **Phacoantigenic glaucoma** **Lens-particle glaucoma**

- The only one described in the *Glaucoma* book as 'rare': Phacoantigenic
- Mediated by inflammatory response to lens proteins in AC: Phacoantigenic; phacolytic
- Mediated by IgG antibodies: Phacoantigenic
- **TM is clogged with macrophages**: Phacolytic

'TM clogged with macrophages' applies also to another form of secondary OAG—which one?
Hemolytic glaucoma

In phacolytic glaucoma, the macrophages are full of two words .

A

For each statement, identify the **lens-related secondary OAG** with which it is associated (some have more than one answer)

Phacolytic glaucoma **Phacoantigenic glaucoma** **Lens-particle glaucoma**

- The only one described in the *Glaucoma* book as 'rare': Phacoantigenic
- Mediated by inflammatory response to **lens proteins** in AC: Phacoantigenic; **phacolytic**
- Mediated by IgG antibodies: Phacoantigenic
- **TM is clogged with macrophages**: Phacolytic

'TM clogged with macrophages' applies also to another form of secondary OAG—which one?
Hemolytic glaucoma

In phacolytic glaucoma, the macrophages are full of lens proteins .

Q

For each statement, identify the **lens-related secondary OAG** with which it is associated (some have more than one answer)

Phacolytic glaucoma **Phacoantigenic glaucoma** **Lens-particle glaucoma**

- The only one described in the *Glaucoma* book as 'rare': Phacoantigenic
- Mediated by inflammatory response to **lens proteins** in AC: Phacoantigenic; **phacolytic**
- Mediated by IgG antibodies: Phacoantigenic
- **TM is clogged with macrophages**: Phacolytic

'TM clogged with macrophages' applies also to another form of secondary OAG—which one?
Hemolytic glaucoma

In phacolytic glaucoma, the macrophages are full of lens proteins .
What are they full of in hemolytic glaucoma?

A

For each statement, identify the **lens-related secondary OAG** with which it is associated (some have more than one answer)

Phacolytic glaucoma **Phacoantigenic glaucoma** **Lens-particle glaucoma**

- The only one described in the *Glaucoma* book as 'rare': Phacoantigenic
- Mediated by inflammatory response to **lens proteins** in AC: Phacoantigenic; **phacolytic**
- Mediated by IgG antibodies: Phacoantigenic
- **TM is clogged with macrophages**: Phacolytic

'TM clogged with macrophages' applies also to another form of secondary OAG—which one?
Hemolytic glaucoma

In phacolytic glaucoma, the macrophages are full of lens proteins .
What are they full of in hemolytic glaucoma?
Hemoglobin

Q

For each statement, identify the **lens-related secondary OAG** with which it is associated (some have more than one answer)

Phacolytic glaucoma **Phacoantigenic glaucoma** **Lens-particle glaucoma**

- The only one described in the *Glaucoma* book as ‘rare’: Phacoantigenic
- Mediated by inflammatory response to lens proteins in AC: Phacoantigenic; phacolytic
- Mediated by IgG antibodies: Phacoantigenic
- TM is clogged with macrophages: Phacolytic
- Chunks of cortex may be visible in AC:

A

For each statement, identify the **lens-related secondary OAG** with which it is associated (some have more than one answer)

Phacolytic glaucoma **Phacoantigenic glaucoma** **Lens-particle glaucoma**

- The only one described in the *Glaucoma* book as ‘rare’: Phacoantigenic
- Mediated by inflammatory response to lens proteins in AC: Phacoantigenic; phacolytic
- Mediated by IgG antibodies: Phacoantigenic
- TM is clogged with macrophages: Phacolytic
- Chunks of cortex may be visible in AC: Lens particle

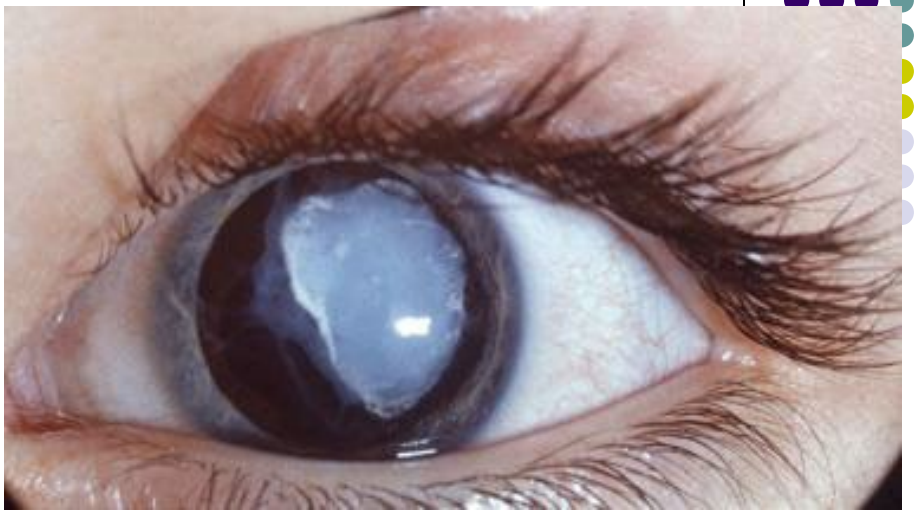

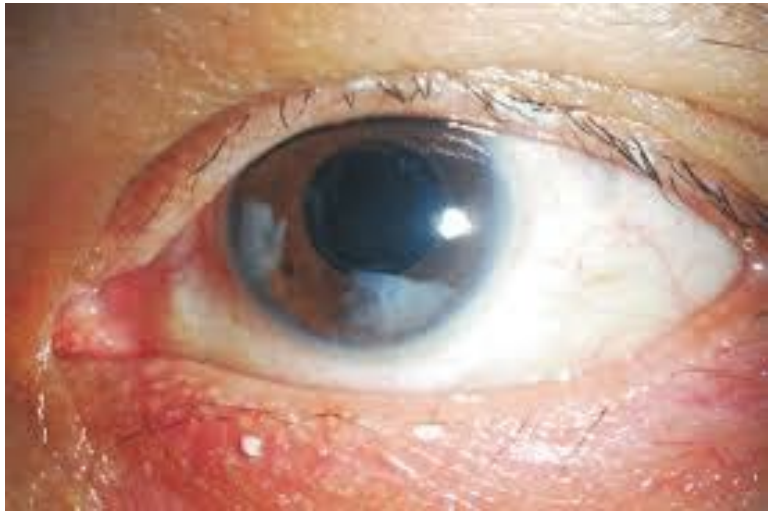

Lens-particle glaucoma

Q

For each statement, identify the **lens-related secondary OAG** with which it is associated (some have more than one answer)

Phacolytic glaucoma **Phacoantigenic glaucoma** **Lens-particle glaucoma**

- The only one described in the *Glaucoma* book as ‘rare’: Phacoantigenic
- Mediated by inflammatory response to lens proteins in AC: Phacoantigenic; phacolytic
- Mediated by IgG antibodies: Phacoantigenic
- TM is clogged with macrophages: Phacolytic
- Chunks of cortex may be visible in AC: Lens particle
- Is also known as [condition name] *uveitis*:

A

For each statement, identify the **lens-related secondary OAG** with which it is associated (some have more than one answer)

Phacolytic glaucoma **Phacoantigenic glaucoma** **Lens-particle glaucoma**

- The only one described in the *Glaucoma* book as ‘rare’: Phacoantigenic
- Mediated by inflammatory response to lens proteins in AC: Phacoantigenic; phacolytic
- Mediated by IgG antibodies: Phacoantigenic
- TM is clogged with macrophages: Phacolytic
- Chunks of cortex may be visible in AC: Lens particle
- Is also known as [condition name] *uveitis*: Phacoantigenic

Q

For each statement, identify the **lens-related secondary OAG** with which it is associated (some have more than one answer)

Phacolytic glaucoma **Phacoantigenic glaucoma** **Lens-particle glaucoma**

- The only one described in the *Glaucoma* book as ‘rare’: Phacoantigenic
- Mediated by inflammatory response to lens proteins in AC: Phacoantigenic; phacolytic
- Mediated by IgG antibodies: Phacoantigenic
- TM is clogged with macrophages: Phacolytic
- Chunks of cortex may be visible in AC: Lens particle
- Is also known as [condition name] *uveitis*: Phacoantigenic
- Capsule is intact:

A

For each statement, identify the **lens-related secondary OAG** with which it is associated (some have more than one answer)

Phacolytic glaucoma **Phacoantigenic glaucoma** **Lens-particle glaucoma**

- The only one described in the *Glaucoma* book as ‘rare’: Phacoantigenic
- Mediated by inflammatory response to lens proteins in AC: Phacoantigenic; phacolytic
- Mediated by IgG antibodies: Phacoantigenic
- TM is clogged with macrophages: Phacolytic
- Chunks of cortex may be visible in AC: Lens particle
- Is also known as [condition name] *uveitis*: Phacoantigenic
- Capsule is intact: Phacolytic

Q

For each statement, identify the **lens-related secondary OAG** with which it is associated (some have more than one answer)

Phacolytic glaucoma **Phacoantigenic glaucoma** **Lens-particle glaucoma**

- The only one described in the *Glaucoma* book as 'rare': Phacoantigenic
- Mediated by inflammatory response to lens proteins in AC: Phacoantigenic; phacolytic
- Mediated by IgG antibodies: Phacoantigenic
- TM is clogged with macrophages: Phacolytic
- Chunks of cortex may be visible in AC: Lens particle
- Is also known as [condition name] *uveitis*: Phacoantigenic
- **Capsule is intact: Phacolytic**

What does this imply about the status of the capsule in phacoantigenic and lens-particle glaucoma?

A

For each statement, identify the **lens-related secondary OAG** with which it is associated (some have more than one answer)

Phacolytic glaucoma **Phacoantigenic glaucoma** **Lens-particle glaucoma**

- The only one described in the *Glaucoma* book as 'rare': Phacoantigenic
- Mediated by inflammatory response to lens proteins in AC: Phacoantigenic; phacolytic
- Mediated by IgG antibodies: Phacoantigenic
- TM is clogged with macrophages: Phacolytic
- Chunks of cortex may be visible in AC: Lens particle
- Is also known as [condition name] *uveitis*: Phacoantigenic
- **Capsule is intact: Phacolytic**

What does this imply about the status of the capsule in phacoantigenic and lens-particle glaucoma?

It implies (correctly) that the capsule is **open** in these conditions

For each statement, identify the **lens-related secondary OAG** with which it is associated (some have more than one answer)

Phacolytic glaucoma **Phacoantigenic glaucoma** **Lens-particle glauco**

- The only one described in the *Glaucoma* book as 'rare
  Phacoantigenic
- Mediated by inflamm ponse to lens proteins in
  Phacoantigenic; pha
- Mediated by IgG ant Phacoantigenic
- TM is clogged with n ges Phacolytic
- Chunks of cortex ma
- Is also known as [co an ge
- **Capsule is intact: Phacolytic**

Phacolytic through intact capsule

This is how I remember that the capsule is intact in phacolytic glaucoma, but **not** in phacoantigenic glaucoma

Phacoantige not intact capsule

What does this imply about the status of the capsule in phacoantigenic and lens-particle glaucoma?

It implies (correctly) that the capsule is **open** in these conditions

Q

For each statement, identify the **lens-related secondary OAG** with which it is associated (some have more than one answer)

Phacolytic glaucoma **Phacoantigenic glaucoma** **Lens-particle glaucoma**

- The only one described in the *Glaucoma* book as ‘rare’: Phacoantigenic
- Mediated by inflammatory response to lens proteins in AC: Phacoantigenic; phacolytic
- Mediated by IgG antibodies: Phacoantigenic
- TM is clogged with macrophages: Phacolytic
- Chunks of cortex may be visible in AC: Lens particle
- Is also known as [condition name] *uveitis*: Phacoantigenic
- Capsule is intact: Phacolytic
- AC reaction is granulomatous:

A

For each statement, identify the **lens-related secondary OAG** with which it is associated (some have more than one answer)

Phacolytic glaucoma **Phacoantigenic glaucoma** **Lens-particle glaucoma**

- The only one described in the *Glaucoma* book as ‘rare’: Phacoantigenic
- Mediated by inflammatory response to lens proteins in AC: Phacoantigenic; phacolytic
- Mediated by IgG antibodies: Phacoantigenic
- TM is clogged with macrophages: Phacolytic
- Chunks of cortex may be visible in AC: Lens particle
- Is also known as [condition name] *uveitis*: Phacoantigenic
- Capsule is intact: Phacolytic
- AC reaction is granulomatous: Phacoantigenic

Q

For each statement, identify the **lens-related secondary OAG** with which it is associated (some have more than one answer)

Phacolytic glaucoma **Phacoantigenic glaucoma** **Lens-particle glaucoma**

- The only one described in the *Glaucoma* book as 'rare': Phacoantigenic
- Mediated by inflammatory response to lens proteins in AC: Phacoantigenic; phacolytic
- Mediated by IgG antibodies: Phacoantigenic
- TM is clogged with macrophages: Phacolytic
- Chunks of cortex may be visible in AC: Lens particle
- Is also known as [condition name] *uveitis*: Phacoantigenic
- Capsule is intact: Phacolytic
- AC reaction is granulomatous: Phacoantigenic
- Is a reaction to *normal* lens proteins:

A

For each statement, identify the **lens-related secondary OAG** with which it is associated (some have more than one answer)

Phacolytic glaucoma **Phacoantigenic glaucoma** **Lens-particle glaucoma**

- The only one described in the *Glaucoma* book as ‘rare’: Phacoantigenic
- Mediated by inflammatory response to lens proteins in AC: Phacoantigenic; phacolytic
- Mediated by IgG antibodies: Phacoantigenic
- TM is clogged with macrophages: Phacolytic
- Chunks of cortex may be visible in AC: Lens particle
- Is also known as [condition name] *uveitis*: Phacoantigenic
- Capsule is intact: Phacolytic
- AC reaction is granulomatous: Phacoantigenic
- Is a reaction to *normal* lens proteins: Phacoantigenic

Q

For each statement, identify the **lens-related secondary OAG** with which it is associated (some have more than one answer)

Phacolytic glaucoma **Phacoantigenic glaucoma** **Lens-particle glaucoma**

- The only one described in the *Glaucoma* book as 'rare': P
- M AC: P
- M
- T
- Chunks of cortex may be visible in AC: Lens particle
- Is also known as [condition name] *uveitis*: Phacoantigenic
- Capsule is intact: Phacolytic
- AC reaction is granulomatous: Phacoantigenic
- **Is a reaction to *normal* lens proteins: Phacoantigenic**

Why is it significant that phacoantigenic glaucoma involves an immune reaction to 'normal' lens proteins?

A

For each statement, identify the **lens-related secondary OAG** with which it is associated (some have more than one answer)

Phacolytic glaucoma **Phacoantigenic glaucoma** **Lens-particle glaucoma**

- The only one described in the *Glaucoma* book as 'rare': P
- M C: P
- M
- T
- Chunks of cortex may be visible in AC: Lens particle
- Is also known as [condition name] *uveitis*: Phacoantigenic
- Capsule is intact: Phacolytic
- AC reaction is granulomatous: Phacoantigenic
- **Is a reaction to *normal* lens proteins: Phacoantigenic**

Why is it significant that phacoantigenic glaucoma involves an immune reaction to 'normal' lens proteins?

In phakic eyes, minute amounts of lens proteins make their way through the capsule and into the AC. Because of this, normal lens proteins enjoy a certain level of immunologic privilege and are well tolerated by the eye.

A

For each statement, identify the **lens-related secondary OAG** with which it is associated (some have more than one answer)

Phacolytic glaucoma **Phacoantigenic glaucoma** **Lens-particle glaucoma**

- The only one described in the *Glaucoma* book as 'rare': P
- M AC: P
- M
- T
- Chunks of cortex may be visible in AC: Lens particle
- Is also known as [condition name] ***uveitis*: Phacoantigenic**
- Capsule is intact: Phacolytic
- AC reaction is granulomatous: Phacoantigenic
- **Is a reaction to *normal* lens proteins: Phacoantigenic**

Why is it significant that phacoantigenic glaucoma involves an immune reaction to 'normal' lens proteins?

In phakic eyes, minute amounts of lens proteins make their way through the capsule and into the AC. Because of this, normal lens proteins enjoy a certain level of immunologic privilege and are well tolerated by the eye. However, violation of the capsule results in massive amounts of lens proteins spilling into the AC. If this influx disrupts the privilege, severe inflammation, ie, phacoantigenic uveitis—and glaucoma—may result.

Q

For each statement, identify the **lens-related secondary OAG** with which it is associated (some have more than one answer)

Phacolytic glaucoma **Phacoantigenic glaucoma** **Lens-particle glaucoma**

- The only one described in the *Glaucoma* book as ‘rare’: Phacoantigenic
- Mediated by inflammatory response to lens proteins in AC: Phacoantigenic; phacolytic
- Mediated by IgG antibodies: Phacoantigenic
- TM is clogged with macrophages: Phacolytic
- Is a reaction to *normal* lens proteins: Phacoantigenic
- Chunks of cortex may be visible in AC: Lens particle
- Is also known as [condition name] *uveitis*: Phacoantigenic
- Capsule is intact: Phacolytic
- AC reaction is granulomatous: Phacoantigenic
- Is a reaction to *denatured* lens proteins:

A

For each statement, identify the **lens-related secondary OAG** with which it is associated (some have more than one answer)

Phacolytic glaucoma **Phacoantigenic glaucoma** **Lens-particle glaucoma**

- The only one described in the *Glaucoma* book as ‘rare’: Phacoantigenic
- Mediated by inflammatory response to lens proteins in AC: Phacoantigenic; phacolytic
- Mediated by IgG antibodies: Phacoantigenic
- TM is clogged with macrophages: Phacolytic
- Is a reaction to *normal* lens proteins: Phacoantigenic
- Chunks of cortex may be visible in AC: Lens particle
- Is also known as [condition name] *uveitis*: Phacoantigenic
- Capsule is intact: Phacolytic
- AC reaction is granulomatous: Phacoantigenic
- Is a reaction to *denatured* lens proteins: Phacolytic

Q

For each statement, identify the **lens-related secondary OAG** with which it is associated (some have more than one answer)

Phacolytic glaucoma **Phacoantigenic glaucoma** **Lens-particle glaucoma**

- The only one described in the *Glaucoma* book as 'rare': Phacoantigenic
- *What does it mean to say a protein has been 'denatured'?*
-
-
-
-
-
-
-
- **Is a reaction to *denatured* lens proteins: Phacolytic**

A

For each statement, identify the **lens-related secondary OAG** with which it is associated (some have more than one answer)

Phacolytic glaucoma **Phacoantigenic glaucoma** **Lens-particle glaucoma**

- The only one described in the *Glaucoma* book as 'rare': Phacoantigenic
- *What does it mean to say a protein has been 'denatured'?*
  It means the protein has been forced out of its native conformation. Because a protein's function is inextricably tied to is shape, denatured proteins do not behave as they do in their native form.
- **Is a reaction to *denatured* lens proteins: Phacolytic**

Q

For each statement, identify the **lens-related secondary OAG** with which it is associated (some have more than one answer)

Phacolytic glaucoma **Phacoantigenic glaucoma** **Lens-particle glaucoma**

- The only one described in the *Glaucoma* book as 'rare': Phacoantigenic
- *What does it mean to say a protein has been 'denatured'?*
  It means the protein has been forced out of its native conformation. Because a protein's function is inextricably tied to is shape, denatured proteins do not behave as they do in their native form.

  Can you give an example of protein denaturation?
- **Is a reaction to *denatured* lens proteins: Phacolytic**

A

For each statement, identify the **lens-related secondary OAG** with which it is associated (some have more than one answer)

Phacolytic glaucoma **Phacoantigenic glaucoma** **Lens-particle glaucoma**

- The only one described in the *Glaucoma* book as 'rare': Phacoantigenic
- *What does it mean to say a protein has been 'denatured'?*
  It means the protein has been forced out of its native conformation. Because a protein's function is inextricably tied to is shape, denatured proteins do not behave as they do in their native form.

  Can you give an example of protein denaturation?
  Consider egg albumin. In its native state, it's a clear liquid. But if sufficient heat is applied, it becomes a white solid. (And if sufficient salsa is applied to the white solid, it becomes delish.)
- **Is a reaction to *denatured* lens proteins: Phacolytic**

Q

For each statement, identify the **lens-related secondary OAG** with which it is associated (some have more than one answer)

Phacolytic glaucoma **Phacoantigenic glaucoma** **Lens-particle glaucoma**

- The only one described in the *Glaucoma* book as 'rare': Phacoantigenic
- *What does it mean to say a protein has been 'denatured'?*
  It means the protein has been forced out of its native conformation. Because a protein's function is inextricably tied to is shape, denatured proteins do not behave as they do in their native form.
- *Can you give an example of protein denaturation?*
  Consider egg albumin. In its native state, it's a clear liquid. But if sufficient heat is applied, it becomes a white solid. (And if sufficient salsa is applied to the white solid, it becomes delish.)
- *What role does denaturation play in the inflammatory process?*
- **Is a reaction to *denatured* lens proteins: Phacolytic**

A

For each statement, identify the **lens-related secondary OAG** with which it is associated (some have more than one answer)

Phacolytic glaucoma **Phacoantigenic glaucoma** **Lens-particle glaucoma**

- The only one described in the *Glaucoma* book as 'rare': Phacoantigenic

What does it mean to say a protein has been 'denatured'?
It means the protein has been forced out of its native conformation. Because a protein's function is inextricably tied to is shape, denatured proteins do not behave as they do in their native form.

Can you give an example of protein denaturation?
Consider egg albumin. In its native state, it's a clear liquid. But if sufficient heat is applied, it becomes a white solid. (And if sufficient salsa is applied to the white solid, it becomes delish.)

What role does denaturation play in the inflammatory process?
Recall that normal lens proteins enjoy a degree of immunologic privilege.
In contrast, *denatured* proteins enjoy no such privilege, and thus tend to attract macrophages in large numbers.

- **Is a reaction to *denatured* lens proteins: Phacolytic**

Q

For each statement, identify the **lens-related secondary OAG** with which it is associated (some have more than one answer)

Phacolytic glaucoma **Phacoantigenic glaucoma** **Lens-particle glaucoma**

- The only one described in the *Glaucoma* book as ‘rare’: Phacoantigenic
- Mediated by inflammatory response to lens proteins in AC: Phacoantigenic; phacolytic
- Mediated by IgG antibodies: Phacoantigenic
- TM is clogged with macrophages: Phacolytic
- Chunks of cortex may be visible in AC: Lens particle
- Is also known as [condition name] *uveitis*: Phacoantigenic
- Capsule is intact: Phacolytic
- AC reaction is granulomatous: Phacoantigenic
- Is a reaction to *normal* lens proteins: Phacoantigenic
- Is a reaction to *denatured* lens proteins: Phacolytic
- The presence of KP is a key clinical finding:

A

For each statement, identify the **lens-related secondary OAG** with which it is associated (some have more than one answer)

Phacolytic glaucoma **Phacoantigenic glaucoma** **Lens-particle glaucoma**

- The only one described in the *Glaucoma* book as ‘rare’: Phacoantigenic
- Mediated by inflammatory response to lens proteins in AC: Phacoantigenic; phacolytic
- Mediated by IgG antibodies: Phacoantigenic
- TM is clogged with macrophages: Phacolytic
- Chunks of cortex may be visible in AC: Lens particle
- Is also known as [condition name] *uveitis*: Phacoantigenic
- Capsule is intact: Phacolytic
- AC reaction is granulomatous: Phacoantigenic
- Is a reaction to *normal* lens proteins: Phacoantigenic
- Is a reaction to *denatured* lens proteins: Phacolytic
- The presence of KP is a key clinical finding: Phacoantigenic

Q

For each statement, identify the **lens-related secondary OAG** with which it is associated (some have more than one answer)

Phacolytic glaucoma **Phacoantigenic glaucoma** **Lens-particle glaucoma**

- The only one described in the *Glaucoma* book as 'rare': Phacoantigenic
- Mediated by inflammatory response to lens proteins in AC: Phacoantigenic; phacolytic
- Mediated by IgG antibodies: Phacoantigenic
- TM is clogged with macrophages: Phacolytic
- Chunks of cortex may be visible in AC: Lens particle
- Is also known as [condition name] *uveitis*: Phacoantigenic
- Capsule is intact: Phacolytic
- AC reaction is granulomatous: Phacoantigenic
- Is a reaction to *normal* lens proteins: Phacoantigenic
- Is a reaction to *denatured* lens proteins: Phacolytic
- **The presence of KP is a key clinical finding: Phacoantigenic**

Are the KP granulomatous, or nongranulomatous?

A

For each statement, identify the **lens-related secondary OAG** with which it is associated (some have more than one answer)

Phacolytic glaucoma **Phacoantigenic glaucoma** **Lens-particle glaucoma**

- The only one described in the *Glaucoma* book as 'rare': Phacoantigenic
- Mediated by inflammatory response to lens proteins in AC: Phacoantigenic; phacolytic
- Mediated by IgG antibodies: Phacoantigenic
- TM is clogged with macrophages: Phacolytic
- Chunks of cortex may be visible in AC: Lens particle
- Is also known as [condition name] *uveitis*: Phacoantigenic
- Capsule is intact: Phacolytic
- **AC reaction is granulomatous: Phacoantigenic**
- Is a reaction to *normal* lens proteins: Phacoantigenic
- Is a reaction to *denatured* lens proteins: Phacolytic
- **The presence of KP is a key clinical finding: Phacoantigenic**

Are the KP granulomatous, or nongranulomatous?
Granulomatous

For each statement, identify the **lens-related secondary OAG** with which it is associated (some have more than one answer)

Phacolytic glaucoma **Phacoantigenic glaucoma** **Lens-particle glaucoma**

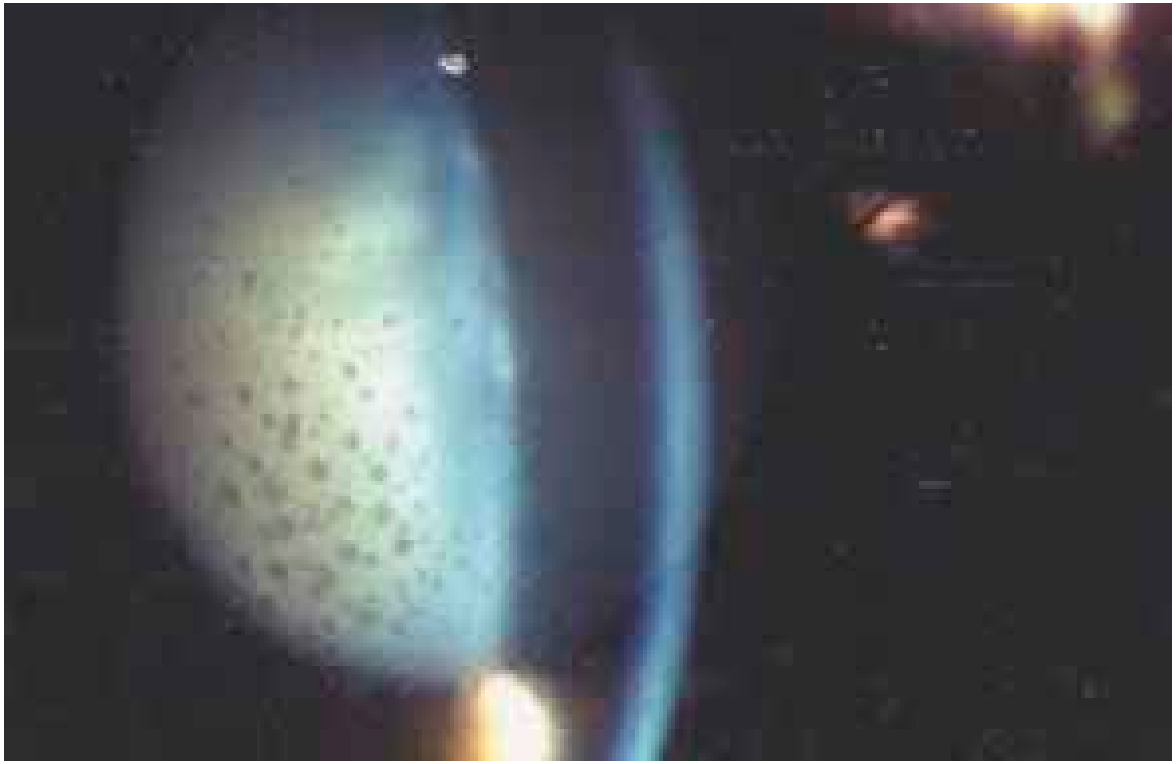

Phacoantigenic glaucoma: Granulomatous KP

Q

For each statement, identify the **lens-related secondary OAG** with which it is associated (some have more than one answer)

Phacolytic glaucoma **Phacoantigenic glaucoma** **Lens-particle glaucoma**

- The only one described in the *Glaucoma* book as ‘rare’: Phacoantigenic
- Mediated by inflammatory response to lens proteins in AC: Phacoantigenic; phacolytic
- Mediated by IgG antibodies: Phacoantigenic
- TM is clogged with macrophages: Phacolytic
- Chunks of cortex may be visible in AC: Lens particle
- Is also known as [condition name] *uveitis*: Phacoantigenic
- Capsule is intact: Phacolytic
- AC reaction is granulomatous: Phacoantigenic
- Is a reaction to *normal* lens proteins: Phacoantigenic
- Is a reaction to *denatured* lens proteins: Phacolytic
- The presence of KP is a key clinical finding: Phacoantigenic
- The one most likely to have a very high IOP:

A

For each statement, identify the **lens-related secondary OAG** with which it is associated (some have more than one answer)

Phacolytic glaucoma **Phacoantigenic glaucoma** **Lens-particle glaucoma**

- The only one described in the *Glaucoma* book as ‘rare’: Phacoantigenic
- Mediated by inflammatory response to lens proteins in AC: Phacoantigenic; phacolytic
- Mediated by IgG antibodies: Phacoantigenic
- TM is clogged with macrophages: Phacolytic
- Chunks of cortex may be visible in AC: Lens particle
- Is also known as [condition name] *uveitis*: Phacoantigenic
- Capsule is intact: Phacolytic
- AC reaction is granulomatous: Phacoantigenic
- Is a reaction to *normal* lens proteins: Phacoantigenic
- Is a reaction to *denatured* lens proteins: Phacolytic
- The presence of KP is a key clinical finding: Phacoantigenic
- The one most likely to have a very high IOP: Phacolytic

Q

For each statement, identify the **lens-related secondary OAG** with which it is associated (some have more than one answer)

Phacolytic glaucoma **Phacoantigenic glaucoma** **Lens-particle glaucoma**

- aka *phacoanaphylactic glaucoma*:

A

For each statement, identify the **lens-related secondary OAG** with which it is associated (some have more than one answer)

Phacolytic glaucoma **Phacoantigenic glaucoma** **Lens-particle glaucoma**

- aka *phacoanaphylactic glaucoma*: Phacoantigenic

Q

For each statement, identify the **lens-related secondary OAG** with which it is associated (some have more than one answer)

Phacolytic glaucoma **Phacoantigenic glaucoma** **Lens-particle glaucoma**

- aka ***phacoanaphylactic*** *glaucoma*: Phacoantigenic

Why is phacoanaphylactic glaucoma *actually a misnomer?*

A

For each statement, identify the **lens-related secondary OAG** with which it is associated (some have more than one answer)

Phacolytic glaucoma **Phacoantigenic glaucoma** **Lens-particle glaucoma**

- aka ***phacoanaphylactic*** *glaucoma*: Phacoantigenic

Why is phacoanaphylactic glaucoma *actually a misnomer?*
Because the condition is not a Type 1 (anaphylactic) reaction

Q

For each statement, identify the **lens-related secondary OAG** with which it is associated (some have more than one answer)

Phacolytic glaucoma **Phacoantigenic glaucoma** **Lens-particle glaucoma**

- aka ***phacoanaphylactic*** *glaucoma*: Phacoantigenic

Why is phacoanaphylactic glaucoma *actually a misnomer?*
Because the condition is not a Type 1 (anaphylactic) reaction

What characteristics inherent to true anaphylaxis are missing in phacoantigenic glaucoma?

A

For each statement, identify the **lens-related secondary OAG** with which it is associated (some have more than one answer)

Phacolytic glaucoma **Phacoantigenic glaucoma** **Lens-particle glaucoma**

- aka ***phacoanaphylactic*** *glaucoma*: Phacoantigenic

Why is phacoanaphylactic glaucoma *actually a misnomer?*
Because the condition is not a Type 1 (anaphylactic) reaction

What characteristics inherent to true anaphylaxis are missing in phacoantigenic glaucoma?
The involvement of IgE, mast cells and basophils

Q

For each statement, identify the **lens-related secondary OAG** with which it is associated (some have more than one answer)

Phacolytic glaucoma **Phacoantigenic glaucoma** **Lens-particle glaucoma**

- aka *phacoanaphylactic glaucoma*: Phacoantigenic
- Usually unilateral:

A

For each statement, identify the **lens-related secondary OAG** with which it is associated (some have more than one answer)

Phacolytic glaucoma **Phacoantigenic glaucoma** **Lens-particle glaucoma**

- aka *phacoanaphylactic glaucoma*: Phacoantigenic
- Usually unilateral: All of them

Q

For each statement, identify the **lens-related secondary OAG** with which it is associated (some have more than one answer)

Phacolytic glaucoma **Phacoantigenic glaucoma** **Lens-particle glaucoma**

- aka *phacoanaphylactic glaucoma*: Phacoantigenic
- Usually unilateral: All of them
- Is mediated by an *adaptive* immune response:

A

For each statement, identify the **lens-related secondary OAG** with which it is associated (some have more than one answer)

Phacolytic glaucoma **Phacoantigenic glaucoma** **Lens-particle glaucoma**

- aka *phacoanaphylactic glaucoma*: Phacoantigenic
- Usually unilateral: All of them
- Is mediated by an *adaptive* immune response: Phacoantigenic

Q

For each statement, identify the **lens-related secondary OAG** with which it is associated (some have more than one answer)

Phacolytic glaucoma **Phacoantigenic glaucoma** **Lens-particle glaucoma**

- aka *phacoanaphylactic glaucoma*: Phacoantigenic
- Usually unilateral: All of them
- Is mediated by an *adaptive* immune response: Phacoantigenic
- Associated with mature/hypermature cataract:

A

For each statement, identify the **lens-related secondary OAG** with which it is associated (some have more than one answer)

Phacolytic glaucoma **Phacoantigenic glaucoma** **Lens-particle glaucoma**

- aka *phacoanaphylactic glaucoma*: Phacoantigenic
- Usually unilateral: All of them
- Is mediated by an *adaptive* immune response: Phacoantigenic
- Associated with mature/hypermature cataract: Phacolytic

Q

For each statement, identify the **lens-related secondary OAG** with which it is associated (some have more than one answer)

Phacolytic glaucoma **Phacoantigenic glaucoma** **Lens-particle glaucoma**

- aka *phacoanaphylactic glaucoma*: Phacoantigenic
- Usually unilateral: All of them
- Is mediated by an *adaptive* immune response: Phacoantigenic
- Associated with **mature**/hypermature **cataract**: Phacolytic

What is a mature cataract*?*

Q/A

For each statement, identify the **lens-related secondary OAG** with which it is associated (some have more than one answer)

Phacolytic glaucoma **Phacoantigenic glaucoma** **Lens-particle glaucoma**

- aka *phacoanaphylactic glaucoma*: Phacoantigenic
- Usually unilateral: All of them
- Is mediated by an *adaptive* immune response: Phacoantigenic
- Associated with **mature**/hypermature **cataract**: Phacolytic

What is a mature cataract*?*

A [nuclear vs cortical vs PSC] cataract that has progressed to involve the entire lens [nucleus vs cortex vs PC]

A

For each statement, identify the **lens-related secondary OAG** with which it is associated (some have more than one answer)

Phacolytic glaucoma **Phacoantigenic glaucoma** **Lens-particle glaucoma**

- aka *phacoanaphylactic glaucoma*: Phacoantigenic
- Usually unilateral: All of them
- Is mediated by an *adaptive* immune response: Phacoantigenic
- Associated with **mature**/hypermature **cataract**: Phacolytic

What is a mature cataract*?*

A cortical cataract that has progressed to involve the entire lens cortex

For each statement, identify the **lens-related secondary OAG** with which it is associated (some have more than one answer)

Phacolytic glaucoma **Phacoantigenic glaucoma** **Lens-particle glaucoma**

Mature cataract

Q

For each statement, identify the **lens-related secondary OAG** with which it is associated (some have more than one answer)

Phacolytic glaucoma **Phacoantigenic glaucoma** **Lens-particle glaucoma**

- aka *phacoanaphylactic glaucoma*: Phacoantigenic
- Usually unilateral: All of them
- Is mediated by an *adaptive* immune response: Phacoantigenic
- Associated with mature/**hypermature cataract**: Phacolytic

What is a mature cataract*?*
A cortical cataract that has progressed to involve the entire lens cortex

What is a hypermature cataract*?*

Q/A

For each statement, identify the **lens-related secondary OAG** with which it is associated (some have more than one answer)

Phacolytic glaucoma **Phacoantigenic glaucoma** **Lens-particle glaucoma**

- aka *phacoanaphylactic glaucoma*: Phacoantigenic
- Usually unilateral: All of them
- Is mediated by an *adaptive* immune response: Phacoantigenic
- Associated with mature/**hypermature cataract**: Phacolytic

What is a mature cataract*?*
A cortical cataract that has progressed to involve the entire lens cortex

What is a hypermature cataract*?*
Mature cataracts may absorb water, transforming them into an swole *cortical cataract*.

A

For each statement, identify the **lens-related secondary OAG** with which it is associated (some have more than one answer)

Phacolytic glaucoma **Phacoantigenic glaucoma** **Lens-particle glaucoma**

- aka *phacoanaphylactic glaucoma*: Phacoantigenic
- Usually unilateral: All of them
- Is mediated by an *adaptive* immune response: Phacoantigenic
- Associated with mature/**hypermature cataract**: Phacolytic

What is a mature cataract*?*
A cortical cataract that has progressed to involve the entire lens cortex

What is a hypermature cataract*?*
Mature cataracts may absorb water, transforming them into an *intumescent cortical cataract*.

A

For each statement, identify the **lens-related secondary OAG** with which it is associated (some have more than one answer)

Phacolytic glaucoma **Phacoantigenic glaucoma** **Lens-particle glaucoma**

- aka *phacoanaphylactic glaucoma*: Phacoantigenic
- Usually unilateral: All of them
- Is mediated by an *adaptive* immune response: Phacoantigenic
- Associated with mature/**hypermature cataract**: Phacolytic

What is a mature cataract*?*
A cortical cataract that has progressed to involve the entire lens cortex

What is a hypermature cataract*?*
Mature cataracts may absorb water, transforming them into an *intumescent cortical cataract*. A *hypermature cataract* results when an intumescent cataract begins leaking water and denatured proteins through its intact anterior capsule.

Q

For each statement, identify the **lens-related secondary OAG** with which it is associated (some have more than one answer)

Phacolytic glaucoma **Phacoantigenic glaucoma** **Lens-particle glaucoma**

- aka *phacoanaphylactic glaucoma*: Phacoantigenic
- Usually unilateral: All of them
- Is mediated by an *adaptive* immune response: Phacoantigenic
- Associated with mature/**hypermature cataract**: Phacolytic

What effect does the leaking of water and proteins have on the volume of the cataract?

intumescent cortical cataract. A *hypermature cataract* results when an intumescent cataract begins **leaking water and denatured proteins through its intact anterior capsule.**

A

For each statement, identify the **lens-related secondary OAG** with which it is associated (some have more than one answer)

Phacolytic glaucoma **Phacoantigenic glaucoma** **Lens-particle glaucoma**

- aka *phacoanaphylactic glaucoma*: Phacoantigenic
- Usually unilateral: All of them
- Is mediated by an *adaptive* immune response: Phacoantigenic
- Associated with mature/**hypermature cataract**: Phacolytic

What effect does the leaking of water and proteins have on the volume of the cataract?
It reduces it significantly

intumescent cortical cataract. A *hypermature cataract* results when an intumescent cataract begins **leaking water and denatured proteins through its intact anterior capsule.**

Q

For each statement, identify the **lens-related secondary OAG** with which it is associated (some have more than one answer)

Phacolytic glaucoma **Phacoantigenic glaucoma** **Lens-particle glaucoma**

- aka *phacoanaphylactic glaucoma*: Phacoantigenic
- Usually unilateral: All of them
- Is mediated by an *adaptive* immune response: Phacoantigenic
- Associated with mature/**hypermature cataract**: Phacolytic

What effect does the leaking of water and proteins have on the volume of the cataract?
It reduces it significantly

This reduction in cataract volume is responsible for a classic finding in hypermature cataracts. What is it?

intumescent cortical cataract. A *hypermature cataract* results when an intumescent cataract begins **leaking water and denatured proteins through its intact anterior capsule.**

Q/A

For each statement, identify the **lens-related secondary OAG** with which it is associated (some have more than one answer)

Phacolytic glaucoma **Phacoantigenic glaucoma** **Lens-particle glaucoma**

- aka *phacoanaphylactic glaucoma*: Phacoantigenic
- Usually unilateral: All of them
- Is mediated by an *adaptive* immune response: Phacoantigenic
- Associated with mature/**hypermature cataract**: Phacolytic

What effect does the leaking of water and proteins have on the volume of the cataract?
It reduces it significantly

This reduction in cataract volume is responsible for a classic finding in hypermature cataracts. What is it?
The anterior capsule is *sign* and *sign*

intumescent cortical cataract. A *hypermature cataract* results when an intumescent cataract begins **leaking water and denatured proteins through its intact anterior capsule.**

A

For each statement, identify the **lens-related secondary OAG** with which it is associated (some have more than one answer)

Phacolytic glaucoma **Phacoantigenic glaucoma** **Lens-particle glaucoma**

- aka *phacoanaphylactic glaucoma*: Phacoantigenic
- Usually unilateral: All of them
- Is mediated by an *adaptive* immune response: Phacoantigenic
- Associated with mature/**hypermature cataract**: Phacolytic

What effect does the leaking of water and proteins have on the volume of the cataract?
It reduces it significantly

This reduction in cataract volume is responsible for a classic finding in hypermature cataracts. What is it?
The anterior capsule is shrunken and wrinkled

intumescent cortical cataract. A *hypermature cataract* results when an intumescent cataract begins **leaking water and denatured proteins through its intact anterior capsule.**

For each statement, identify the **lens-related secondary OAG** with which it is associated (some have more than one answer)

Phacolytic glaucoma **Phacoantigenic glaucoma** **Lens-particle glaucoma**

Hypermature cataract. Note the capsular wrinkling

Q

For each statement, identify the **lens-related secondary OAG** with which it is associated (some have more than one answer)

Phacolytic glaucoma **Phacoantigenic glaucoma** **Lens-particle glaucoma**

- aka *phacoanaphylactic glaucoma*: Phacoantigenic
- Usually unilateral: All of them
- Is mediated by an *adaptive* immune response: Phacoantigenic
- Associated with mature/**hypermature cataract**: Phacolytic

What is a **mature cataract***?*
A cortical cataract that has progressed to involve the entire lens cortex

What is a hypermature cataract*?*
Mature cataracts may absorb water, transforming them into an *intumescent cortical cataract*. A *hypermature cataract* results when an intumescent cataract begins leaking water and denatured proteins through its intact anterior capsule.

Take note of the stages:

Mature cataract → ***?***

A/Q

For each statement, identify the **lens-related secondary OAG** with which it is associated (some have more than one answer)

Phacolytic glaucoma **Phacoantigenic glaucoma** **Lens-particle glaucoma**

- aka *phacoanaphylactic glaucoma*: Phacoantigenic
- Usually unilateral: All of them
- Is mediated by an *adaptive* immune response: Phacoantigenic
- Associated with mature/**hypermature cataract**: Phacolytic

What is a **mature cataract***?*
A cortical cataract that has progressed to involve the entire lens cortex

What is a hypermature cataract*?*
Mature cataracts may absorb water, transforming them into an ***intumescent cortical cataract***. A *hypermature cataract* results when an intumescent cataract begins leaking water and denatured proteins through its intact anterior capsule.

Take note of the stages:

Mature cataract → intumescent cataract → ***?***

A

For each statement, identify the **lens-related secondary OAG** with which it is associated (some have more than one answer)

Phacolytic glaucoma **Phacoantigenic glaucoma** **Lens-particle glaucoma**

- aka *phacoanaphylactic glaucoma*: Phacoantigenic
- Usually unilateral: All of them
- Is mediated by an *adaptive* immune response: Phacoantigenic
- Associated with mature/**hypermature cataract**: Phacolytic

What is a **mature cataract***?*
A cortical cataract that has progressed to involve the entire lens cortex

What is a hypermature cataract*?*
Mature cataracts may absorb water, transforming them into an ***intumescent cortical cataract***. A ***hypermature cataract*** results when an intumescent cataract begins leaking water and denatured proteins through its intact anterior capsule.

Take note of the stages:

Mature cataract → intumescent cataract → hypermature cataract

Q

For each statement, identify the **lens-related secondary OAG** with which it is associated (some have more than one answer)

Phacolytic glaucoma **Phacoantigenic glaucoma** **Lens-particle glaucoma**

- aka *phacoanaphylactic glaucoma*: Phacoantigenic
- Usually unilateral: All of them
- Is mediated by an *adaptive* immune response: Phacoantigenic
- Associated with mature/**hypermature cataract**: Phacolytic

What is a **mature cataract***?*
A cortical cataract that has progressed to involve the entire lens cortex

What is a hypermature cataract*?*
Mature cataracts may absorb water, transforming them into an ***intumescent cortical cataract***. A ***hypermature cataract*** results when an intumescent cataract begins leaking water and denatured proteins through its intact anterior capsule.

Take note of the stages:

A

For each statement, identify the **lens-related secondary OAG** with which it is associated (some have more than one answer)

Phacolytic glaucoma **Phacoantigenic glaucoma** **Lens-particle glaucoma**

- aka *phacoanaphylactic glaucoma*: Phacoantigenic
- Usually unilateral: All of them
- Is mediated by an *adaptive* immune response: Phacoantigenic
- Associated with mature/**hypermature cataract**: Phacolytic

What is a **mature cataract***?*
A cortical cataract that has progressed to involve the entire lens cortex

What is a hypermature cataract*?*
Mature cataracts may **absorb water**, transforming them into an ***intumescent cortical cataract***. A ***hypermature cataract*** results when an intumescent cataract begins leaking water and denatured proteins through its intact anterior capsule.

Take note of the stages:

Mature cataract → intumescent cataract → hypermature cataract

Cataract ***absorbs*** water ← *What happens*

Q

For each statement, identify the **lens-related secondary OAG** with which it is associated (some have more than one answer)

Phacolytic glaucoma **Phacoantigenic glaucoma** **Lens-particle glaucoma**

- aka *phacoanaphylactic glaucoma*: Phacoantigenic
- Usually unilateral: All of them
- Is mediated by an *adaptive* immune response: Phacoantigenic
- Associated with mature/**hypermature cataract**: Phacolytic

What is a **mature cataract***?*
A cortical cataract that has progressed to involve the entire lens cortex

What is a hypermature cataract*?*
Mature cataracts may **absorb water**, transforming them into an ***intumescent cortical cataract***. A ***hypermature cataract*** results when an intumescent cataract begins leaking water and denatured proteins through its intact anterior capsule.

Take note of the stages:

Mature cataract → intumescent cataract → hypermature cataract

Cataract ***absorbs*** water ← *What happens* → Cataract [ ] water

A

For each statement, identify the **lens-related secondary OAG** with which it is associated (some have more than one answer)

Phacolytic glaucoma **Phacoantigenic glaucoma** **Lens-particle glaucoma**

- aka *phacoanaphylactic glaucoma*: Phacoantigenic
- Usually unilateral: All of them
- Is mediated by an *adaptive* immune response: Phacoantigenic
- Associated with mature/**hypermature cataract**: Phacolytic

What is a **mature cataract***?*
A cortical cataract that has progressed to involve the entire lens cortex

What is a hypermature cataract*?*
Mature cataracts may **absorb water**, transforming them into an ***intumescent cortical cataract***. A ***hypermature cataract*** results when an intumescent cataract begins **leaking water** and denatured proteins through its intact anterior capsule.

Take note of the stages:

Mature cataract → intumescent cataract → hypermature cataract

Cataract ***absorbs*** water ← *What happens* → Cataract ***leaks*** water*

*and proteins

Q

For each statement, identify the **lens-related secondary OAG** with which it is associated (some have more than one answer)

Phacolytic glaucoma **Phacoantigenic glaucoma** **Lens-particle glaucoma**

- aka *phacoanaphylactic glaucoma*: Phacoantigenic
- Usually unilateral: All of them
- Is mediated by an *adaptive* immune response: Phacoantigenic
- Associated with mature/**hypermature cataract**: Phacolytic

All three of these pose a particular challenge during an early, crucial step in cataract surgery. What step, and what challenge?

Take note of the stages:

Mature cataract → intumescent cataract → hypermature cataract

A

For each statement, identify the **lens-related secondary OAG** with which it is associated (some have more than one answer)

Phacolytic glaucoma **Phacoantigenic glaucoma** **Lens-particle glaucoma**

- aka *phacoanaphylactic glaucoma*: Phacoantigenic
- Usually unilateral: All of them
- Is mediated by an *adaptive* immune response: Phacoantigenic
- Associated with mature/**hypermature cataract**: Phacolytic

All three of these pose a particular challenge during an early, crucial step in cataract surgery. What step, and what challenge?

For all three stages, the red reflex is completely obscured. As most cataract surgeons rely on the red reflex to visualize the anterior capsule during capsulorrhexis, this step cannot be performed in a conventional manner.

Take note of the stages:

Mature cataract → intumescent cataract → hypermature cataract

Q

For each statement, identify the **lens-related secondary OAG** with which it is associated (some have more than one answer)

Phacolytic glaucoma **Phacoantigenic glaucoma** **Lens-particle glaucoma**

- aka *phacoanaphylactic glaucoma*: Phacoantigenic
- Usually unilateral: All of them
- Is mediated by an *adaptive* immune response: Phacoantigenic
- Associated with mature/**hypermature cataract**: Phacolytic

All three of these pose a particular challenge during an early, crucial step in cataract surgery. What step, and what challenge?

For all three stages, the red reflex is completely obscured. As most cataract surgeons rely on the red reflex to visualize the anterior capsule during capsulorrhexis, this step cannot be performed in a conventional manner.

What step do most surgeons take to facilitate capsulorrhexis in these cases?

Take note of the stages:

Mature cataract → intumescent cataract → hypermature cataract

Q/A

For each statement, identify the **lens-related secondary OAG** with which it is associated (some have more than one answer)

Phacolytic glaucoma **Phacoantigenic glaucoma** **Lens-particle glaucoma**

- aka *phacoanaphylactic glaucoma*: Phacoantigenic
- Usually unilateral: All of them
- Is mediated by an *adaptive* immune response: Phacoantigenic
- Associated with mature/**hypermature cataract**: Phacolytic

All three of these pose a particular challenge during an early, crucial step in cataract surgery. What step, and what challenge?

For all three stages, the red reflex is completely obscured. As most cataract surgeons rely on the red reflex to visualize the anterior capsule during capsulorrhexis, this step cannot be performed in a conventional manner.

What step do most surgeons take to facilitate capsulorrhexis in these cases?

They stain the anterior capsule with [two words]

Take note of the stages:

Mature cataract → intumescent cataract → hypermature cataract

A

For each statement, identify the **lens-related secondary OAG** with which it is associated (some have more than one answer)

Phacolytic glaucoma **Phacoantigenic glaucoma** **Lens-particle glaucoma**

- aka *phacoanaphylactic glaucoma*: Phacoantigenic
- Usually unilateral: All of them
- Is mediated by an *adaptive* immune response: Phacoantigenic
- Associated with mature/**hypermature cataract**: Phacolytic

All three of these pose a particular challenge during an early, crucial step in cataract surgery. What step, and what challenge?

For all three stages, the red reflex is completely obscured. As most cataract surgeons rely on the red reflex to visualize the anterior capsule during capsulorrhexis, this step cannot be performed in a conventional manner.

What step do most surgeons take to facilitate capsulorrhexis in these cases?

They stain the anterior capsule with trypan blue

Take note of the stages:

Mature cataract → intumescent cataract → hypermature cataract

Q

For each statement, identify the **lens-related secondary OAG** with which it is associated (some have more than one answer)

Phacolytic glaucoma **Phacoantigenic glaucoma** **Lens-particle glaucoma**

- aka *phacoanaphylactic glaucoma*: Phacoantigenic
- Usually unilateral: All of them
- Is mediated by an *adaptive* immune response: Phacoantigenic
- Associated with mature/**hypermature cataract**: Phacolytic

Let's drill down on intumescent cataracts *for a moment. In this context, what does* intumescent *mean?*

All th … *ery.*
Wha
For a … y on
the r
perfo

What step do most surgeons take to facilitate capsulorrhexis in these cases?
They stain the anterior capsule with trypan blue

Take note of the stages:

Mature cataract → **intumescent cataract** → hypermature cataract

A

For each statement, identify the **lens-related secondary OAG** with which it is associated (some have more than one answer)

Phacolytic glaucoma **Phacoantigenic glaucoma** **Lens-particle glaucoma**

- aka *phacoanaphylactic glaucoma*: Phacoantigenic
- Usually unilateral: All of them
- Is mediated by an *adaptive* immune response: Phacoantigenic
- Associated with mature/**hypermature cataract**: Phacolytic

Let's drill down on intumescent cataracts *for a moment. In this context, what does* intumescent *mean?*
It means 'swollen.' As mentioned a few slides ago, the event that transforms a *mature* cataract into an *intumescent* cataract is absorption of water, and this absorption results in swelling of the lens.

All th ... *ery.*
Wha
For a ... y on
the r
perfo

What step do most surgeons take to facilitate capsulorrhexis in these cases?
They stain the anterior capsule with trypan blue

Take note of the stages:

Mature cataract → **intumescent cataract** → hypermature cataract

Q

For each statement, identify the **lens-related secondary OAG** with which it is associated (some have more than one answer)

Phacolytic glaucoma **Phacoantigenic glaucoma** **Lens-particle glaucoma**

- aka *phacoanaphylactic glaucoma*: Phacoantigenic
- Usually unilateral: All of them
- Is mediated by an *adaptive* immune response: Phacoantigenic
- Associated with mature/**hypermature cataract**: Phacolytic

Let's drill down on intumescent cataracts *for a moment. In this context, what does* intumescent *mean?*
It means 'swollen.' As mentioned a few slides ago, the event that transforms a *mature* cataract into an *intumescent* cataract is absorption of water, and this absorption results in swelling of the lens.

What effect does swelling have on the internal dynamics of the lens?

All th ... *ery.*
Wha
For a ... y on
the r
perfo

What step do most surgeons take to facilitate capsulorrhexis in these cases?
They stain the anterior capsule with trypan blue

Take note of the stages:

Mature cataract → **intumescent cataract** → hypermature cataract

A

For each statement, identify the **lens-related secondary OAG** with which it is associated (some have more than one answer)

Phacolytic glaucoma **Phacoantigenic glaucoma** **Lens-particle glaucoma**

- aka *phacoanaphylactic glaucoma*: Phacoantigenic
- Usually unilateral: All of them
- Is mediated by an *adaptive* immune response: Phacoantigenic
- Associated with mature/**hypermature cataract**: Phacolytic

Let's drill down on intumescent cataracts *for a moment. In this context, what does* intumescent *mean?*
It means 'swollen.' As mentioned a few slides ago, the event that transforms a *mature* cataract into an *intumescent* cataract is absorption of water, and this absorption results in swelling of the lens.

What effect does swelling have on the internal dynamics of the lens?
It increases the pressure within the lens

All th ... *ery.*
Wha
For a ... y on
the r
perfo

What step do most surgeons take to facilitate capsulorrhexis in these cases?
They stain the anterior capsule with trypan blue

Take note of the stages:

Mature cataract → **intumescent cataract** → hypermature cataract

Q

For each statement, identify the **lens-related secondary OAG** with which it is associated (some have more than one answer)

Phacolytic glaucoma **Phacoantigenic glaucoma** **Lens-particle glaucoma**

- aka *phacoanaphylactic glaucoma*: Phacoantigenic
- Usually unilateral: All of them
- Is mediated by an *adaptive* immune response: Phacoantigenic
- Associated with mature/**hypermature cataract**: Phacolytic

Let's drill down on intumescent cataracts *for a moment. In this context, what does* intumescent *mean?*

As if obscuration of the red reflex wasn't enough, the increased intralenticular pressure of an intumescent cataract poses an additional challenge during capsulorrhexis—what is it?

What effect does swelling have on the internal dynamics of the lens?

It increases the pressure within the lens

What step do most surgeons take to facilitate capsulorrhexis in these cases?

They stain the anterior capsule with trypan blue

Take note of the stages:

Mature cataract → **intumescent cataract** → hypermature cataract

A

For each statement, identify the **lens-related secondary OAG** with which it is associated (some have more than one answer)

Phacolytic glaucoma **Phacoantigenic glaucoma** **Lens-particle glaucoma**

- aka *phacoanaphylactic glaucoma*: Phacoantigenic
- Usually unilateral: All of them
- Is mediated by an *adaptive* immune response: Phacoantigenic
- Associated with mature/**hypermature cataract**: Phacolytic

Let's drill down on intumescent cataracts *for a moment. In this context, what does* intumescent *mean?*

As if obscuration of the red reflex wasn't enough, the increased intralenticular pressure of an intumescent cataract poses an additional challenge during capsulorrhexis—what is it?
When the surgeon makes the initial rent in the capsule, the increased pressure within an intumescent cataract may cause the rent to suddenly and uncontrollably extend to the periphery

What effect does swelling have on the internal dynamics of the lens?
It **increases the pressure within the lens**

What step do most surgeons take to facilitate capsulorrhexis in these cases?
They stain the anterior capsule with trypan blue

Take note of the stages:

Mature cataract → **intumescent cataract** → hypermature cataract

Q

For each statement, identify the **lens-related secondary OAG** with which it is associated (some have more than one answer)

Phacolytic glaucoma **Phacoantigenic glaucoma** **Lens-particle glaucoma**

- aka *phacoanaphylactic glaucoma*: Phacoantigenic
- Usually unilateral: All of them
- Is mediated by an *adaptive* immune response: Phacoantigenic
- Associated with mature/**hypermature cataract**: Phacolytic

Let's drill down on intumescent cataracts *for a moment. In this context, what does* intumescent *mean?*

As if obscuration of the red reflex wasn't enough, the increased intralenticular pressure of an intumescent cataract poses an additional challenge during capsulorrhexis—what is it?

When the surgeon makes the initial rent in the capsule, the increased pressure within an intumescent cataract may cause **the rent to suddenly and uncontrollably extend to the periphery**

If/when the rent runs peripherally, what is the resulting appearance of the lens?

ery.

the r y on

perf

Wha

They stain the anterior capsule with trypan blue

Take note of the stages:

Mature cataract → **intumescent cataract** → hypermature cataract

A

For each statement, identify the **lens-related secondary OAG** with which it is associated (some have more than one answer)

Phacolytic glaucoma **Phacoantigenic glaucoma** **Lens-particle glaucoma**

- aka *phacoanaphylactic glaucoma*: Phacoantigenic
- Usually unilateral: All of them
- Is mediated by an *adaptive* immune response: Phacoantigenic
- Associated with mature/**hypermature cataract**: Phacolytic

Let's drill down on intumescent cataracts *for a moment. In this context, what does* intumescent *mean?*

As if obscuration of the red reflex wasn't enough, the increased intralenticular pressure of an intumescent cataract poses an additional challenge during capsulorrhexis—what is it?
When the surgeon makes the initial rent in the capsule, the increased pressure within an intumescent cataract may cause **the rent to suddenly and uncontrollably extend to the periphery**

If/when the rent runs peripherally, what is the resulting appearance of the lens?
Recall that, because of red-reflex obscuration, **trypan blue** is used in all these cases.

Wha

They stain the anterior capsule with **trypan blue**

Take note of the stages:

Mature cataract → **intumescent cataract** → hypermature cataract

A

For each statement, identify the **lens-related secondary OAG** with which it is associated (some have more than one answer)

Phacoantigenic glaucoma **Lens-particle glaucoma**

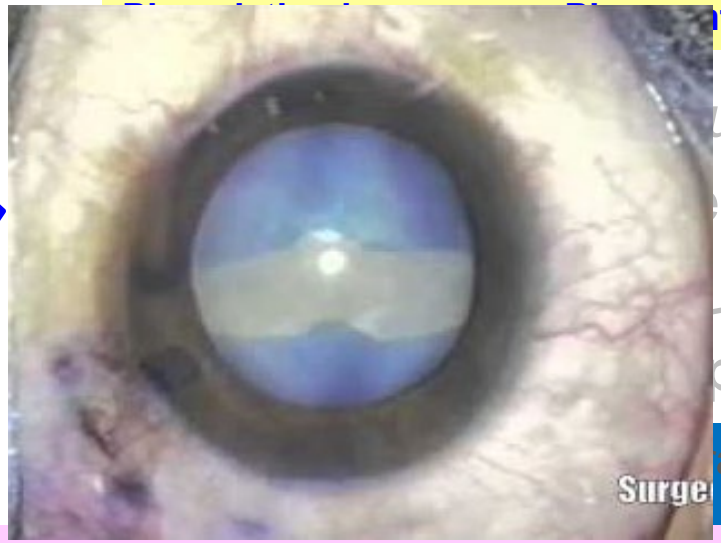

- ucoma: Phacoantigenic
- em
- immune response: Phacoantigenic
- **permature cataract**: Phacolytic

acts for a moment. In this context, what does

As if obscuration of the red reflex wasn't enough, the increased intralenticular pressure of an intumescent cataract poses an additional challenge during capsulorrhexis—what is it?

When the surgeon makes the initial rent in the capsule, the increased pressure within an intumescent cataract may cause **the rent to suddenly and uncontrollably extend to the periphery**

ery.

y on

the r

perfo

If/when the rent runs peripherally, what is the resulting appearance of the lens?

Recall that, because of red-reflex obscuration, **trypan blue** is used in all these cases. Thus, after the rent runs out, the surgeon sees a **white stripe** (the cataract) between **two areas of blue** (the undisturbed, trypan blue-stained capsule).

Wha

They stain the anterior capsule with **trypan blue**

Take note of the stages:

Mature cataract → **intumescent cataract** → hypermature cataract

Q

For each statement, identify the **lens-related secondary OAG** with which it is associated (some have more than one answer)

Phacoantigenic glaucoma **Lens-particle glaucoma**

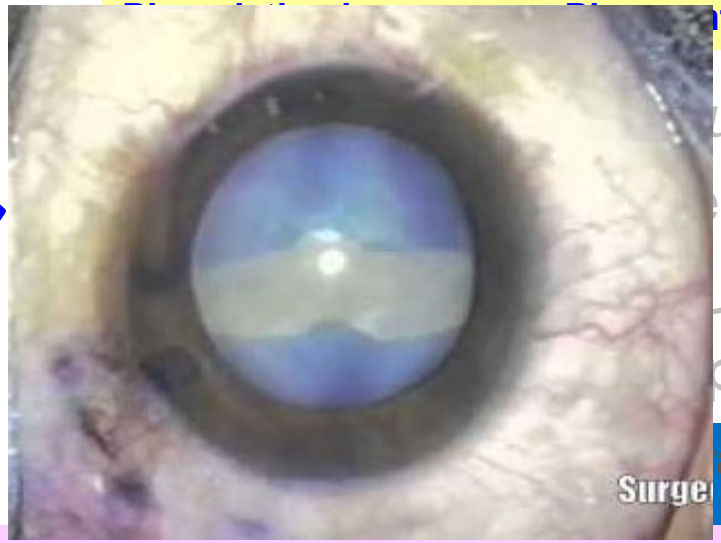

- *ucoma*: Phacoantigenic
- em
- immune response: Phacoantigenic
- **permature cataract**: Phacolytic

acts for a moment. In this context, what does

As if obscuration of the red reflex wasn't enough, the increased intralenticular pressure of an intumesce ... *very.*
When the
intumescent cataract may cause the rent to suddenly and uncontrollably extend to the periphery
y on
the r
perf
Wha
They stain the anterior capsule with **trypan blue**

This appearance has led to a memorable name for this finding. What is it?

If/when the rent runs peripherally, what is the resulting appearance of the lens?
Recall that, because of red-reflex obscuration, **trypan blue** is used in all these cases.
Thus, after the rent runs out, the surgeon sees a **white stripe** (the cataract) between **two areas of blue** (the undisturbed, trypan blue-stained capsule).

Take note of the stages:

Mature cataract → **intumescent cataract** → hypermature cataract

A

For each statement, identify the **lens-related secondary OAG** with which it is associated (some have more than one answer)

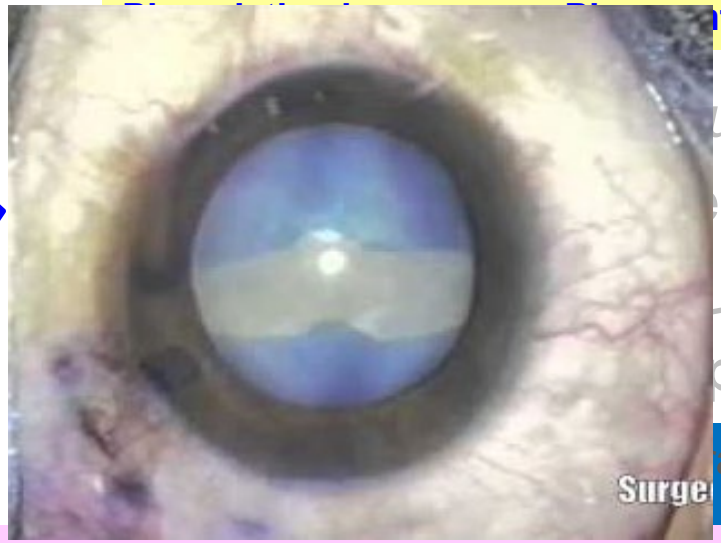

As if obscuration of the red reflex wasn't enough, the increased intralenticular pressure of an intumesce

This appearance has led to a memorable name for this finding. What is it?
It is known as '**Argentinian flag sign**'

If/when the rent runs peripherally, what is the resulting appearance of the lens?
Recall that, because of red-reflex obscuration, **trypan blue** is used in all these cases.
Thus, after the rent runs out, the surgeon sees a **white stripe** (the cataract) between **two areas of blue** (the undisturbed, trypan blue-stained capsule).

They stain the anterior capsule with **trypan blue**

Take note of the stages:

Mature cataract → **intumescent cataract** → hypermature cataract

Q

For each statement, identify the **lens-related secondary OAG** with which it is associated (some have more than one answer)

Phacolytic glaucoma **Phacoantigenic glaucoma** **Lens-particle glaucoma**

- aka *phacoanaphylactic glaucoma*: Phacoantigenic
- Usually unilateral: All of them
- Is mediated by an *adaptive* immune response: Phacoantigenic
- Associated with mature/**hypermature cataract**: Phacolytic

When faced with an intumescent cataract, what can the surgeon do to minimize the likelihood of seeing an Argentinian flag?

--?

--?

When the surgeon makes the initial cut in the capsule, the increased pressure within an intumescent cataract may cause **the rent to suddenly and uncontrollably extend to the periphery**

If/when the rent runs peripherally, what is the resulting appearance of the lens?

Recall that, because of red-reflex obscuration, **trypan blue** is used in all these cases. Thus, after the rent runs out, the surgeon sees a **white stripe** (the cataract) between **two areas of blue** (the undisturbed, trypan blue-stained capsule).

They stain the anterior capsule with **trypan blue**

Take note of the stages:

Mature cataract → **intumescent cataract** → hypermature cataract

A

For each statement, identify the **lens-related secondary OAG** with which it is associated (some have more than one answer)

Phacolytic glaucoma **Phacoantigenic glaucoma** **Lens-particle glaucoma**

- aka *phacoanaphylactic glaucoma*: Phacoantigenic
- Usually unilateral: All of them
- Is mediated by an *adaptive* immune response: Phacoantigenic
- Associated with mature/**hypermature cataract**: Phacolytic

When faced with an intumescent cataract, what can the surgeon do to minimize the likelihood of seeing an Argentinian flag?

--Counteract the positive pressure within the lens by filling the AC with a high-viscosity OVD

--***?***

When the surgeon makes the initial cut in the capsule, the increased pressure within an intumescent cataract may cause **the rent to suddenly and uncontrollably extend to the periphery**

If/when the rent runs peripherally, what is the resulting appearance of the lens?

Recall that, because of red-reflex obscuration, **trypan blue** is used in all these cases. Thus, after the rent runs out, the surgeon sees a **white stripe** (the cataract) between **two areas of blue** (the undisturbed, trypan blue-stained capsule).

Wha

They stain the anterior capsule with **trypan blue**

Take note of the stages:

Mature cataract → **intumescent cataract** → hypermature cataract

A

For each statement, identify the **lens-related secondary OAG** with which it is associated (some have more than one answer)

Phacolytic glaucoma **Phacoantigenic glaucoma** **Lens-particle glaucoma**

- aka *phacoanaphylactic glaucoma*: Phacoantigenic
- Usually unilateral: All of them
- Is mediated by an *adaptive* immune response: Phacoantigenic
- Associated with mature/**hypermature cataract**: Phacolytic

When faced with an intumescent cataract, what can the surgeon do to minimize the likelihood of seeing an Argentinian flag?

--Counteract the positive pressure within the lens by filling the AC with a high-viscosity OVD

--Reduce intralenticular pressure by aspirating cortical material immediately upon creating the initial rent

When the surgeon makes the initial rent in the capsule, the increased pressure within an intumescent cataract may cause **the rent to suddenly and uncontrollably extend to the periphery**

If/when the rent runs peripherally, what is the resulting appearance of the lens?

Recall that, because of red-reflex obscuration, **trypan blue** is used in all these cases. Thus, after the rent runs out, the surgeon sees a **white stripe** (the cataract) between **two areas of blue** (the undisturbed, trypan blue-stained capsule).

They stain the anterior capsule with **trypan blue**

Take note of the stages:

Mature cataract → **intumescent cataract** → hypermature cataract

Q

For each statement, identify the **lens-related secondary OAG** with which it is associated (some have more than one answer)

Phacolytic glaucoma **Phacoantigenic glaucoma** **Lens-particle glaucoma**

- aka *phacoanaphylactic glaucoma*: Phacoantigenic
- Usually unilateral: All of them
- Is mediated by an *adaptive* immune response: Phacoantigenic
- Associated with mature/**hypermature cataract**: Phacolytic

Next question

What is a **matur**
A cortical cataract that has progressed to involve the e lens cortex

What is a hypermature cataract*?*
Mature cataracts may absorb water, transforming th n
intumescent cortical cataract. A ***hypermature cata*** results when an
intumescent cataract beg
its intact anterior capsule.

Finally: What stage occurs after *the hypermature stage?*

Take note of the stages:

Mature cataract → intumescent cataract → hypermature cataract → ?

A

For each statement, identify the **lens-related secondary OAG** with which it is associated (some have more than one answer)

Phacolytic glaucoma **Phacoantigenic glaucoma** **Lens-particle glaucoma**

- aka *phacoanaphylactic glaucoma*: Phacoantigenic
- Usually unilateral: All of them
- Is mediated by an *adaptive* immune response: Phacoantigenic
- Associated with mature/**hypermature cataract**: Phacolytic

What is a **mature cataract***?*
A cortical cataract that has progressed to involve the entire lens cortex

What is a hypermature cataract*?*
Mature cataracts may absorb water, transforming them into an ***intumescent cortical cataract***. A ***hypermature cataract*** results when an intumescent cataract begins leaking water and denatured proteins through its intact anterior capsule.

Finally: What stage occurs after *the hypermature stage?*

Take note of the stages:

Morganian cataract

Mature cataract → intumescent cataract → hypermature cataract ^

Q

For each statement, identify the **lens-related secondary OAG** with which it is associated (some have more than one answer)

Phacolytic glaucoma **Phacoantigenic glaucoma** **Lens-particle glaucoma**

- aka *phacoanaphylactic glaucoma*: Phacoantigenic
- Usually unilateral: All of them
- Is mediated by an *adaptive* immune response: Phacoantigenic
- Associated with mature/**hypermature cataract**: Phacolytic

What is a **mature cataract***?*
A cortical cataract that has progressed to involve the entire lens cortex

What is a hypermature cataract*?*
Mature cataracts may absorb water, transforming them into an ***intumescent cortical cataract***. A ***hypermature cataract*** results when an intumescent cataract begins leaking water and denatured proteins through its intact ant

What change occurs as a cortical cataract progresses from the hypermature *to the* morgagnian *stage?*

mature stage?

Morganian cataract

Take note of the stag

Mature cataract

re cataract

A

For each statement, identify the **lens-related secondary OAG** with which it is associated (some have more than one answer)

Phacolytic glaucoma **Phacoantigenic glaucoma** **Lens-particle glaucoma**

- aka *phacoanaphylactic glaucoma*: Phacoantigenic
- Usually unilateral: All of them
- Is mediated by an *adaptive* immune response: Phacoantigenic
- Associated with mature/**hypermature cataract**: Phacolytic

What is a **mature cataract***?*
A cortical cataract that has progressed to involve the entire lens cortex

What is a hypermature cataract*?*
Mature cataracts may absorb water, transforming them into an ***intumescent cortical cataract***. A ***hypermature cataract*** results when an intumescent cataract begins leaking water and denatured proteins through its intact ant

What change occurs as a cortical cataract progresses from the hypermature *to the* morgagnian *stage?*
Further and extensive liquefaction of the cortical material

mature stage?

Take note of the stag

Morganian cataract

Mature cataract

re cataract

Q

For each statement, identify the **lens-related secondary OAG** with which it is associated (some have more than one answer)

Phacolytic glaucoma **Phacoantigenic glaucoma** **Lens-particle glaucoma**

- aka *phacoanaphylactic glaucoma*: Phacoantigenic
- Usually unilateral: All of them
- Is mediated by an *adaptive* immune response: Phacoantigenic
- Associated with mature/**hypermature cataract**: Phacolytic

What is a **mature cataract***?*
A cortical cataract that has progressed to involve the entire lens cortex

What is a hypermature cataract*?*
Mature cataracts may absorb water, transforming them into an ***intumescent cortical cataract***. A ***hypermature cataract*** results when an intumescent cataract begins leaking water and denatured proteins through its intact ant

mature stage?

Take note of the stag

Morganian cataract

Mature cataract

re cataract

What change occurs as a cortical cataract progresses from the hypermature *to the* morgagnian *stage?*
Further and extensive liquefaction of the cortical material

What is the slit-lamp appearance of a morgagnian cataract?

A

For each statement, identify the **lens-related secondary OAG** with which it is associated (some have more than one answer)

Phacolytic glaucoma **Phacoantigenic glaucoma** **Lens-particle glaucoma**

- aka *phacoanaphylactic glaucoma*: Phacoantigenic
- Usually unilateral: All of them
- Is mediated by an *adaptive* immune response: Phacoantigenic
- Associated with mature/**hypermature cataract**: Phacolytic

What is a **mature cataract***?*
A cortical cataract that has progressed to involve the entire lens cortex

What is a hypermature cataract*?*
Mature cataracts may absorb water, transforming them into an ***intumescent cortical cataract***. A ***hypermature cataract*** results when an intumescent cataract begins leaking water and denatured proteins through its intact ant

What change occurs as a cortical cataract progresses from the hypermature *to the* morgagnian *stage?*
Further and extensive liquefaction of the cortical material

What is the slit-lamp appearance of a morgagnian cataract?
The dense brown nuclear cataract is observed to be freely mobile within the liquified remnants of the cortical cataract

mature stage?

Morganian cataract

Take note of the stag

Mature cataract

re cataract

For each statement, identify the **lens-related secondary OAG** with which it is associated (some have more than one answer)

Phacolytic glaucoma **Phacoantigenic glaucoma** **Lens-particle glaucoma**

Morgagnian cataract

Q

For each statement, identify the **lens-related secondary OAG** with which it is associated (some have more than one answer)

Phacolytic glaucoma **Phacoantigenic glaucoma** **Lens-particle glaucoma**

- aka *phacoanaphylactic glaucoma*: Phacoantigenic
- Usually unilateral: All of them
- Is mediated by an *adaptive* immune response: Phacoantigenic
- Associated with mature/hypermature cataract: Phacolytic
- Vitritis may be present:

A

For each statement, identify the **lens-related secondary OAG** with which it is associated (some have more than one answer)

Phacolytic glaucoma **Phacoantigenic glaucoma** **Lens-particle glaucoma**

- aka *phacoanaphylactic glaucoma*: Phacoantigenic
- Usually unilateral: All of them
- Is mediated by an *adaptive* immune response: Phacoantigenic
- Associated with mature/hypermature cataract: Phacolytic
- Vitritis may be present: Phacoantigenic

Q

For each statement, identify the **lens-related secondary OAG** with which it is associated (some have more than one answer)

Phacolytic glaucoma **Phacoantigenic glaucoma** **Lens-particle glaucoma**

- aka *phacoanaphylactic glaucoma*: Phacoantigenic
- Usually unilateral: All of them
- Is mediated by an *adaptive* immune response: Phacoantigenic
- Associated with mature/hypermature cataract: Phacolytic
- Vitritis may be present: Phacoantigenic
- Gonioscopy reveals cortical material in the angle:

A

For each statement, identify the **lens-related secondary OAG** with which it is associated (some have more than one answer)

Phacolytic glaucoma **Phacoantigenic glaucoma** **Lens-particle glaucoma**

- aka *phacoanaphylactic glaucoma*: Phacoantigenic
- Usually unilateral: All of them
- Is mediated by an *adaptive* immune response: Phacoantigenic
- Associated with mature/hypermature cataract: Phacolytic
- Vitritis may be present: Phacoantigenic
- Gonioscopy reveals cortical material in the angle: Lens particle

Q

For each statement, identify the **lens-related secondary OAG** with which it is associated (some have more than one answer)

Phacolytic glaucoma **Phacoantigenic glaucoma** **Lens-particle glaucoma**

- aka *phacoanaphylactic glaucoma*: Phacoantigenic
- Usually unilateral: All of them
- Is mediated by an *adaptive* immune response: Phacoantigenic
- Associated with mature/hypermature cataract: Phacolytic
- Vitritis may be present: Phacoantigenic
- Gonioscopy reveals cortical material in the angle: **Lens particle**

How should lens-particle glaucoma be managed?

A

For each statement, identify the **lens-related secondary OAG** with which it is associated (some have more than one answer)

Phacolytic glaucoma **Phacoantigenic glaucoma** **Lens-particle glaucoma**

- aka *phacoanaphylactic glaucoma*: Phacoantigenic
- Usually unilateral: All of them
- Is mediated by an *adaptive* immune response: Phacoantigenic
- Associated with mature/hypermature cataract: Phacolytic
- Vitritis may be present: Phacoantigenic
- Gonioscopy reveals cortical material in the angle: **Lens particle**

How should lens-particle glaucoma be managed?

If possible, medical management should be employed to control the inflammation and IOP until the eye can absorb the inciting lens material

Q

For each statement, identify the **lens-related secondary OAG** with which it is associated (some have more than one answer)

Phacolytic glaucoma **Phacoantigenic glaucoma** **Lens-particle glaucoma**

- aka *phacoanaphylactic glaucoma*: Phacoantigenic
- Usually unilateral: All of them
- Is mediated by an *adaptive* immune response: Phacoantigenic
- Associated with mature/hypermature cataract: Phacolytic
- Vitritis may be present: Phacoantigenic
- Gonioscopy reveals cortical material in the angle: **Lens particle**

How should lens-particle glaucoma be managed?

If possible, medical management should be employed to control the inflammation and IOP until the eye can absorb the inciting lens material

If medical management proves inadequate, what is the next step?

A

For each statement, identify the **lens-related secondary OAG** with which it is associated (some have more than one answer)

Phacolytic glaucoma **Phacoantigenic glaucoma** **Lens-particle glaucoma**

- aka *phacoanaphylactic glaucoma*: Phacoantigenic
- Usually unilateral: All of them
- Is mediated by an *adaptive* immune response: Phacoantigenic
- Associated with mature/hypermature cataract: Phacolytic
- Vitritis may be present: Phacoantigenic
- Gonioscopy reveals cortical material in the angle: **Lens particle**

How should lens-particle glaucoma be managed?
If possible, medical management should be employed to control the inflammation and IOP until the eye can absorb the inciting lens material

If medical management proves inadequate, what is the next step?
Surgical removal of the offending material

Q

For each statement, identify the **lens-related secondary OAG** with which it is associated (some have more than one answer)

Phacolytic glaucoma **Phacoantigenic glaucoma** **Lens-particle glaucoma**

- aka *phacoanaphylactic glaucoma*: Phacoantigenic
- Usually unilateral: All of them
- Is mediated by an *adaptive* immune response: Phacoantigenic
- Associated with mature/hypermature cataract: Phacolytic
- Vitritis may be present: Phacoantigenic
- Gonioscopy reveals cortical material in the angle: Lens particle
- Least likely to develop elevated IOP:

A

For each statement, identify the **lens-related secondary OAG** with which it is associated (some have more than one answer)

Phacolytic glaucoma **Phacoantigenic glaucoma** **Lens-particle glaucoma**

- aka *phacoanaphylactic glaucoma*: Phacoantigenic
- Usually unilateral: All of them
- Is mediated by an *adaptive* immune response: Phacoantigenic
- Associated with mature/hypermature cataract: Phacolytic
- Vitritis may be present: Phacoantigenic
- Gonioscopy reveals cortical material in the angle: Lens particle
- Least likely to develop elevated IOP: Phacoantigenic

Q

For each statement, identify the **lens-related secondary OAG** with which it is associated (some have more than one answer)

Phacolytic glaucoma **Phacoantigenic glaucoma** **Lens-particle glaucoma**

- aka *phacoanaphylactic glaucoma*: Phacoantigenic
- Usually unilateral: All of them
- Is mediated by an *adaptive* immune response: Phacoantigenic
- Associated with mature/hypermature cataract: Phacolytic
- Vitritis may be present: Phacoantigenic
- Gonioscopy reveals cortical material in the angle: Lens particle
- Least likely to develop elevated IOP: Phacoantigenic
- Is mediated by an *innate* immune response:

A

For each statement, identify the **lens-related secondary OAG** with which it is associated (some have more than one answer)

Phacolytic glaucoma **Phacoantigenic glaucoma** **Lens-particle glaucoma**

- aka *phacoanaphylactic glaucoma*: Phacoantigenic
- Usually unilateral: All of them
- Is mediated by an *adaptive* immune response: Phacoantigenic
- Associated with mature/hypermature cataract: Phacolytic
- Vitritis may be present: Phacoantigenic
- Gonioscopy reveals cortical material in the angle: Lens particle
- Least likely to develop elevated IOP: Phacoantigenic
- Is mediated by an *innate* immune response: Phacolytic

Q

For each statement, identify the **lens-related secondary OAG** with which it is associated (some have more than one answer)

Phacolytic glaucoma **Phacoantigenic glaucoma** **Lens-particle glaucoma**

- aka *phacoanaphylactic glaucoma*: Phacoantigenic
- Usually unilateral: All of them
- Is mediated by an *adaptive* immune response: Phacoantigenic
- Associated with mature/hypermature cataract: Phacolytic
- Vitritis may be present: Phacoantigenic
- Gonioscopy reveals cortical material in the angle: Lens particle
- Least likely to develop elevated IOP: Phacoantigenic
- Is mediated by an *innate* immune response: Phacolytic

There are two broad categories of immune response—what are they?

A

For each statement, identify the **lens-related secondary OAG** with which it is associated (some have more than one answer)

Phacolytic glaucoma **Phacoantigenic glaucoma** **Lens-particle glaucoma**

- aka *phacoanaphylactic glaucoma*: Phacoantigenic
- Usually unilateral: All of them
- Is mediated by an ***adaptive*** immune response: Phacoantigenic
- Associated with mature/hypermature cataract: Phacolytic
- Vitritis may be present: Phacoantigenic
- Gonioscopy reveals cortical material in the angle: Lens particle
- Least likely to develop elevated IOP: Phacoantigenic
- Is mediated by an ***innate*** immune response: Phacolytic

There are two broad categories of immune response—what are they?
Innate and **adaptive**

Q

For each statement, identify the **lens-related secondary OAG** with which it is associated (some have more than one answer)

Phacolytic glaucoma **Phacoantigenic glaucoma** **Lens-particle glaucoma**

- aka *phacoanaphylactic glaucoma*: Phacoantigenic
- Usually unilateral: All of them
- Is mediated by an ***adaptive*** immune response: Phacoantigenic
- Associated with mature/hypermature cataract: Phacolytic
- Vitritis may be present: Phacoantigenic
- Gonioscopy reveals cortical material in the angle: Lens particle
- Least likely to develop elevated IOP: Phacoantigenic
- Is mediated by an ***innate*** immune response: Phacolytic

There are two broad categories of immune response—what are they?
Innate and **adaptive**

In general, what is the nature of each, and how do they differ?

A

For each statement, identify the **lens-related secondary OAG** with which it is associated (some have more than one answer)

Phacolytic glaucoma **Phacoantigenic glaucoma** **Lens-particle glaucoma**

- aka *phacoanaphylactic glaucoma*: Phacoantigenic
- Usually unilateral: All of them
- Is mediated by an ***adaptive*** immune response: Phacoantigenic
- Associated with mature/hypermature cataract: Phacolytic
- Vitritis may be present: Phacoantigenic
- Gonioscopy reveals cortical material in the angle: Lens particle
- Least likely to develop elevated IOP: Phacoantigenic
- Is mediated by an ***innate*** immune response: Phacolytic

There are two broad categories of immune response—what are they?
Innate and **adaptive**

In general, what is the nature of each, and how do they differ?
The adaptive immune response involves 'education,' with surveillance cells learning to recognize and remember foreign material.

A

For each statement, identify the **lens-related secondary OAG** with which it is associated (some have more than one answer)

Phacolytic glaucoma **Phacoantigenic glaucoma** **Lens-particle glaucoma**

- aka *phacoanaphylactic glaucoma*: Phacoantigenic
- Usually unilateral: All of them
- Is mediated by an ***adaptive*** immune response: Phacoantigenic
- Associated with mature/hypermature cataract: Phacolytic
- Vitritis may be present: Phacoantigenic
- Gonioscopy reveals cortical material in the angle: Lens particle
- Least likely to develop elevated IOP: Phacoantigenic
- Is mediated by an ***innate*** immune response: Phacolytic

There are two broad categories of immune response—what are they?
Innate and **adaptive**

In general, what is the nature of each, and how do they differ?
The adaptive immune response involves 'education,' with surveillance cells learning to recognize and remember foreign material. OTOH, the innate (or *natural*) immune response does not require education—it relies on 'preprogrammed' immune cells to recognize foreign material encountered in tissue or blood.

Q

For each statement, identify the **lens-related secondary OAG** with which it is associated (some have more than one answer)

Phacolytic glaucoma **Phacoantigenic glaucoma** **Lens-particle glaucoma**

- aka *phacoanaphylactic glaucoma*: Phacoantigenic
- Usually unilateral: All of them
- Is mediated by an ***adaptive*** immune response: Phacoantigenic
- Associated with mature/hypermature cataract: Phacolytic
- Vitritis may be present: Phacoantigenic
- Gonioscopy reveals cortical material in the angle: Lens particle
- Least likely to develop elevated IOP: Phacoantigenic
- Is mediated by an ***innate*** immune response: Phacolytic

There are two broad categories of immune response—what are they?
Innate and **adaptive**

In general, what is the nature of e
The adaptive immune response involves "education," with surveillance cells learning to recognize and remember foreign material. OTOH, the innate (or *natural*) immune response does not require education—it relies on **'preprogrammed' immune cells** to recognize foreign material encountered in tissue or blood.

What are the two main effector cell types of innate immunity?

A

For each statement, identify the **lens-related secondary OAG** with which it is associated (some have more than one answer)

Phacolytic glaucoma **Phacoantigenic glaucoma** **Lens-particle glaucoma**

- aka *phacoanaphylactic glaucoma*: Phacoantigenic
- Usually unilateral: All of them
- Is mediated by an ***adaptive*** immune response: Phacoantigenic
- Associated with mature/hypermature cataract: Phacolytic
- Vitritis may be present: Phacoantigenic
- Gonioscopy reveals cortical material in the angle: Lens particle
- Least likely to develop elevated IOP: Phacoantigenic
- Is mediated by an ***innate*** immune response: Phacolytic

There are two broad categories of immune response—what are they?
Innate and **adaptive**

In general, what is the nature of e
The adaptive immune response involves "education," with surveillance cells learning to recognize and remember foreign material. OTOH, the innate (or *natural*) immune response does not require education—it relies on **'preprogrammed' immune cells** to recognize foreign material encountered in tissue or blood.

What are the two main effector cell types of innate immunity?
Neutrophils and **macrophages**

For each statement, identify the **lens-related secondary OAG** with which it is associated (some have more than one answer)

<u>And now, an overly long sidebar regarding immunology and the lens-related secondary OAGs</u>: Some clinicians reserve the term *immune response* for clinical situations in which an **adaptive** immune response is involved. That is, if the clinical situation involves only an innate response, such clinicians opt to use the more general term *inflammation* in describing the clinical picture.

ic

e

ity?

For each statement, identify the **lens-related secondary OAG** with which it is associated (some have more than one answer)

<u>And now, an overly long sidebar regarding immunology and the lens-related secondary OAGs</u>: Some clinicians reserve the term *immune response* for clinical situations in which an **adaptive** immune response is involved. That is, if the clinical situation involves only an innate response, such clinicians opt to use the more general term *inflammation* in describing the clinical picture. *That said, the signs and symptoms produced by both adaptive and innate immune responses are recognized clinically as 'inflammation,' and despite their underlying differences in mechanism, are often indistinguishable at the slit lamp*.

ic

e

ity?

For each statement, identify the **lens-related secondary OAG** with which it is associated (some have more than one answer)

<u>And now, an overly long sidebar regarding immunology and the lens-related secondary OAGs</u>: Some clinicians reserve the term *immune response* for clinical situations in which an **adaptive** immune response is involved. That is, if the clinical situation involves only an innate response, such clinicians opt to use the more general term *inflammation* in describing the clinical picture. *That said, the signs and symptoms produced by both adaptive and innate immune responses are recognized clinically as 'inflammation,' and despite their underlying differences in mechanism, are often indistinguishable at the slit lamp*.

I'm going on about this because **it explains what may seem to be inconsistencies among the *BCSC* books with regard to phacolytic, phacoantigenic and lens-particle glaucoma**.

For each statement, identify the **lens-related secondary OAG** with which it is associated (some have more than one answer)

<u>And now, an overly long sidebar regarding immunology and the lens-related secondary OAGs</u>: Some clinicians reserve the term *immune response* for clinical situations in which an **adaptive** immune response is involved. That is, if the clinical situation involves only an innate response, such clinicians opt to use the more general term *inflammation* in describing the clinical picture. *That said, the signs and symptoms produced by both adaptive and innate immune responses are recognized clinically as 'inflammation,' and despite their underlying differences in mechanism, are often indistinguishable at the slit lamp*.

I'm going on about this because **it explains what may seem to be inconsistencies among the *BCSC* books with regard to phacolytic, phacoantigenic and lens-particle glaucoma**. Take the *Lens* book. It states that "phacoantigenic uveitis" (it does not use the term phacoantigenic *glaucoma*) is "immune-mediated." However, it pointedly states that phacolytic glaucoma does **not** elicit an immune response. This is an example of the *immune response* = *adaptive response* mindset mentioned above. Likewise, the *Path* book addresses phacoantigenic uveitis in a section entitled *Inflammations*, but not phacolytic glaucoma—it is discussed under *Secondary Glaucoma with Material in the Trabecular Meshwork*. (The term *lens-particle glaucoma* does not appear in the *Path* book's index.)

For each statement, identify the **lens-related secondary OAG** with which it is associated (some have more than one answer)

And now, an overly long sidebar regarding immunology and the lens-related secondary OAGs: Some clinicians reserve the term *immune response* for clinical situations in which an **adaptive** immune response is involved. That is, if the clinical situation involves only an innate response, such clinicians opt to use the more general term *inflammation* in describing the clinical picture. *That said, the signs and symptoms produced by both adaptive and innate immune responses are recognized clinically as 'inflammation,' and despite their underlying differences in mechanism, are often indistinguishable at the slit lamp*.

I'm going on about this because **it explains what may seem to be inconsistencies among the *BCSC* books with regard to phacolytic, phacoantigenic and lens-particle glaucoma**. Take the *Lens* book. It states that "phacoantigenic uveitis" (it does not use the term phacoantigenic *glaucoma*) is "immune-mediated." However, it pointedly states that phacolytic glaucoma does **not** elicit an immune response. This is an example of the *immune response* = *adaptive response* mindset mentioned above. Likewise, the *Path* book addresses phacoantigenic uveitis in a section entitled *Inflammations*, but not phacolytic glaucoma—it is discussed under *Secondary Glaucoma with Material in the Trabecular Meshwork*. (The term *lens-particle glaucoma* does not appear in the *Path* book's index.) In contrast, the *Uveitis* book eschews the term *phacoantigenic uveitis/glaucoma* entirely, using instead the term *lens-induced uveitis.* It goes on to describe phacolytic glaucoma in a manner consistent with the other books. *Lens-particle glaucoma* does not appear in its index either.

For each statement, identify the **lens-related secondary OAG** with which it is associated (some have more than one answer)

And now, an overly long sidebar regarding immunology and the lens-related secondary OAGs: Some clinicians reserve the term *immune response* for clinical situations in which an **adaptive** immune response is involved. That is, if the clinical situation involves only an innate response, such clinicians opt to use the more general term *inflammation* in describing the clinical picture. *That said, the signs and symptoms produced by both adaptive and innate immune responses are recognized clinically as 'inflammation,' and despite their underlying differences in mechanism, are often indistinguishable at the slit lamp*.

I'm going on about this because **it explains what may seem to be inconsistencies among the *BCSC* books with regard to phacolytic, phacoantigenic and lens-particle glaucoma**. Take the *Lens* book. It states that "phacoantigenic uveitis" (it does not use the term phacoantigenic *glaucoma*) is "immune-mediated." However, it pointedly states that phacolytic glaucoma does **not** elicit an immune response. This is an example of the *immune response* = *adaptive response* mindset mentioned above. Likewise, the *Path* book addresses phacoantigenic uveitis in a section entitled *Inflammations*, but not phacolytic glaucoma—it is discussed under *Secondary Glaucoma with Material in the Trabecular Meshwork*. (The term *lens-particle glaucoma* does not appear in the *Path* book's index.) In contrast, the *Uveitis* book eschews the term *phacoantigenic uveitis/glaucoma* entirely, using instead the term *lens-induced uveitis.* It goes on to describe phacolytic glaucoma in a manner consistent with the other books. *Lens-particle glaucoma* does not appear in its index either. Finally, the *Glaucoma* book groups all three conditions together under the heading *Lens-Induced Glaucoma*, and does not address the issue of innate vs adaptive immunity. Instead, it refers simply to 'inflammation' in the description of all three conditions. The term phacoantigenic *uveitis* does not appear.

For each statement, identify the **lens-related secondary OAG** with which it is associated (some have more than one answer)

And now, an overly long sidebar regarding immunology and the lens-related secondary OAGs: Some clinicians reserve the term *immune response* for clinical situations in which an **adaptive** immune response is involved. That is, if the clinical situation involves only an innate response, such clinicians opt to use the more general term *inflammation* in describing the clinical picture. *That said, the signs and symptoms produced by both adaptive and innate immune responses are recognized clinically as 'inflammation,' and despite their underlying differences in mechanism, are often indistinguishable at the slit lamp*.

I'm going on about this because **it explains what may seem to be inconsistencies among the *BCSC* books with regard to phacolytic, phacoantigenic and lens-particle glaucoma**. Take the *Lens* book. It states that "phacoantigenic uveitis" (it does not use the term phacoantigenic *glaucoma*) is "immune-mediated." However, it pointedly states that phacolytic glaucoma does **not** elicit an immune response. This is an example of the *immune response* = *adaptive response* mindset mentioned above. Likewise, the *Path* book addresses phacoantigenic uveitis in a section entitled *Inflammations*, but not phacolytic glaucoma—it is discussed under *Secondary Glaucoma with Material in the Trabecular Meshwork*. (The term *lens-particle glaucoma* does not appear in the *Path* book's index.) In contrast, the *Uveitis* book eschews the term *phacoantigenic uveitis/glaucoma* entirely, using instead the term *lens-induced uveitis.* It goes on to describe phacolytic glaucoma in a manner consistent with the other books. *Lens-particle glaucoma* does not appear in its index either. Finally, the *Glaucoma* book groups all three conditions together under the heading *Lens-Induced Glaucoma*, and does not address the issue of innate vs adaptive immunity. Instead, it refers simply to 'inflammation' in the description of all three conditions. The term phacoantigenic *uveitis* does not appear.

TLDR When studying the lens-related secondary OAGs, make sure to read about them in all four of the *BCSC* books that address them—*Glaucoma*, *Uveitis*, *Lens* and *Path*—and be prepared to grapple with inconsistencies when doing so.

Q

For each statement, identify the **lens-related secondary OAG** with which it is associated (some have more than one answer)

Phacolytic glaucoma **Phacoantigenic glaucoma** **Lens-particle glaucoma**

- aka *phacoanaphylactic glaucoma*: Phacoantigenic
- Usually unilateral: All of them
- Is mediated by an *adaptive* immune response: Phacoantigenic
- Associated with mature/hypermature cataract: Phacolytic
- Vitritis may be present: Phacoantigenic
- Gonioscopy reveals cortical material in the angle: Lens particle
- Least likely to develop elevated IOP: Phacoantigenic
- Is mediated by an *innate* immune response: Phacolytic
- PAS development is not a concern:

A

For each statement, identify the **lens-related secondary OAG** with which it is associated (some have more than one answer)

Phacolytic glaucoma **Phacoantigenic glaucoma** **Lens-particle glaucoma**

- aka *phacoanaphylactic glaucoma*: Phacoantigenic
- Usually unilateral: All of them
- Is mediated by an *adaptive* immune response: Phacoantigenic
- Associated with mature/hypermature cataract: Phacolytic
- Vitritis may be present: Phacoantigenic
- Gonioscopy reveals cortical material in the angle: Lens particle
- Least likely to develop elevated IOP: Phacoantigenic
- Is mediated by an *innate* immune response: Phacolytic
- PAS development is not a concern: Phacolytic

Q

For each statement, identify the **lens-related secondary OAG** with which it is associated (some have more than one answer)

Phacolytic glaucoma **Phacoantigenic glaucoma** **Lens-particle glaucoma**

- aka *phacoanaphylactic glaucoma*: Phacoantigenic
- Usually unilateral: All of them
- Is mediated by an *adaptive* immune response: Phacoantigenic
- Associated with mature/hypermature cataract: Phacolytic
- Vitritis may be present: Phacoantigenic
- Gonioscopy reveals cortical material in the angle: Lens particle
- Least likely to develop elevated IOP: Phacoantigenic
- Is mediated by an *innate* immune response: Phacolytic
- PAS development is not a concern: Phacolytic
- Classic presentation: Elderly pt with hx longstanding poor vision in affected eye c/o new-onset redness/pain and worsening vision:

A

For each statement, identify the **lens-related secondary OAG** with which it is associated (some have more than one answer)

Phacolytic glaucoma **Phacoantigenic glaucoma** **Lens-particle glaucoma**

- aka *phacoanaphylactic glaucoma*: Phacoantigenic
- Usually unilateral: All of them
- Is mediated by an *adaptive* immune response: Phacoantigenic
- Associated with mature/hypermature cataract: Phacolytic
- Vitritis may be present: Phacoantigenic
- Gonioscopy reveals cortical material in the angle: Lens particle
- Least likely to develop elevated IOP: Phacoantigenic
- Is mediated by an *innate* immune response: Phacolytic
- PAS development is not a concern: Phacolytic
- Classic presentation: Elderly pt with hx longstanding poor vision in affected eye c/o new-onset redness/pain and worsening vision: Phacolytic

Q

For each statement, identify the **lens-related secondary OAG** with which it is associated (some have more than one answer)

Phacolytic glaucoma **Phacoantigenic glaucoma** **Lens-particle glaucoma**

- aka *phacoanaphylactic glaucoma*: Phacoantigenic
- Usually unilateral: All of them
- Is mediated by an *adaptive* immune response: Phacoantigenic
- **Associated with mature/hypermature cataract: Phacolytic**
- Vitritis may be present: Phacoantigenic
- Gonioscopy reveals cortical material in the angle: Lens particle
- Least
- Is me c
- PAS
- Classic presentation: Elderly pt with hx longstanding poor vision in affected eye c/ new-onset redness/pain and **worsening vision: Phacolytic**

Given that their cataracts can't get much worse, what accounts for the fact that phacolytic glaucoma pts c/o an acute worsening of VA coinciding with the onset of their pain and ocular injection?

A

For each statement, identify the **lens-related secondary OAG** with which it is associated (some have more than one answer)

Phacolytic glaucoma **Phacoantigenic glaucoma** **Lens-particle glaucoma**

- aka *phacoanaphylactic glaucoma*: Phacoantigenic
- Usually unilateral: All of them
- Is mediated by an *adaptive* immune response: Phacoantigenic
- **Associated with mature/hypermature cataract: Phacolytic**
- Vitritis may be present: Phacoantigenic
- Gonioscopy reveals cortical material in the angle: Lens particle
- Least
- Is me c
- PAS
- Classic presentation: Elderly pt with hx longstanding poor vision in affected eye c/ new-onset redness/pain and **worsening vision: Phacolytic**

Given that their cataracts can't get much worse, what accounts for the fact that phacolytic glaucoma pts c/o an acute worsening of VA coinciding with the onset of their pain and ocular injection?
The IOP spike smashes their corneal endothelium, resulting in corneal edema which renders bad VA even worse

For each statement, identify the **lens-related secondary OAG** with which it is associated (some have more than one answer)

Phacolytic glaucoma **Phacoantigenic glaucoma** **Lens-particle glaucoma**

Phacolytic glaucoma: Corneal edema

Q

For each statement, identify the **lens-related secondary OAG** with which it is associated (some have more than one answer)

Phacolytic glaucoma **Phacoantigenic glaucoma** **Lens-particle glaucoma**

- aka *phacoanaphylactic glaucoma*: Phacoantigenic
- Usually unilateral: All of them
- Is mediated by an *adaptive* immune response: Phacoantigenic
- Associated with mature/hypermature cataract: Phacolytic
- Vitritis may be present: Phacoantigenic
- Gonioscopy reveals cortical material in the angle: Lens particle
- Least likely to develop elevated IOP: Phacoantigenic
- Is mediated by an *innate* immune response: Phacolytic
- PAS development is not a concern: Phacolytic
- Classic presentation: Elderly pt with hx longstanding poor vision in affected eye c/o new-onset redness/pain and worsening vision: Phacolytic
- Fellow eye may become involved:

A

For each statement, identify the **lens-related secondary OAG** with which it is associated (some have more than one answer)

Phacolytic glaucoma **Phacoantigenic glaucoma** **Lens-particle glaucoma**

- aka *phacoanaphylactic glaucoma*: Phacoantigenic
- Usually unilateral: All of them
- Is mediated by an *adaptive* immune response: Phacoantigenic
- Associated with mature/hypermature cataract: Phacolytic
- Vitritis may be present: Phacoantigenic
- Gonioscopy reveals cortical material in the angle: Lens particle
- Least likely to develop elevated IOP: Phacoantigenic
- Is mediated by an *innate* immune response: Phacolytic
- PAS development is not a concern: Phacolytic
- Classic presentation: Elderly pt with hx longstanding poor vision in affected eye c/o new-onset redness/pain and worsening vision: Phacolytic
- Fellow eye may become involved: Phacoantigenic

Q

For each statement, identify the **lens-related secondary OAG** with which it is associated (some have more than one answer)

Phacolytic glaucoma **Phacoantigenic glaucoma** **Lens-particle glaucoma**

- aka *phacoanaphylactic glaucoma*: Phacoantigenic
- Usually unilateral: All of them
- Is mediated by an *adaptive* immune response: Phacoantigenic
- Associated with mature/hypermature cataract: Phacolytic
- Vitritis may be present: Phacoantigenic
- Gonioscopy reveals cortical material in the angle: Lens-particle

How is it the fellow eye can become involved in phacoantigenic glaucoma?

- Classic presentation: Elderly pt with hx longstanding poor vision in affected eye c/o new-onset redness/pain and worsening vision: Phacolytic
- **Fellow eye may become involved: Phacoantigenic**

A

For each statement, identify the **lens-related secondary OAG** with which it is associated (some have more than one answer)

Phacolytic glaucoma **Phacoantigenic glaucoma** **Lens-particle glaucoma**

- aka *phacoanaphylactic glaucoma*: Phacoantigenic
- Usually unilateral: All of them
- Is mediated by an *adaptive* immune response: Phacoantigenic
- Associated with mature/hypermature cataract: Phacolytic
- Vitritis may be present: Phacoantigenic
- Gonioscopy reveals cortical material in the angle: Lens-particle

How is it the fellow eye can become involved in phacoantigenic glaucoma?
Recall that it is normal for minute amounts of lens protein to be found in the AC of a phakic eye.

- Classic presentation: Elderly pt with hx longstanding poor vision in affected eye c/o new-onset redness/pain and worsening vision: Phacolytic
- **Fellow eye may become involved: Phacoantigenic**

A

For each statement, identify the **lens-related secondary OAG** with which it is associated (some have more than one answer)

Phacolytic glaucoma **Phacoantigenic glaucoma** **Lens-particle glaucoma**

- aka *phacoanaphylactic glaucoma*: Phacoantigenic
- Usually unilateral: All of them
- Is mediated by an *adaptive* immune response: Phacoantigenic
- Associated with mature/hypermature cataract: Phacolytic
- Vitritis may be present: Phacoantigenic
- Gonioscopy reveals cortical material in the angle: Lens-particle

How is it the fellow eye can become involved in phacoantigenic glaucoma?
Recall that it is normal for minute amounts of lens protein to be found in the AC of a phakic eye. Recall further that phacoantigenic glaucoma involves an adaptive response in which the immune system becomes sensitized to normal lens proteins.

- Classic presentation: Elderly pt with hx longstanding poor vision in affected eye c/o new-onset redness/pain and worsening vision: Phacolytic
- **Fellow eye may become involved: Phacoantigenic**

A

For each statement, identify the **lens-related secondary OAG** with which it is associated (some have more than one answer)

Phacolytic glaucoma **Phacoantigenic glaucoma** **Lens-particle glaucoma**

- aka *phacoanaphylactic glaucoma*: Phacoantigenic
- Usually unilateral: All of them
- Is mediated by an *adaptive* immune response: Phacoantigenic
- Associated with mature/hypermature cataract: Phacolytic
- Vitritis may be present: Phacoantigenic
- Gonioscopy reveals cortical material in the angle: Lens-particle

How is it the fellow eye can become involved in phacoantigenic glaucoma?
Recall that it is normal for minute amounts of lens protein to be found in the AC of a phakic eye. Recall further that phacoantigenic glaucoma involves an adaptive response in which the immune system becomes sensitized to normal lens proteins. If an immune system that has become sensitized to normal lens proteins encounters them in the AC of the fellow eye, it may kick off a uveitic process in that eye.

- Classic presentation: Elderly pt with hx longstanding poor vision in affected eye c/o new-onset redness/pain and worsening vision: Phacolytic
- **Fellow eye may become involved: Phacoantigenic**

Q

For each statement, identify the **lens-related secondary OAG** with which it is associated (some have more than one answer)

Phacolytic glaucoma **Phacoantigenic glaucoma** **Lens-particle glaucoma**

- aka *phacoanaphylactic glaucoma*: Phacoantigenic
- Usually unilateral: All of them
- Is mediated by an *adaptive* immune response: Phacoantigenic
- Associated with mature/hypermature cataract: Phacolytic
- Vitritis may be present: Phacoantigenic
- Gonioscopy reveals cortical material in the angle: Lens particle
- Least likely to develop elevated IOP: Phacoantigenic
- Is mediated by an *innate* immune response: Phacolytic
- PAS development is not a concern: Phacolytic
- Classic presentation: Elderly pt with hx longstanding poor vision in affected eye c/o new-onset redness/pain and worsening vision: Phacolytic
- Fellow eye may become involved: Phacoantigenic
- The *absence* of KP is a key clinical finding:

A

For each statement, identify the **lens-related secondary OAG** with which it is associated (some have more than one answer)

Phacolytic glaucoma **Phacoantigenic glaucoma** **Lens-particle glaucoma**

- aka *phacoanaphylactic glaucoma*: Phacoantigenic
- Usually unilateral: All of them
- Is mediated by an *adaptive* immune response: Phacoantigenic
- Associated with mature/hypermature cataract: Phacolytic
- Vitritis may be present: Phacoantigenic
- Gonioscopy reveals cortical material in the angle: Lens particle
- Least likely to develop elevated IOP: Phacoantigenic
- Is mediated by an *innate* immune response: Phacolytic
- PAS development is not a concern: Phacolytic
- Classic presentation: Elderly pt with hx longstanding poor vision in affected eye c/o new-onset redness/pain and worsening vision: Phacolytic
- Fellow eye may become involved: Phacoantigenic
- The *absence* of KP is a key clinical finding: Phacolytic

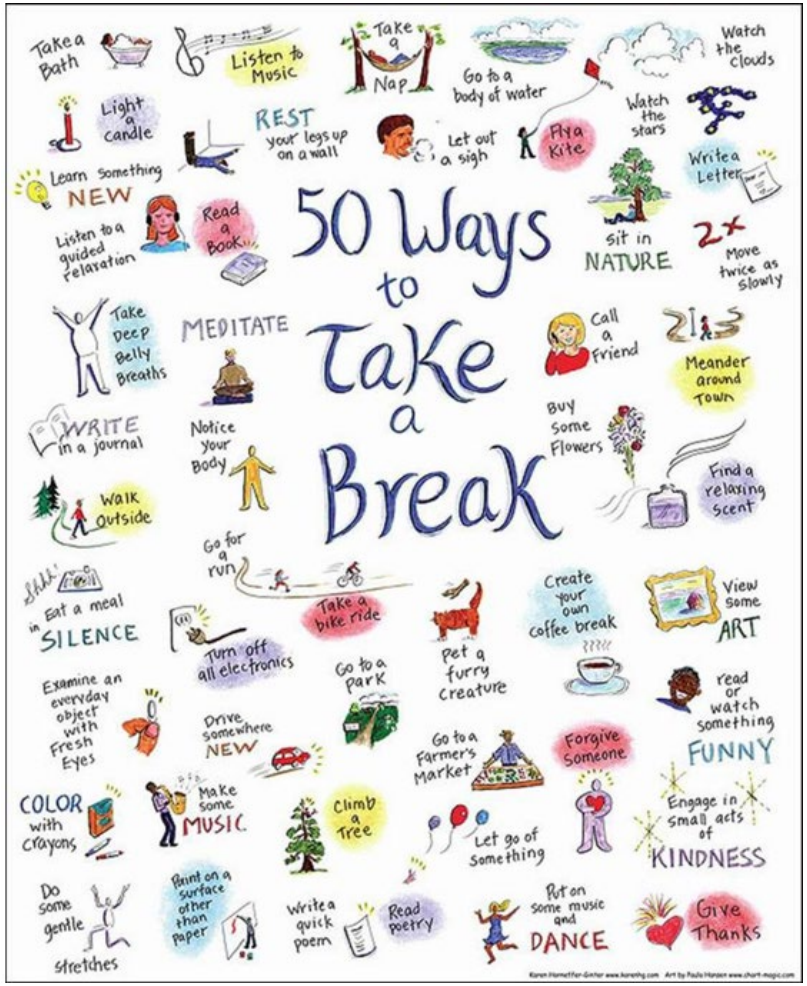

(This is a good point in the set to take a break)

Open-angle Glaucoma: *Secondary*

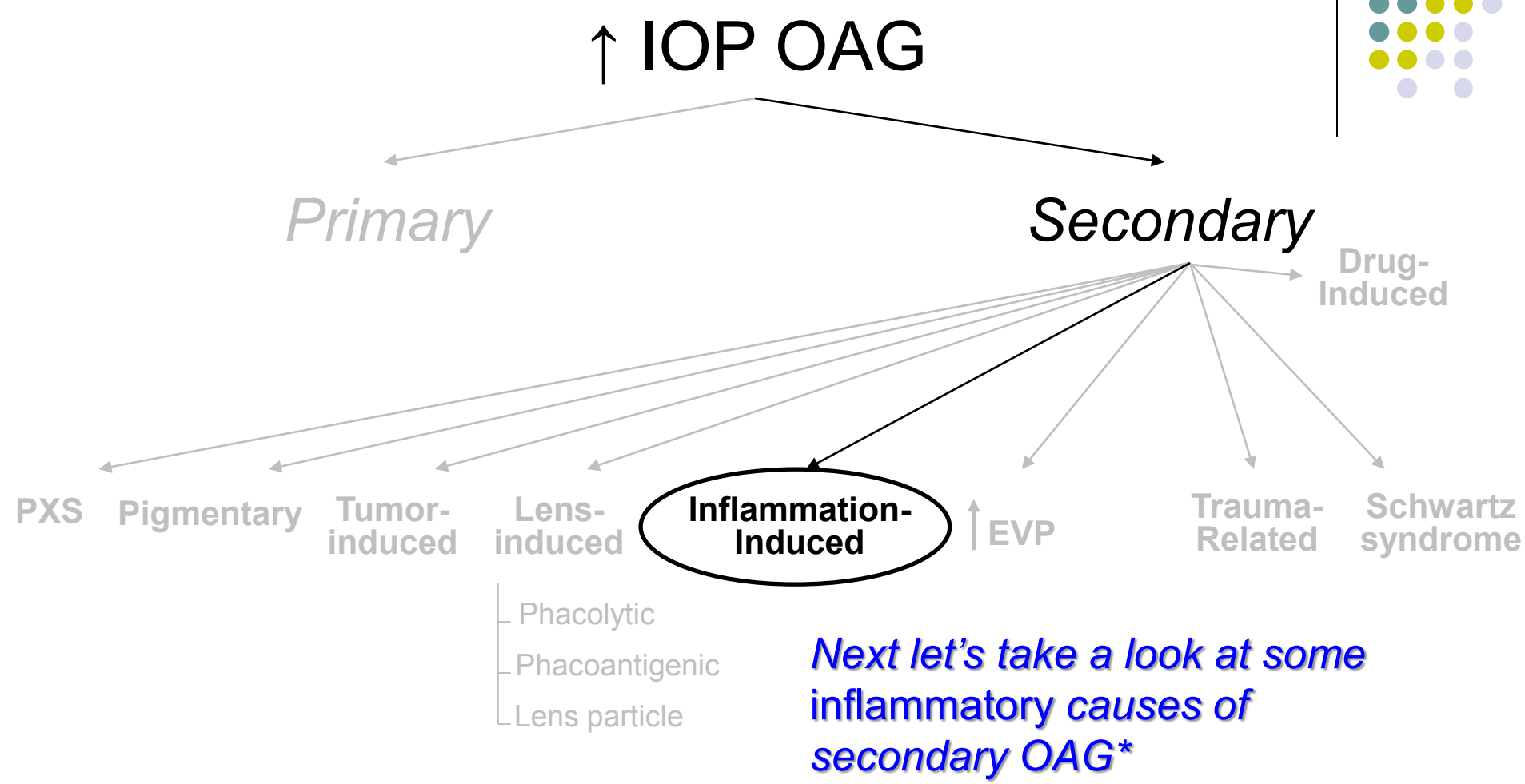

Next let's take a look at some inflammatory *causes of secondary OAG**

*Not involving the lens, that is

Q

Open-angle Glaucoma: *Secondary*

Is elevated IOP a common manifestation of uveitis?

A

Open-angle Glaucoma: *Secondary*

Is elevated IOP a common manifestation of uveitis?

No—in fact, a **lower**-than-normal IOP is expected

Q

Open-angle Glaucoma: *Secondary*

Is elevated IOP a common manifestation of uveitis?
No—in fact, a **lower**-than-normal IOP is expected

Why does the IOP tend to be lower in an inflamed eye?

A

Open-angle Glaucoma: *Secondary*

Is elevated IOP a common manifestation of uveitis?
No—in fact, a **lower**-than-normal IOP is expected

Why does the IOP tend to be lower in an inflamed eye?
Inflammation causes the ciliary body to ‘shut down’ to some extent, resulting in aqueous hyposecretion

Q

Open-angle Glaucoma: *Secondary*

Is elevated IOP a common manifestation of uveitis?
No—in fact, a **lower**-than-normal IOP is expected

Why does the IOP tend to be lower in an inflamed eye?
Inflammation causes the ciliary body to ‘shut down’ to some extent, resulting in aqueous hyposecretion

When elevated IOP does occur in the setting of uveitis, a number of different mechanisms may be responsible. What are they?
--
--
--

A

Open-angle Glaucoma: *Secondary*

Is elevated IOP a common manifestation of uveitis?
No—in fact, a **lower**-than-normal IOP is expected

Why does the IOP tend to be lower in an inflamed eye?
Inflammation causes the ciliary body to 'shut down' to some extent, resulting in aqueous hyposecretion

When elevated IOP does occur in the setting of uveitis, a number of different mechanisms may be responsible. What are they?
--Inflammation of the TM causing it to swell
--Blocking of the angle by inflammatory material
--Clogging of Schlemm's canal with inflammatory debris

Q

Open-angle Glaucoma: *Secondary*

Is elevated IOP a common manifestation of uveitis?
No—in fact, a **lower**-than-normal IOP is expected

Why does the IOP tend to be lower in an inflamed eye?
Inflammation causes the ciliary body to 'shut down' to some extent, resulting in aqueous hyposecretion

When elevated IOP does occur in the setting of uveitis, a number of different mechanisms may be responsible. What are they?
--Inflammation of the TM causing it to swell
--Blocking of the angle by inflammatory material
--Clogging of Schlemm's canal with inflammatory debris
--*And lest we forget, the classic iatrogenic cause of elevated IOP in uveitis:*

A

Open-angle Glaucoma: *Secondary*

Is elevated IOP a common manifestation of uveitis?
No—in fact, a **lower**-than-normal IOP is expected

Why does the IOP tend to be lower in an inflamed eye?
Inflammation causes the ciliary body to 'shut down' to some extent, resulting in aqueous hyposecretion

When elevated IOP does occur in the setting of uveitis, a number of different mechanisms may be responsible. What are they?
--Inflammation of the TM causing it to swell
--Blocking of the angle by inflammatory material
--Clogging of Schlemm's canal with inflammatory debris
--*And lest we forget, the classic iatrogenic cause of elevated IOP in uveitis:*
Steroid-induced reduced TM outflow

Q

Open-angle Glaucoma: *Secondary*

Is elevated IOP a common manifestation of uveitis?
No—in fact, a **lower**-than-normal IOP is expected

Why does the IOP tend to be lower in an inflamed eye?
Inflammation causes the ciliary body to 'shut down' to some extent, resulting in aqueous hyposecretion

When elevated IOP does occur in the setting of uveitis, a number of different mechanisms may be responsible. What are they?
--Inflammation of the TM causing it to swell
--Blocking of the angle by inflammatory material
--Clogging of Schlemm's canal with inflammatory debris
--*And lest we forget, the classic iatrogenic cause of elevated IOP in uveitis:*
Steroid-induced reduced TM outflow

In general terms, what is the mechanism of steroid-induced IOP elevation?

A

Open-angle Glaucoma: *Secondary*

Is elevated IOP a common manifestation of uveitis?
No—in fact, a **lower**-than-normal IOP is expected

Why does the IOP tend to be lower in an inflamed eye?
Inflammation causes the ciliary body to 'shut down' to some extent, resulting in aqueous hyposecretion

When elevated IOP does occur in the setting of uveitis, a number of different mechanisms may be responsible. What are they?
--Inflammation of the TM causing it to swell
--Blocking of the angle by inflammatory material
--Clogging of Schlemm's canal with inflammatory debris
--*And lest we forget, the classic iatrogenic cause of elevated IOP in uveitis:*
Steroid-induced reduced TM outflow

In general terms, what is the mechanism of steroid-induced IOP elevation?
While still uncertain, it likely stems from impeded outflow at the TM owing to remodeling of the TM induced by the steroid

Open-angle Glaucoma: *Secondary*

Is elevated IOP a common manifestation of uveitis?
No—in fact, a **lower**-than-normal IOP is expected

Why does the IOP tend to be lower in an inflamed eye?
Inflammation causes the ciliary body to 'shut down' to some extent, resulting in aqueous hyposecretion

When elevated IOP does occur in the setting of uveitis, a number of different mechanisms may be responsible. What are they?
--Inflammation of the TM causing it to swell
--Blocking of the angle by inflammatory material
--Clogging of Schlemm's canal with inflammatory debris
--*And lest we forget, the classic iatrogenic cause of elevated IOP in uveitis:*
Steroid-induced reduced TM outflow

In general *vation?*
Steroid-in

Steroid-induced IOP elevation will be addressed in greater detail later in the slide-set

Q

Seven forms of uveitic 2ndry OAG mentioned in the Glaucoma *book*

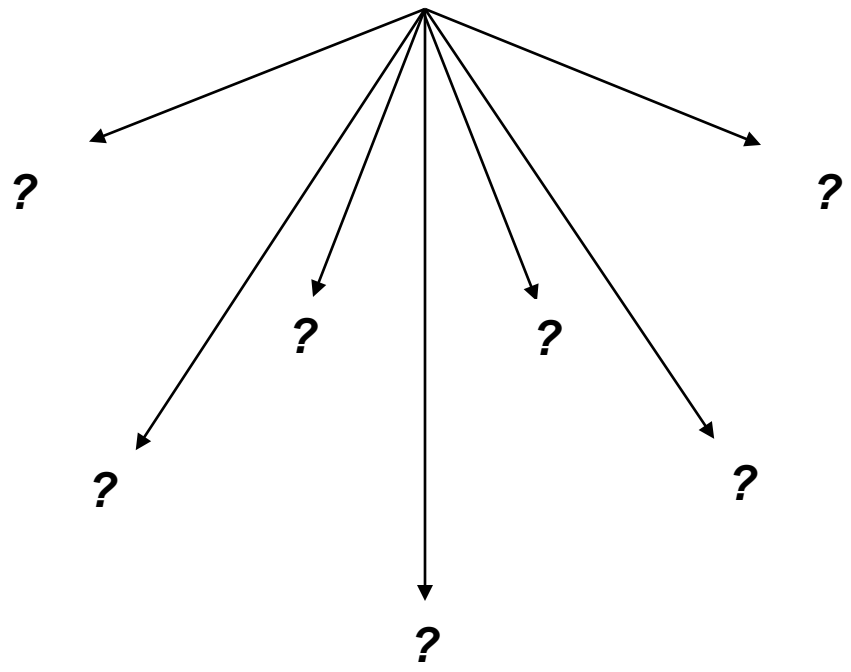

While there are many causes of OAG secondary to intraocular inflammation, the Glaucoma *book sees fit to mention seven by name. What are they?*

A

Seven forms of uveitic 2ndry OAG mentioned in the Glaucoma *book*

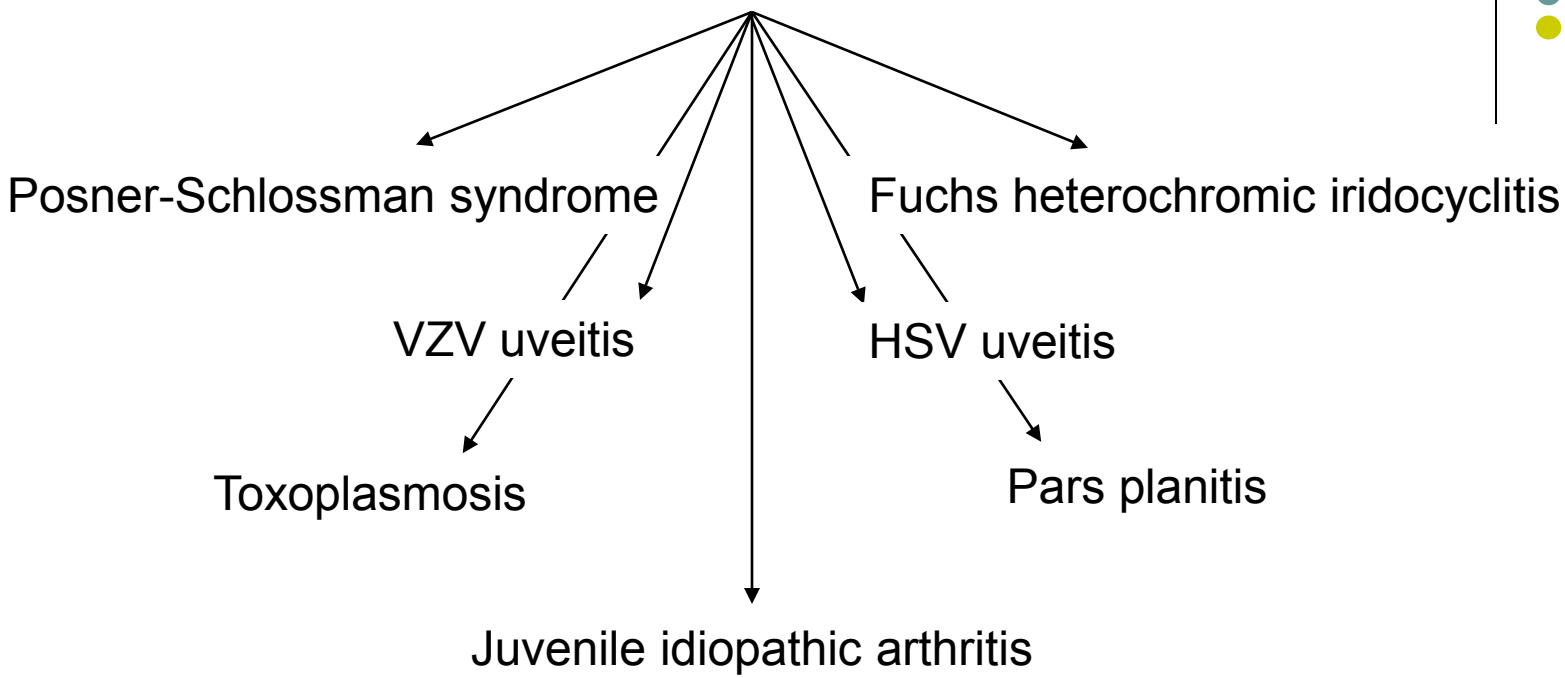

While there are many causes of OAG secondary to intraocular inflammation, the Glaucoma *book sees fit to mention seven by name. What are they?*

Q

Two forms of uveitic 2ndry OAG addressed in the Glaucoma *book*

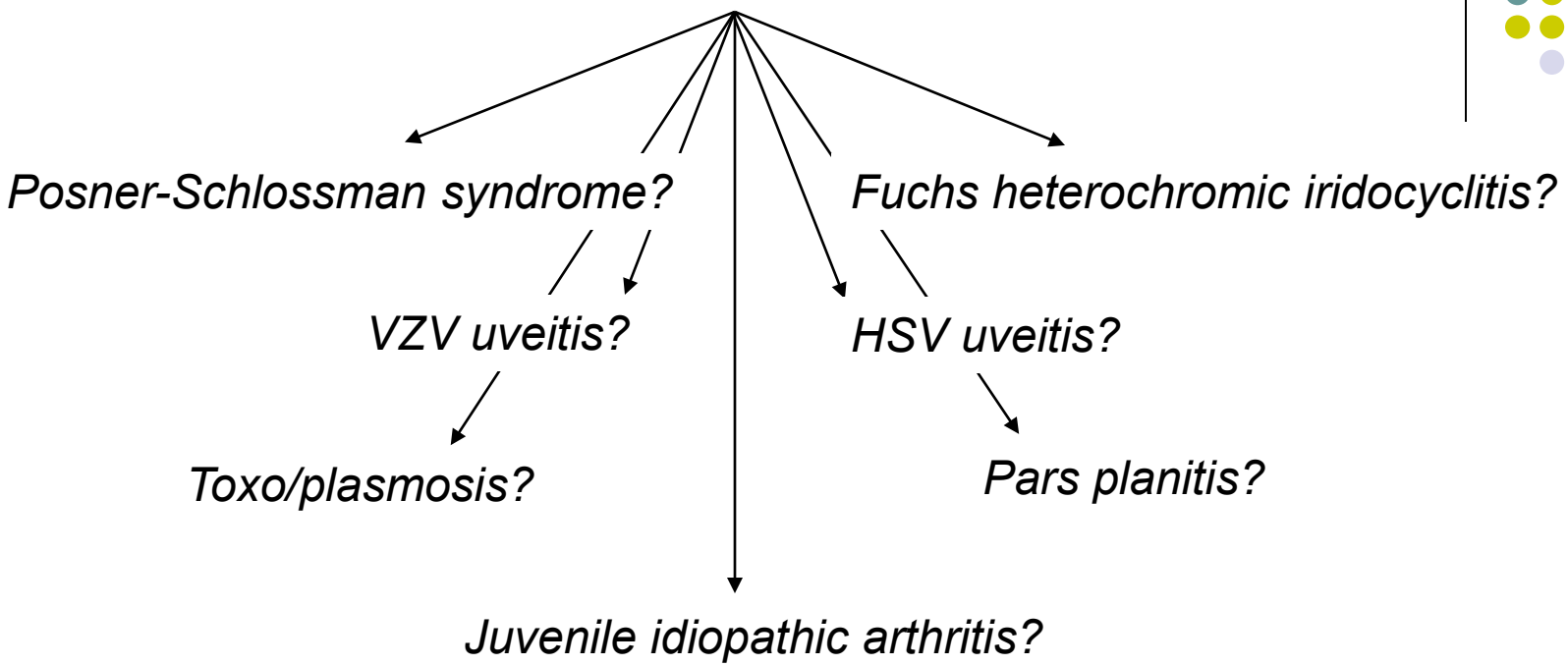

Of the seven, the Glaucoma *book addresses two in detail—so in this slide-set, we will follow suit. Which ones?*

A

Two forms of uveitic 2ndry OAG addressed in the Glaucoma *book*

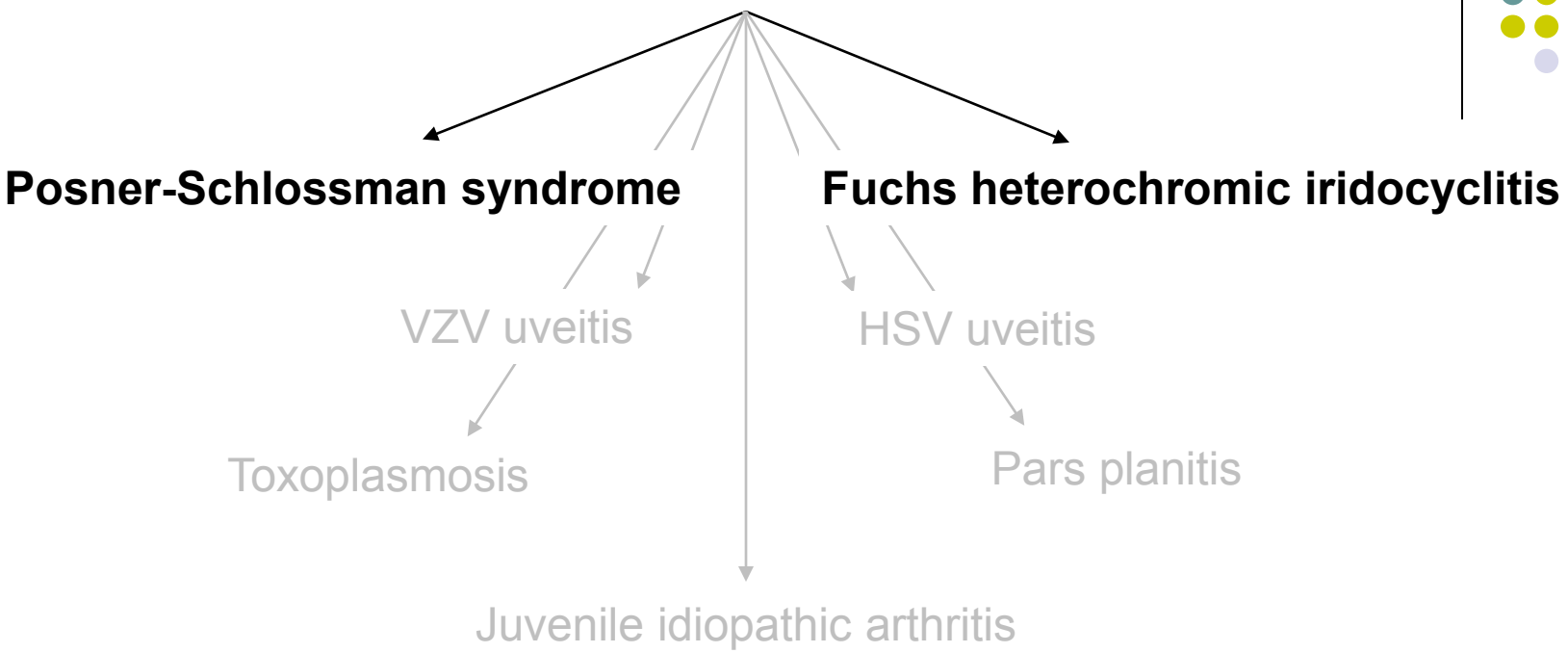

Of the seven, the Glaucoma *book addresses two in detail—so in this slide-set, we will follow suit. Which ones?*

(Note: All of the others are covered extensively in other slide-sets; see the Table of Contents*)*

Q

Two forms of uveitic 2ndry OAG addressed in the Glaucoma *book*

Posner-Schlossman syndrome
(aka [redacted])

Fuchs heterochromic iridocyclitis

By what noneponymous name is P-S syndrome also known?

A

Two forms of uveitic 2ndry OAG addressed in the Glaucoma *book*

Posner-Schlossman syndrome
(aka *glaucomatocyclitic crisis*)

Fuchs heterochromic iridocyclitis

By what noneponymous name is P-S syndrome also known?

Q

Two forms of uveitic 2ndry OAG addressed in the Glaucoma *book*

Posner-Schlossman syndrome
(aka *glaucomatocyclitic crisis*)

--?

Fuchs heterochromic iridocyclitis

--?

Does each tend to present unilaterally, or bilaterally?

A

Two forms of uveitic 2ndry OAG addressed in the Glaucoma *book*

Posner-Schlossman syndrome
(aka *glaucomatocyclitic crisis*)

--Unilateral

Fuchs heterochromic iridocyclitis

--Unilateral

Does each tend to present unilaterally, or bilaterally?

Q

Two forms of uveitic 2ndry OAG addressed in the Glaucoma *book*

Posner-Schlossman syndrome
(aka *glaucomatocyclitic crisis*)

--Unilateral
--***?***

Fuchs heterochromic iridocyclitis

--Unilateral
--***?***

What demographic is typically affected?

A

Two forms of uveitic 2ndry OAG addressed in the Glaucoma *book*

Posner-Schlossman syndrome
(aka *glaucomatocyclitic crisis*)

--Unilateral
--Young to middle-aged adults

Fuchs heterochromic iridocyclitis

--Unilateral
--Young to middle-aged adults

What demographic is typically affected?

Q

Two forms of uveitic 2ndry OAG addressed in the Glaucoma *book*

Posner-Schlossman syndrome
(aka *glaucomatocyclitic crisis*)

--Unilateral
--Young to middle-aged adults
--Inflammation is…

Fuchs heterochromic iridocyclitis

--Unilateral
--Young to middle-aged adults
--Inflammation is…

Is inflammation typically mild, or severe?

A

Two forms of uveitic 2ndry OAG addressed in the Glaucoma *book*

Posner-Schlossman syndrome
(aka *glaucomatocyclitic crisis*)

--Unilateral
--Young to middle-aged adults
--Inflammation is…mild

Fuchs heterochromic iridocyclitis

--Unilateral
--Young to middle-aged adults
--Inflammation is…mild

Is inflammation typically mild, or severe?

Q

Two forms of uveitic 2ndry OAG addressed in the Glaucoma *book*

Posner-Schlossman syndrome
(aka *glaucomatocyclitic crisis*)

--Unilateral
--Young to middle-aged adults
--Inflammation is…mild
--IOP elevation usually…

Fuchs heterochromic iridocyclitis

--Unilateral
--Young to middle-aged adults
--Inflammation is…mild
--IOP elevation usually…

Is IOP elevation typically mild, or severe?

A

Two forms of uveitic 2ndry OAG addressed in the Glaucoma *book*

Posner-Schlossman syndrome
(aka *glaucomatocyclitic crisis*)

--Unilateral
--Young to middle-aged adults
--Inflammation is…mild
--IOP elevation usually…**severe**

Fuchs heterochromic iridocyclitis

--Unilateral
--Young to middle-aged adults
--Inflammation is…mild
--IOP elevation usually…**mild** (or absent)

Is IOP elevation typically mild, or severe?

Q

Two forms of uveitic 2ndry OAG addressed in the Glaucoma *book*

Posner-Schlossman syndrome
(aka *glaucomatocyclitic crisis*)

--Unilateral
--Young to middle-aged adults
--Inflammation is…mild
--IOP elevation usually…**severe**
--Is a _____ condition

Fuchs heterochromic iridocyclitis

--Unilateral
--Young to middle-aged adults
--Inflammation is…mild
--IOP elevation usually…**mild** (or absent)
--Is a _____ condition

Is it an acute, chronic, *or* recurrent *condition?*

A

Two forms of uveitic 2ndry OAG addressed in the Glaucoma *book*

Posner-Schlossman syndrome
(aka *glaucomatocyclitic crisis*)

--Unilateral
--Young to middle-aged adults
--Inflammation is…mild
--IOP elevation usually…**severe**
--Is a **recurrent** condition

Fuchs heterochromic iridocyclitis

--Unilateral
--Young to middle-aged adults
--Inflammation is…mild
--IOP elevation usually…**mild** (or absent)
--Is a **chronic** condition

Is it an acute, chronic, *or* recurrent *condition?*

Q

Two forms of uveitic 2ndry OAG addressed in the Glaucoma *book*

Posner-Schlossman syndrome
(aka *glaucomatocyclitic crisis*)

--Unilateral
--Young to middle-aged adults
--Inflammation is…mild
--IOP elevation usually…**severe**
--Is a **recurrent** condition

Fuchs heterochromic iridocyclitis

--Unilateral
--Young to middle-aged adults
--Inflammation is…mild
--IOP elevation usually…**mild** (or absent)
--Is a **chronic** condition

Is it an **acute**, **chronic**, *or* **recurrent** *condition?*

What does it mean to say a uveitic condition is acute, recurrent *or* chronic*?*

Q

Two forms of uveitic 2ndry OAG addressed in the Glaucoma *book*

Posner-Schlossman syndrome
(aka *glaucomatocyclitic crisis*)

--Unilateral
--Young to middle-aged adults
--Inflammation is…mild
--IOP elevation usually…**severe**
--Is a **recurrent** condition

Fuchs heterochromic iridocyclitis

--Unilateral
--Young to middle-aged adults
--Inflammation is…mild
--IOP elevation usually…**mild** (or absent)
--Is a **chronic** condition

Is it an **acute**, **chronic**, *or* **recurrent** *condition?*

What does it mean to say a uveitic condition is acute, recurrent *or* chronic*?*
--An acute *uveitis…*
--A recurrent *uveitis…*
--A chronic *uveitis…*

A

Two forms of uveitic 2ndry OAG addressed in the Glaucoma *book*

Posner-Schlossman syndrome
(aka *glaucomatocyclitic crisis*)

--Unilateral
--Young to middle-aged adults
--Inflammation is…mild
--IOP elevation usually…**severe**
--Is a **recurrent** condition

Fuchs heterochromic iridocyclitis

--Unilateral
--Young to middle-aged adults
--Inflammation is…mild
--IOP elevation usually…**mild** (or absent)
--Is a **chronic** condition

Is it an **acute**, **chronic**, *or* **recurrent** *condition?*

What does it mean to say a uveitic condition is acute, recurrent *or* chronic*?*
--*An* acute *uveitis*…comes on suddenly, and resolves fairly quickly
--*A* recurrent *uveitis*…
--*A* chronic *uveitis*…

Q

Two forms of uveitic 2ndry OAG addressed in the Glaucoma *book*

Posner-Schlossman syndrome
(aka *glaucomatocyclitic crisis*)

--Unilateral
--Young to middle-aged adults
--Inflammation is…mild
--IOP elevation usually…**severe**
--Is a **recurrent** condition

Fuchs heterochromic iridocyclitis

--Unilateral
--Young to middle-aged adults
--Inflammation is…mild
--IOP elevation usually…**mild** (or absent)
--Is a **chronic** condition

Is it an **acute**, **chronic**, *or* **recurrent** *condition?*

What does it mean to say a uveitic condition is acute, recurrent *or* chronic*?*
--*An* acute *uveitis*…comes on suddenly, and resolves fairly quickly
--*A* recurrent *uveitis*…
--*A* chronic *uveitis*…

Q/A

Two forms of uveitic 2ndry OAG addressed in the Glaucoma *book*

Posner-Schlossman syndrome
(aka *glaucomatocyclitic crisis*)

--Unilateral
--Young to middle-aged adults
--Inflammation is…mild
--IOP elevation usually…**severe**
--Is a **recurrent** condition

Fuchs heterochromic iridocyclitis

--Unilateral
--Young to middle-aged adults
--Inflammation is…mild
--IOP elevation usually…**mild** (or absent)
--Is a **chronic** condition

Is it an **acute**, **chronic**, *or* **recurrent** *condition?*

What does it mean to say a uveitic condition is acute, recurrent *or* chronic?
--*An* acute *uveitis*…comes on suddenly, and resolves fairly quickly
--*A* recurrent *uveitis*…eventually relapses, but is quiescent off-treatment for at least period of time
--*A* chronic *uveitis*…

A

Two forms of uveitic 2ndry OAG addressed in the Glaucoma *book*

Posner-Schlossman syndrome
(aka *glaucomatocyclitic crisis*)

--Unilateral
--Young to middle-aged adults
--Inflammation is…mild
--IOP elevation usually…**severe**
--Is a **recurrent** condition

Fuchs heterochromic iridocyclitis

--Unilateral
--Young to middle-aged adults
--Inflammation is…mild
--IOP elevation usually…**mild** (or absent)
--Is a **chronic** condition

Is it an **acute**, **chronic**, *or* **recurrent** *condition?*

What does it mean to say a uveitic condition is acute, recurrent *or* chronic?
--*An* acute *uveitis*…comes on suddenly, and resolves fairly quickly
--*A* recurrent *uveitis*…eventually relapses, but is quiescent off-treatment for at least 3 months
--*A* chronic *uveitis*…

Q

Two forms of uveitic 2ndry OAG addressed in the Glaucoma *book*

Posner-Schlossman syndrome
(aka *glaucomatocyclitic crisis*)

--Unilateral
--Young to middle-aged adults
--Inflammation is…mild
--IOP elevation usually…**severe**
--Is a **recurrent** condition

Fuchs heterochromic iridocyclitis

--Unilateral
--Young to middle-aged adults
--Inflammation is…mild
--IOP elevation usually…**mild** (or absent)
--Is a **chronic** condition

Is it an **acute**, **chronic**, *or* **recurrent** *condition?*

What does it mean to say a uveitic condition is acute, recurrent *or* chronic?
--*An* acute *uveitis*…comes on suddenly, and resolves fairly quickly
--*A* recurrent *uveitis*…eventually relapses, but is quiescent off-treatment for at least 3 months
--*A* chronic *uveitis*…

Q/A

Two forms of uveitic 2ndry OAG addressed in the Glaucoma *book*

Posner-Schlossman syndrome
(aka *glaucomatocyclitic crisis*)

--Unilateral
--Young to middle-aged adults
--Inflammation is…mild
--IOP elevation usually…**severe**
--Is a **recurrent** condition

Fuchs heterochromic iridocyclitis

--Unilateral
--Young to middle-aged adults
--Inflammation is…mild
--IOP elevation usually…**mild** (or absent)
--Is a **chronic** condition

Is it an **acute**, **chronic**, *or* **recurrent** *condition?*

What does it mean to say a uveitic condition is acute, recurrent *or* chronic?
--*An* acute *uveitis*…comes on suddenly, and resolves fairly quickly
--*A* recurrent *uveitis*…eventually relapses, but is quiescent off-treatment for at least 3 months
--*A* chronic *uveitis*…**also** relapses, but its quiescent periods off-treatment last more v less than 3 months

A

Two forms of uveitic 2ndry OAG addressed in the Glaucoma *book*

Posner-Schlossman syndrome
(aka *glaucomatocyclitic crisis*)

--Unilateral
--Young to middle-aged adults
--Inflammation is…mild
--IOP elevation usually…**severe**
--Is a **recurrent** condition

Fuchs heterochromic iridocyclitis

--Unilateral
--Young to middle-aged adults
--Inflammation is…mild
--IOP elevation usually…**mild** (or absent)
--Is a **chronic** condition

Is it an **acute**, **chronic**, *or* **recurrent** *condition?*

What does it mean to say a uveitic condition is acute, recurrent *or* chronic?
--*An* acute *uveitis*…comes on suddenly, and resolves fairly quickly
--*A* recurrent *uveitis*…eventually relapses, but is quiescent off-treatment for at least 3 months
--*A* chronic *uveitis*…**also** relapses, but its quiescent periods off-treatment last **less** than 3 months

Two forms of uveitic 2ndry OAG addressed in the Glaucoma *book*

Posner-Schlossman syndrome
(aka *glaucomatocyclitic crisis*)

--Unilateral
--Young to middle-aged adults
--Inflammation is…mild
--IOP elevation usually…**severe**
--Is a **recurrent** condition

Fuchs heterochromic iridocyclitis

--Unilateral
--Young to middle-aged adults
--Inflammation is…mild
--IOP elevation usually…**mild** (or absent)
--Is a **chronic** condition

Is it an **acute**, **chronic**, *or* **recurrent** *condition?*

What does it mean to say a uveitic condition is acute, recurrent *or* chronic?
--*An* acute *uveitis*…comes on suddenly, and resolves fairly quickly
--*A* recurrent *uveitis*…eventually relapses, but is quiescent off-treatment for at least 3 months
--*A* chronic *uveitis*…**also** relapses, but its quiescent periods off-treatment last **less** than 3 months

Take special note of the difference between recurrent ***and*** chronic ***uveitis, a commonly misunderstood distinction***

Q

Two forms of uveitic 2ndry OAG addressed in the Glaucoma *book*

Posner-Schlossman syndrome
(aka *glaucomatocyclitic crisis*)

--Unilateral
--Young to middle-aged adults
--Inflammation is…mild
--IOP elevation usually…**severe**
--Is a **recurrent** condition
-- [redacted] response to steroids

Fuchs heterochromic iridocyclitis

--Unilateral
--Young to middle-aged adults
--Inflammation is…mild
--IOP elevation usually…**mild** (or absent)
--Is a **chronic** condition
-- [redacted] response to steroids

Does inflammation in each respond well, or poorly to steroids?

A

Two forms of uveitic 2ndry OAG addressed in the Glaucoma *book*

Posner-Schlossman syndrome
(aka *glaucomatocyclitic crisis*)

--Unilateral
--Young to middle-aged adults
--Inflammation is…mild
--IOP elevation usually…**severe**
--Is a **recurrent** condition
--**Good** response to steroids

Fuchs heterochromic iridocyclitis

--Unilateral
--Young to middle-aged adults
--Inflammation is…mild
--IOP elevation usually…**mild** (or absent)
--Is a **chronic** condition
--**Poor** response to steroids

Does inflammation in each respond well, or poorly to steroids?

Q

Two forms of uveitic 2ndry OAG addressed in the Glaucoma *book*

Posner-Schlossman syndrome
(aka *glaucomatocyclitic crisis*)

--Unilateral
--Young to middle-aged adults
--Inflammation is…mild
--IOP elevation usually…**severe**
--Is a **recurrent** condition
--**Good** response to steroids
--KP are 'white and ____'

Fuchs heterochromic iridocyclitis

--Unilateral
--Young to middle-aged adults
--Inflammation is…mild
--IOP elevation usually…**mild** (or absent)
--Is a **chronic** condition
--**Poor** response to steroids
--KP are 'white and ____'

What is the classic descriptor of the shape of KP for each?

A

Two forms of uveitic 2ndry OAG addressed in the Glaucoma *book*

Posner-Schlossman syndrome
(aka *glaucomatocyclitic crisis*)

--Unilateral
--Young to middle-aged adults
--Inflammation is…mild
--IOP elevation usually…**severe**
--Is a **recurrent** condition
--**Good** response to steroids
--KP are 'white and **round** '

Fuchs heterochromic iridocyclitis

--Unilateral
--Young to middle-aged adults
--Inflammation is…mild
--IOP elevation usually…**mild** (or absent)
--Is a **chronic** condition
--**Poor** response to steroids
--KP are 'white and **stellate** '

What is the classic descriptor of the shape of KP for each?

Q

Two forms of uveitic 2ndry OAG addressed in the Glaucoma *book*

Posner-Schlossman syndrome
(aka *glaucomatocyclitic crisis*)

--Unilateral
--Young to middle-aged adults
--Inflammation is…mild
--IOP elevation usually…**severe**
--Is a **recurrent** condition
--**Good** response to steroids
--KP are 'white and **round** '

Fuchs heterochromic iridocyclitis

--Unilateral
--Young to middle-aged adults
--Inflammation is…mild
--IOP elevation usually…**mild** (or absent)
--Is a **chronic** condition
--**Poor** response to steroids
--KP are 'white and **stellate** '

Are the KP distributed diffusely, or limited to Arlt's triangle?

A

Two forms of uveitic 2ndry OAG addressed in the Glaucoma *book*

Posner-Schlossman syndrome
(aka *glaucomatocyclitic crisis*)

--Unilateral
--Young to middle-aged adults
--Inflammation is…mild
--IOP elevation usually…**severe**
--Is a **recurrent** condition
--**Good** response to steroids
--KP are 'white and **round** '

Fuchs heterochromic iridocyclitis

--Unilateral
--Young to middle-aged adults
--Inflammation is…mild
--IOP elevation usually…**mild** (or absent)
--Is a **chronic** condition
--**Poor** response to steroids
--KP are 'white and **stellate** '

Are the KP distributed diffusely, or limited to Arlt's triangle?
They are diffusely distributed in both conditions

Open-angle Glaucoma: *Secondary*

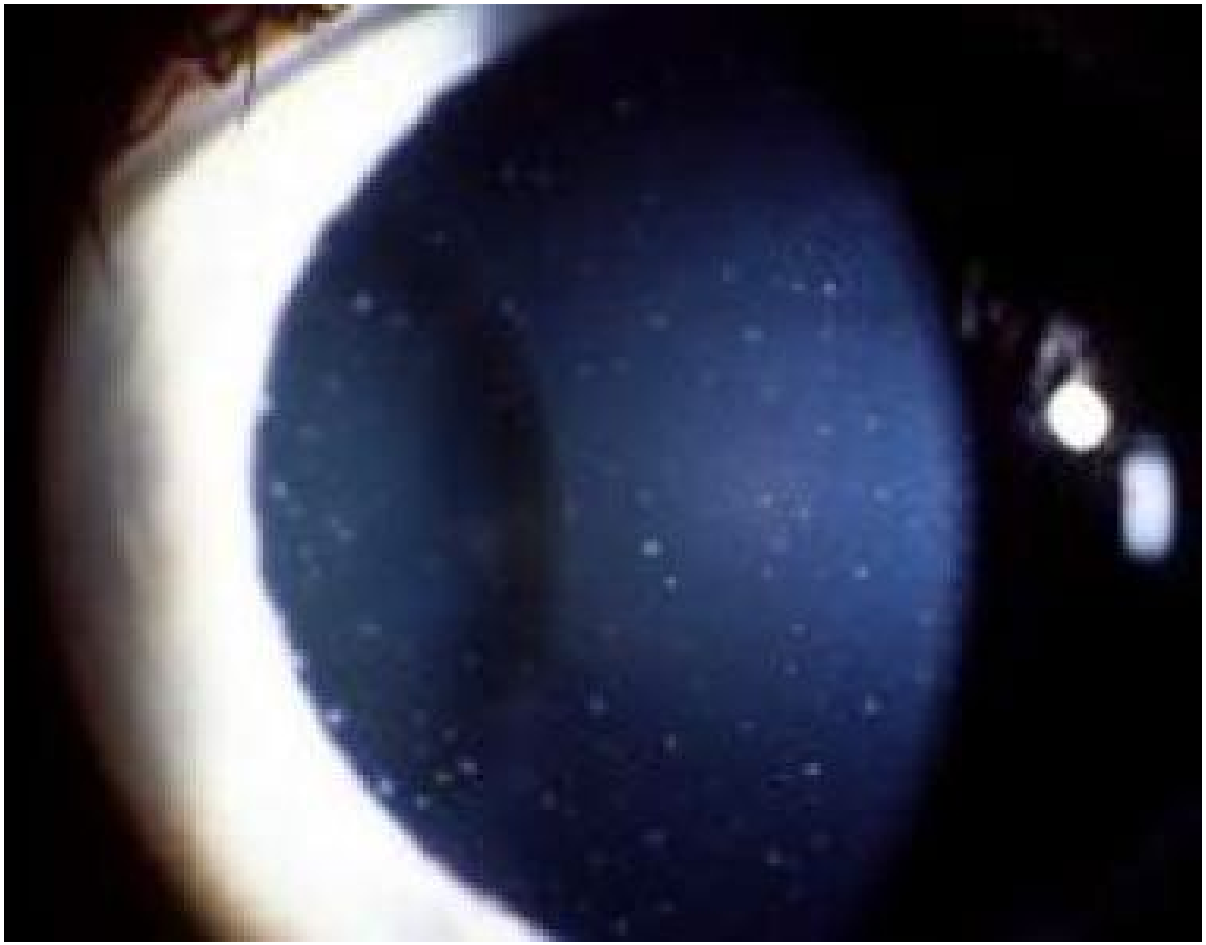

FHI: Stellate KP. Note the diffuse distribution

Q

Two forms of uveitic 2ndry OAG addressed in the Glaucoma *book*

Posner-Schlossman syndrome
(aka *glaucomatocyclitic crisis*)

--Unilateral
--Young to middle-aged adults
--Inflammation is…mild
--IOP elevation usually…**severe**
--Is a **recurrent** condition
--**Good** response to steroids
--KP are 'white and **round** '

Fuchs heterochromic iridocyclitis

--Unilateral
--Young to middle-aged adults
--Inflammation is…mild
--IOP elevation usually…**mild** (or absent)
--Is a **chronic** condition
--**Poor** response to steroids
--KP are 'white and **stellate** '

Are the KP distributed diffusely, or limited to ***Arlt's triangle****?*
They are diffusely distributed in both conditions

Where is Arlt's triangle *located?*

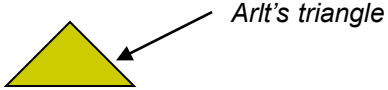

A

Two forms of uveitic 2ndry OAG addressed in the Glaucoma *book*

Posner-Schlossman syndrome
(aka *glaucomatocyclitic crisis*)

--Unilateral
--Young to middle-aged adults
--Inflammation is…mild
--IOP elevation usually…**severe**
--Is a **recurrent** condition
--**Good** response to steroids
--KP are 'white and **round** '

Fuchs heterochromic iridocyclitis

--Unilateral
--Young to middle-aged adults
--Inflammation is…mild
--IOP elevation usually…**mild** (or absent)
--Is a **chronic** condition
--**Poor** response to steroids
--KP are 'white and **stellate** '

Are the KP distributed diffusely, or limited to ***Arlt's triangle****?*
They are diffusely distributed in both conditions

Where is Arlt's triangle *located?*
Its apex is at the corneal center, and base in the inferior cornea

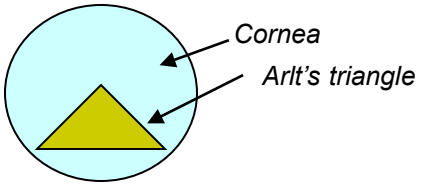

Q

Two forms of uveitic 2ndry OAG addressed in the Glaucoma *book*

Posner-Schlossman syndrome
(aka *glaucomatocyclitic crisis*)

--Unilateral
--Young to middle-aged adults
--Inflammation is…mild
--IOP elevation usually…**severe**
--Is a **recurrent** condition
--**Good** response to steroids
--KP are 'white and **round** '

Fuchs heterochromic iridocyclitis

--Unilateral
--Young to middle-aged adults
--Inflammation is…mild
--IOP elevation usually…**mild** (or absent)
--Is a **chronic** condition
--**Poor** response to steroids
--KP are 'white and **stellate** '

Which is associated with heterochromia iridis?





A

Two forms of uveitic 2ndry OAG addressed in the Glaucoma *book*

Posner-Schlossman syndrome
(aka *glaucomatocyclitic crisis*)

--Unilateral
--Young to middle-aged adults
--Inflammation is…mild
--IOP elevation usually…**severe**
--Is a **recurrent** condition
--**Good** response to steroids
--KP are 'white and **round** '

Fuchs heterochromic iridocyclitis

--Unilateral
--Young to middle-aged adults
--Inflammation is…mild
--IOP elevation usually…**mild** (or absent)
--Is a **chronic** condition
--**Poor** response to steroids
--KP are 'white and **stellate** '
--Associated with heterochromia iridis

Which is associated with heterochromia iridis?





Open-angle Glaucoma: *Secondary*

FHI: Heterochromia

Q

Two forms of uveitic 2ndry OAG addressed in the Glaucoma *book*

Posner-Schlossman syndrome
(aka *glaucomatocyclitic crisis*)

--Unilateral
--Young to middle-aged adults
--Inflammation is…mild
--IOP elevation usually…**severe**
--Is a **recurrent** condition
--**Good** response to steroids
--KP are 'white and **round** '

Fuchs heterochromic iridocyclitis

--Unilateral
--Young to middle-aged adults
--Inflammation is…mild
--IOP elevation usually…**mild** (or absent)
--Is a **chronic** condition
--**Poor** response to steroids
--KP are 'white and **stellate** '
--Associated with **heterochromia iridis**

*Is the affected eye the **darker** eye or the **lighter** eye?*

Which is associated with heterochromia iridis?

?



?



A

Two forms of uveitic 2ndry OAG addressed in the Glaucoma *book*

Posner-Schlossman syndrome
(aka *glaucomatocyclitic crisis*)

--Unilateral
--Young to middle-aged adults
--Inflammation is…mild
--IOP elevation usually…**severe**
--Is a **recurrent** condition
--**Good** response to steroids
--KP are 'white and **round** '

Fuchs heterochromic iridocyclitis

--Unilateral
--Young to middle-aged adults
--Inflammation is…mild
--IOP elevation usually…**mild** (or absent)
--Is a **chronic** condition
--**Poor** response to steroids
--KP are 'white and **stellate** '
--Associated with **heterochromia iridis**

*Is the affected eye the **darker** eye or the **lighter** eye?*
The lighter (with one exception)

Which is associated with heterochromia iridis?

Q

Two forms of uveitic 2ndry OAG addressed in the Glaucoma *book*

Posner-Schlossman syndrome
(aka *glaucomatocyclitic crisis*)

--Unilateral
--Young to middle-aged adults
--Inflammation is…mild

Fuchs heterochromic iridocyclitis

--Unilateral
--Young to middle-aged adults
--Inflammation is…mild
--IOP elevation usually…**mild** (or absent)
ondition
to steroids
nd **stellate**
heterochromia iridis

What is the exception; ie, under what circumstances is the **darker** *eye the one with FHI?*

Is the affected eye the darker eye or the lighter eye?
The lighter (**with one exception**)
Which is associated with heterochromia iridis?





A

Two forms of uveitic 2ndry OAG addressed in the Glaucoma *book*

Posner-Schlossman syndrome
(aka *glaucomatocyclitic crisis*)

--Unilateral
--Young to middle-aged adults
--Inflammation is…mild

Fuchs heterochromic iridocyclitis

--Unilateral
--Young to middle-aged adults
--Inflammation is…mild
--IOP elevation usually…**mild** (or absent)
ondition
to steroids
nd **stellate**
heterochromia iridis

What is the exception; ie, under what circumstances is the **darker** *eye the one with FHI?*
In individuals with light-blue eyes…

Is the affected eye the darker eye or the lighter eye?
The lighter (**with one exception**)
Which is associated with heterochromia iridis?





A

Two forms of uveitic 2ndry OAG addressed in the Glaucoma *book*

Posner-Schlossman syndrome
(aka *glaucomatocyclitic crisis*)

--Unilateral
--Young to middle-aged adults
--Inflammation is…mild

Fuchs heterochromic iridocyclitis

--Unilateral
--Young to middle-aged adults
--Inflammation is…mild
--IOP elevation usually…**mild** (or absent)
ondition
to steroids
nd **stellate**
heterochromia iridis

What is the exception; ie, under what circumstances is the **darker** *eye the one with FHI?*
In individuals with light-blue eyes…the iris atrophy stemming from the FHI process will make visible the **darkly-pigmented epithelium of the posterior iris, thus making the eye appear darker**

Is the affected eye the darker eye or the lighter eye?
The lighter (with one exception)
Which is associated with heterochromia iridis?

Q

Two forms of uveitic 2ndry OAG addressed in the Glaucoma *book*

Posner-Schlossman syndrome
(aka *glaucomatocyclitic crisis*)

--Unilateral

Fuchs heterochromic iridocyclitis

--Unilateral
--Young to middle-aged adults
…mild
usually…**mild** (or absent)
ondition
to steroids
nd **stellate**
heterochromia iridis

In addition to heterochromia, the atrophic changes give the iris an appearance that has been likened to damage caused by an insect. What is the two-word description for this appearance?

iris atrophy

In individuals with light-blue eyes…the FHI process will make visible the **darkly-pigmented epithelium of the posterior iris, thus making the eye appear darker**

Is the affected eye the darker eye or the lighter eye?

The lighter (with one exception)

Which is associated with heterochromia iridis?





A

Two forms of uveitic 2ndry OAG addressed in the Glaucoma *book*

Posner-Schlossman syndrome
(aka *glaucomatocyclitic crisis*)

--Unilateral

Fuchs heterochromic iridocyclitis

--Unilateral
--Young to middle-aged adults
…mild
usually…**mild** (or absent)
ondition
to steroids
nd **stellate**
heterochromia iridis

In addition to heterochromia, the atrophic changes give the iris an appearance that has been likened to damage caused by an insect. What is the two-word description for this appearance?
'Moth eaten'

In individuals with light-blue eyes…the **iris atrophy** stemming from the FHI process will make visible the **darkly-pigmented epithelium of the posterior iris, thus making the eye appear darker**

Is the affected eye the darker eye or the lighter eye?
The lighter (with one exception)

Which is associated with heterochromia iridis?





Open-angle Glaucoma: *Secondary*

FHI: ‘Moth eaten’ iris. Note the smooth stromal architecture and loss of iris crypts

Q

Two forms of uveitic 2ndry OAG addressed in the Glaucoma *book*

Posner-Schlossman syndrome
(aka *glaucomatocyclitic crisis*)

--Unilateral
--Young to middle-aged adults
--Inflammation is…mild
--IOP elevation usually…**severe**
--Is a **recurrent** condition
--**Good** response to steroids
--KP are 'white and **round** '

Fuchs heterochromic iridocyclitis

--Unilateral
--Young to middle-aged adults
--Inflammation is…mild
--IOP elevation usually…**mild** (or absent)
--Is a **chronic** condition
--**Poor** response to steroids
--KP are 'white and **stellate** '
--Associated with heterochromia iridis

Which is associated with NVI and NVA?

A

Two forms of uveitic 2ndry OAG addressed in the Glaucoma *book*

Posner-Schlossman syndrome
(aka *glaucomatocyclitic crisis*)

--Unilateral
--Young to middle-aged adults
--Inflammation is…mild
--IOP elevation usually…**severe**
--Is a **recurrent** condition
--**Good** response to steroids
--KP are 'white and **round** '

Fuchs heterochromic iridocyclitis

--Unilateral
--Young to middle-aged adults
--Inflammation is…mild
--IOP elevation usually…**mild** (or absent)
--Is a **chronic** condition
--**Poor** response to steroids
--KP are 'white and **stellate** '
--Associated with heterochromia iridis
--Associated with NVI and NVA

Which is associated with NVI and NVA?

Q

Two forms of uveitic 2ndry OAG addressed in the Glaucoma *book*

Posner-Schlossman syndrome
(aka *glaucomatocyclitic crisis*)

--Unilateral
--Young to middle-aged adults
--Inflammation is…mild
--IOP elevation usually…**severe**
--Is a **recurrent** condition
--**Good** response to steroids
--KP are 'white and **round** '

Fuchs heterochromic iridocyclitis

--Unilateral
--Young to middle-aged adults
--Inflammation is…mild
--IOP elevation usually…**mild** (or absent)
--Is a **chronic** condition
--**Poor** response to steroids
--KP are 'white and **stellate** '
--Associated with heterochromia iridis
--**Associated with NVI and NVA**

Which is associated with

Do NVI and NVA in FHI lead to PAS and NVG?

A

Two forms of uveitic 2ndry OAG addressed in the Glaucoma *book*

Posner-Schlossman syndrome
(aka *glaucomatocyclitic crisis*)

--Unilateral
--Young to middle-aged adults
--Inflammation is…mild
--IOP elevation usually…**severe**
--Is a **recurrent** condition
--**Good** response to steroids
--KP are 'white and **round** '

Fuchs heterochromic iridocyclitis

--Unilateral
--Young to middle-aged adults
--Inflammation is…mild
--IOP elevation usually…**mild** (or absent)
--Is a **chronic** condition
--**Poor** response to steroids
--KP are 'white and **stellate** '
--Associated with heterochromia iridis
--**Associated with NVI and NVA**, but PAS and/or NVG rarely develop

Which is associated with

Do NVI and NVA in FHI lead to PAS and NVG?
Only rarely

Q

Two forms of uveitic 2ndry OAG addressed in the Glaucoma *book*

Posner-Schlossman syndrome
(aka *glaucomatocyclitic crisis*)

--Unilateral
--Young to middle-aged adults
--Inflammation is…mild
--IOP elevation usually…**severe**
--Is a **recurrent** condition
--**Good** response to steroids
--KP are 'white and **round** '

Fuchs heterochromic iridocyclitis

--Unilateral
--Young to middle-aged adults
--Inflammation is…mild
--IOP elevation usually…**mild** (or absent)
--Is a **chronic** condition
--**Poor** response to steroids
--KP are 'white and **stellate** '
--Associated with heterochromia iridis
--**Associated with NVI and NVA**, but PAS and/or NVG rarely develop

The NVA vessels in FHI rupture easily, and it not uncommon for FHI pts to develop a small hyphema when the paracentesis wound is made at the start of cataract surgery. What is the eponymous name for this classic finding?

A

Two forms of uveitic 2ndry OAG addressed in the Glaucoma *book*

Posner-Schlossman syndrome
(aka *glaucomatocyclitic crisis*)

--Unilateral
--Young to middle-aged adults
--Inflammation is…mild
--IOP elevation usually…**severe**
--Is a **recurrent** condition
--**Good** response to steroids
--KP are 'white and **round** '

Fuchs heterochromic iridocyclitis

--Unilateral
--Young to middle-aged adults
--Inflammation is…mild
--IOP elevation usually…**mild** (or absent)
--Is a **chronic** condition
--**Poor** response to steroids
--KP are 'white and **stellate** '
--Associated with heterochromia iridis
--**Associated with NVI and NVA**, but PAS and/or NVG rarely develop

The NVA vessels in FHI rupture easily, and it not uncommon for FHI pts to develop a small hyphema when the paracentesis wound is made at the start of cataract surgery. What is the eponymous name for this classic finding?
Amsler's sign

Q

Two forms of uveitic 2ndry OAG addressed in the Glaucoma *book*

Posner-Schlossman syndrome
(aka *glaucomatocyclitic crisis*)

--Unilateral
--Young to middle-aged adults
--Inflammation is…mild
--IOP elevation usually…**severe**
--Is a **recurrent** condition
--**Good** response to steroids
--KP are 'white and **round** '

Fuchs heterochromic iridocyclitis

--Unilateral
--Young to middle-aged adults
--Inflammation is…mild
--IOP elevation usually…**mild** (or absent)
--Is a **chronic** condition
--**Poor** response to steroids
--KP are 'white and **stellate** '
--Associated with heterochromia iridis
--**Associated with NVI and NVA**, but PAS and/or NVG rarely develop

The NVA vessels in FHI rupture easily, and it not uncommon for FHI pts to develop a small hyphema when the paracentesis wound is made at the start of cataract surgery. What is the eponymous name for this classic finding?
Amsler's sign

Is Amsler's sign pathognomonic for FHI?

A

Two forms of uveitic 2ndry OAG addressed in the Glaucoma *book*

Posner-Schlossman syndrome
(aka *glaucomatocyclitic crisis*)

--Unilateral
--Young to middle-aged adults
--Inflammation is…mild
--IOP elevation usually…**severe**
--Is a **recurrent** condition
--**Good** response to steroids
--KP are 'white and **round** '

Fuchs heterochromic iridocyclitis

--Unilateral
--Young to middle-aged adults
--Inflammation is…mild
--IOP elevation usually…**mild** (or absent)
--Is a **chronic** condition
--**Poor** response to steroids
--KP are 'white and **stellate** '
--Associated with heterochromia iridis
--**Associated with NVI and NVA**, but PAS and/or NVG rarely develop

The NVA vessels in FHI rupture easily, and it not uncommon for FHI pts to develop a small hyphema when the paracentesis wound is made at the start of cataract surgery. What is the eponymous name for this classic finding?
Amsler's sign

Is Amsler's sign pathognomonic for FHI?
No

Q

Two forms of uveitic 2ndry OAG addressed in the Glaucoma *book*

Posner-Schlossman syndrome
(aka *glaucomatocyclitic crisis*)

--Unilateral
--Young to middle-aged adults
--Inflammation is…mild
--IOP elevation usually…**severe**
--Is a **recurrent** condition
--**Good** response to steroids
--KP are 'white and **round** '

Fuchs heterochromic iridocyclitis

--Unilateral
--Young to middle-aged adults
--Inflammation is…mild
--IOP elevation usually…**mild** (or absent)
--Is a **chronic** condition
--**Poor** response to steroids
--KP are 'white and **stellate** '
--Associated with heterochromia iridis
--**Associated with NVI and NVA**, but PAS and/or NVG rarely develop

The NVA vessels in FHI rupture easily, and it not uncommon for FHI pts to develop a small hyphema when the paracentesis wound is made at the start of cataract surgery.

Can other clinical maneuvers cause these vessels to bleed?

assic finding?
Amsler's sign

Is Amsler's sign pathognomonic for FHI?
No

Q/A

Two forms of uveitic 2ndry OAG addressed in the Glaucoma *book*

Posner-Schlossman syndrome
(aka *glaucomatocyclitic crisis*)

--Unilateral
--Young to middle-aged adults
--Inflammation is…mild
--IOP elevation usually…**severe**
--Is a **recurrent** condition
--**Good** response to steroids
--KP are 'white and **round** '

Fuchs heterochromic iridocyclitis

--Unilateral
--Young to middle-aged adults
--Inflammation is…mild
--IOP elevation usually…**mild** (or absent)
--Is a **chronic** condition
--**Poor** response to steroids
--KP are 'white and **stellate** '
--Associated with heterochromia iridis
--**Associated with NVI and NVA**, but PAS and/or NVG rarely develop

The NVA vessels in FHI rupture easily, and it not uncommon for FHI pts to develop a small hyphema when the paracentesis wound is made at the start of cataract surgery.

Can other clinical maneuvers cause these vessels to bleed?
Yes—hyphema in FHI can occur subsequent to [redacted], and even [redacted] two words

assic finding?
Amsler's sign

Is Amsler's sign pathognomonic for FHI?
No

A

Two forms of uveitic 2ndry OAG addressed in the Glaucoma *book*

Posner-Schlossman syndrome
(aka *glaucomatocyclitic crisis*)

--Unilateral
--Young to middle-aged adults
--Inflammation is…mild
--IOP elevation usually…**severe**
--Is a **recurrent** condition
--**Good** response to steroids
--KP are 'white and **round** '

Fuchs heterochromic iridocyclitis

--Unilateral
--Young to middle-aged adults
--Inflammation is…mild
--IOP elevation usually…**mild** (or absent)
--Is a **chronic** condition
--**Poor** response to steroids
--KP are 'white and **stellate** '
--Associated with heterochromia iridis
--**Associated with NVI and NVA**, but PAS and/or NVG rarely develop

The NVA vessels in FHI rupture easily, and it not uncommon for FHI pts to develop a small hyphema when the paracentesis wound is made at the start of cataract surgery.

Can other clinical maneuvers cause these vessels to bleed?
Yes—hyphema in FHI can occur subsequent to gonioscopy , and even applanation tonometry

assic finding?
Amsler's sign

Is Amsler's sign pathognomonic for FHI?
No

Q

Two forms of uveitic 2ndry OAG addressed in the Glaucoma *book*

Posner-Schlossman syndrome
(aka *glaucomatocyclitic crisis*)

--Unilateral
--Young to middle-aged adults
--Inflammation is…mild
--IOP elevation usually…**severe**
--Is a **recurrent** condition
--**Good** response to steroids
--KP are 'white and **round** '

Fuchs heterochromic iridocyclitis

--Unilateral
--Young to middle-aged adults
--Inflammation is…mild
--IOP elevation usually…**mild** (or absent)
--Is a **chronic** condition
--**Poor** response to steroids
--KP are 'white and **stellate** '
--Associated with heterochromia iridis
--Associated with NVI and NVA, but PAS and/or NVG rarely develop

Which has a strong association with cataract, and with what type of cataract is it associated?

A

Two forms of uveitic 2ndry OAG addressed in the Glaucoma *book*

Posner-Schlossman syndrome
(aka *glaucomatocyclitic crisis*)

--Unilateral
--Young to middle-aged adults
--Inflammation is…mild
--IOP elevation usually…**severe**
--Is a **recurrent** condition
--**Good** response to steroids
--KP are 'white and **round** '

Fuchs heterochromic iridocyclitis

--Unilateral
--Young to middle-aged adults
--Inflammation is…mild
--IOP elevation usually…**mild** (or absent)
--Is a **chronic** condition
--**Poor** response to steroids
--KP are 'white and **stellate** '
--Associated with heterochromia iridis
--Associated with NVI and NVA, but PAS and/or NVG rarely develop
--Associated with PSC

Which has a strong association with cataract, and with what type of cataract is it associated?

Open-angle Glaucoma: *Secondary*

FHI: Note the cataract

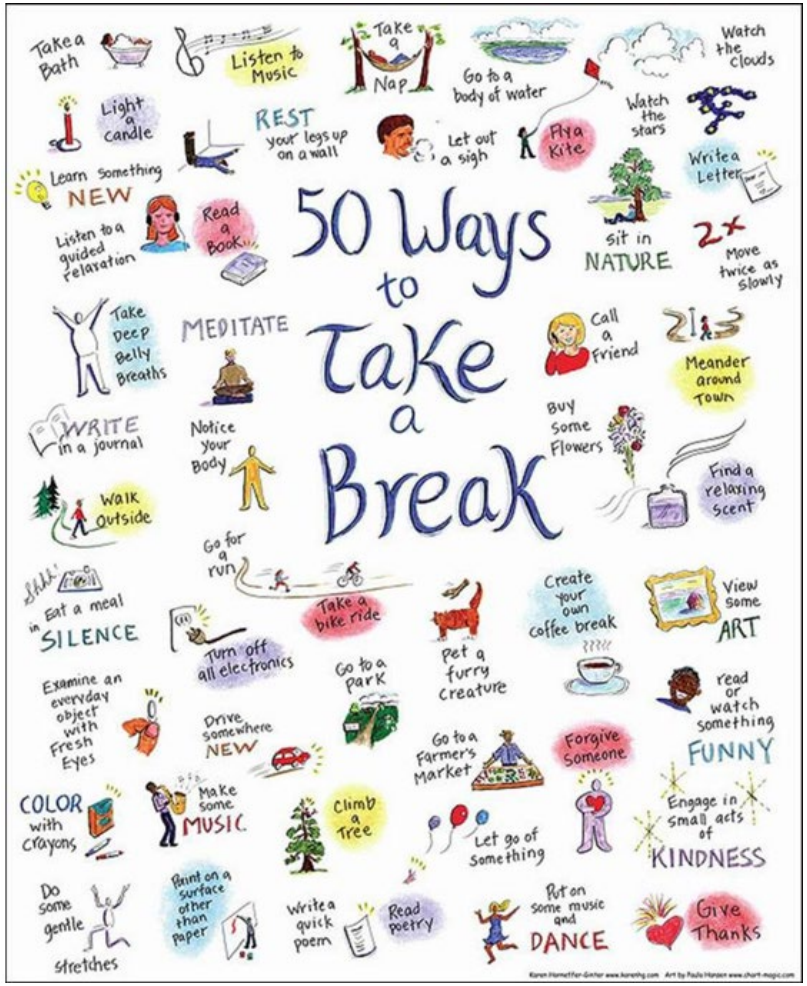

(This is a good point in the set to take a break)

Open-angle Glaucoma: *Secondary*

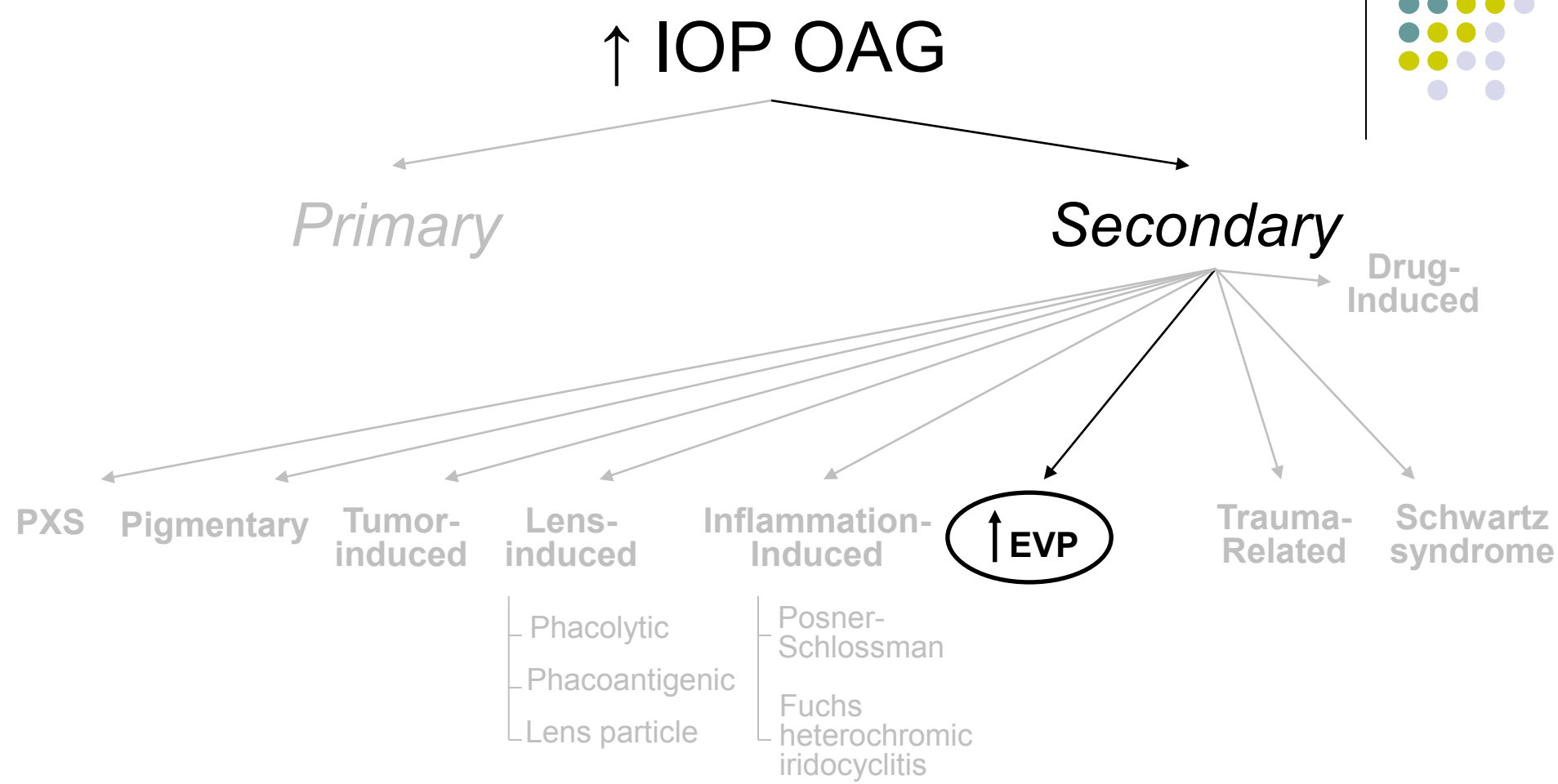

Next let's take a look at OAG secondary to increased EVP

Q

Open-angle Glaucoma: *Secondary*

OAG 2ndry to ↑ EVP

What does EVP *stand for in this context?*

A

Open-angle Glaucoma: *Secondary*

OAG 2ndry to ↑ EVP

What does EVP *stand for in this context?*
Episcleral venous pressure, ie, the BP in the episcleral venous plexus

Q

Open-angle Glaucoma: *Secondary*

OAG 2ndry to ↑ EVP

What does EVP *stand for in this context?*
Episcleral venous pressure, ie, the BP in the episcleral venous plexus

What is the episcleral venous plexus*?*

A

Open-angle Glaucoma: *Secondary*

OAG 2ndry to ↑ EVP

What does EVP *stand for in this context?*
Episcleral venous pressure, ie, the BP in the episcleral venous plexus

What is the episcleral venous plexus*?*

The episcleral venous plexus is the network of venous channels located in the episclera in the peri-limbal region

Q

Open-angle Glaucoma: *Secondary*

OAG 2ndry to ↑ EVP

What does EVP *stand for in this context?*
Episcleral venous pressure, ie, the BP in the episcleral venous plexus

What is the episcleral venous plexus*?*

The episcleral venous plexus is the network of venous channels located in the **episclera** in the peri-limbal region

What is the episclera*?*

A

Open-angle Glaucoma: *Secondary*

OAG 2ndry to ↑ EVP

What does EVP *stand for in this context?*
Episcleral venous pressure, ie, the BP in the episcleral venous plexus

What is the episcleral venous plexus*?*

The episcleral venous plexus is the network of venous channels located in the **episclera** in the peri-limbal region

What is the episclera*?*
The outermost of the three layers of the sclera

Q

Open-angle Glaucoma: *Secondary*

OAG 2ndry to ↑ EVP

What does EVP *stand for in this context?*
Episcleral venous pressure, ie, the BP in the episcleral venous plexus

What is the episcleral venous plexus*?*

The episcleral venous plexus is the network of venous channels located in the **episclera** in the peri-limbal region

What is the episclera*?*
The outermost of the three layers of the sclera

Out to in, what are the other two layers?
--Episclera
--***?***
--

A

Open-angle Glaucoma: *Secondary*

OAG 2ndry to ↑ EVP

What does EVP *stand for in this context?*
Episcleral venous pressure, ie, the BP in the episcleral venous plexus

What is the episcleral venous plexus*?*

The episcleral venous plexus is the network of venous channels located in the **episclera** in the peri-limbal region

What is the episclera*?*
The outermost of the three layers of the sclera

Out to in, what are the other two layers?
--Episclera
--Stroma
--**?**

A

Open-angle Glaucoma: *Secondary*

OAG 2ndry to ↑ EVP

What does EVP *stand for in this context?*
Episcleral venous pressure, ie, the BP in the episcleral venous plexus

What is the episcleral venous plexus*?*

The episcleral venous plexus is the network of venous channels located in the **episclera** in the peri-limbal region

What is the episclera*?*
The outermost of the three layers of the sclera

Out to in, what are the other two layers?
--Episclera
--Stroma
--Lamina fusca

Open-angle Glaucoma: *Secondary*

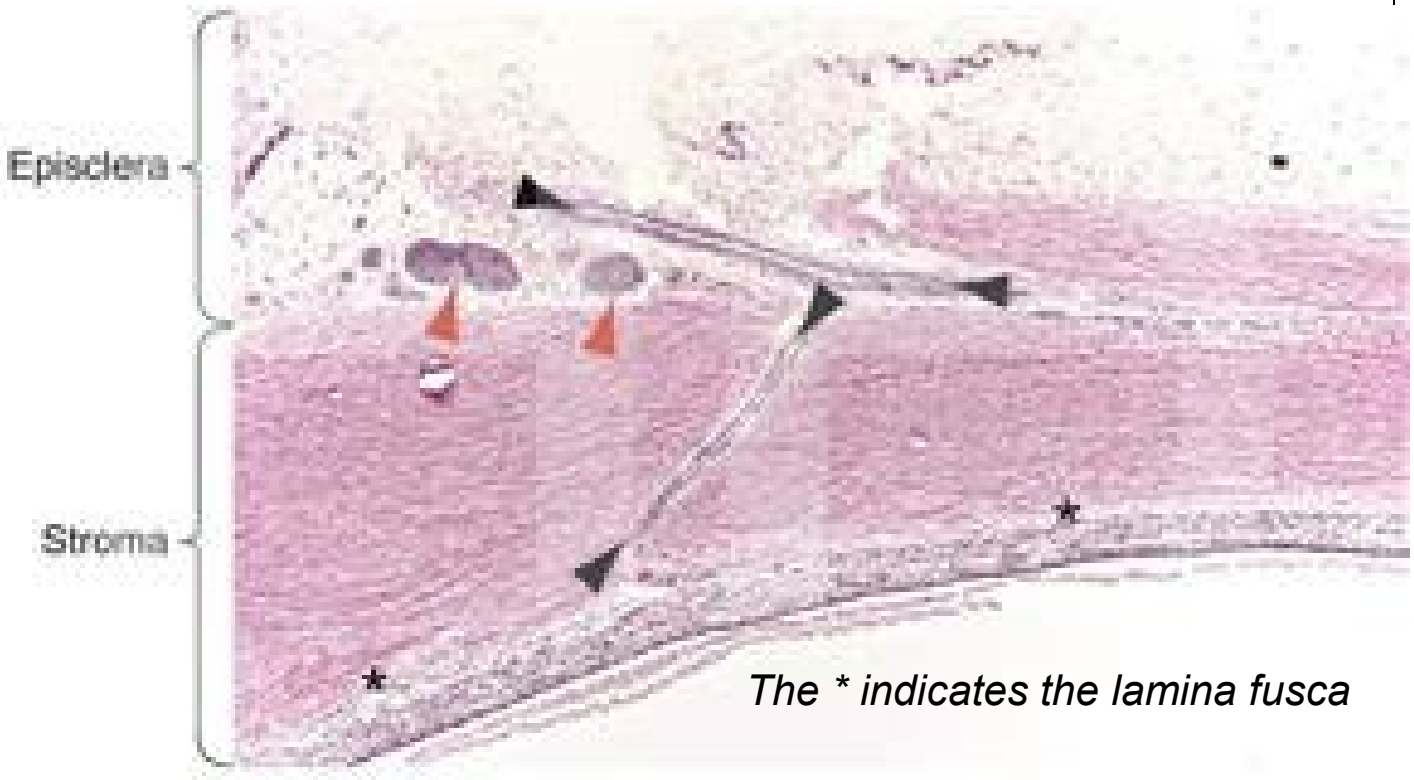

Sclera: Anatomy

Q

Open-angle Glaucoma: *Secondary*

OAG 2ndry to ↑ EVP

What does EVP *stand for in this context?*
Episcleral venous pressure, ie, the BP in the episcleral venous plexus

What is the episcleral venous plexus*? From where does it receive its intake?*

Next Q

The episcleral venous plexus is the network of venous channels located in the episclera in the peri-limbal region

Q/A

Open-angle Glaucoma: *Secondary*

OAG 2ndry to ↑ EVP

What does EVP *stand for in this context?*
Episcleral venous pressure, ie, the BP in the episcleral venous plexus

What is the episcleral venous plexus*? From where does it receive its intake?*

Next Q

The episcleral venous plexus is the network of venous channels located in the episclera in the peri-limbal region. So-called two words carry aqueous to it that drained from Schlemm's canal via collector channels.

A

Open-angle Glaucoma: *Secondary*

OAG 2ndry to ↑ EVP

What does EVP *stand for in this context?*
Episcleral venous pressure, ie, the BP in the episcleral venous plexus

What is the episcleral venous plexus*? From where does it receive its intake?*

Next Q

The episcleral venous plexus is the network of venous channels located in the episclera in the peri-limbal region. So-called aqueous veins carry aqueous to it that drained from Schlemm's canal via collector channels.

Open-angle Glaucoma: *Secondary*

Looky here

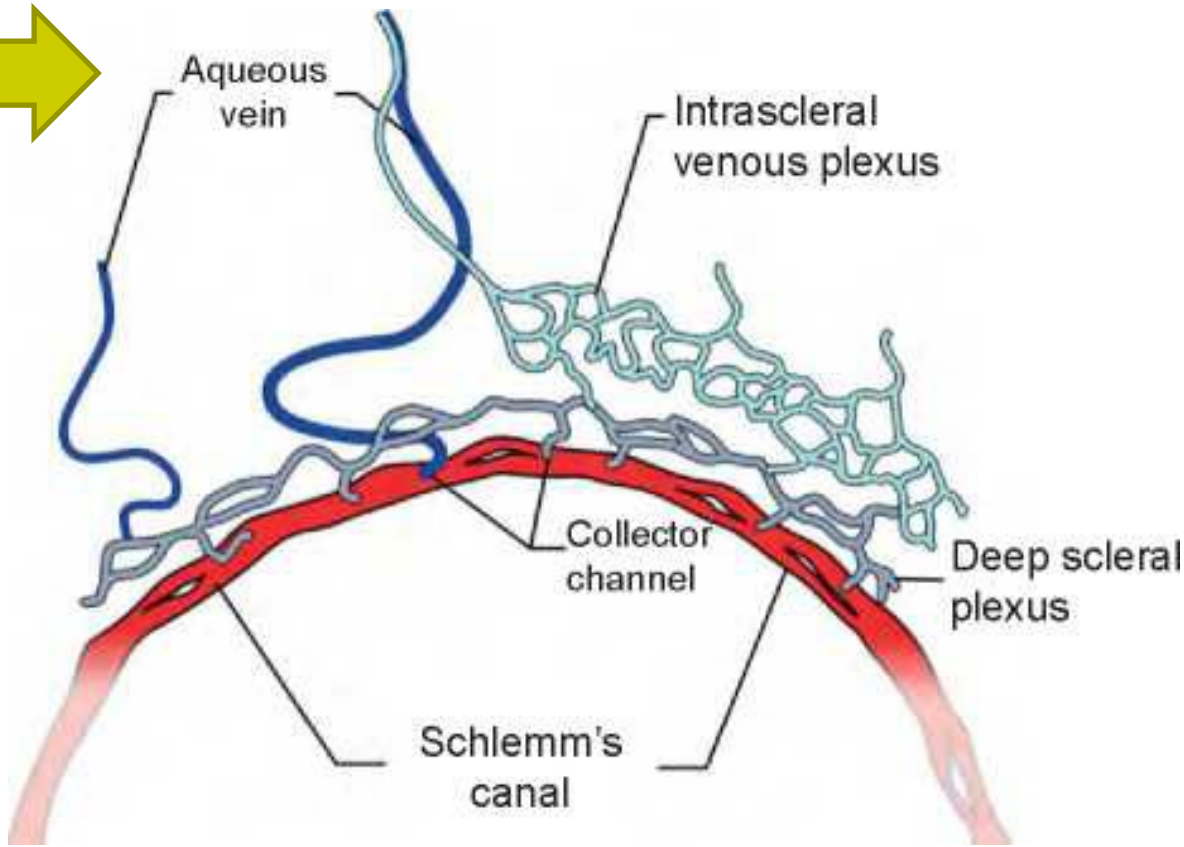

Conventional aqueous outflow pathway

Open-angle Glaucoma: *Secondary*

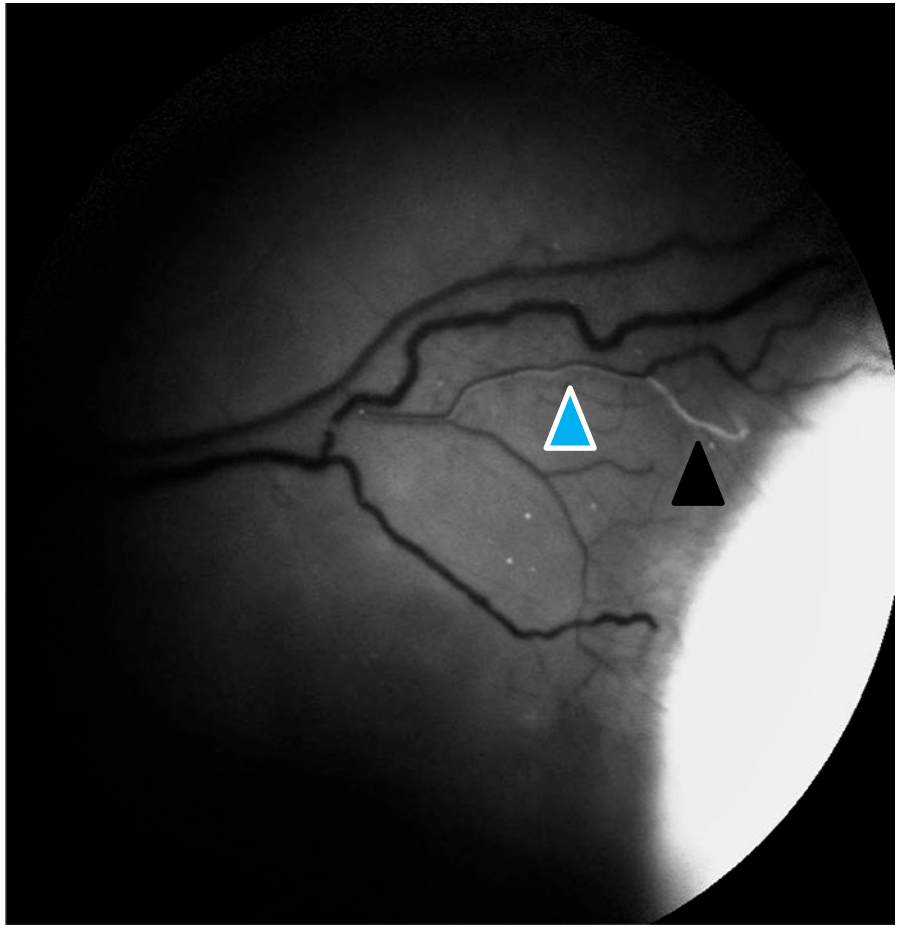

Aqueous vein. Note that the first portion (*black arrowhead*) contains only aqueous, whereas upon emptying into a venule, laminar flow consisting of separate aqueous and blood columns can be seen (*blue arrowhead*)

Q

Open-angle Glaucoma: *Secondary*

Next Q

OAG 2ndry to ↑ EVP

What does EVP *stand for in this context?*
Episcleral venous pressure, ie, the BP in the episcleral venous plexus

What is the episcleral venous plexus*? From where does it receive its intake? To where does it subsequently discharge that intake?*
The episcleral venous plexus is the network of venous channels located in the episclera in the peri-limbal region. So-called aqueous veins carry aqueous to it that drained from Schlemm's canal via collector channels.

A

Open-angle Glaucoma: *Secondary*

Next Q

OAG 2ndry to ↑ EVP

What does EVP *stand for in this context?*
Episcleral venous pressure, ie, the BP in the episcleral venous plexus

What is the episcleral venous plexus*? From where does it receive its intake? To where does it subsequently discharge that intake?*
The episcleral venous plexus is the network of venous channels located in the episclera in the peri-limbal region. So-called aqueous veins carry aqueous to it that drained from Schlemm's canal via collector channels. The plexus eventually discharges into uveal vessels that subsequently empty into the vortex veins.

Q

Open-angle Glaucoma: *Secondary*

OAG 2ndry to ↑ EVP

What does EVP *stand for in this context?*
Episcleral venous pressure, ie, the BP in the episcleral venous plexus

What is the episcleral venous plexus*? From where does it receive its intake? To where does it subsequently discharge that intake?*
The episcleral venous plexus is the network of venous channels located in the episclera in the peri-limbal region. So-called aqueous veins carry aqueous to it that drained from Schlemm's canal via collector channels. The plexus eventually discharges into uveal vessels that subsequently empty into the vortex veins.

There are two main pathways for blood leaving the globe. What are they?

A

Open-angle Glaucoma: *Secondary*

OAG 2ndry to ↑ EVP

What does EVP *stand for in this context?*
Episcleral venous pressure, ie, the BP in the episcleral venous plexus

What is the episcleral venous plexus*? From where does it receive its intake? To where does it subsequently discharge that intake?*
The episcleral venous plexus is the network of venous channels located in the episclera in the peri-limbal region. So-called aqueous veins carry aqueous to it that drained from Schlemm's canal via collector channels. The plexus eventually discharges into uveal vessels that subsequently empty into the vortex veins.

There are two main pathways for blood leaving the globe. What are they?
The central retinal vein (CRV), and the vortex veins

Q

Open-angle Glaucoma: *Secondary*

OAG 2ndry to ↑ EVP

What does EVP *stand for in this context?*
Episcleral venous pressure, ie, the BP in the episcleral venous plexus

What is the episcleral venous plexus*? From where does it receive its intake? To where does it subsequently discharge that intake?*
The episcleral venous plexus is the network of venous channels located in the episclera in the peri-limbal region. So-called aqueous veins carry aqueous to it that drained from Schlemm's canal via collector channels. The plexus eventually discharges into uveal vessels that subsequently empty into the **vortex veins**.

There are two main pathways for blood leaving the globe. What are they?
The central retinal vein (CRV), and the **vortex veins**

How many vortex veins are there?

A

Open-angle Glaucoma: *Secondary*

OAG 2ndry to ↑ EVP

What does EVP *stand for in this context?*
Episcleral venous pressure, ie, the BP in the episcleral venous plexus

What is the episcleral venous plexus*? From where does it receive its intake? To where does it subsequently discharge that intake?*
The episcleral venous plexus is the network of venous channels located in the episclera in the peri-limbal region. So-called aqueous veins carry aqueous to it that drained from Schlemm's canal via collector channels. The plexus eventually discharges into uveal vessels that subsequently empty into the **vortex veins**.

There are two main pathways for blood leaving the globe. What are they?
The central retinal vein (CRV), and the **vortex veins**

How many vortex veins are there?
4-7 (can be more)

Q

Open-angle Glaucoma: *Secondary*

OAG 2ndry to ↑ EVP

What does EVP *stand for in this context?*
Episcleral venous pressure, ie, the BP in the episcleral venous plexus

What is the episcleral venous plexus*? From where does it receive its intake? To where does it subsequently discharge that intake?*
The episcleral venous plexus is the network of venous channels located in the episclera in the peri-limbal region. So-called aqueous veins carry aqueous to it that drained from Schlemm's canal via collector channels. The plexus eventually discharges into uveal vessels that subsequently empty into the **vortex veins**.

There are two main pathways for blood leaving the globe. What are they?
The central retinal vein (CRV), and the **vortex veins**

How many vortex veins are there?
4-7 (can be more)

Where are they located?

A

Open-angle Glaucoma: *Secondary*

OAG 2ndry to ↑ EVP

What does EVP *stand for in this context?*
Episcleral venous pressure, ie, the BP in the episcleral venous plexus

What is the episcleral venous plexus*? From where does it receive its intake? To where does it subsequently discharge that intake?*
The episcleral venous plexus is the network of venous channels located in the episclera in the peri-limbal region. So-called aqueous veins carry aqueous to it that drained from Schlemm's canal via collector channels. The plexus eventually discharges into uveal vessels that subsequently empty into the **vortex veins**.

There are two main pathways for blood leaving the globe. What are they?
The central retinal vein (CRV), and the **vortex veins**

How many vortex veins are there?
4-7 (can be more)

Where are they located?
The pierce the sclera roughly at the equator of the globe. There is at least one (often more) in each quadrant of the eye.

Open-angle Glaucoma: *Secondary*

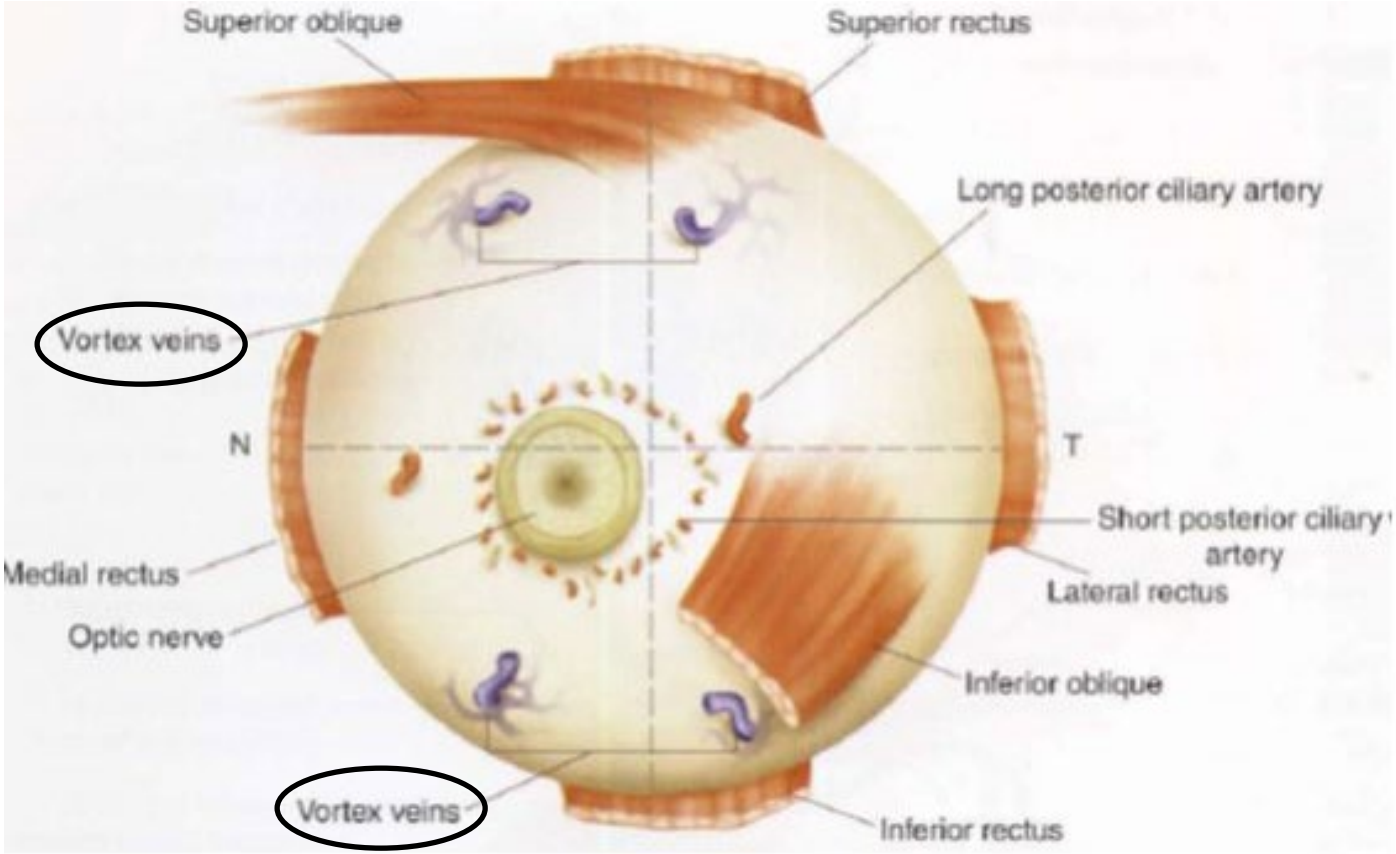

Vortex veins

Open-angle Glaucoma: *Secondary*

Vortex veins. Their ampullae are visible during DFE (the large circle is approximating the equator of the globe)

Q

Open-angle Glaucoma: *Secondary*

OAG 2ndry to ↑ EVP

What does EVP *stand for in this context?*
Episcleral venous pressure, ie, the BP in the episcleral venous plexus

What is the episcleral venous plexus*? From where does it receive its intake? To where does it subsequently discharge that intake?*
The episcleral venous plexus is the network of venous channels located in the episclera in the peri-limbal region. So-called aqueous veins carry aqueous to it that drained from Schlemm's canal via collector channels. The plexus eventually discharges into uveal vessels that subsequently empty into the **vortex veins**.

There are two main pathways for blood leaving the globe. What are they?
The central retinal vein (CRV), and the vortex veins

What ocular structures does each pathway drain?
--The CRV:
--The vortex veins:

A

Open-angle Glaucoma: *Secondary*

OAG 2ndry to ↑ EVP

What does EVP *stand for in this context?*
Episcleral venous pressure, ie, the BP in the episcleral venous plexus

What is the episcleral venous plexus*? From where does it receive its intake? To where does it subsequently discharge that intake?*
The episcleral venous plexus is the network of venous channels located in the episclera in the peri-limbal region. So-called aqueous veins carry aqueous to it that drained from Schlemm's canal via collector channels. The plexus eventually discharges into uveal vessels that subsequently empty into the **vortex veins**.

There are two main pathways for blood leaving the globe. What are they?
The central retinal vein (CRV), and the vortex veins

What ocular structures does each pathway drain?
--The CRV: The retina
--The vortex veins: Pretty much everything else

Q

Open-angle Glaucoma: *Secondary*

OAG 2ndry to ↑ EVP

What does EVP *stand for in this context?*
Episcleral venous pressure, ie, the BP in the episcleral venous plexus

What is the episcleral venous plexus*? From where does it receive its intake? To where does it subsequently discharge that intake?*
The episcleral venous plexus is the network of venous channels located in the episclera in the peri-limbal region. So-called aqueous veins carry aqueous to it that drained from Schlemm's canal via collector channels. The plexus eventually discharges into uveal vessels that subsequently empty into the **vortex veins**.

There are two main pathways for blood leaving the globe. What are they?
The central retinal vein (CRV), and the vortex veins

What ocular structures does each pathway drain?
--The CRV: The retina
--The vortex veins: **Pretty much everything else**

What ocular structure comprises the lion's share of 'everything else'?

Q/A

Open-angle Glaucoma: *Secondary*

OAG 2ndry to ↑ EVP

What does EVP *stand for in this context?*
Episcleral venous pressure, ie, the BP in the episcleral venous plexus

What is the episcleral venous plexus*? From where does it receive its intake? To where does it subsequently discharge that intake?*
The episcleral venous plexus is the network of venous channels located in the episclera in the peri-limbal region. So-called aqueous veins carry aqueous to it that drained from Schlemm's canal via collector channels. The plexus eventually discharges into uveal vessels that subsequently empty into the **vortex veins**.

There are two main pathways for blood leaving the globe. What are they?
The central retinal vein (CRV), and the vortex veins

What ocular structures does each pathway drain?
--The CRV: The retina
--The vortex veins: **Pretty much everything else**

What ocular structure comprises the lion's share of 'everything else'?
The uvea, ie, the three parts of the uvea

A

Open-angle Glaucoma: *Secondary*

OAG 2ndry to ↑ EVP

What does EVP *stand for in this context?*
Episcleral venous pressure, ie, the BP in the episcleral venous plexus

What is the episcleral venous plexus*? From where does it receive its intake? To where does it subsequently discharge that intake?*
The episcleral venous plexus is the network of venous channels located in the episclera in the peri-limbal region. So-called aqueous veins carry aqueous to it that drained from Schlemm's canal via collector channels. The plexus eventually discharges into uveal vessels that subsequently empty into the **vortex veins**.

There are two main pathways for blood leaving the globe. What are they?
The central retinal vein (CRV), and the vortex veins

What ocular structures does each pathway drain?
--The CRV: The retina
--The vortex veins: **Pretty much everything else**

What ocular structure comprises the lion's share of 'everything else'?
The uvea, ie, the choroid, ciliary body and iris

Q

Open-angle Glaucoma: *Secondary*

OAG 2ndry to ↑ EVP

What does EVP *stand for in this context?*
Episcleral venous pressure, ie, the BP in the episcleral venous plexus

What is the episcleral venous plexus*? From where does it receive its intake? To where does it subsequently discharge that intake?*
The episcleral venous plexus is the network of venous channels located in the episclera in the peri-limbal region. So-called aqueous veins carry aqueous to it that drained from Schlemm's canal via collector channels. The plexus eventually discharges into uveal vessels that subsequently empty into the **vortex veins**.

There are two main pathways for blood leaving the globe. What are they?
The central retinal vein (CRV), and the vortex veins

What ocular structures does each pathway drain?
--The CRV: The retina
--The vortex veins: Pretty much everything else

What venous structure receives the majority of CRV and vortex veins outflow?

A

Open-angle Glaucoma: *Secondary*

OAG 2ndry to ↑ EVP

What does EVP *stand for in this context?*
Episcleral venous pressure, ie, the BP in the episcleral venous plexus

What is the episcleral venous plexus*? From where does it receive its intake? To where does it subsequently discharge that intake?*
The episcleral venous plexus is the network of venous channels located in the episclera in the peri-limbal region. So-called aqueous veins carry aqueous to it that drained from Schlemm's canal via collector channels. The plexus eventually discharges into uveal vessels that subsequently empty into the **vortex veins**.

There are two main pathways for blood leaving the globe. What are they?
The central retinal vein (CRV), and the vortex veins

What ocular structures does each pathway drain?
--The CRV: The retina
--The vortex veins: Pretty much everything else

What venous structure receives the majority of CRV and vortex veins outflow?
The superior ophthalmic vein (SOV)

Open-angle Glaucoma: *Secondary*

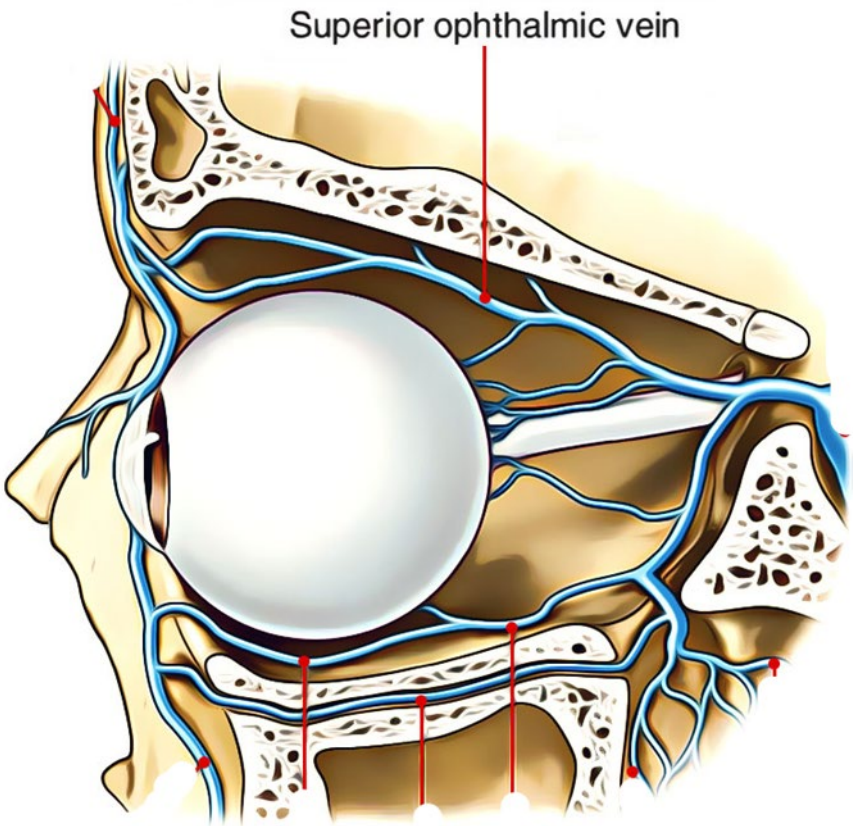

Superior ophthalmic vein

Q

Open-angle Glaucoma: *Secondary*

OAG 2ndry to ↑ EVP

What does EVP *stand for in this context?*
Episcleral venous pressure, ie, the BP in the episcleral venous plexus

What is the episcleral venous plexus*? From where does it receive its intake? To where does it subsequently discharge that intake?*
The episcleral venous plexus is the network of venous channels located in the episclera in the peri-limbal region. So-called aqueous veins carry aqueous to it that drained from Schlemm's canal via collector channels. The plexus eventually discharges into uveal vessels that subsequently empty into the **vortex veins**.

There are two main pathways for blood leaving the globe. What are they?
The central retinal vein (CRV), and the vortex veins

What ocular structures does each pathway drain?
--The CRV: The retina
--The vortex veins: Pretty much everything else

What venous structure receives the majority of CRV and vortex veins outflow?
The superior ophthalmic vein (SOV)

Into what structure does the SOV empty?

A

Open-angle Glaucoma: *Secondary*

OAG 2ndry to ↑ EVP

What does EVP *stand for in this context?*
Episcleral venous pressure, ie, the BP in the episcleral venous plexus

What is the episcleral venous plexus*? From where does it receive its intake? To where does it subsequently discharge that intake?*
The episcleral venous plexus is the network of venous channels located in the episclera in the peri-limbal region. So-called aqueous veins carry aqueous to it that drained from Schlemm's canal via collector channels. The plexus eventually discharges into uveal vessels that subsequently empty into the **vortex veins**.

There are two main pathways for blood leaving the globe. What are they?
The central retinal vein (CRV), and the vortex veins

What ocular structures does each pathway drain?
--The CRV: The retina
--The vortex veins: Pretty much everything else

What venous structure receives the majority of CRV and vortex veins outflow?
The superior ophthalmic vein (SOV)

Into what structure does the SOV empty?
The cavernous sinus

Open-angle Glaucoma: *Secondary*

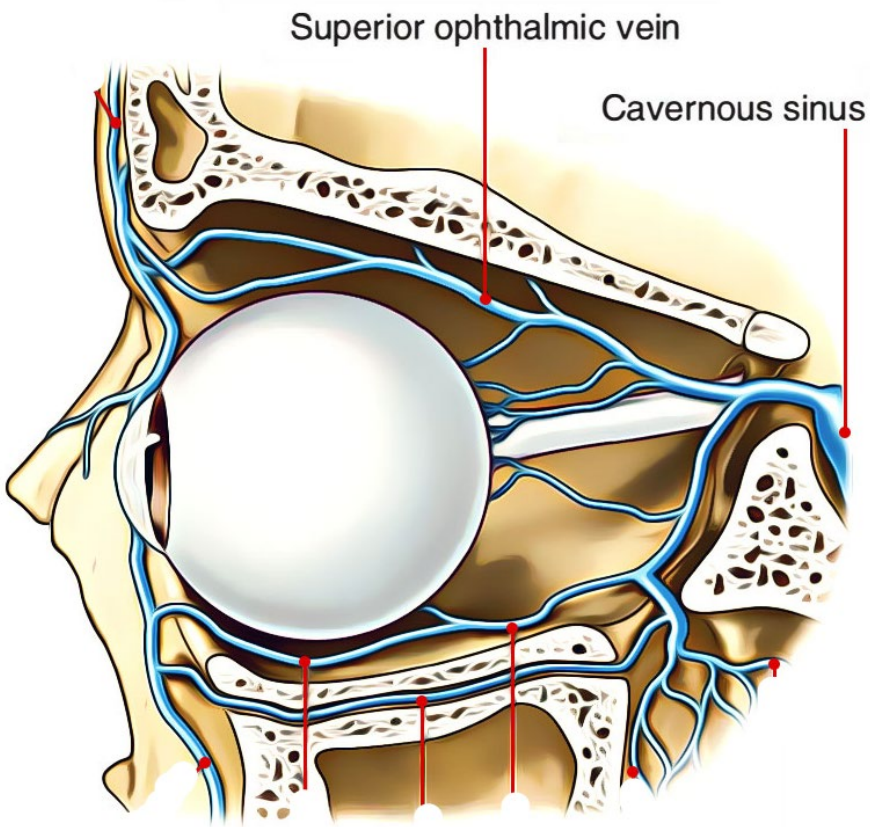

Cavernous sinus

Q

Open-angle Glaucoma: *Secondary*

OAG 2ndry to ↑ EVP

What does EVP *stand for in this context?*
Episcleral venous pressure, ie, the BP in the episcleral venous plexus

What is the episcleral venous plexus*? From where does it receive its intake? To where does it subsequently discharge that intake?*
The episcleral venous plexus is the network of venous channels located in the episclera in the peri-limbal region. So-called aqueous veins carry aqueous to it that drained from Schlemm's canal via collector channels. The plexus eventually discharges into uveal vessels that subsequently empty into the vortex veins.

What is the normal range for EVP?

Q/A

Open-angle Glaucoma: *Secondary*

OAG 2ndry to ↑ EVP

What does EVP *stand for in this context?*
Episcleral venous pressure, ie, the BP in the episcleral venous plexus

What is the episcleral venous plexus*? From where does it receive its intake? To where does it subsequently discharge that intake?*
The episcleral venous plexus is the network of venous channels located in the episclera in the peri-limbal region. So-called aqueous veins carry aqueous to it that drained from Schlemm's canal via collector channels. The plexus eventually discharges into uveal vessels that subsequently empty into the vortex veins.

What is the normal range for EVP?
5-9 mmHg—same as abb.

A

Open-angle Glaucoma: *Secondary*

OAG 2ndry to ↑ EVP

What does EVP *stand for in this context?*
Episcleral venous pressure, ie, the BP in the episcleral venous plexus

What is the episcleral venous plexus*? From where does it receive its intake? To where does it subsequently discharge that intake?*
The episcleral venous plexus is the network of venous channels located in the episclera in the peri-limbal region. So-called aqueous veins carry aqueous to it that drained from Schlemm's canal via collector channels. The plexus eventually discharges into uveal vessels that subsequently empty into the vortex veins.

What is the normal range for EVP?
5-9 mmHg—same as CVP

Q

Open-angle Glaucoma: *Secondary*

OAG 2ndry to ↑ EVP

What does EVP *stand for in this context?*
Episcleral venous pressure, ie, the BP in the episcleral venous plexus

What is the episcleral venous plexus*? From where does it receive its intake? To where does it subsequently discharge that intake?*
The episcleral venous plexus is the network of venous channels located in the episclera in the peri-limbal region. So-called aqueous veins carry aqueous to it that drained from Schlemm's canal via collector channels. The plexus eventually discharges into uveal vessels that subsequently empty into the vortex veins.

What is the normal range for EVP?
5-9 mmHg—same as **CVP**

What does CVP *stand for in this context?*

Q/A

Open-angle Glaucoma: *Secondary*

OAG 2ndry to ↑ EVP

What does EVP *stand for in this context?*
Episcleral venous pressure, ie, the BP in the episcleral venous plexus

What is the episcleral venous plexus*? From where does it receive its intake? To where does it subsequently discharge that intake?*
The episcleral venous plexus is the network of venous channels located in the episclera in the peri-limbal region. So-called aqueous veins carry aqueous to it that drained from Schlemm's canal via collector channels. The plexus eventually discharges into uveal vessels that subsequently empty into the vortex veins.

What is the normal range for EVP?
5-9 mmHg—same as **CVP**

What does CVP *stand for in this context?*
Central venous pressure, ie, the blood pressure in the two words

A

Open-angle Glaucoma: *Secondary*

OAG 2ndry to ↑ EVP

What does EVP *stand for in this context?*
Episcleral venous pressure, ie, the BP in the episcleral venous plexus

What is the episcleral venous plexus*? From where does it receive its intake? To where does it subsequently discharge that intake?*
The episcleral venous plexus is the network of venous channels located in the episclera in the peri-limbal region. So-called aqueous veins carry aqueous to it that drained from Schlemm's canal via collector channels. The plexus eventually discharges into uveal vessels that subsequently empty into the vortex veins.

What is the normal range for EVP?
5-9 mmHg—same as **CVP**

What does CVP *stand for in this context?*
Central venous pressure, ie, the blood pressure in the right atrium

Q

Open-angle Glaucoma: *Secondary*

OAG 2ndry to ↑ EVP

What does EVP *stand for in this context?*
Episcleral venous pressure, ie, the BP in the episcleral venous plexus

What is the episcleral venous plexus*? From where does it receive its intake? To where does it subsequently discharge that intake?*
The episcleral venous plexus is the network of venous channels located in the episclera in the peri-limbal region. So-called aqueous veins carry aqueous to it that drained from Schlemm's canal via collector channels. The plexus eventually discharges into uveal vessels that subsequently empty into the vortex veins.

What is the normal range for EVP?
5-9 mmHg—same as CVP

What happens if EVP increases significantly?

A

Open-angle Glaucoma: *Secondary*

OAG 2ndry to ↑ EVP

What does EVP *stand for in this context?*
Episcleral venous pressure, ie, the BP in the episcleral venous plexus

What is the episcleral venous plexus*? From where does it receive its intake? To where does it subsequently discharge that intake?*
The episcleral venous plexus is the network of venous channels located in the episclera in the peri-limbal region. So-called aqueous veins carry aqueous to it that drained from Schlemm's canal via collector channels. The plexus eventually discharges into uveal vessels that subsequently empty into the vortex veins.

What is the normal range for EVP?
5-9 mmHg—same as CVP

What happens if EVP increases significantly?
If EVP is high, back-pressure will be transmitted to the AC via the aqueous veins, collector channels, Schlemm's canal and TM, causing a proportional increase in IOP.

A

Open-angle Glaucoma: *Secondary*

OAG 2ndry to ↑ EVP

What does EVP *stand for in this context?*
Episcleral venous pressure, ie, the BP in the episcleral venous plexus

What is the episcleral venous plexus*? From where does it receive its intake? To where does it subsequently discharge that intake?*
The episcleral venous plexus is the network of venous channels located in the episclera in the peri-limbal region. So-called aqueous veins carry aqueous to it that drained from Schlemm's canal via collector channels. The plexus eventually discharges into uveal vessels that subsequently empty into the vortex veins.

What is the normal range for EVP?
5-9 mmHg—same as CVP

What happens if EVP increases significantly?
If EVP is high, back-pressure will be transmitted to the AC via the aqueous veins, collector channels, Schlemm's canal and TM, causing a proportional increase in IOP. *And if IOP is elevated high enough for long enough, the pt will develop OAG 2ndry to the increased EVP.*

Q

Open-angle Glaucoma: *Secondary*

OAG 2ndry to ↑ EVP

What does EVP *stand for in this context?*
Episcleral venous pressure, ie, the BP in the episcleral venous plexus

What is the episcleral venous plexus*? From where does it receive its intake? To where does it subsequently discharge that intake?*
The episcleral venous plexus is the network of venous channels located in the episclera in the peri-limbal region. So-called aqueous veins carry aqueous to it that drained from Schlemm's canal via collector channels. The plexus eventually discharges into uveal vessels that subsequently empty into the vortex veins.

What is the normal range for EVP?
5-9 mmHg—sam

What happens if
If EVP is high, b
collector channel
And if IOP is elev
the increased EV

In addition to elevated IOP, what other sign/symptoms might result from elevated EVP?

A

Open-angle Glaucoma: *Secondary*

OAG 2ndry to ↑ EVP

What does EVP *stand for in this context?*
Episcleral venous pressure, ie, the BP in the episcleral venous plexus

What is the episcleral venous plexus*? From where does it receive its intake? To where does it subsequently discharge that intake?*
The episcleral venous plexus is the network of venous channels located in the episclera in the peri-limbal region. So-called aqueous veins carry aqueous to it that drained from Schlemm's canal via collector channels. The plexus eventually discharges into uveal vessels that subsequently empty into the vortex veins.

What is the normal range for EVP?
5-9 mmHg—sam

What happens if
If EVP is high, b
collector channel
And if IOP is elev
the increased EV

In addition to elevated IOP, what other sign/symptoms might result from elevated EVP?
The pt may c/o and present with a chronic 'red eye'

Q

Open-angle Glaucoma: *Secondary*

OAG 2ndry to ↑ EVP

What does EVP *stand for in this context?*
Episcleral venous pressure, ie, the BP in the episcleral venous plexus

What is the episcleral venous plexus*? From where does it receive its intake? To where does it subsequently discharge that intake?*
The episcleral venous plexus is the network of venous channels located in the episclera in the peri-limbal region. So-called aqueous veins carry aqueous to it that drained from Schlemm's canal via collector channels. The plexus eventually discharges into uveal vessels that subsequently empty into the vortex veins.

What is the normal range for EVP?
5-9 mmHg—sam

What happens if
If EVP is high, b
collector channel
And if IOP is elev
the increased EV

In addition to elevated IOP, what other sign/symptoms might result from elevated EVP?
The pt may c/o and present with a chronic 'red eye'

Two aspects of such a red-eye presentation—one symptom-related, one sign-related—will suggest it's not a run-of-the-mill red eye. What are they?
--Symptom-wise…

--Sign-wise…

A

Open-angle Glaucoma: *Secondary*

OAG 2ndry to ↑ EVP

What does EVP *stand for in this context?*
Episcleral venous pressure, ie, the BP in the episcleral venous plexus

What is the episcleral venous plexus*? From where does it receive its intake? To where does it subsequently discharge that intake?*
The episcleral venous plexus is the network of venous channels located in the episclera in the peri-limbal region. So-called aqueous veins carry aqueous to it that drained from Schlemm's canal via collector channels. The plexus eventually discharges into uveal vessels that subsequently empty into the vortex veins.

What is the normal range for EVP?
5-9 mmHg—sam

What happens if
If EVP is high, b
collector channel
And if IOP is elev
the increased EV

In addition to elevated IOP, what other sign/symptoms might result from elevated EVP?
The pt may c/o and present with a chronic 'red eye'

Two aspects of such a red-eye presentation—one symptom-related, one sign-related—will suggest it's not a run-of-the-mill red eye. What are they?
*--Symptom-wise…*The presentation will lack c/o related to ocular surface dz—no FBS, itching, tearing, etc
--Sign-wise…

Q

Open-angle Glaucoma: *Secondary*

OAG 2ndry to ↑ EVP

What does EVP *stand for in this context?*
Episcleral venous pressure, ie, the BP in the episcleral venous plexus

What is the episcleral venous plexus*? From where does it receive its intake? To where does it subsequently discharge that intake?*
The episcleral venous plexus is the network of venous channels located in the episclera in the peri-limbal region. So-called aqueous veins carry aqueous to it that drained from Schlemm's canal via collector channels. The plexus eventually discharges into uveal vessels that subsequently empty into the vortex veins.

What is the normal range for EVP?
5-9 mmHg—sam

What happens if
If EVP is high, b
collector channel
And if IOP is elev
the increased EV

In addition to elevated IOP, what other sign/symptoms might result from elevated EVP?
The pt may c/o and present with a chronic 'red eye'

Two aspects of such a red-eye presentation—one symptom-related, one sign-related—will suggest it's not a run-of-the-mill red eye. What are they?
*--Symptom-wise…*The presentation will lack c/o related to ocular surface dz—no FBS, itching, tearing, etc
--Sign-wise…

A

Open-angle Glaucoma: *Secondary*

OAG 2ndry to ↑ EVP

What does EVP *stand for in this context?*
Episcleral venous pressure, ie, the BP in the episcleral venous plexus

What is the episcleral venous plexus*? From where does it receive its intake? To where does it subsequently discharge that intake?*
The episcleral venous plexus is the network of venous channels located in the episclera in the peri-limbal region. So-called aqueous veins carry aqueous to it that drained from Schlemm's canal via collector channels. The plexus eventually discharges into uveal vessels that subsequently empty into the vortex veins.

What is the normal range for EVP?
5-9 mmHg—sam

What happens if
If EVP is high, b
collector channel
And if IOP is elev
the increased EV

In addition to elevated IOP, what other sign/symptoms might result from elevated EVP?
The pt may c/o and present with a chronic 'red eye'

Two aspects of such a red-eye presentation—one symptom-related, one sign-related—will suggest it's not a run-of-the-mill red eye. What are they?
--*Symptom-wise…*The presentation will lack c/o related to ocular surface dz—no FBS, itching, tearing, etc
--*Sign-wise…*The episcleral veins will be 'prominent'—dilated and/or tortuous

Open-angle Glaucoma: *Secondary*

Prominent episcleral veins 2ndry to increased EVP

Q

Open-angle Glaucoma: *Secondary*

OAG 2ndry to ↑ EVP

Idiopathic

?

?

In cases for which a cause can be identified, what are the two basic mechanisms of increased EVP?

A

Open-angle Glaucoma: *Secondary*

OAG 2ndry to ↑ EVP

Idiopathic

Arterial and/or venous abnormalities

Venous obstruction

In cases for which a cause can be identified, what are the two basic mechanisms of increased EVP?

Open-angle Glaucoma: *Secondary*

OAG 2ndry to ↑ EVP

Idiopathic

Arterial and/or venous abnormalities

Venous obstruction

Note for those of you thought 'AV malformation' was the correct answer here…

Open-angle Glaucoma: *Secondary*

OAG 2ndry to ↑ EVP

Idiopathic

Arterial and/or venous abnormalities

Venous obstruction

Note for those of you thought 'AV malformation' was the correct answer here…
This is one of very few times where I'm substituting my judgment for that of a *BCSC* book. The *Glaucoma* book does indeed label this category "AV malformations," but that term clearly does **not** apply to all of the conditions the *Glaucoma* book hangs under it (TBH, I don't think it applies to *any* of them). This I why I decided to go with my own term—the anodyne-but-accurate *Arterial and/or venous abnormalities*.

Q

Open-angle Glaucoma: *Secondary*

OAG 2ndry to ↑ EVP

- Idiopathic
- Arterial and/or venous abnormalities
  - ? ← *Umbrella term for several conditions*
  - ? ← *Fairly specific condition, but can present several ways*
  - ? ← *Very specific condition*
- Venous obstruction

The Glaucoma *book mentions three arterial/venous abnormalities as causes—what are they?*

A

Open-angle Glaucoma: *Secondary*

OAG 2ndry to ↑ EVP

- Idiopathic
- Arterial and/or venous abnormalities
  - A-V fistula *Umbrella term for several conditions*
  - Orbital varix *Fairly specific condition, but can present several ways*
  - Sturge-Weber syndrome *Very specific condition*
- Venous obstruction

The Glaucoma *book mentions three arterial/venous abnormalities as causes—what are they?*

Q

Open-angle Glaucoma: *Secondary*

OAG 2ndry to ↑ EVP

- Idiopathic
- Arterial and/or venous abnormalities
  - A-V fistula
  - Orbital varix
  - Sturge-Weber syndrome
- Venous obstruction
  - ? *Category of condition*
  - ? *Very specific condition*

It mentions two causes of venous obstruction—what are they?

A

Open-angle Glaucoma: *Secondary*

OAG 2ndry to ↑ EVP

- Idiopathic
- Arterial and/or venous abnormalities
  - A-V fistula
  - Orbital varix
  - Sturge-Weber syndrome
- Venous obstruction
  - Retrobulbar tumor
  - Thyroid eye dz

It mentions two causes of venous obstruction—what are they?

Q

Open-angle Glaucoma: *Secondary*

OAG 2ndry to ↑ EVP

Idiopathic?

Arterial and/or venous abnormalities

- *A-V fistula?*
- *Orbital varix?*
- *Sturge-Weber syndrome?*

Venous obstruction

- *Retrobulbar tumor?*
- *Thyroid eye dz?*

Finally: Of the conditions known to cause 2ndry OAG owing to increased EVP, which is most common?

A

Open-angle Glaucoma: *Secondary*

OAG 2ndry to ↑ EVP

Idiopathic

Arterial and/or venous abnormalities
- A-V fistula
- Orbital varix
- Sturge-Weber syndrome

Venous obstruction
- Retrobulbar tumor
- Thyroid eye dz

Finally: Of the conditions known to cause 2ndry OAG owing to increased EVP, which is most common?
Idiopathic

Q

Open-angle Glaucoma: *Secondary*

OAG 2ndry to ↑ EVP

- *Idiopathic*
- *Arterial and/or venous abnormalities*
  - **A-V fistula**
  - Orbital varix
- *Venous obstruction*
  - Retrobulbar tumor
  - Thyroid eye dz

The A-V fistulas implicated in OAG 2ndry to increased EVP: Where are they located?

A

Open-angle Glaucoma: *Secondary*

OAG 2ndry to ↑ EVP

- *Idiopathic*
- *Arterial and/or venous abnormalities*
  - **A-V fistula**
  - Orbital varix
- *Venous obstruction*
  - Retrobulbar tumor
  - Thyroid eye dz

The A-V fistulas implicated in OAG 2ndry to increased EVP: Where are they located?

The cavernous sinus (CS)

Q

Open-angle Glaucoma: *Secondary*

OAG 2ndry to ↑ EVP

- *Idiopathic*
- *Arterial and/or venous abnormalities*
  - **A-V fistula**
  - Orbital varix
- *Venous obstruction*
  - Retrobulbar tumor
  - Thyroid eye dz

The A-V fistulas implicated in OAG 2ndry to increased EVP: Where are they located?
The cavernous sinus (CS)

An aspect of CS anatomy makes it uniquely vulnerable to the development of A-V fistulas. What is it?

Q/A

Open-angle Glaucoma: *Secondary*

OAG 2ndry to ↑ EVP

Idiopathic

Arterial and/or venous abnormalities
- **A-V fistula**
- Orbital varix

Venous obstruction
- Retrobulbar tumor
- Thyroid eye dz

The A-V fistulas implicated in OAG 2ndry to increased EVP: Where are they located?
The cavernous sinus (CS)

An aspect of CS anatomy makes it uniquely vulnerable to the development of A-V fistulas. What is it?
It is the configuration--unique in the human body--of having an *arterial* structure (the [redacted] artery and its [redacted] branches) wholly within the confines of a *venous* structure (ie, the CS itself)

A

Open-angle Glaucoma: *Secondary*

OAG 2ndry to ↑ EVP

- *Idiopathic*
- *Arterial and/or venous abnormalities*
  - **A-V fistula**
  - Orbital varix
- *Venous obstruction*
  - Retrobulbar tumor
  - Thyroid eye dz

The A-V fistulas implicated in OAG 2ndry to increased EVP: Where are they located?
The cavernous sinus (CS)

An aspect of CS anatomy makes it uniquely vulnerable to the development of A-V fistulas. What is it?
It is the configuration--unique in the human body--of having an *arterial* structure (the internal carotid artery and its dural branches) wholly within the confines of a *venous* structure (ie, the CS itself)

Open-angle Glaucoma: *Secondary*

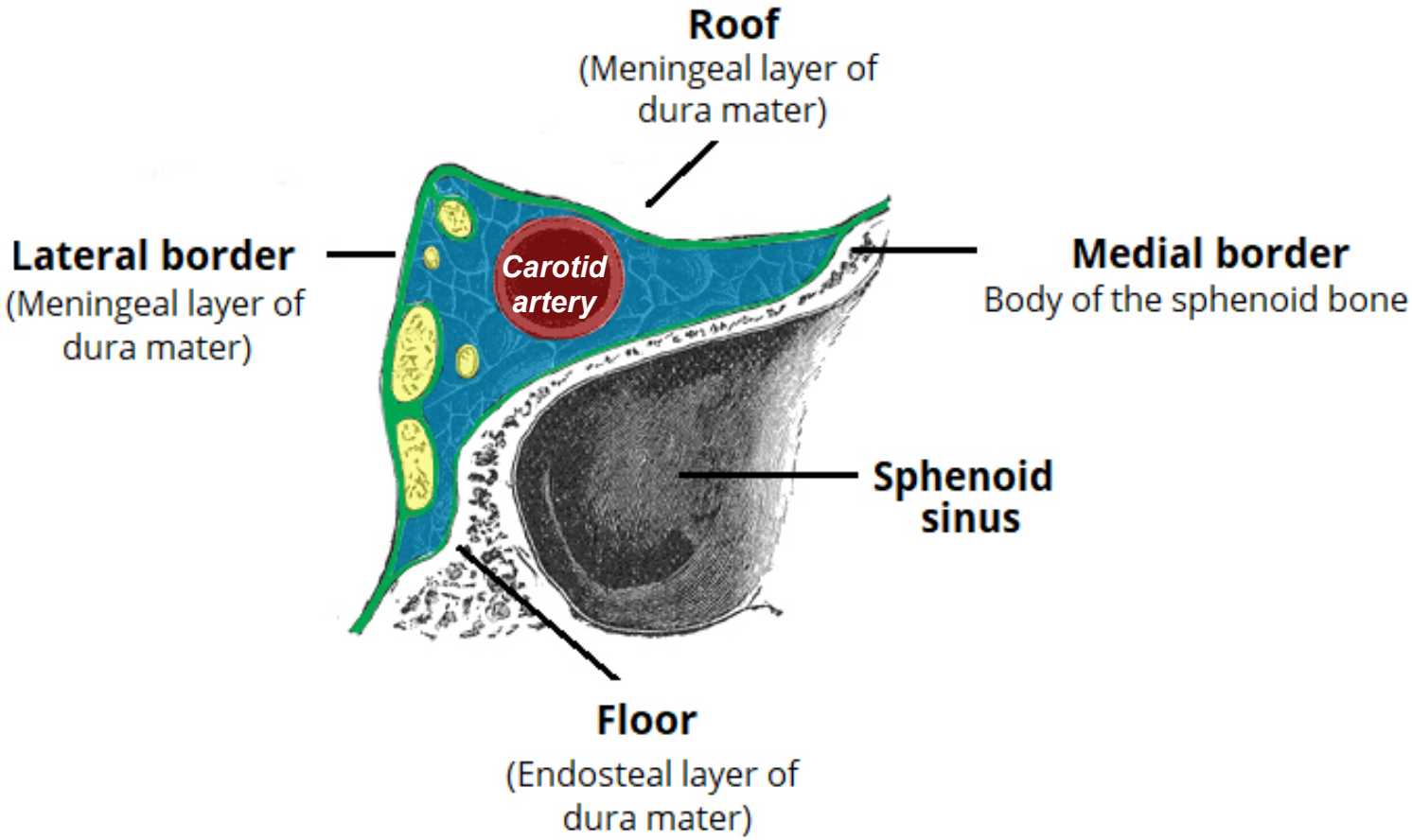

Relationship between the internal carotid artery and the CS

Q

Open-angle Glaucoma: *Secondary*

OAG 2ndry to ↑ EVP

Idiopathic

Arterial and/or venous abnormalities
- **A-V fistula**
- Orbital varix

Venous obstruction
- Retrobulbar tumor
- Thyroid eye dz

The A-V fistulas implicated in OAG 2ndry to increased EVP: Where are they located?
The cavernous sinus (CS)

An aspect of CS anatomy makes it uniquely vulnerable to the development of A-V fistulas. What is it?
It is the configuration--unique in the human body--of having an *arterial* structure (the internal carotid artery and its dural branches) wholly within the confines of a *venous* structure (ie, the CS itself)

What is the fundamental problem that results from a fistula within the CS?

A

Open-angle Glaucoma: *Secondary*

OAG 2ndry to ↑ EVP

Idiopathic

Arterial and/or venous abnormalities
- **A-V fistula**
- Orbital varix

Venous obstruction
- Retrobulbar tumor
- Thyroid eye dz

The A-V fistulas implicated in OAG 2ndry to increased EVP: Where are they located?
The cavernous sinus (CS)

An aspect of CS anatomy makes it uniquely vulnerable to the development of A-V fistulas. What is it?
It is the configuration--unique in the human body--of having an *arterial* structure (the internal carotid artery and its dural branches) wholly within the confines of a *venous* structure (ie, the CS itself)

What is the fundamental problem that results from a fistula within the CS?
It's a pressure thing. A fistula allows high-pressure blood from the arterial tree to flow into the low-pressure, venous-sided CS. The subsequent increase in blood pressure within the CS impedes venous flow into the CS, leading to congestion of the eye and orbit.

A

Open-angle Glaucoma: *Secondary*

OAG 2ndry to ↑ EVP

Idiopathic

Arterial and/or venous abnormalities
- **A-V fistula**
- Orbital varix

Venous obstruction
- Retrobulbar tumor
- Thyroid eye dz

The A-V fistulas implicated in OAG 2ndry to increased EVP: Where are they located?
The cavernous sinus (CS)

An aspect of CS anatomy makes it uniquely vulnerable to the development of A-V fistulas. What is it?
It is the configuration--unique in the human body--of having an *arterial* structure (the internal carotid artery and its dural branches) wholly within the confines of a *venous* structure (ie, the CS itself)

What is the fundamental problem that results from a fistula within the CS?
It's a pressure thing. A fistula allows high-pressure blood from the arterial tree to flow into the low-pressure, venous-sided CS. The subsequent increase in blood pressure within the CS impedes venous flow into the CS, leading to congestion of the eye and orbit. Further, if the pressure increase within the CS is significant enough, reversal of blood flow through the venous structures that drain into the CS will occur--that is, blood will circulate **from** the CS **to** the eye and orbit.

Open-angle Glaucoma: *Secondary*

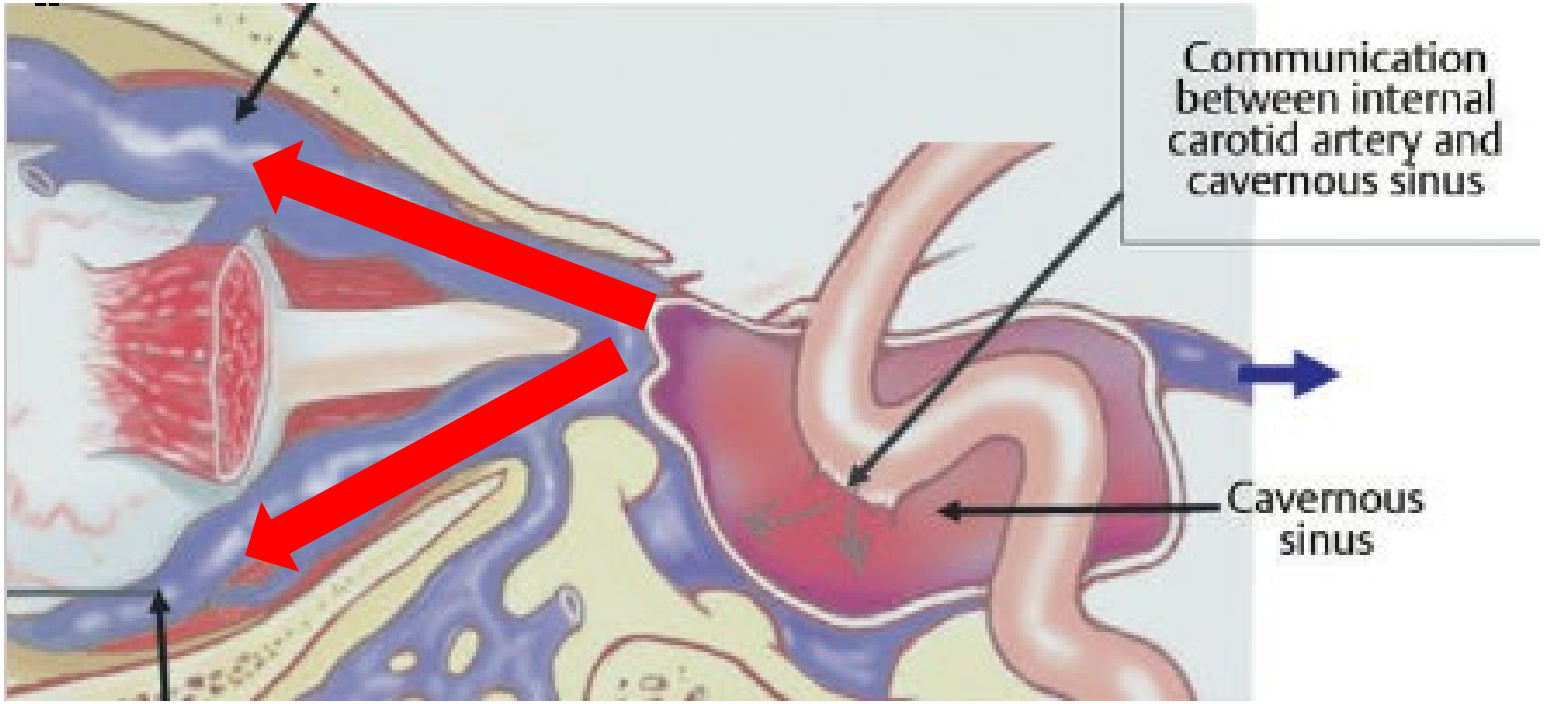

Carotid-CS fistula

Q

Open-angle Glaucoma: *Secondary*

OAG 2ndry to ↑ EVP

Idiopathic

Arterial and/or venous abnormalities

- **A-V fistula**

Venous obstruction

- Retrobulbar tumor
- Thyroid eye dz

Earlier in the slide-set, the main venous conduit from the eye and orbit to the CS was identified. What was it again?

pressure, venous-sided CS. The subsequent increase in blood pressure within the CS **impedes venous flow into the CS, leading to congestion of the eye and orbit**. Further, if the pressure increase within the CS is significant enough, reversal of blood flow through the venous structures that drain into the CS will occur--that is, blood will circulate **from** the CS **to** the eye and orbit.

A

Open-angle Glaucoma: *Secondary*

OAG 2ndry to ↑ EVP

Idiopathic

Arterial and/or venous abnormalities

- **A-V fistula**

Venous obstruction

- Retrobulbar tumor
- Thyroid eye dz

Earlier in the slide-set, the main venous conduit from the eye and orbit to the CS was identified. What was it again?

The superior ophthalmic vein (SOV)

pressure, venous-sided CS. The subsequent increase in blood pressure within the CS **impedes venous flow into the CS, leading to congestion of the eye and orbit**. Further, if the pressure increase within the CS is significant enough, reversal of blood flow through the venous structures that drain into the CS will occur--that is, blood will circulate **from** the CS **to** the eye and orbit.

Q

Open-angle Glaucoma: *Secondary*

OAG 2ndry to ↑ EVP

Idiopathic

Arterial and/or venous abnormalities
- **A-V fistula**

Venous obstruction
- Retrobulbar tumor
- Thyroid eye dz

Earlier in the slide-set, the main venous conduit from the eye and orbit to the CS was identified. What was it again?
The superior ophthalmic vein (SOV)

In a pt with a CS fistula, what is the appearance of the superior ophthalmic vein on orbital imaging studies?

pressure, venous-sided CS. The subsequent increase in blood pressure within the CS **impedes venous flow into the CS, leading to congestion of the eye and orbit**. Further, if the pressure increase within the CS is significant enough, reversal of blood flow through the venous structures that drain into the CS will occur--that is, blood will circulate **from** the CS **to** the eye and orbit.

A

Open-angle Glaucoma: *Secondary*

OAG 2ndry to ↑ EVP

Idiopathic

Arterial and/or venous abnormalities
- **A-V fistula**

Venous obstruction
- Retrobulbar tumor
- Thyroid eye dz

Earlier in the slide-set, the main venous conduit from the eye and orbit to the CS was identified. What was it again?
The superior ophthalmic vein (SOV)

In a pt with a CS fistula, what is the appearance of the superior ophthalmic vein on orbital imaging studies?
It is enlarged. This is an important sign to search for when reviewing imaging studies in cases of suspected CS fistulas!

pressure, venous-sided CS. The subsequent increase in blood pressure within the CS **impedes venous flow into the CS, leading to congestion of the eye and orbit**. Further, if the pressure increase within the CS is significant enough, reversal of blood flow through the venous structures that drain into the CS will occur--that is, blood will circulate **from** the CS **to** the eye and orbit.

Open-angle Glaucoma: *Secondary*

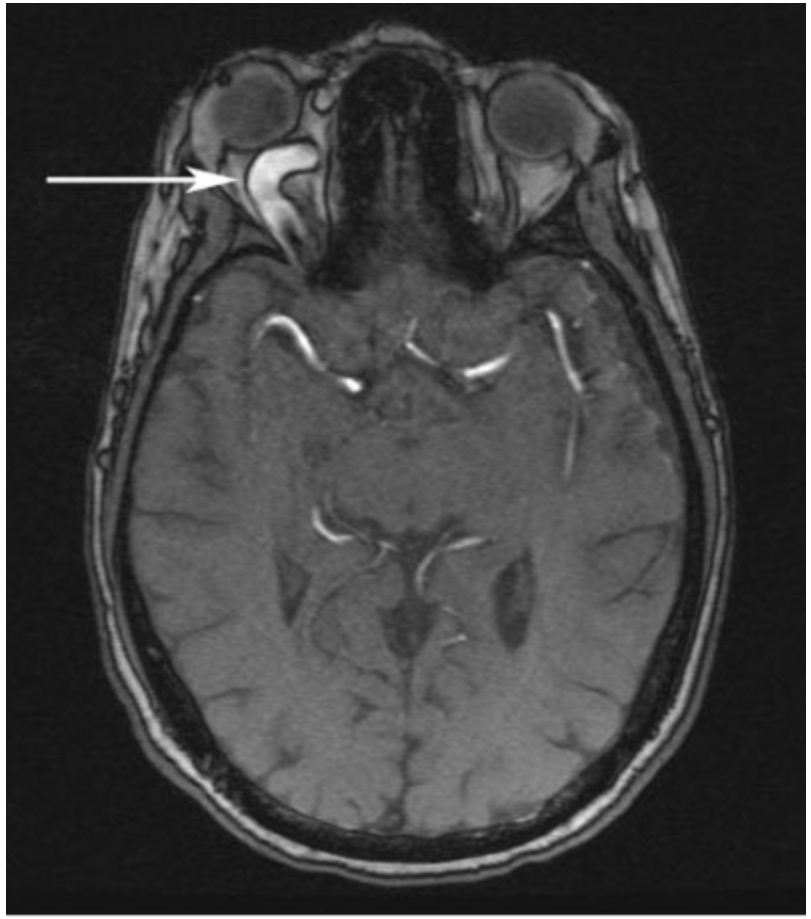

Carotid-CS fistula: Enlarged SOV on MRA

Open-angle Glaucoma: *Secondary*

OAG 2ndry to ↑ EVP

Idiopathic

Arterial and/or venous abnormalities
- **A-V fistula**

Venous obstruction
- Retrobulbar tumor
- Thyroid eye dz

Earlier in the slide-set, the main venous conduit from the eye and orbit to the CS was identified. What was it again?
The superior ophthalmic vein (SOV)

In a pt with … *imaging stu*

It is enlarged. This is an important sign to search for when reviewing imaging studies in cases of suspected CS fistulas!

For more on A-V fistulas, see slide-set N19

pressure, venous-sided CS. The subsequent increase in blood pressure within the CS **impedes venous flow into the CS, leading to congestion of the eye and orbit**. Further, if the pressure increase within the CS is significant enough, reversal of blood flow through the venous structures that drain into the CS will occur--that is, blood will circulate **from** the CS **to** the eye and orbit.

Q

Open-angle Glaucoma: *Secondary*

OAG 2ndry to ↑ EVP

- *Idiopathic*
- *Arterial and/or venous abnormalities*
  - A-V fistula
  - **Orbital varix**
  - Sturge-Weber syndrome
- *Venous obstruction*
  - Retrobulbar tumor
  - Thyroid eye dz

Orbital varices are known also by what other name?

A

Open-angle Glaucoma: *Secondary*

OAG 2ndry to ↑ EVP

- *Idiopathic*
- *Arterial and/or venous abnormalities*
  - A-V fistula
  - **Orbital varix**
  - Sturge-Weber syndrome
- *Venous obstruction*
  - Retrobulbar tumor
  - Thyroid eye dz

Orbital varices are known also by what other name?
Orbital venous malformations

Q

Open-angle Glaucoma: *Secondary*

OAG 2ndry to ↑ EVP

Idiopathic

Arterial and/or venous abnormalities
- A-V fistula
- **Orbital varix**
- Sturge-Weber syndrome

Venous obstruction
- Retrobulbar tumor
- Thyroid eye dz

Orbital varices are known also by what other name?
Orbital venous malformations

What is the classic presenting sign?

Q/A

Open-angle Glaucoma: *Secondary*

OAG 2ndry to ↑ EVP

Idiopathic

Arterial and/or venous abnormalities
- A-V fistula
- **Orbital varix**
- Sturge-Weber syndrome

Venous obstruction
- Retrobulbar tumor
- Thyroid eye dz

Orbital varices are known also by what other name?
Orbital venous malformations

What is the classic presenting sign?
Proptosis that occurs or worsens when the pt's head is [ ], or when the pt [action]

A

Open-angle Glaucoma: *Secondary*

OAG 2ndry to ↑ EVP

- *Idiopathic*
- *Arterial and/or venous abnormalities*
  - A-V fistula
  - **Orbital varix**
  - Sturge-Weber syndrome
- *Venous obstruction*
  - Retrobulbar tumor
  - Thyroid eye dz

Orbital varices are known also by what other name?
Orbital venous malformations

What is the classic presenting sign?
Proptosis that occurs or worsens when the pt's head is dependent , or when the pt Valsalvas

Q

Open-angle Glaucoma: *Secondary*

OAG 2ndry to ↑ EVP

Idiopathic

Arterial and/or venous abnormalities

- A-V fistula
- **Orbital varix**
- Sturge-Weber syndrome

Venous obstruction

- Retrobulbar tumor
- Thyroid eye dz

Orbital varices are known also by what other name?
Orbital venous malformations

What is the clas
Proptosis that
the pt Valsalvas

Do these pts always have proptosis at rest, ie, when not Valsalva-ing?

A

Open-angle Glaucoma: *Secondary*

OAG 2ndry to ↑ EVP

Idiopathic

Arterial and/or venous abnormalities

- A-V fistula
- **Orbital varix**
- Sturge-Weber syndrome

Venous obstruction

- Retrobulbar tumor
- Thyroid eye dz

Orbital varices are known also by what other name?
Orbital venous malformations

What is the clas
Proptosis that
the pt Valsalvas

Do these pts always have proptosis at rest, ie, when not Valsalva-ing?
No; in fact, it is not uncommon for the affected eye to be **enophthalmic** at rest

Q

Open-angle Glaucoma: *Secondary*

OAG 2ndry to ↑ EVP

Idiopathic

Arterial and/or venous abnormalities
- A-V fistula
- **Orbital varix**
- Sturge-Weber syndrome

Venous obstruction
- Retrobulbar tumor
- Thyroid eye dz

Orbital varices are known also by what other name?
Orbital venous malformations

What is the classic presenting sign?
Proptosis that occurs or worsens when the pt's head is dependent , or when the pt Valsalvas

What is the best means of diagnosing an orbital varix?

Q/A

Open-angle Glaucoma: *Secondary*

OAG 2ndry to ↑ EVP

Idiopathic

Arterial and/or venous abnormalities
- A-V fistula
- **Orbital varix**
- Sturge-Weber syndrome

Venous obstruction
- Retrobulbar tumor
- Thyroid eye dz

Orbital varices are known also by what other name?
Orbital venous malformations

What is the classic presenting sign?
Proptosis that occurs or worsens when the pt's head is dependent , or when the pt Valsalvas

What is the best means of diagnosing an orbital varix?
Perform contrast-enhanced spiral CT while the pt action

A

Open-angle Glaucoma: *Secondary*

OAG 2ndry to ↑ EVP

- *Idiopathic*
- *Arterial and/or venous abnormalities*
  - A-V fistula
  - **Orbital varix**
  - Sturge-Weber syndrome
- *Venous obstruction*
  - Retrobulbar tumor
  - Thyroid eye dz

Orbital varices are known also by what other name?
Orbital venous malformations

What is the classic presenting sign?
Proptosis that occurs or worsens when the pt's head is dependent , or when the pt Valsalvas

What is the best means of diagnosing an orbital varix?
Perform contrast-enhanced spiral CT while the pt Valsalvas

Open-angle Glaucoma: *Secondary*

Orbital varix. A 70-year-old woman who presented due to an orbital mass incidentally discovered on an outside brain MR imaging. Axial (*A* and *C*) and coronal (*B* and *D*) CT images of the orbits without (*A* and *B*) and with (*C* and *D*) a Valsalva maneuver demonstrate inducible enlargement of a lobular structure in the right orbit (*arrows*), consistent with a varix. The patient subsequently reported right-eye fullness when bending over.

Q

Open-angle Glaucoma: *Secondary*

OAG 2ndry to ↑ EVP

Idiopathic

Arterial and/or venous abnormalities
- A-V fistula
- **Orbital varix**
- Sturge-Weber syndrome

Venous obstruction
- Retrobulbar tumor
- Thyroid eye dz

Orbital varices are known also by what other name?
Orbital venous malformations

What is the classic presenting sig
Proptosis that occurs or worsens
the pt Valsalvas

Why spiral CT?

What is the best means of diagnosing an orbital varix?
Perform contrast-enhanced **spiral CT** while the pt Valsalvas

A

Open-angle Glaucoma: *Secondary*

OAG 2ndry to ↑ EVP

Idiopathic

Arterial and/or venous abnormalities
- A-V fistula
- **Orbital varix**
- Sturge-Weber syndrome

Venous obstruction
- Retrobulbar tumor
- Thyroid eye dz

Orbital varices are known also by what other name?
Orbital venous malformations

What is the classic presenting sig
Proptosis that occurs or worsens
the pt Valsalvas

What is the best means of diagnosing an orbital varix?
Perform contrast-enhanced **spiral CT** while the pt Valsalvas

Why spiral CT?
Because it's a relatively fast imaging modality

Q

Open-angle Glaucoma: *Secondary*

OAG 2ndry to ↑ EVP

Idiopathic

Arterial and/or venous abnormalities
- A-V fistula
- **Orbital varix**
- Sturge-Weber syndrome

Venous obstruction
- Retrobulbar tumor
- Thyroid eye dz

Orbital varices are known also by what other name?
Orbital venous malformations

What is the classic presenting sig
Proptosis that occurs or worsens
the pt Valsalvas

What is the best means of diagnosing an orbital varix?
Perform contrast-enhanced **spiral CT** while the pt Valsalvas

Why spiral CT?
Because it's a relatively fast imaging modality

Why is speed important?

A

Open-angle Glaucoma: *Secondary*

OAG 2ndry to ↑ EVP

Idiopathic

Arterial and/or venous abnormalities
- A-V fistula
- **Orbital varix**
- Sturge-Weber syndrome

Venous obstruction
- Retrobulbar tumor
- Thyroid eye dz

Orbital varices are known also by what other name?
Orbital venous malformations

What is the classic presenting sig
Proptosis that occurs or worsens
the pt Valsalvas

What is the best means of diagnosing an orbital varix?
Perform contrast-enhanced **spiral CT while the pt Valsalvas**

Why spiral CT?
Because it's a relatively fast imaging modality

Why is speed important?
Because the pt is holding her breath!

Q

Open-angle Glaucoma: *Secondary*

OAG 2ndry to ↑ EVP

Idiopathic

Arterial and/or venous abnormalities
- A-V fistula
- **Orbital varix**
- Sturge-Weber syndrome

Venous obstruction
- Retrobulbar tumor
- Thyroid eye dz

Orbital varices are known also by what other name?
Orbital venous malformations

What is the classic presenting sign?
Proptosis that occurs or worsens when the pt's head is dependent , or when the pt Valsalvas

What is the best means of diagnosing an orbital varix?
Perform contrast-enhanced spiral CT while the pt Valsalvas

How should orbital varices be managed?

A

Open-angle Glaucoma: *Secondary*

OAG 2ndry to ↑ EVP

Idiopathic

Arterial and/or venous abnormalities
- A-V fistula
- **Orbital varix**
- Sturge-Weber syndrome

Venous obstruction
- Retrobulbar tumor
- Thyroid eye dz

Orbital varices are known also by what other name?
Orbital venous malformations

What is the classic presenting sign?
Proptosis that occurs or worsens when the pt's head is dependent , or when the pt Valsalvas

What is the best means of diagnosing an orbital varix?
Perform contrast-enhanced spiral CT while the pt Valsalvas

How should orbital varices be managed?
Conservatively, if at all possible—complete excision is difficult, and significant intra-op bleeding is a concern

Q

Open-angle Glaucoma: *Secondary*

OAG 2ndry to ↑ EVP

Idiopathic

Arterial and/or venous abnormalities
- A-V fistula
- **Orbital varix**
- Sturge-Weber syndrome

Venous obstruction
- Retrobulbar tumor
- Thyroid eye dz

Orbital varices are known also by what other name?
Orbital venous malformations

What is the classic presenting sign?
Proptosis that occurs or worsens when the pt's head is dependent , or when the pt. Valsalvas

Per the Orbit *book, in what two circumstances should excision of an orbital varix be considered?*
--
--

What
Perfo

How should orbital varices be managed?
Conservatively, if at all possible—complete excision is difficult, and significant intra-op bleeding is a concern

A

Open-angle Glaucoma: *Secondary*

OAG 2ndry to ↑ EVP

Idiopathic

Arterial and/or venous abnormalities
- A-V fistula
- **Orbital varix**
- Sturge-Weber syndrome

Venous obstruction
- Retrobulbar tumor
- Thyroid eye dz

Orbital varices are known also by what other name?
Orbital venous malformations

What is the classic presenting sign?
Proptosis that occurs or worsens when the pt's head is dependent , or when the pt. Valsalvas

Per the Orbit *book, in what two circumstances should excision of an orbital varix be considered?*
--If the varix is causing severe pain
--If optic-nerve compression is threatening vision

What
Perfo

How should orbital varices be managed?
Conservatively, if at all possible—complete excision is difficult, and significant intra-op bleeding is a concern

Q

Open-angle Glaucoma: *Secondary*

OAG 2ndry to ↑ EVP

Idiopathic

Arterial and/or venous abnormalities

- A-V fistula
- Orbital varix
- **Sturge-Weber syndrome**

Venous obstruction

- Retrobulbar tumor
- Thyroid eye dz

In one word, what sort of condition is Sturge-Weber?

A

Open-angle Glaucoma: *Secondary*

OAG 2ndry to ↑ EVP

- *Idiopathic*
- *Arterial and/or venous abnormalities*
  - A-V fistula
  - Orbital varix
  - **Sturge-Weber syndrome**
- *Venous obstruction*
  - Retrobulbar tumor
  - Thyroid eye dz

In one word, what sort of condition is Sturge-Weber?
A phakomatosis

Q

Open-angle Glaucoma: *Secondary*

OAG 2ndry to ↑ EVP

Idiopathic

Arterial and/or venous abnormalities
- A-V fistula
- Orbital varix
- **Sturge-Weber syndrome**

Venous obstruction
- Retrobulbar tumor
- Thyroid eye dz

In one word, what sort of condition is Sturge-Weber?
A **phakomatosis**

Briefly, what is a phakomatosis?

Q/A

Open-angle Glaucoma: *Secondary*

OAG 2ndry to ↑ EVP

Idiopathic

Arterial and/or venous abnormalities
- A-V fistula
- Orbital varix
- **Sturge-Weber syndrome**

Venous obstruction
- Retrobulbar tumor
- Thyroid eye dz

In one word, what sort of condition is Sturge-Weber?
A **phakomatosis**

Briefly, what is a phakomatosis?
A congenital condition involving hamartomatous lesions of multiple organ systems, usually including the abb. , ____ and ____

A

Open-angle Glaucoma: *Secondary*

OAG 2ndry to ↑ EVP

Idiopathic

Arterial and/or venous abnormalities
- A-V fistula
- Orbital varix
- **Sturge-Weber syndrome**

Venous obstruction
- Retrobulbar tumor
- Thyroid eye dz

In one word, what sort of condition is Sturge-Weber?
A **phakomatosis**

Briefly, what is a phakomatosis?
A congenital condition involving hamartomatous lesions of multiple organ systems, usually including the CNS , eyes and skin

Q

Open-angle Glaucoma: *Secondary*

OAG 2ndry to ↑ EVP

Idiopathic

Arterial and/or venous abnormalities
- A-V fistula
- Orbital varix
- **Sturge-Weber syndrome**

Venous obstruction
- Retrobulbar tumor
- Thyroid eye dz

In one word, what sort of condition is Sturge-Weber?
A **phakomatosis**

Briefly, what is a phakomatosis?
A congenital condition involving hamartomatous lesions of multiple organ systems, usually including the CNS , eyes and skin

By what more-descriptive name does the BCSC Peds *book refer to them?*

A

Open-angle Glaucoma: *Secondary*

OAG 2ndry to ↑ EVP

Idiopathic

Arterial and/or venous abnormalities
- A-V fistula
- Orbital varix
- **Sturge-Weber syndrome**

Venous obstruction
- Retrobulbar tumor
- Thyroid eye dz

In one word, what sort of condition is Sturge-Weber?
A **phakomatosis**

Briefly, what is a phakomatosis?
A congenital condition involving hamartomatous lesions of multiple organ systems, usually including the **CNS** , eyes and skin

By what more-descriptive name does the BCSC Peds *book refer to them?*
As **neuro…**

A

Open-angle Glaucoma: *Secondary*

OAG 2ndry to ↑ EVP

Idiopathic

Arterial and/or venous abnormalities
- A-V fistula
- Orbital varix
- **Sturge-Weber syndrome**

Venous obstruction
- Retrobulbar tumor
- Thyroid eye dz

In one word, what sort of condition is Sturge-Weber?
A **phakomatosis**

Briefly, what is a phakomatosis?
A congenital condition involving hamartomatous lesions of multiple organ systems, usually including the **CNS** , **eyes** and skin

By what more-descriptive name does the BCSC Peds *book refer to them?*
As **neuro-oculo…**

A

Open-angle Glaucoma: *Secondary*

OAG 2ndry to ↑ EVP

Idiopathic

Arterial and/or venous abnormalities
- A-V fistula
- Orbital varix
- **Sturge-Weber syndrome**

Venous obstruction
- Retrobulbar tumor
- Thyroid eye dz

In one word, what sort of condition is Sturge-Weber?
A **phakomatosis**

Briefly, what is a phakomatosis?
A congenital condition involving hamartomatous lesions of multiple organ systems, usually including the **CNS** , **eyes** and **skin**

By what more-descriptive name does the BCSC Peds *book refer to them?*
As **neuro-oculocutaneous** syndromes

Q

Open-angle Glaucoma: *Secondary*

OAG 2ndry to ↑ EVP

Idiopathic

Arterial and/or venous abnormalities
- A-V fistula
- Orbital varix
- **Sturge-Weber syndrome**

Venous obstruction
- Retrobulbar tumor
- Thyroid eye dz

In one word, what sort of condition is Sturge-Weber?
A phakomatosis

By what noneponymous name is Sturge-Weber known?

A

Open-angle Glaucoma: *Secondary*

OAG 2ndry to ↑ EVP

- *Idiopathic*
- *Arterial and/or venous abnormalities*
  - A-V fistula
  - Orbital varix
  - **Sturge-Weber syndrome**
- *Venous obstruction*
  - Retrobulbar tumor
  - Thyroid eye dz

In one word, what sort of condition is Sturge-Weber?
A phakomatosis

By what noneponymous name is Sturge-Weber known?
Encephalotrigeminal angiomatosis

Q

Open-angle Glaucoma: *Secondary*

OAG 2ndry to ↑ EVP

Idiopathic

Arterial and/or venous abnormalities

- A-V fistula
- Orbital varix
- **Sturge-Weber syndrome**

Venous obstruction

- Retrobulbar tumor
- Thyroid eye dz

What facial lesion is a hallmark of Sturge-Weber syndrome?

Q/A

Open-angle Glaucoma: *Secondary*

OAG 2ndry to ↑ EVP

Idiopathic

Arterial and/or venous abnormalities

- A-V fistula
- Orbital varix
- **Sturge-Weber syndrome**

Venous obstruction

- Retrobulbar tumor
- Thyroid eye dz

What facial lesion is a hallmark of Sturge-Weber syndrome?

The port wine stain, aka ‘ two words ’

A

Open-angle Glaucoma: *Secondary*

OAG 2ndry to ↑ EVP

Idiopathic

Arterial and/or venous abnormalities

- A-V fistula
- Orbital varix
- **Sturge-Weber syndrome**

Venous obstruction

- Retrobulbar tumor
- Thyroid eye dz

What facial lesion is a hallmark of Sturge-Weber syndrome?
The port wine stain, aka ‘ nevus flammeus ’

Open-angle Glaucoma: *Secondary*

Sturge-Weber: Port-wine stain

Q

Open-angle Glaucoma: *Secondary*

OAG 2ndry to ↑ EVP

Idiopathic

Arterial and/or venous abnormalities

- A-V fistula
- Orbital varix
- **Sturge-Weber syndrome**

Venous obstruction

- Retrobulbar tumor
- Thyroid eye dz

What facial lesion is a hallmark of Sturge-Weber syndrome?
The port wine stain, aka ‘ nevus flammeus ’

When does it present?

A

Open-angle Glaucoma: *Secondary*

OAG 2ndry to ↑ EVP

Idiopathic

Arterial and/or venous abnormalities
- A-V fistula
- Orbital varix
- **Sturge-Weber syndrome**

Venous obstruction
- Retrobulbar tumor
- Thyroid eye dz

What facial lesion is a hallmark of Sturge-Weber syndrome?
The port wine stain, aka ‘ nevus flammeus ’

When does it present?
At birth

Open-angle Glaucoma: *Secondary*

Sturge-Weber: Port-wine stain

Q

Open-angle Glaucoma: *Secondary*

OAG 2ndry to ↑ EVP

Idiopathic

Arterial and/or venous abnormalities

- A-V fistula
- Orbital varix
- **Sturge-Weber syndrome**

Venous obstruction

- Retrobulbar tumor
- Thyroid eye dz

What facial lesion is a hallmark of Sturge-Weber syndrome?
The port wine stain, aka ‘ nevus flammeus ’

When does it present?
At birth

What is the typical pattern of distribution?

A

Open-angle Glaucoma: *Secondary*

OAG 2ndry to ↑ EVP

Idiopathic

Arterial and/or venous abnormalities
- A-V fistula
- Orbital varix
- **Sturge-Weber syndrome**

Venous obstruction
- Retrobulbar tumor
- Thyroid eye dz

What facial lesion is a hallmark of Sturge-Weber syndrome?
The port wine stain, aka ‘ nevus flammeus ’

When does it present?
At birth

What is the typical pattern of distribution?
It comports to the distribution of one or more divisions of CN5

Q

Open-angle Glaucoma: *Secondary*

OAG 2ndry to ↑ EVP

Idiopathic

Arterial and/or venous abnormalities
- A-V fistula
- Orbital varix
- **Sturge-Weber syndrome**

Venous obstruction
- Retrobulbar tumor
- Thyroid eye dz

What facial lesion is a hallmark of Sturge-Weber syndrome?
The port wine stain, aka ‘ nevus flammeus ’

When does it present?
At birth

What is the typical pattern of distribution?
It comports to the distribution of one or more divisions of CN5

All infants with Sturge-Weber syndrome have a port wine stain.
Do all infants with a port wine stain have Sturge-Weber syndrome?

A

Open-angle Glaucoma: *Secondary*

OAG 2ndry to ↑ EVP

Idiopathic

Arterial and/or venous abnormalities
- A-V fistula
- Orbital varix
- **Sturge-Weber syndrome**

Venous obstruction
- Retrobulbar tumor
- Thyroid eye dz

What facial lesion is a hallmark of Sturge-Weber syndrome?
The port wine stain, aka ‘ nevus flammeus ’

When does it present?
At birth

What is the typical pattern of distribution?
It comports to the distribution of one or more divisions of CN5

All infants with Sturge-Weber syndrome have a port wine stain.
Do all infants with a port wine stain have Sturge-Weber syndrome?
No

Q

Open-angle Glaucoma: *Secondary*

OAG 2ndry to ↑ EVP

Idiopathic

Arterial and/or venous abnormalities

- A-V fistula
- Orbital varix
- **Sturge-Weber syndrome**

Venous obstruction

- Retrobulbar tumor
- Thyroid eye dz

What facial lesion is a hallm
The port wine stain, aka ' ne

When does it present?
At birth

What is the typical pattern o
It comports to the distributio

All infants with Sturge-Webe
Do all infants with a port win
No

What posterior-pole lesion is a hallmark of Sturge-Weber syndrome?

[redacted]

A

Open-angle Glaucoma: *Secondary*

OAG 2ndry to ↑ EVP

Idiopathic

Arterial and/or venous abnormalities

- A-V fistula
- Orbital varix
- **Sturge-Weber syndrome**

Venous obstruction

- Retrobulbar tumor
- Thyroid eye dz

What facial lesion is a hallm
The port wine stain, aka ' ne

When does it present?
At birth

What is the typical pattern o
It comports to the distributio

All infants with Sturge-Webe
Do all infants with a port win
No

What posterior-pole lesion is a hallmark of Sturge-Weber syndrome?
The **diffuse choroidal hemangioma**

Q

Open-angle Glaucoma: *Secondary*

OAG 2ndry to ↑ EVP

Idiopathic

Arterial and/or venous abnormalities

- A-V fistula
- Orbital varix
- **Sturge-Weber syndrome**

Venous obstruction

- Retrobulbar tumor
- Thyroid eye dz

What facial lesion is a hallm
The port wine stain, aka ' ne

When does it present?
At birth

What is the typical pattern o
It comports to the distributio

All infants with Sturge-Webe
Do all infants with a port win
No

What posterior-pole lesion is a hallmark of Sturge-Weber syndrome?
The **diffuse choroidal hemangioma**

By what food-based name is the DFE appearance of a diffuse choroidal hemangioma known?

A

Open-angle Glaucoma: *Secondary*

OAG 2ndry to ↑ EVP

Idiopathic

Arterial and/or venous abnormalities
- A-V fistula
- Orbital varix
- **Sturge-Weber syndrome**

Venous obstruction
- Retrobulbar tumor
- Thyroid eye dz

What facial lesion is a hallm
The port wine stain, aka ' ne

When does it present?
At birth

What is the typical pattern o
It comports to the distributio

All infants with Sturge-Webe
Do all infants with a port win
No

What posterior-pole lesion is a hallmark of Sturge-Weber syndrome?
The **diffuse choroidal hemangioma**

By what food-based name is the DFE appearance of a diffuse choroidal hemangioma known?
'Tomato catsup fundus'

Open-angle Glaucoma: *Secondary*

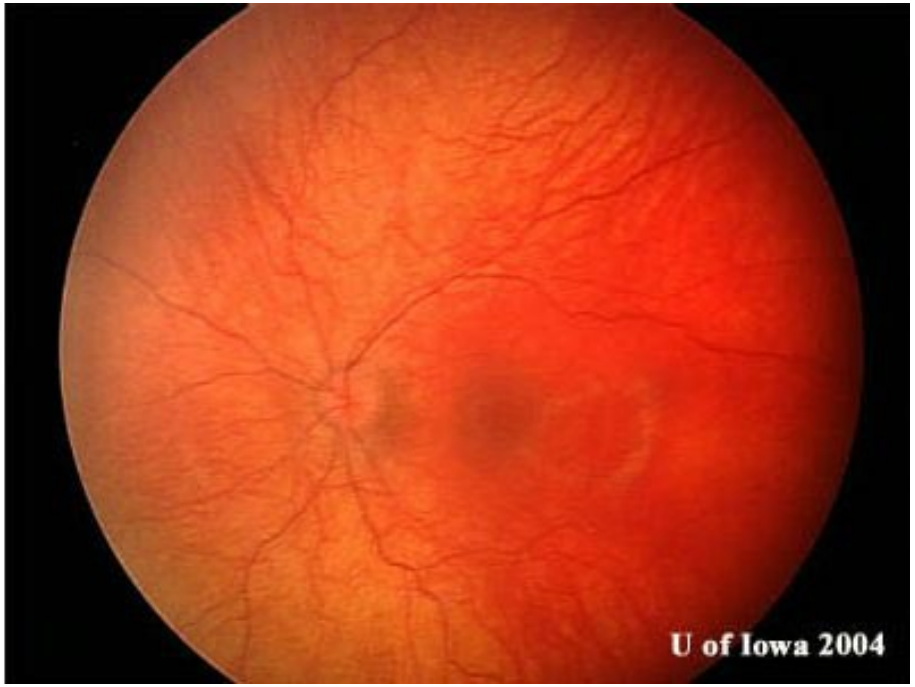

Sturge-Weber: Tomato catsup fundus OD

Q

Open-angle Glaucoma: *Secondary*

OAG 2ndry to ↑ EVP

Idiopathic

Arterial and/or venous abnormalities
- A-V fistula
- Orbital varix
- **Sturge-Weber syndrome**

Venous obstruction
- Retrobulbar tumor
- Thyroid eye dz

What facial lesion is a hallm
The port wine stain, aka ' ne

When does it present?
At birth

What is the typical pattern o
It comports to the distributio

All infants with Sturge-Webe
Do all infants with a port win
No

What posterior-pole lesion is a hallmark of Sturge-Weber syndrome?
The **diffuse choroidal hemangioma**

Diffuse choroidal hemangioma is present in what percent of SWS?

A

Open-angle Glaucoma: *Secondary*

OAG 2ndry to ↑ EVP

Idiopathic

Arterial and/or venous abnormalities

- A-V fistula
- Orbital varix
- **Sturge-Weber syndrome**

Venous obstruction

- Retrobulbar tumor
- Thyroid eye dz

What facial lesion is a hallm
The port wine stain, aka ' ne

When does it present?
At birth

What is the typical pattern o
It comports to the distributio

All infants with Sturge-Webe
Do all infants with a port win
No

What posterior-pole lesion is a hallmark of Sturge-Weber syndrome?
The **diffuse choroidal hemangioma**

Diffuse choroidal hemangioma is present in what percent of SWS?
About 50%

Q

Open-angle Glaucoma: *Secondary*

OAG 2ndry to ↑ EVP

Idiopathic

Arterial and/or venous abnormalities
- A-V fistula
- Orbital varix
- **Sturge-Weber syndrome**

Venous obstruction
- Retrobulbar tumor
- Thyroid eye dz

What facial lesion is a hallm
The port wine stain, aka ' ne

When does it present?
At birth

What is the typical pattern o
It comports to the distributio

All infants with Sturge-Webe
Do all infants with a port win
No

What posterior-pole lesion is a hallmark of Sturge-Weber syndrome?
The **diffuse choroidal hemangioma**

Diffuse choroidal hemangioma is present in what percent of SWS?
About 50%

Can the choroidal hemangioma be present bilaterally?

A

Open-angle Glaucoma: *Secondary*

OAG 2ndry to ↑ EVP

Idiopathic

Arterial and/or venous abnormalities

- A-V fistula
- Orbital varix
- **Sturge-Weber syndrome**

Venous obstruction

- Retrobulbar tumor
- Thyroid eye dz

What facial lesion is a hallm
The port wine stain, aka ' ne

When does it present?
At birth

What is the typical pattern o
It comports to the distributio

All infants with Sturge-Webe
Do all infants with a port win
No

What posterior-pole lesion is a hallmark of Sturge-Weber syndrome?
The **diffuse choroidal hemangioma**

Diffuse choroidal hemangioma is present in what percent of SWS?
About 50%

Can the choroidal hemangioma be present bilaterally?
Yes, but it's uncommon

Q

Open-angle Glaucoma: *Secondary*

OAG 2ndry to ↑ EVP

Idiopathic

Arterial and/or venous abnormalities

- A-V fistula
- Orbital varix
- **Sturge-Weber syndrome**

Venous obstruction

- Retrobulbar tumor
- Thyroid eye dz

What facial lesion is a hallm
The port wine stain, aka ' ne

When does it present?
At birth

What is the typical pattern o
It comports to the distributio

All infants with Sturge-Webe
Do all infants with a port win
No

What posterior-pole lesion is a hallmark of Sturge-Weber syndrome?
The **diffuse choroidal hemangioma**

Diffuse choroidal hemangioma is present in what percent of SWS?
About 50%

Can the choroidal hemangioma be present bilaterally?
Yes, but it's uncommon

Does the choroidal hemangioma have malignant potential?

A

Open-angle Glaucoma: *Secondary*

OAG 2ndry to ↑ EVP

Idiopathic

Arterial and/or venous abnormalities
- A-V fistula
- Orbital varix
- **Sturge-Weber syndrome**

Venous obstruction
- Retrobulbar tumor
- Thyroid eye dz

What facial lesion is a hallm
The port wine stain, aka ' ne

When does it present?
At birth

What is the typical pattern o
It comports to the distributio

All infants with Sturge-Webe
Do all infants with a port win
No

What posterior-pole lesion is a hallmark of Sturge-Weber syndrome?
The **diffuse choroidal hemangioma**

Diffuse choroidal hemangioma is present in what percent of SWS?
About 50%

Can the choroidal hemangioma be present bilaterally?
Yes, but it's uncommon

Does the choroidal hemangioma have malignant potential?
No

Q

Open-angle Glaucoma: *Secondary*

OAG 2ndry to ↑ EVP

Idiopathic

Arterial and/or venous

Venous obstruction

There is another DFE finding that is a hallmark of Sturge-Weber syndrome. What is it?

– Orbital varix

– **Sturge-Weber syndrome**

What facial lesion is a hallm
The port wine stain, aka ‘ ne

When does it present?
At birth

What is the typical pattern o
It comports to the distributio

All infants with Sturge-Webe
Do all infants with a port win
No

What posterior-pole lesion is a hallmark of Sturge-Weber syndrome?
The **diffuse choroidal hemangioma**

Diffuse choroidal hemangioma is present in what percent of SWS?
About 50%

Can the choroidal hemangioma be present bilaterally?
Yes, but it’s uncommon

Does the choroidal hemangioma have malignant potential?
No

A

Open-angle Glaucoma: *Secondary*

OAG 2ndry to ↑ EVP

Idiopathic

Arterial and/or venous

Venous obstruction

There is another DFE finding that is a hallmark of Sturge-Weber syndrome. What is it?
Glaucomatous cupping of the ONH, aka the reason we're talking about it!

– Orbital varix

– **Sturge-Weber syndrome**

What facial lesion is a hallm
The port wine stain, aka ' ne

When does it present?
At birth

What is the typical pattern o
It comports to the distributio

All infants with Sturge-Webe
Do all infants with a port win
No

What posterior-pole lesion is a hallmark of Sturge-Weber syndrome?
The **diffuse choroidal hemangioma**

Diffuse choroidal hemangioma is present in what percent of SWS?
About 50%

Can the choroidal hemangioma be present bilaterally?
Yes, but it's uncommon

Does the choroidal hemangioma have malignant potential?
No

Open-angle Glaucoma: *Secondary*

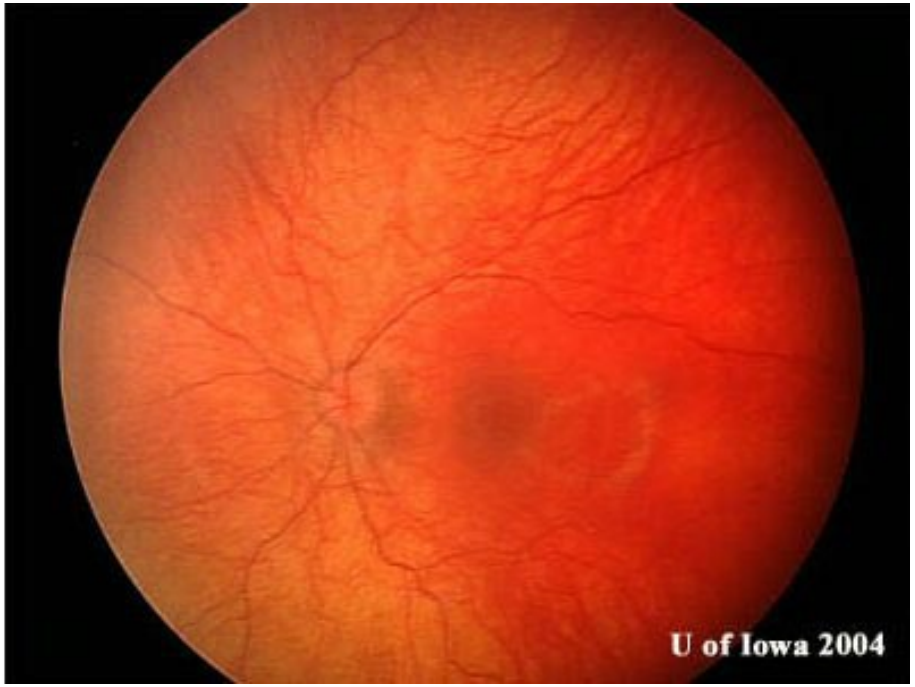

Sturge-Weber: Same pic, but this time take note the glaucomatous cupping on the affected side

Q

Open-angle Glaucoma: *Secondary*

OAG 2ndry to ↑ EVP

Idiopathic

Arterial and/or venous

Venous obstruction

There is another DFE finding that is a hallmark of Sturge-Weber syndrome. What is it?

Glaucomatous cupping of the ONH, aka the reason we're talking about it!

Sturge-Weber syndrome

What facial lesion is a hallm

The port wine stain, aka ' ne

What posterior-pole lesion is a hallmark of Sturge-Weber syndrome?

The **diffuse choroidal hemangioma**

What percent of Sturge-Weber syndrome pts develop glaucoma?

what percent of SWS?

bilaterally?

All infants with Sturge-Webe

Do all infants with a port win

No

Does the choroidal hemangioma have malignant potential?

No

A

Open-angle Glaucoma: *Secondary*

OAG 2ndry to ↑ EVP

Idiopathic

Arterial and/or venous

Venous obstruction

There is another DFE finding that is a hallmark of Sturge-Weber syndrome. What is it?

Glaucomatous cupping of the ONH, aka the reason we're talking about it!

Sturge-Weber syndrome

What facial lesion is a hallm

The port wine stain, aka ' ne

What posterior-pole lesion is a hallmark of Sturge-Weber syndrome?

The **diffuse choroidal hemangioma**

What percent of Sturge-Weber syndrome pts develop glaucoma?

Estimates run as high as 70

what percent of SWS?

bilaterally?

All infants with Sturge-Webe

Do all infants with a port win

No

Does the choroidal hemangioma have malignant potential?

No

Q

Open-angle Glaucoma: *Secondary*

OAG 2ndry to ↑ EVP

Idiopathic

Arterial and/or venous

Venous obstruction

There is another DFE finding that is a hallmark of Sturge-Weber syndrome. What is it?

Glaucomatous cupping of the ONH, aka the reason we're talking about it!

Sturge-Weber syndrome

What facial lesion is a hallm

The **port wine stain**, aka '

What posterior-pole lesion is a hallmark of Sturge-Weber syndrome?

The **diffuse choroidal hemangioma**

What percent of Sturge-Weber syndrome pts develop glaucoma?

Estimates run as high as 70

Is there a relationship between the port-wine stain and risk of glaucoma?

what percent of SWS?

bilaterally?

All infants with Sturge-Webe

Do all infants with a port win

No

Does the choroidal hemangioma have malignant potential?

No

Q/A

Open-angle Glaucoma: *Secondary*

OAG 2ndry to ↑ EVP

Idiopathic

Arterial and/or venous

Venous obstruction

There is another DFE finding that is a hallmark of Sturge-Weber syndrome. What is it?

Glaucomatous cupping of the ONH, aka the reason we're talking about it!

Sturge-Weber syndrome

What facial lesion is a hallm

The **port wine stain**, aka '

What posterior-pole lesion is a hallmark of Sturge-Weber syndrome?

The **diffuse choroidal hemangioma**

What percent of Sturge-Weber syndrome pts develop glaucoma?

Estimates run as high as 70

Is there a relationship between the port-wine stain and risk of glaucoma?

Yes—if the port-wine stain involves the [redacted], the risk is increased

what percent of SWS?

bilaterally?

All infants with Sturge-Webe

Do all infants with a port win

No

Does the choroidal hemangioma have malignant potential?

No

A

Open-angle Glaucoma: *Secondary*

OAG 2ndry to ↑ EVP

Idiopathic

Arterial and/or venous

Venous obstruction

There is another DFE finding that is a hallmark of Sturge-Weber syndrome. What is it?

Glaucomatous cupping of the ONH, aka the reason we're talking about it!

Sturge-Weber syndrome

What facial lesion is a hallm

The **port wine stain**, aka '

What posterior-pole lesion is a hallmark of Sturge-Weber syndrome?

The **diffuse choroidal hemangioma**

What percent of Sturge-Weber syndrome pts develop glaucoma?

Estimates run as high as 70

Is there a relationship between the port-wine stain and risk of glaucoma?

Yes—if the port-wine stain involves the **eyelid** , the risk is increased

what percent of SWS?

bilaterally?

All infants with Sturge-Webe

Do all infants with a port win

No

Does the choroidal hemangioma have malignant potential?

No

Open-angle Glaucoma: *Secondary*

OAG 2ndry to ↑ EVP

Idiopathic

Arterial and/or venous

Venous obstruction

There is another DFE finding that is a hallmark of Sturge-Weber syndrome. What is it?
Glaucomatous cupping of the ONH, aka the reason we're talking about it!

Sturge-Weber syndrome

What facial lesion is a hallm
The **port wine stain**, aka '

What posterior-pole lesion is a hallmark of Sturge-Weber syndrome?
The **diffuse choroidal hemangioma**

What percent of Sturge-Weber syndrome pts develop glaucoma?

VS?

For more on Sturge-Weber syndrome, see slide-set P10

Is there a relationship between the port-wine stain and risk of glaucoma?
Yes—if the port-wine stain involves the **eyelid** , the risk is increased

bilaterally?

All infants with Sturge-Webe
Do all infants with a port win
No

Does the choroidal hemangioma have malignant potential?
No

Q

Open-angle Glaucoma: *Secondary*

OAG 2ndry to ↑ EVP

- *Idiopathic*
- *Arterial and/or venous abnormalities*
  - A-V fistula
- *Venous obstruction*
  - Retrobulbar tumor
  - **Thyroid eye dz**

In a nutshell, what causes increased EVP in thyroid eye dz (TED)?

A

Open-angle Glaucoma: *Secondary*

OAG 2ndry to ↑ EVP

- *Idiopathic*
- *Arterial and/or venous abnormalities*
  - A-V fistula
- *Venous obstruction*
  - Retrobulbar tumor
  - **Thyroid eye dz**

In a nutshell, what causes increased EVP in thyroid eye dz (TED)?
Recall that TED involves congestion of the orbit owing to both infiltrating inflammatory cells as well as increased secretion of ground substance (eg, glycosaminoglycans). This increase in orbital mass leads to proptosis (TED is the #1 cause of both uni- and bilateral proptosis in adults).

Q

Open-angle Glaucoma: *Secondary*

OAG 2ndry to ↑ EVP

- *Idiopathic*
- *Arterial and/or venous abnormalities*
  - A-V fistula
- *Venous obstruction*
  - Retrobulbar tumor
  - **Thyroid eye dz**

In a nutshell, what causes increased EVP in thyroid eye dz (TED)?
Recall that TED involves congestion of the orbit owing to both infiltrating inflammatory cells as well as increased secretion of ground substance (eg, glycosaminoglycans). This increase in orbital mass leads to proptosis (TED is the #1 cause of both uni- and bilateral proptosis in adults). Further, the orbital congestion often compresses the two words, which in turn increases EVP.

A

Open-angle Glaucoma: *Secondary*

OAG 2ndry to ↑ EVP

- *Idiopathic*
- *Arterial and/or venous abnormalities*
  - A-V fistula
- *Venous obstruction*
  - Retrobulbar tumor
  - **Thyroid eye dz**

In a nutshell, what causes increased EVP in thyroid eye dz (TED)?
Recall that TED involves congestion of the orbit owing to both infiltrating inflammatory cells as well as increased secretion of ground substance (eg, glycosaminoglycans). This increase in orbital mass leads to proptosis (TED is the #1 cause of both uni- and bilateral proptosis in adults). Further, the orbital congestion often compresses the vortex veins , which in turn increases EVP.

Open-angle Glaucoma: *Secondary*

OAG 2ndry to ↑ EVP

- *Idiopathic*
- *Arterial and/or venous abnormalities*
  - A-V fistula
- *Venous obstruction*
  - Retrobulbar tumor
  - **Thyroid eye dz**

In a nutshell, what causes increased EVP in thyroid eye dz (TED)?
Recall that TED matory cells as well as increase s increase in orbital mass leads to proptosis (TED is the #1 cause of both uni- and bilateral proptosis in adults). Further, the orbital congestion often compresses the vortex veins , which in turn increases EVP.

For more on TED, see slide-set O5

Q

Open-angle Glaucoma: *Secondary*

OAG 2ndry to ↑ EVP

Is OAG 2ndry to increased EVP amenable to medical management?

Q/A

Open-angle Glaucoma: *Secondary*

OAG 2ndry to ↑ EVP

Is OAG 2ndry to increased EVP amenable to medical management?
Yes, provided the clinician keep in mind that treatments which work by [redacted] are unlikely to be effective

A

Open-angle Glaucoma: *Secondary*

OAG 2ndry to ↑ EVP

Is OAG 2ndry to increased EVP amenable to medical management?
Yes, provided the clinician keep in mind that treatments which work by increasing TM outflow are unlikely to be effective

Q

Open-angle Glaucoma: *Secondary*

OAG 2ndry to ↑ EVP

Is OAG 2ndry to increased EVP amenable to medical management?
Yes, provided the clinician keep in mind that treatments which work by increasing TM outflow are unlikely to be effective

Why don't treatments directed at increasing TM outflow work?

A

Open-angle Glaucoma: *Secondary*

OAG 2ndry to ↑ EVP

Is OAG 2ndry to increased EVP amenable to medical management?
Yes, provided the clinician keep in mind that treatments which work by increasing TM outflow are unlikely to be effective

Why don't treatments directed at increasing TM outflow work?
Because of the pathophysiology of the condition—the mechanism by which IOP is elevated.

A

Open-angle Glaucoma: *Secondary*

OAG 2ndry to ↑ EVP

Is OAG 2ndry to increased EVP amenable to medical management?
Yes, provided the clinician keep in mind that treatments which work by increasing TM outflow are unlikely to be effective

Why don't treatments directed at increasing TM outflow work?
Because of the pathophysiology of the condition—the mechanism by which IOP is elevated. Remember: High EVP produces back-pressure that is transmitted to the AC via a path that directly involves the TM. Because of this, the TM is not amenable to therapeutic maneuvers intended to enhance its functionality.

Q

Open-angle Glaucoma: *Secondary*

OAG 2ndry to ↑ EVP

Is OAG 2ndry to increased EVP amenable to medical management?
Yes, provided the clinician keep in mind that treatments which work by increasing TM outflow are unlikely to be effective

Why don't treatments directed at increasing TM outflow work?
Because of the pathophysiology of the condition—the mechanism by which IOP is elevated. Remember: High EVP produces back-pressure that is transmitted to the AC via a path that directly involves the TM. Because of this, **the TM is not amenable to therapeutic maneuvers intended to enhance its functionality**.

Which two therapies are off the table?
--
Hints forthcoming…
--

Q

Open-angle Glaucoma: *Secondary*

OAG 2ndry to ↑ EVP

Is OAG 2ndry to increased EVP amenable to medical management?
Yes, provided the clinician keep in mind that treatments which work by increasing TM outflow are unlikely to be effective

Why don't treatments directed at increasing TM outflow work?
Because of the pathophysiology of the condition—the mechanism by which IOP is elevated. Remember: High EVP produces back-pressure that is transmitted to the AC via a path that directly involves the TM. Because of this, **the TM is not amenable to therapeutic maneuvers intended to enhance its functionality**.

Which two therapies are off the table?
-- *(this one is NBD, because you never use it anyway)*
-- *(this one you use a **lot**)*

Q/A

Open-angle Glaucoma: *Secondary*

OAG 2ndry to ↑ EVP

Is OAG 2ndry to increased EVP amenable to medical management?
Yes, provided the clinician keep in mind that treatments which work by increasing TM outflow are unlikely to be effective

Why don't treatments directed at increasing TM outflow work?
Because of the pathophysiology of the condition—the mechanism by which IOP is elevated. Remember: High EVP produces back-pressure that is transmitted to the AC via a path that directly involves the TM. Because of this, **the TM is not amenable to therapeutic maneuvers intended to enhance its functionality**.

Which two therapies are off the table?
--Topical tx with…
--Surgical tx with…

A

Open-angle Glaucoma: *Secondary*

OAG 2ndry to ↑ EVP

Is OAG 2ndry to increased EVP amenable to medical management?
Yes, provided the clinician keep in mind that treatments which work by increasing TM outflow are unlikely to be effective

Why don't treatments directed at increasing TM outflow work?
Because of the pathophysiology of the condition—the mechanism by which IOP is elevated. Remember: High EVP produces back-pressure that is transmitted to the AC via a path that directly involves the TM. Because of this, **the TM is not amenable to therapeutic maneuvers intended to enhance its functionality**.

Which two therapies are off the table?
--Topical tx with…**pilo**
--Surgical tx with…**SLT**

Open-angle Glaucoma: *Secondary*

OAG 2ndry to ↑ EVP

Is OAG 2ndry to increased EVP amenable to medical management?
Yes, provided the clinician keep in mind that treatments which work by increasing TM outflow are unlikely to be effective

Why don't treatments directed at increasing TM outflow work?
Because of the pathophysiology of the condition—the mechanism by which IOP is elevated. Remember: High EVP produces back-pressure that is transmitted to the AC via a path that directly involves the TM. Because of this, **the TM is not amenable to therapeutic maneuvers intended to enhance its functionality**.

Which two therapies are off the table?
--Topical tx with…**pilo**
--**Surgical tx with**…*MIGS?*

If you answered MIGS…

Open-angle Glaucoma: *Secondary*

OAG 2ndry to ↑ EVP

Is OAG 2ndry to increased EVP amenable to medical management?
Yes, provided the clinician keep in mind that treatments which work by increasing TM outflow are unlikely to be effective

Why don't treatments directed at increasing TM outflow work?
Because of the pathophysiology of the condition—the mechanism by which IOP is elevated. Remember: High EVP produces back-pressure that is transmitted to the AC via a path that directly involves the TM. Because of this, **the TM is not amenable to therapeutic maneuvers intended to enhance its functionality**.

Which two therapies are off the table?
--Topical tx with…**pilo**
--**Surgical tx with**…*MIGS?*

If you answered MIGS…The *Glaucoma* book in my possession does not address these procedures specifically in the context of elevated EVP. But it would certainly stand to reason that procedures intended to facilitate TM outflow (as is the case for all FDA-approved MIGS at the time of this writing) would be ineffective as well.

Q

Open-angle Glaucoma: *Secondary*

OAG 2ndry to ↑ EVP

Is OAG 2ndry to increased EVP amenable to medical management?
Yes, provided the clinician keep in mind that treatments which work by increasing TM outflow are unlikely to be effective

Why don't treatments directed at increasing TM outflow work?
Because of the pathophysiology of the condition—the mechanism by which IOP is elevated. Remember: High EVP produces back-pressure that is transmitted to the AC via a path that directly involves the TM. Because of this, the TM is not amenable to therapeutic maneuvers intended to enhance its functionality.

OK, so what treatments should *be employed?*

Q/A

Open-angle Glaucoma: *Secondary*

OAG 2ndry to ↑ EVP

Is OAG 2ndry to increased EVP amenable to medical management?
Yes, provided the clinician keep in mind that treatments which work by increasing TM outflow are unlikely to be effective

Why don't treatments directed at increasing TM outflow work?
Because of the pathophysiology of the condition—the mechanism by which IOP is elevated. Remember: High EVP produces back-pressure that is transmitted to the AC via a path that directly involves the TM. Because of this, the TM is not amenable to therapeutic maneuvers intended to enhance its functionality.

OK, so what treatments should *be employed?*
Drops that three words should be used, along with those that

three diff words

A

Open-angle Glaucoma: *Secondary*

OAG 2ndry to ↑ EVP

Is OAG 2ndry to increased EVP amenable to medical management?
Yes, provided the clinician keep in mind that treatments which work by increasing TM outflow are unlikely to be effective

Why don't treatments directed at increasing TM outflow work?
Because of the pathophysiology of the condition—the mechanism by which IOP is elevated. Remember: High EVP produces back-pressure that is transmitted to the AC via a path that directly involves the TM. Because of this, the TM is not amenable to therapeutic maneuvers intended to enhance its functionality.

OK, so what treatments should *be employed?*
Drops that decrease aqueous production should be used, along with those that increase uveoscleral outflow

Q

Open-angle Glaucoma: *Secondary*

OAG 2ndry to ↑ EVP

Is OAG 2ndry to increased EVP amenable to medical management?
Yes, provided the clinician keep in mind that treatments which work by increasing TM outflow are unlikely to be effective

Why don't treatments directed at increasing TM outflow work?
Because of the pathophysiology of the condition—the mechanism by which IOP is elevated. Remember: High EVP produces back-pressure that is transmitted to the AC via a path that directly involves the TM. Because of this, the TM is not amenable to therapeutic maneuvers intended to enhance its functionality.

OK, so what treatments should *be employed?*
Drops that decrease aqueous production should be used, along with those that increase uveoscleral outflow

If medical management fails, should filtering surgery be pursued?

Q/A

Open-angle Glaucoma: *Secondary*

OAG 2ndry to ↑ EVP

Is OAG 2ndry to increased EVP amenable to medical management?
Yes, provided the clinician keep in mind that treatments which work by increasing TM outflow are unlikely to be effective

Why don't treatments directed at increasing TM outflow work?
Because of the pathophysiology of the condition—the mechanism by which IOP is elevated. Remember: High EVP produces back-pressure that is transmitted to the AC via a path that directly involves the TM. Because of this, the TM is not amenable to therapeutic maneuvers intended to enhance its functionality.

OK, so what treatments should *be employed?*
Drops that decrease aqueous production should be used, along with those that increase uveoscleral outflow

If medical management fails, should filtering surgery be pursued?
While not strictly contraindicated, it is best not attempted by surgeons who are faint of heart, because the presence of elevated EVP significantly increases the risk of intra-op [redacted] of the uvea.

A

Open-angle Glaucoma: *Secondary*

OAG 2ndry to ↑ EVP

Is OAG 2ndry to increased EVP amenable to medical management?
Yes, provided the clinician keep in mind that treatments which work by increasing TM outflow are unlikely to be effective

Why don't treatments directed at increasing TM outflow work?
Because of the pathophysiology of the condition—the mechanism by which IOP is elevated. Remember: High EVP produces back-pressure that is transmitted to the AC via a path that directly involves the TM. Because of this, the TM is not amenable to therapeutic maneuvers intended to enhance its functionality.

OK, so what treatments should *be employed?*
Drops that decrease aqueous production should be used, along with those that increase uveoscleral outflow

If medical management fails, should filtering surgery be pursued?
While not strictly contraindicated, it is best not attempted by surgeons who are faint of heart, because the presence of elevated EVP significantly increases the risk of intra-op effusion and/or hemorrhage of the uvea.

A

Open-angle Glaucoma: *Secondary*

OAG 2ndry to ↑ EVP

Is OAG 2ndry to increased EVP amenable to medical management?
Yes, provided the clinician keep in mind that treatments which work by increasing TM outflow are unlikely to be effective

Why don't treatments directed at increasing TM outflow work?
Because of the pathophysiology of the condition—the mechanism by which IOP is elevated. Remember: High EVP produces back-pressure that is transmitted to the AC via a path that directly involves the TM. Because of this, the TM is not amenable to therapeutic maneuvers intended to enhance its functionality.

OK, so what treatments should *be employed?*
Drops that decrease aqueous production should be used, along with those that increase uveoscleral outflow

If medical management fails, should filtering surgery be pursued?
While not strictly contraindicated, it is best not attempted by surgeons who are faint of heart, because the presence of elevated EVP significantly increases the risk of intra-op effusion and/or hemorrhage of the uvea. **Filtering surgeries on these eyes can get real sporty real fast.**

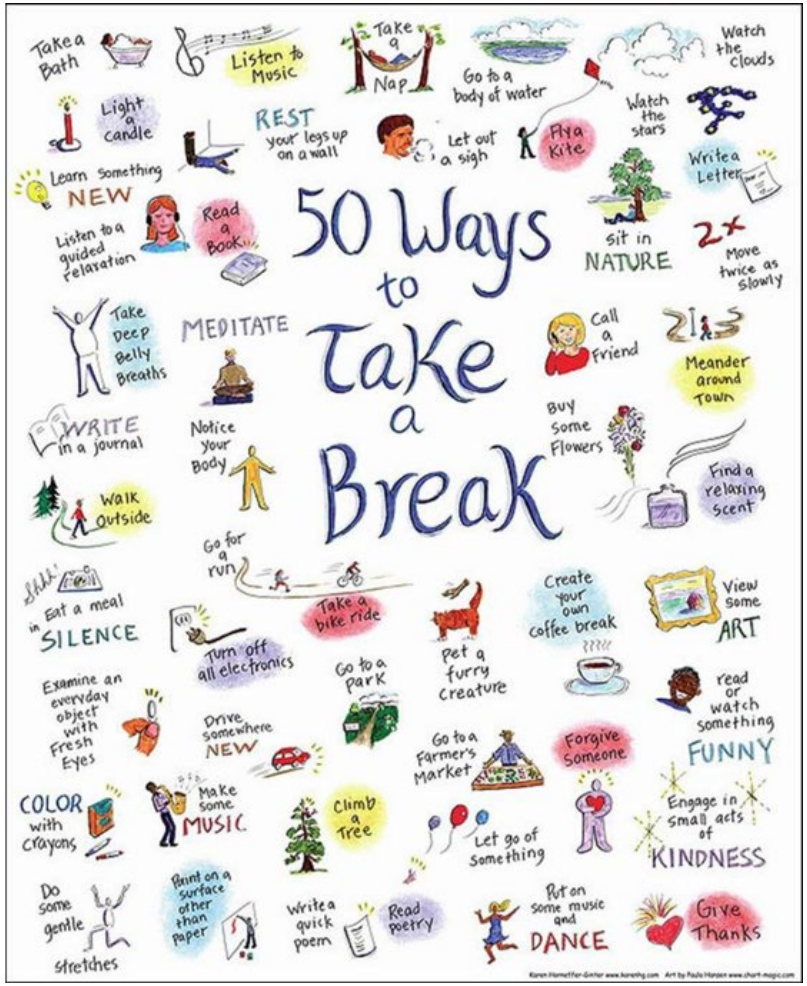

(This is a good point in the set to take a break)

Open-angle Glaucoma: *Secondary*

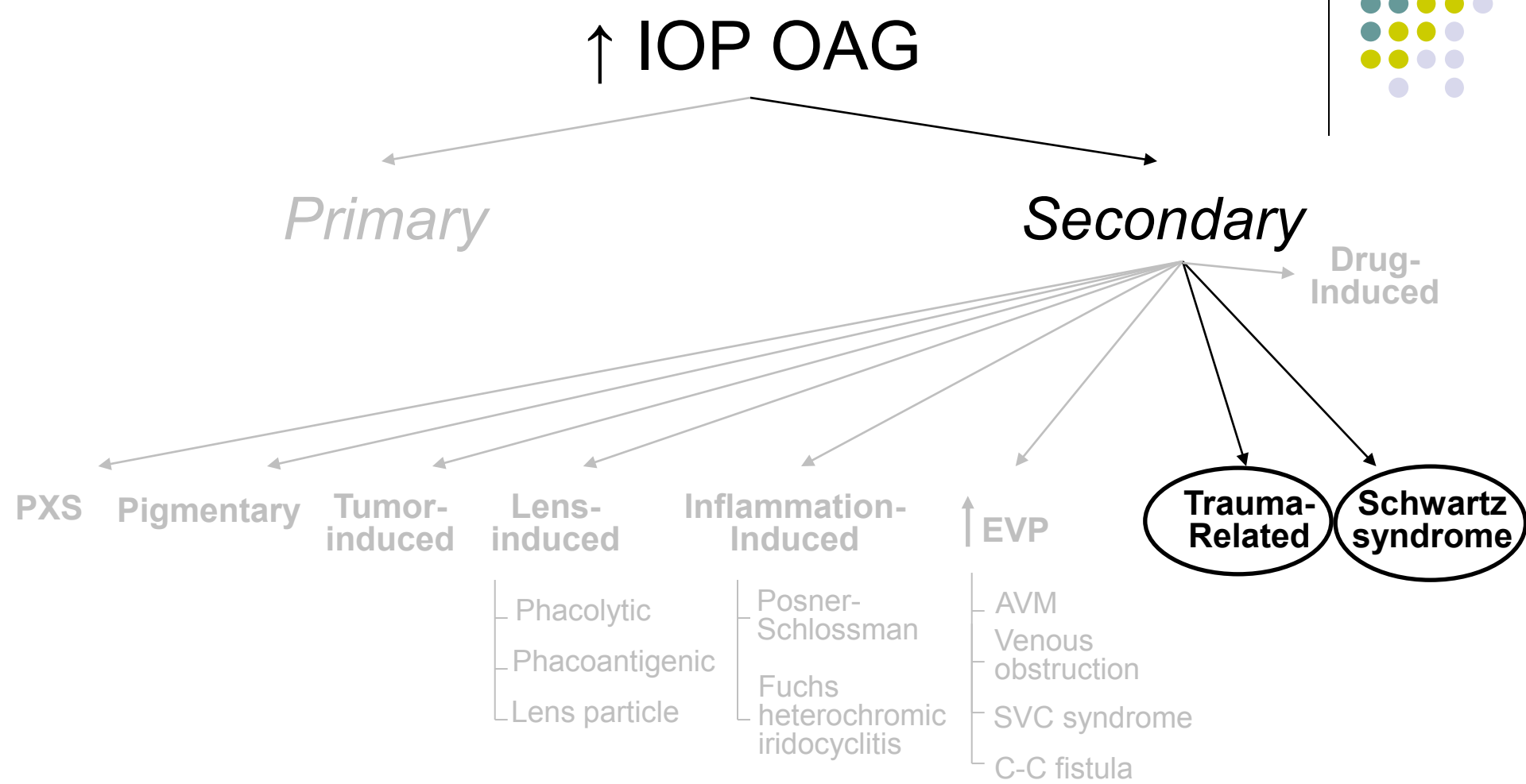

Next let's take a look at certain trauma-related causes of secondary OAG, along with Schwartz syndrome

Q

Open-angle Glaucoma: *Secondary*

Glaucoma 2ndry to hyphema

Hemolytic glaucoma

Ghost-cell glaucoma

One of these things is not like the others. Which two belong together, which one stands alone, and why?

A

Open-angle Glaucoma: *Secondary*

Glaucoma 2ndry to hyphema

Follows ***AC*** bleed

Hemolytic glaucoma

Ghost-cell glaucoma

Follow ***vitreous*** bleed

One of these things is not like the others. Which two belong together, which one stands alone, and why?

Open-angle Glaucoma: *Secondary*

Glaucoma 2ndry to hyphema

Follows ***AC*** bleed

Hyphema is covered in its own slide-set (FELT12)

Hemolytic glaucoma

Ghost-cell glaucoma

Follow ***vitreous*** bleed

Open-angle Glaucoma: *Secondary*

Glaucoma 2ndry to hyphema

Follows ***AC*** bleed

Hemolytic glaucoma **Ghost-cell glaucoma**

Follow ***vitreous*** bleed

The remainder of this set will focus on **hemolytic-** *and* **ghost-cell glaucoma**

Open-angle Glaucoma: *Secondary*

Glaucoma 2ndry to hyphema

Follows ***AC*** bleed

Hemolytic glaucoma **Ghost-cell glaucoma**

Follow ***vitreous*** bleed

THIS IS IMPORTANT! Take a moment to file a mental note before proceeding:
Hemolytic- and ghost-cell glaucoma follow a ***vitreous*** bleed, not an ***AC*** bleed!

Q

Open-angle Glaucoma: *Secondary*

Glaucoma 2ndry to hyphema

Follows ***AC*** bleed

Hemolytic glaucoma **Ghost-cell glaucoma**

Follow ***vitreous*** bleed

What causes of vitreous hemorrhage are involved?

A

Open-angle Glaucoma: *Secondary*

Glaucoma 2ndry to hyphema

Follows ***AC*** bleed

Hemolytic glaucoma **Ghost-cell glaucoma**

Follow ***vitreous*** bleed

What causes of vitreous hemorrhage are involved?
The usual suspects—PDR, CRVO, etc, as well as trauma

Q

Open-angle Glaucoma: *Secondary*

Glaucoma 2ndry to hyphema

Follows ***AC*** bleed

Hemolytic glaucoma **Ghost-cell glaucoma**

Follow ***vitreous*** bleed

What causes of vitreous hemorrhage are involved?
The usual suspects—PDR, CRVO, etc, as well as trauma

How does the blood get from the vitreous cavity to the AC?

A

Open-angle Glaucoma: *Secondary*

Glaucoma 2ndry to hyphema

Follows ***AC*** bleed

Hemolytic glaucoma **Ghost-cell glaucoma**

Follow ***vitreous*** bleed

What causes of vitreous hemorrhage are involved?
The usual suspects—PDR, CRVO, etc, as well as trauma

How does the blood get from the vitreous cavity to the AC?
It can occur spontaneously, but more commonly there's a hx of anterior hyaloid face disruption from trauma or surgery (eg, cataract; PPV) that provides a ready pathway for cells to reach the AC

Q

Open-angle Glaucoma: *Secondary*

Glaucoma 2ndry to hyphema

↑

Follows ***AC*** bleed

Hemolytic glaucoma

↓

?

Ghost-cell glaucoma

↓

?

In a nutshell, what is the mechanism underlying both hemolytic and ghost-cell glaucomas?

A

Open-angle Glaucoma: *Secondary*

Glaucoma 2ndry to hyphema

↑

Follows ***AC*** bleed

Hemolytic glaucoma

↓

TM clogged

Ghost-cell glaucoma

↓

TM clogged

In a nutshell, what is the mechanism underlying both hemolytic and ghost-cell glaucomas?

TM clogging→impeded aqueous outflow→increased IOP

Q

Open-angle Glaucoma: *Secondary*

Glaucoma 2ndry to hyphema

↑

Follows ***AC*** bleed

Hemolytic glaucoma

↓

TM clogged with…

?

Ghost-cell glaucoma

↓

TM clogged with…

?

In each condition, what is clogging the TM?

--Hemolytic glaucoma: ***?***

--Ghost-cell glaucoma: ***?***

A

Open-angle Glaucoma: *Secondary*

Glaucoma 2ndry to hyphema

↑

Follows ***AC*** bleed

Hemolytic glaucoma

↓

TM clogged with…
Hgb-laden macrophages

Ghost-cell glaucoma

↓

TM clogged with…
degenerated RBCs

In each condition, what is clogging the TM?
--Hemolytic glaucoma: Hgb-laden macrophages
--Ghost-cell glaucoma: Degenerated RBCs

Open-angle Glaucoma: *Secondary*

Glaucoma 2ndry to hyphema

Follows ***AC*** bleed

Hemolytic glaucoma

TM clogged with…

Hgb-laden macrophages

Ghost-cell glaucoma

TM clogged with…

degenerated RBCs

Make another mental note: While ghost-cell glaucoma involves RBCs as would be expected in a hemorrhage-related condition, in hemolytic glaucoma the culprit is **not** RBCs—it's ***macrophages***

Q

Open-angle Glaucoma: *Secondary*

Glaucoma 2ndry to hyphema

Follows ***AC*** bleed

Hemolytic glaucoma

TM clogged with…

Hgb-laden macrophages

Ghost-cell glaucoma

TM clogged with…
degenerated RBCs

What's up with the macrophages? How do they figure in all this?

A

Open-angle Glaucoma: *Secondary*

Glaucoma 2ndry to hyphema

Follows ***AC*** bleed

Hemolytic glaucoma

TM clogged with…

Hgb-laden macrophages

Ghost-cell glaucoma

TM clogged with…
degenerated RBCs

What's up with the macrophages? How do they figure in all this?
RBCs in a vitreous hemorrhage start to break down after a week or two. The degeneration of these cells attracts macrophages, which consume both the effete RBCs as well as the hemoglobin-related material they release. Heavy-laden with globules of degenerated Hgb and other RBC detritus, these macrophages end up in the AC, and ultimately the angle.

Open-angle Glaucoma: *Secondary*

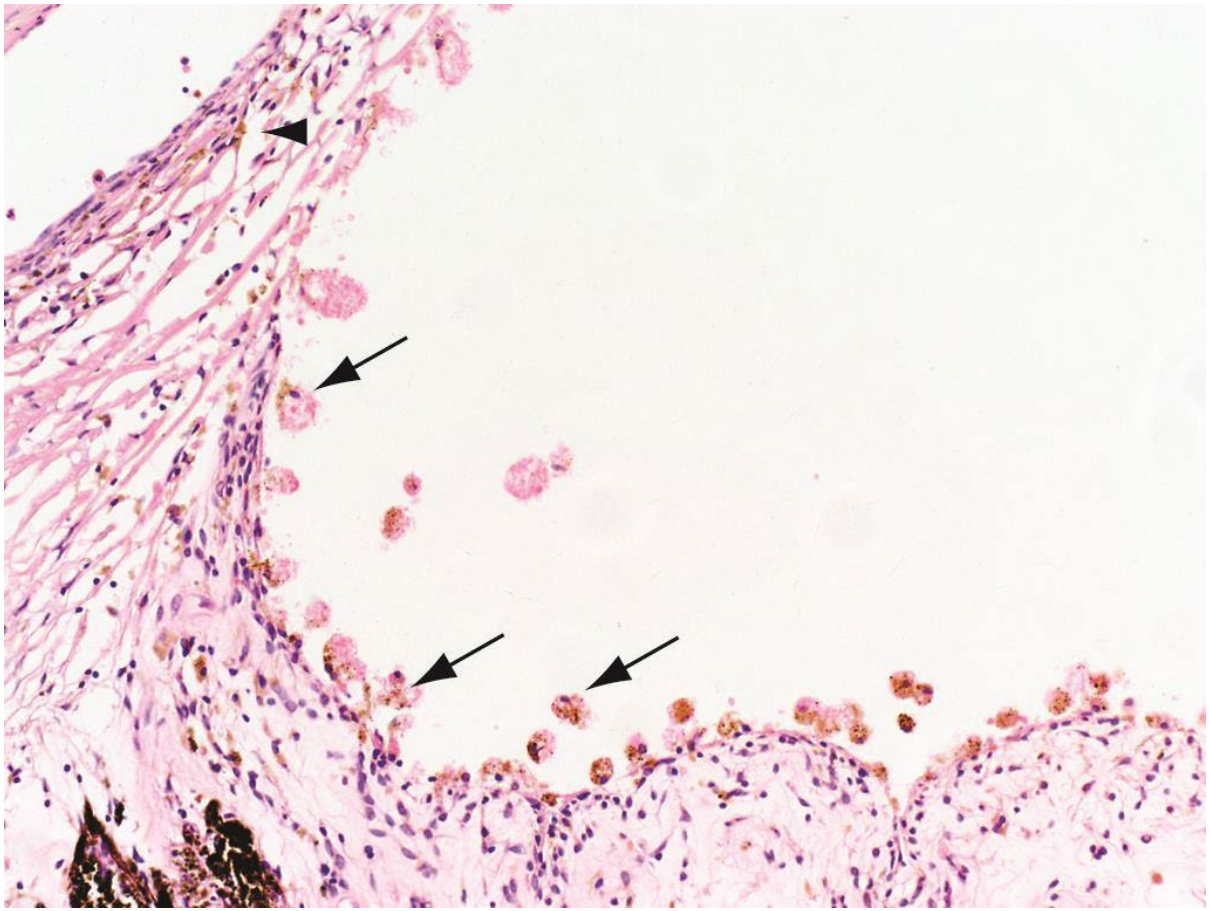

Hemolytic glaucoma. The anterior chamber angle contains macrophages with erythrocytic debris and rust-colored intracytoplasmic material (arrows).

Q

Open-angle Glaucoma: *Secondary*

Glaucoma 2ndry to hyphema

Follows ***AC*** bleed

Hemolytic glaucoma

TM clogged with…

Hgb-laden macrophages

Ghost-cell glaucoma

TM clogged with…
degenerated RBCs

What's up with the macrophages? How do they figure in all this?
RBCs in a vitreous hemorrhage start to break down after a week or two. The degeneration of these cells attract the effete RBCs as well as the hemoglobin-related **globules of degenerated Hgb** and other RBC detri AC, and ultimately the angle.

'Globules of degenerated Hgb' are known by what eponymous name?

A

Open-angle Glaucoma: *Secondary*

Glaucoma 2ndry to hyphema

↑

Follows ***AC*** bleed

Hemolytic glaucoma

↓

TM clogged with…

Hgb-laden macrophages

Ghost-cell glaucoma

↓

TM clogged with…

degenerated RBCs

What's up with the macrophages? How do they figure in all this?

RBCs in a vitreous hemorrhage start to break down after a week or two. The degeneration of these cells attract the effete RBCs as well as the hemoglobin-related **globules of degenerated Hgb** and other RBC detri AC, and ultimately the angle.

'Globules of degenerated Hgb' are known by what eponymous name?

Heinz bodies

Open-angle Glaucoma: *Secondary*

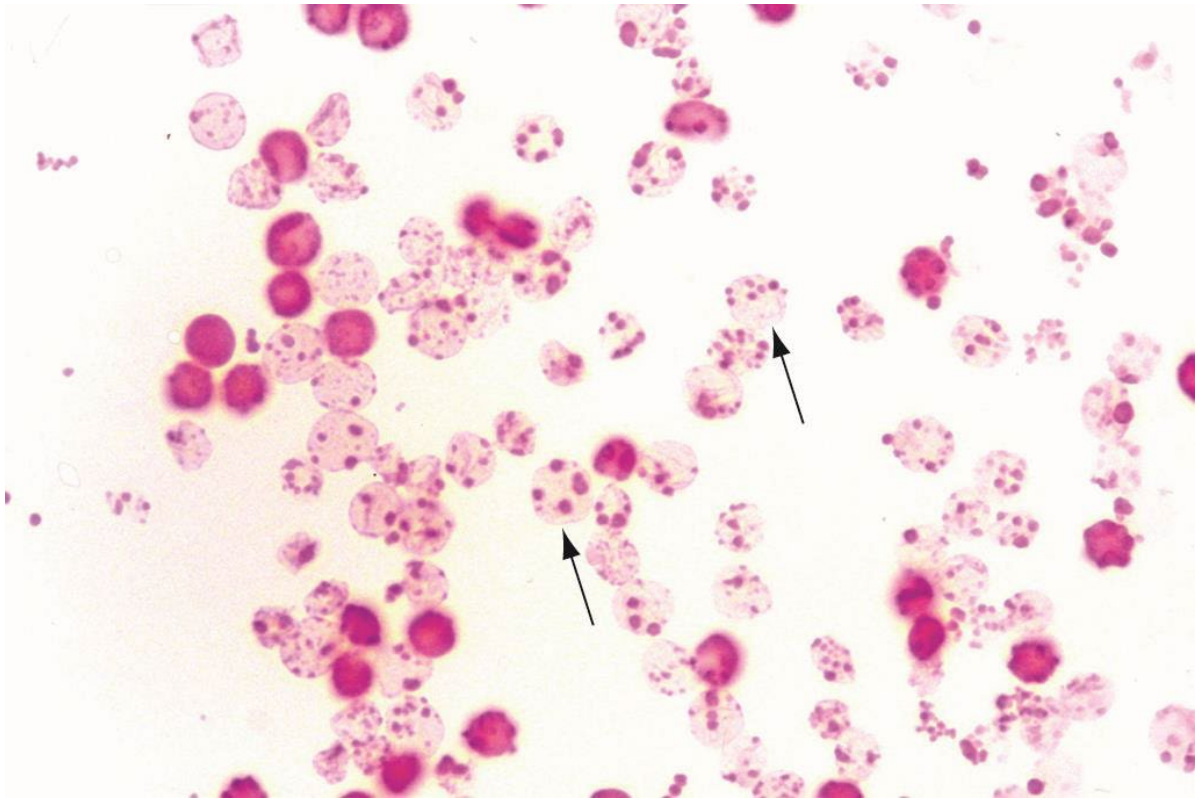

Hemolytic glaucoma. The degenerating hemoglobin is present as small globules known as Heinz bodies (arrows).

Q

Open-angle Glaucoma: *Secondary*

Glaucoma 2ndry to hyphema

Follows ***AC*** bleed

Hemolytic glaucoma

TM clogged with…

Hgb-laden macrophages

Ghost-cell glaucoma

TM clogged with…
degenerated RBCs

What's up with the macrophages? How do they figure in all this?
RBCs in a vitreous hemorrhage start to break down after a week or two. The degeneration of these cells attract the effete RBCs as well as the hemoglobin-related **globules of degenerated Hgb** and other RBC deb AC, and ultimately the angle.

'Globules of degenerated Hgb' are known by what eponymous name?

Heinz bodies

'Heinz bodies'? *Bruh, the BCSC* Glaucoma *book does* **not** *mention Heinz bodies. Why are you including details we don't need to know?*

A

Open-angle Glaucoma: *Secondary*

Glaucoma 2ndry to hyphema

Follows ***AC*** bleed

Hemolytic glaucoma

TM clogged with…

Hgb-laden macrophages

Ghost-cell glaucoma

TM clogged with…
degenerated RBCs

What's up with the macrophages? How do they figure in all this?
RBCs in a vitreous hemorrhage start to break down after a week or two. The degeneration of these cells attract the effete RBCs as well as the hemoglobin-related **globules of degenerated Hgb** and other RBC detr AC, and ultimately the angle.

'Globules of degenerated Hgb' are known by what eponymous name?
Heinz bodies

'Heinz bodies'? *Bruh, the BCSC* Glaucoma *book does* **not** *mention Heinz bodies. Why are you including details we don't need to know?*
I wouldn't do you like that bruh—the *Pathology* book mentions Heinz bodies in *its* discussion of hemolytic- and ghost-cell glaucoma, so it's fair game for the OKAP

Q

Open-angle Glaucoma: *Secondary*

Glaucoma 2ndry to hyphema

Follows ***AC*** bleed

Hemolytic glaucoma

TM clogged with… *macrophages*

Ghost-cell glaucoma

TM clogged with… degenerated RBCs

Finally: 'Macrophages clogging the TM' should bring to mind another form of 2ndry OAG—what is it?

A

Open-angle Glaucoma: *Secondary*

Glaucoma 2ndry to hyphema

Follows ***AC*** bleed

Hemolytic glaucoma

TM clogged with… *macrophages*

Ghost-cell glaucoma

TM clogged with… degenerated RBCs

Finally: 'Macrophages clogging the TM' should bring to mind another form of 2ndry OAG—what is it?

Phacolytic glaucoma (addressed earlier in the slide-set)

Q

Open-angle Glaucoma: *Secondary*

Glaucoma 2ndry to hyphema

↑

Follows ***AC*** bleed

Hemolytic glaucoma

↓

TM clogged with…
Hgb-laden macrophages

Ghost-cell glaucoma

↓

TM clogged with…
degenerated RBCs

Degenerated RBCs pose a special problem for the TM--why?

A

Open-angle Glaucoma: *Secondary*

Glaucoma 2ndry to hyphema

↑

Follows ***AC*** bleed

Hemolytic glaucoma

↓

TM clogged with…
Hgb-laden macrophages

Ghost-cell glaucoma

↓

TM clogged with…
degenerated RBCs

Degenerated RBCs pose a special problem for the TM--why?
Healthy RBCs are very pliable, and gloop through the TM fairly easily. In contrast, degenerated RBCs become spherical and stiff, and do not pass easily through it; instead, they pile up in and clog the angle, preventing aqueous egress.

Q

Open-angle Glaucoma: *Secondary*

Glaucoma 2ndry to hyphema

↑

Follows ***AC*** bleed

Hemolytic glaucoma

↓

TM clogged with…
Hgb-laden macrophages

Ghost-cell glaucoma

↓

TM clogged with…
degenerated RBCs

Degenerated RBCs pose a special problem for the TM--why?
Healthy RBCs are very pliable, and gloop through the TM fairly easily. In contrast, degenerated RBCs become spherical and stiff, and **do not pass easily through it**; instead, they pile up in and clog the angle, preventing aqueous egress.

'RBCs that do not pass easily through the TM'—what other clinical scenario does that sound like?

Q/A

Open-angle Glaucoma: *Secondary*

Glaucoma 2ndry to hyphema

Follows ***AC*** bleed

Hemolytic glaucoma

TM clogged with…
Hgb-laden macrophages

Ghost-cell glaucoma

TM clogged with…
degenerated RBCs

Degenerated RBCs pose a special problem for the TM--why?
Healthy RBCs are very pliable, and gloop through the TM fairly easily. In contrast, degenerated RBCs become spherical and stiff, and **do not pass easily through it**; instead, they pile up in and clog the angle, preventing aqueous egress.

'RBCs that do not pass easily through the TM'—what other clinical scenario does that sound like?
Hyphema in a sickle-cell pt. Recall that the relatively basic v acidic nature of aqueous promotes RBC sickling. Sickled RBCs are significantly stiffer, and thus unable to pass easily through the TM.

A

Open-angle Glaucoma: *Secondary*

Glaucoma 2ndry to hyphema

↑

Follows ***AC*** bleed

Hemolytic glaucoma

↓

TM clogged with…
Hgb-laden macrophages

Ghost-cell glaucoma

↓

TM clogged with…
degenerated RBCs

Degenerated RBCs pose a special problem for the TM--why?
Healthy RBCs are very pliable, and gloop through the TM fairly easily. In contrast, degenerated RBCs become spherical and stiff, and **do not pass easily through it**; instead, they pile up in and clog the angle, preventing aqueous egress.

'RBCs that do not pass easily through the TM'—what other clinical scenario does that sound like?
Hyphema in a sickle-cell pt. Recall that the relatively acidic nature of aqueous promotes RBC sickling. Sickled RBCs are significantly stiffer, and thus unable to pass easily through the TM.

Q

Open-angle Glaucoma: *Secondary*

Glaucoma 2ndry to hyphema

Follows ***AC*** bleed

Hemolytic glaucoma

TM clogged with…
Hgb-laden macrophages

(Classic clinical description)

Ghost-cell glaucoma

TM clogged with…
degenerated RBCs

(Classic clinical description)

What does examination of the AC reveal?

Q/A

Open-angle Glaucoma: *Secondary*

Glaucoma 2ndry to hyphema

↑

Follows ***AC*** bleed

Hemolytic glaucoma

↓

TM clogged with…
Hgb-laden macrophages

↓

color ***cells in AC***

Ghost-cell glaucoma

↓

TM clogged with…
degenerated RBCs

↓

color ***cells in AC***

What does examination of the AC reveal?

A

Open-angle Glaucoma: *Secondary*

Glaucoma 2ndry to hyphema

↑

Follows ***AC*** bleed

Hemolytic glaucoma

↓

TM clogged with…
Hgb-laden macrophages

↓

***Red-tinged* cells in AC**

Ghost-cell glaucoma

↓

TM clogged with…
degenerated RBCs

↓

***Tan-colored* cells in AC**

What does examination of the AC reveal?

Q

Open-angle Glaucoma: *Secondary*

Glaucoma 2ndry to hyphema

↑

Follows ***AC*** bleed

Hemolytic glaucoma

↓

TM clogged with…
Hgb-laden macrophages

↓

***Red-tinged* cells in AC**

Ghost-cell glaucoma

↓

TM clogged with…
degenerated RBCs

↓

***Tan-colored* cells in AC**

Would these 'red-tinged cells' be Hgb-laden macrophages?

A

Open-angle Glaucoma: *Secondary*

Glaucoma 2ndry to hyphema

↑

Follows ***AC*** bleed

Hemolytic glaucoma

↓

TM clogged with…
Hgb-laden macrophages

↓

***Red-tinged* cells in AC**

Ghost-cell glaucoma

↓

TM clogged with…
degenerated RBCs

↓

***Tan-colored* cells in AC**

Would these 'red-tinged cells' be Hgb-laden macrophages?
Indeed they would

Q

Open-angle Glaucoma: *Secondary*

Glaucoma 2ndry to hyphema

Follows ***AC*** bleed

Hemolytic glaucoma

TM clogged with… Hgb-laden macrophages

Red-tinged cells in AC

Ghost-cell glaucoma

TM clogged with… degenerated RBCs

Tan-colored cells in AC

Would these 'tan-colored cells' be the ghost cells after which the condition was named?

A

Open-angle Glaucoma: *Secondary*

Glaucoma 2ndry to hyphema

Follows ***AC*** bleed

Hemolytic glaucoma

TM clogged with… Hgb-laden macrophages

Red-tinged cells in AC

Ghost-cell glaucoma

TM clogged with… degenerated RBCs

***Tan-colored* cells in AC**

Would these 'tan-colored cells' be the ghost cells after which the condition was named?

Indeed they would

Open-angle Glaucoma: *Secondary*

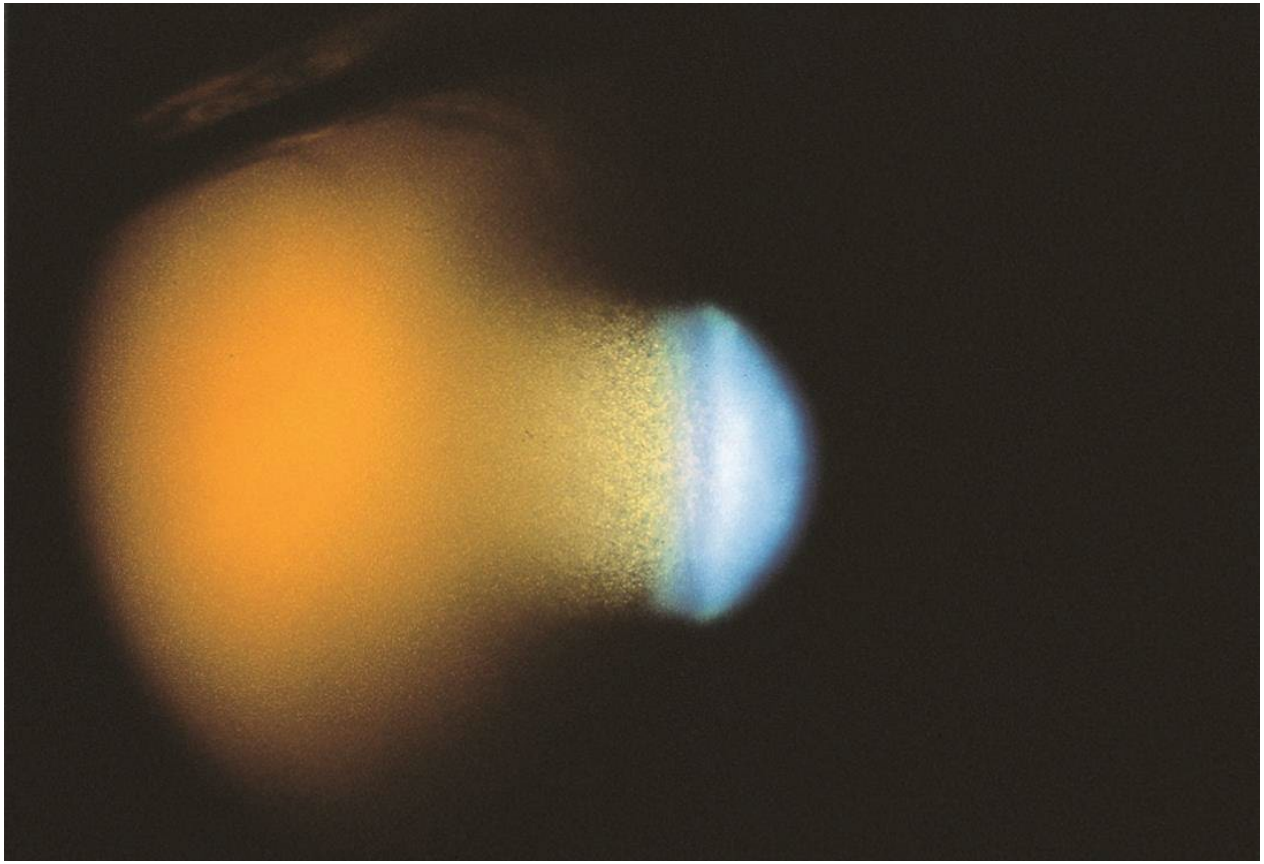

Ghost-cell glaucoma. Copious tan-colored cells in the AC.

Q

Open-angle Glaucoma: *Secondary*

Glaucoma 2ndry to hyphema

↑

Follows ***AC*** bleed

Hemolytic glaucoma

↓

TM clogged with…
Hgb-laden macrophages

↓

Red-tinged cells in AC

Ghost-cell glaucoma

↓

TM clogged with…
degenerated RBCs

↓

Tan-colored cells in AC

Would these 'tan-colored cells' be the ghost cells after which the condition was named?
Indeed they would

What's the origin story of the ghost cells?

A

Open-angle Glaucoma: *Secondary*

Glaucoma 2ndry to hyphema

↑

Follows ***AC*** bleed

Hemolytic glaucoma

↓

TM clogged with…
Hgb-laden macrophages

↓

Red-tinged cells in AC

Ghost-cell glaucoma

↓

TM clogged with…
degenerated RBCs

↓

Tan-colored cells in AC

Would these 'tan-colored cells' be the ghost cells after which the condition was named?
Indeed they would

What's the origin story of the ghost cells?
They are RBCs from the vitreous bleed that have lost their hemoglobin

Q

Open-angle Glaucoma: *Secondary*

Glaucoma 2ndry to hyphema

Follows ***AC*** bleed

Hemolytic glaucoma

TM clogged with… Hgb-laden macrophages

Red-tinged cells in AC

Ghost-cell glaucoma

TM clogged with… degenerated RBCs

***Tan-colored* cells in AC**

Would these 'tan-colored cells' be the ghost cells after which the condition was named?
Indeed they would

How long does it take for RBCs to turn into ghost cells?

What's the origin story of the ghost cells?
They are RBCs from the vitreous bleed that have lost their hemoglobin

A

Open-angle Glaucoma: *Secondary*

Glaucoma 2ndry to hyphema

↑

Follows ***AC*** bleed

Hemolytic glaucoma

↓

TM clogged with…
Hgb-laden macrophages

↓

Red-tinged cells in AC

Ghost-cell glaucoma

↓

TM clogged with…
degenerated RBCs

↓

Tan-colored cells in AC

Would these 'tan-colored cells' be the ghost cells after which the condition was named?
Indeed they would

How long does it take for RBCs to turn into ghost cells?
1-3 months

What's the origin story of the ghost cells?
They are RBCs from the vitreous bleed that have lost their hemoglobin

Q

Open-angle Glaucoma: *Secondary*

Glaucoma 2ndry to hyphema

↑

Follows ***AC*** bleed

Hemolytic glaucoma

↓

TM clogged with…
Hgb-laden macrophages

↓

***Red-tinged* cells in AC**

Ghost-cell glaucoma

↓

TM clogged with…
degenerated RBCs

↓

***Tan-colored* cells in AC**

↓

(Classic clinical description)

What does examination of the vitreous cavity reveal?

Q/A

Open-angle Glaucoma: *Secondary*

Glaucoma 2ndry to hyphema

↑

Follows ***AC*** bleed

Hemolytic glaucoma

↓

TM clogged with…
Hgb-laden macrophages

↓

***Red-tinged* cells in AC**

Ghost-cell glaucoma

↓

TM clogged with…
degenerated RBCs

↓

***Tan-colored* cells in AC**

↓

color ***hemorrhage in the vitreous***

What does examination of the vitreous cavity reveal?

A

Open-angle Glaucoma: *Secondary*

Glaucoma 2ndry to hyphema

↑

Follows ***AC*** bleed

Hemolytic glaucoma

↓

TM clogged with…
Hgb-laden macrophages

↓

***Red-tinged* cells in AC**

Ghost-cell glaucoma

↓

TM clogged with…
degenerated RBCs

↓

***Tan-colored* cells in AC**

↓

***Khaki-colored* hemorrhage in the vitreous**

What does examination of the vitreous cavity reveal?

Q

Open-angle Glaucoma: *Secondary*

Glaucoma 2ndry to hyphema

Follows ***AC*** bleed

Hemolytic glaucoma

Ghost-cell glaucoma

Do hemolytic- and ghost-cell glaucoma resolve spontaneously?

Khaki-colored hemorrhage in the vitreous

A

Open-angle Glaucoma: *Secondary*

Glaucoma 2ndry to hyphema

Follows ***AC*** bleed

Hemolytic glaucoma

Ghost-cell glaucoma

Do hemolytic- and ghost-cell glaucoma resolve spontaneously?
Usually, once the instigating vitreous hemorrhage has cleared

Khaki-colored hemorrhage in the vitreous

Q

Open-angle Glaucoma: *Secondary*

Glaucoma 2ndry to hyphema

Follows ***AC*** bleed

Hemolytic glaucoma

Ghost-cell glaucoma

Do hemolytic- and ghost-cell glaucoma resolve spontaneously?
Usually, once the instigating vitreous hemorrhage has cleared

In the interim, how should the IOP be managed?

Khaki-colored hemorrhage in the vitreous

A

Open-angle Glaucoma: *Secondary*

Glaucoma 2ndry to hyphema

Follows ***AC*** bleed

Hemolytic glaucoma

Ghost-cell glaucoma

Do hemolytic- and ghost-cell glaucoma resolve spontaneously?
Usually, once the instigating vitreous hemorrhage has cleared

In the interim, how should the IOP be managed?
With aqueous suppressants if possible

Khaki-colored hemorrhage in the vitreous

Q

Open-angle Glaucoma: *Secondary*

Glaucoma 2ndry to hyphema

Follows ***AC*** bleed

Hemolytic glaucoma

Ghost-cell glaucoma

Do hemolytic- and ghost-cell glaucoma resolve spontaneously?
Usually, once the instigating vitreous hemorrhage has cleared

In the interim, how should the IOP be managed?
With aqueous suppressants if possible

If medical management fails, what is the next step?

Khaki-colored hemorrhage in the vitreous

A

Open-angle Glaucoma: *Secondary*

Glaucoma 2ndry to hyphema

Follows ***AC*** bleed

Hemolytic glaucoma

Ghost-cell glaucoma

Do hemolytic- and ghost-cell glaucoma resolve spontaneously?
Usually, once the instigating vitreous hemorrhage has cleared

In the interim, how should the IOP be managed?
With aqueous suppressants if possible

If medical management fails, what is the next step?
AC washout

Khaki-colored hemorrhage in the vitreous

Q

Open-angle Glaucoma: *Secondary*

Glaucoma 2ndry to hyphema

Follows ***AC*** bleed

Hemolytic glaucoma

Ghost-cell glaucoma

Do hemolytic- and ghost-cell glaucoma resolve spontaneously?
Usually, once the instigating vitreous hemorrhage has cleared

In the interim, how should the IOP be managed?
With aqueous suppressants if possible

If medical management fails, what is the next step?
AC washout

And if the AC washout fails?

Khaki-colored hemorrhage in the vitreous

A

Open-angle Glaucoma: *Secondary*

Glaucoma 2ndry to hyphema

Follows ***AC*** bleed

Hemolytic glaucoma

Ghost-cell glaucoma

Do hemolytic- and ghost-cell glaucoma resolve spontaneously?
Usually, once the instigating vitreous hemorrhage has cleared

In the interim, how should the IOP be managed?
With aqueous suppressants if possible

If medical management fails, what is the next step?
AC washout

And if the AC washout fails?
PPV (if the hemorrhage is persistent) vs filtering surgery should be considered

Khaki-colored hemorrhage in the vitreous

Q

Open-angle Glaucoma: *Secondary*

Schwartz syndrome → Follows…

Hemolytic glaucoma, Ghost-cell glaucoma → Follow vitreous bleed

Changing gears slightly…There is another form of secondary OAG called Schwartz syndrome *that, like hemolytic- and ghost-cell glaucoma, follows a posterior-segment event—but* not *a bleed. What event does it follow?*

A

Open-angle Glaucoma: *Secondary*

Schwartz syndrome

↓

Follows…***RRD***

Hemolytic glaucoma Ghost-cell glaucoma

↔

Follow vitreous bleed

Changing gears slightly…There is another form of secondary OAG called Schwartz syndrome *that, like hemolytic- and ghost-cell glaucoma, follows a posterior-segment event—but* not *a bleed. What event does it follow?*
Rhegmatogenous retinal detachment (RRD)

Q

Open-angle Glaucoma: *Secondary*

Schwartz syndrome

Follows…***RRD***

Hemolytic glaucoma

Ghost-cell glaucoma

Follow vitreous bleed

Changing gears slightly…There is another form of secondary OAG called Schwartz syndrome that, like hemolytic- and ghost-cell glaucoma, follows a posterior-segment event—but **not** *a bleed. What event does it follow?*

Rhegmatogenous retinal detachment (RRD)

Huh? I thought RRD was associated with **reduced** *IOP. What gives?*

A

Open-angle Glaucoma: *Secondary*

Schwartz syndrome

Follows…***RRD***

Hemolytic glaucoma

Ghost-cell glaucoma

Follow vitreous bleed

Changing gears slightly…There is another form of secondary OAG called Schwartz syndrome *that, like hemolytic- and ghost-cell glaucoma, follows a posterior-segment event—but* **not** *a bleed. What event does it follow?*

Rhegmatogenous retinal detachment (RRD)

Huh? I thought RRD was associated with **reduced** *IOP. What gives?*
Acute RRD is indeed associated with reduced IOP. Schwartz syndrome is associated with **chronic** RRD.

Q

Open-angle Glaucoma: *Secondary*

Schwartz syndrome

Follows…***RRD***

Hemolytic glaucoma

Ghost-cell glaucoma

Follow vitreous bleed

What is the mechanism of reduced IOP in acute RRD?

lary OAG called
aucoma, follows a
es it follow?

Huh? I thought RRD was associated with ***reduced*** *IOP. What gives?*
Acute RRD is indeed associated with reduced IOP. Schwartz syndrome is associated with **chronic** RRD.

A

Open-angle Glaucoma: *Secondary*

Schwartz syndrome

Follows…***RRD***

Hemolytic glaucoma

Ghost-cell glaucoma

Follow vitreous bleed

What is the mechanism of reduced IOP in acute RRD?
Recall that one function of the RPE is to deturgesce the subretinal space by actively pumping fluid out of it. RRD allows intraocular fluid to pass into the subretinal space, where the RPE attempts to remove it.

lary OAG called
aucoma, follows a
es it follow?

Huh? I thought RRD was associated with ***reduced*** *IOP. What gives?*
Acute RRD is indeed associated with reduced IOP. Schwartz syndrome is associated with **chronic** RRD.

A

Open-angle Glaucoma: *Secondary*

Schwartz syndrome

Follows…***RRD***

Hemolytic glaucoma

Ghost-cell glaucoma

Follow vitreous bleed

What is the mechanism of reduced IOP in acute RRD?
Recall that one function of the RPE is to deturgesce the subretinal space by actively pumping fluid out of it. RRD allows intraocular fluid to pass into the subretinal space, where the RPE attempts to remove it. If a significant enough portion of this fluid is removed, IOP will go down.

lary OAG called
aucoma, follows a
es it follow?

Huh? I thought RRD was associated with ***reduced*** *IOP. What gives?*
Acute RRD is indeed associated with reduced IOP. Schwartz syndrome is associated with **chronic** RRD.

Open-angle Glaucoma: *Secondary*

Schwartz syndrome

Hemolytic glaucoma → TM clogged

Ghost-cell glaucoma → TM clogged

In both hemolytic and ghost-cell glaucomas, increased IOP results from clogging of the TM that impedes aqueous egress.

Changing gears slightly…There is an [illegible] *that, like hemolytic- and ghost-cell glaucoma, follows a posterior-segment event—but* **not** *a bleed. What event does it follow?*

Rhegmatogenous retinal detachment (RRD)

Q

Open-angle Glaucoma: *Secondary*

Schwartz syndrome	Hemolytic glaucoma	Ghost-cell glaucoma
↓	↓	↓
?	TM clogged	TM clogged

What is the mechanism of IOP elevation in Schwartz syndrome?

In both hemolytic and ghost-cell glaucomas, increased IOP results from clogging of the TM that impedes aqueous egress.

Changing gears slightly: There is another form of secondary OAG called Schwartz syndrome *that, like hemolytic- and ghost-cell glaucoma, follows a posterior-segment event—but* **not** *a bleed. What event does it follow?*

Rhegmatogenous retinal detachment (RRD)

A

Open-angle Glaucoma: *Secondary*

Schwartz syndrome	Hemolytic glaucoma	Ghost-cell glaucoma
↓	↓	↓
TM clogged	TM clogged	TM clogged

What is the mechanism of IOP elevation in Schwartz syndrome?
The same thing—TM clogging

In both hemolytic and ghost-cell glaucomas, increased IOP results from clogging of the TM that impedes aqueous egress.

Changing gears slightly: There is another form of secondary OAG called Schwartz syndrome *that, like hemolytic- and ghost-cell glaucoma, follows a posterior-segment event—but* **not** *a bleed. What event does it follow?*
Rhegmatogenous retinal detachment (RRD)

Open-angle Glaucoma: *Secondary*

Schwartz syndrome	Hemolytic glaucoma	Ghost-cell glaucoma
↓	↓	↓
TM clogged	TM clogged with… Hgb-laden macrophages	TM clogged with… degenerated RBCs

In hemolytic glaucoma, the TM is clogged with macrophages; in ghost-cell glaucoma, it's degenerated RBCs.

Changing gears slightly…There is a
Schwartz syndrome *that, like hemoly*
posterior-segment event—but **not** *a*
Rhegmatogenous retinal detachment (RRD)

Q

Open-angle Glaucoma: *Secondary*

Schwartz syndrome	Hemolytic glaucoma	Ghost-cell glaucoma
↓	↓	↓
TM clogged with…	TM clogged with…	TM clogged with…
?	Hgb-laden macrophages	degenerated RBCs

What is clogging the TM in Schwartz syndrome?

In hemolytic glaucoma, the TM is clogged with macrophages; in ghost-cell glaucoma, it's degenerated RBCs.

here is ar
e hemoly
ut **not** *a*

Rhegmatogenous retinal detachment (RRD)

A

Open-angle Glaucoma: *Secondary*

Schwartz syndrome	Hemolytic glaucoma	Ghost-cell glaucoma
↓	↓	↓
TM clogged with…	TM clogged with…	TM clogged with…
PR outer segments	Hgb-laden macrophages	degenerated RBCs

What is clogging the TM in Schwartz syndrome?
Photoreceptor outer segments

In hemolytic glaucoma, the TM is clogged with macrophages; in ghost-cell glaucoma, it's degenerated RBCs.

here is ar
e hemoly
ut **not** *a*

Rhegmatogenous retinal detachment (RRD)

Open-angle Glaucoma: *Secondary*

Schwartz syndrome

↓

TM clogged with…
PR outer segments

What is clogging the TM in Schwartz syndrome?
Photoreceptor outer segments

Hemolytic glaucoma

↓

TM clogged with…
Hgb-laden macrophages

Ghost-cell glaucoma

↓

TM clogged with…
degenerated RBCs

In hemolytic glaucoma, the TM is clogged with macrophages; in ghost-cell glaucoma, it's degenerated RBCs.

Rhegmatogenous retinal detachment (RRD)

To sum it up: In Schwartz syndrome, chronic RRD allows enough time for liberated PR outer segs to migrate into the AC, where their accumulation in the angle ends up clogging the TM and elevating IOP.

Q

Open-angle Glaucoma: *Secondary*

Schwartz syndrome

↓

TM clogged with…
PR outer segments

What is clogging the TM in Schwartz syndrome?
Photoreceptor outer segments

Hemolytic glaucoma

↓

TM clogged with…
Hgb-laden macrophages

Ghost-cell glaucoma

↓

TM clogged with…
degenerated RBCs

is ar
emoly
ot a

In hemolytic glaucoma, the TM is clogged with macrophages; in ghost-cell glaucoma, it's degenerated RBCs.

Rhegmatogenous retinal detachment (RRD)

To sum it up: In Schwartz syndrome, chronic RRD allows enough time for liberated ***PR outer segs to migrate into the AC****, where their accumulation in the angle ends up clogging the TM and elevating IOP.*

All these PR outer segs floating around the AC—can they be mistaken for inflammatory cells?

A

Open-angle Glaucoma: *Secondary*

Schwartz syndrome

↓

TM clogged with…
PR outer segments

What is clogging the TM in Schwartz syndrome?
Photoreceptor outer segments

Hemolytic glaucoma

↓

TM clogged with…
Hgb-laden macrophages

Ghost-cell glaucoma

↓

TM clogged with…
degenerated RBCs

In hemolytic glaucoma, the TM is clogged with macrophages; in ghost-cell glaucoma, it's degenerated RBCs.

Rhegmatogenous retinal detachment (RRD)

To sum it up: In Schwartz syndrome, chronic RRD allows enough time for liberated ***PR outer segs to migrate into the AC****, where their accumulation in the angle ends up clogging the TM and elevating IOP.*

All these PR outer segs floating around the AC—can they be mistaken for inflammatory cells?
Yes, uveitic glaucoma is a common misdiagnosis in Schwartz syndrome

Q

Open-angle Glaucoma: *Secondary*

Schwartz syndrome	Hemolytic glaucoma	Ghost-cell glaucoma
↓	↓	↓
TM clogged with…	TM clogged with…	TM clogged with…
PR outer segments	Hgb-laden macrophages	degenerated RBCs

Changing gears slightly…There is another form of secondary OAG called Schwartz syndrome *that, like hemolytic- and ghost-cell glaucoma, follows a posterior-segment event—but* **not** *a bleed. What event does it follow?*
Rhegmatogenous retinal detachment (RRD)

What's the best way to manage Schwartz syndrome?

A

Open-angle Glaucoma: *Secondary*

Schwartz syndrome	Hemolytic glaucoma	Ghost-cell glaucoma
↓	↓	↓
TM clogged with…	TM clogged with…	TM clogged with…
PR outer segments	Hgb-laden macrophages	degenerated RBCs

Changing gears slightly…There is another form of secondary OAG called Schwartz syndrome *that, like hemolytic- and ghost-cell glaucoma, follows a posterior-segment event—but* **not** *a bleed. What event does it follow?*
Rhegmatogenous retinal detachment (RRD)

What's the best way to manage Schwartz syndrome?
Repair the RRD

Open-angle Glaucoma: *Secondary*

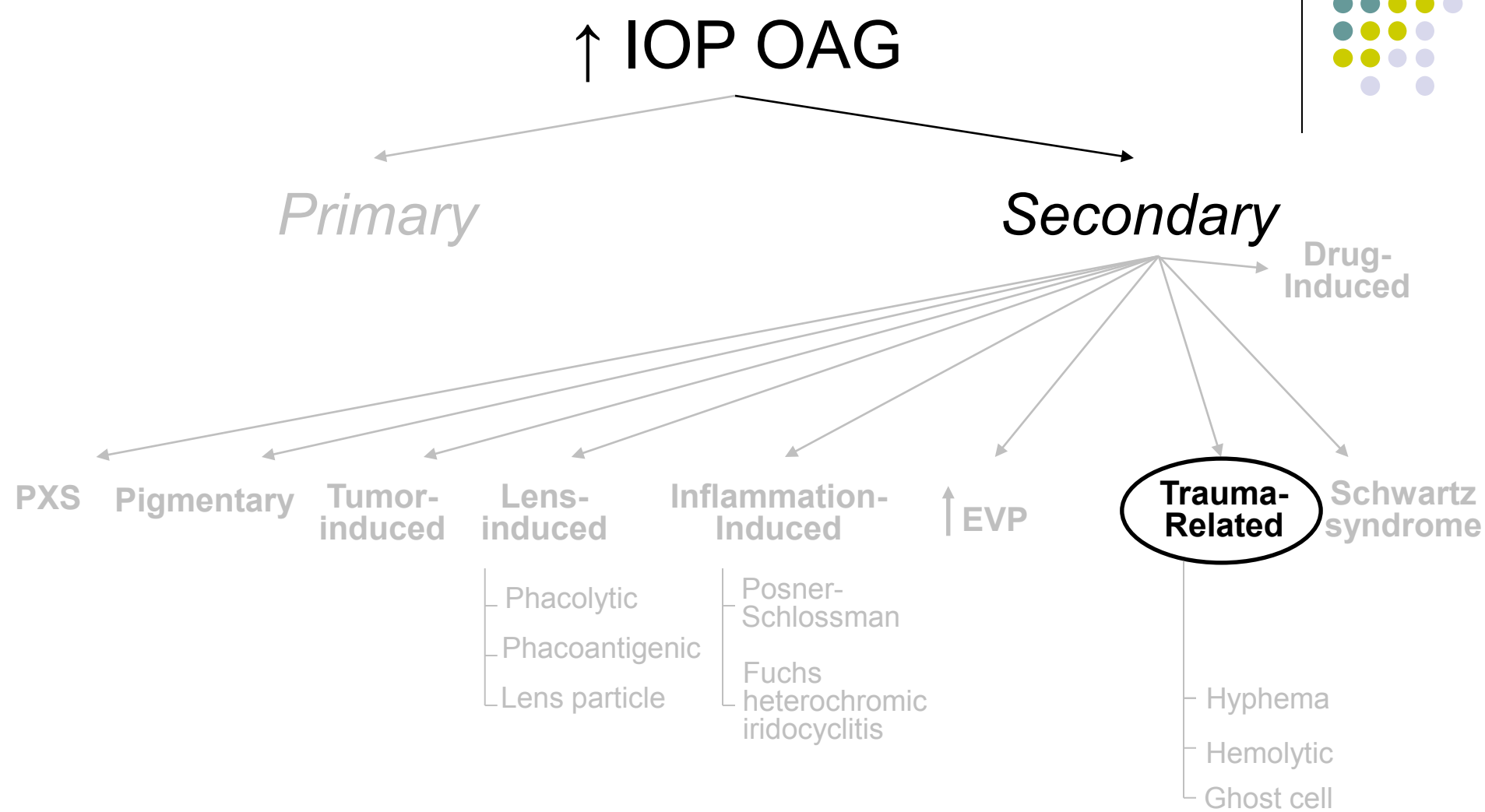

Next let's take a look at other trauma-related causes of secondary OAG

Q

Open-angle Glaucoma: *Secondary*

- Three types of post-trauma angle changes:

1) one type of angle change

2) another type of angle change

3) a third type of angle change

A

Open-angle Glaucoma: *Secondary*

- Three types of post-trauma angle changes:

  1) Angle recession

  2) Cyclodialysis cleft

  3) Iridodialysis

Q

Open-angle Glaucoma: *Secondary*

- Three types of post-trauma angle changes:

1) Angle recession

- Tear between orientation *and* orientation CB fibers *(CB = ciliary body)*

2) Cyclodialysis cleft

3) Iridodialysis

A

Open-angle Glaucoma: *Secondary*

- Three types of post-trauma angle changes:

1) Angle recession

- Tear between longitudinal and circular CB fibers

2) Cyclodialysis cleft

3) Iridodialysis

Q

Open-angle Glaucoma: *Secondary*

- Three types of post-trauma angle changes:

1) Angle recession

- Tear between longitudinal and circular CB fibers
- Classic description on gonio: adjective CBB *(CBB = ciliary body band)*

2) Cyclodialysis cleft

3) Iridodialysis

A

Open-angle Glaucoma: *Secondary*

- Three types of post-trauma angle changes:

1) Angle recession

- Tear between longitudinal and circular CB fibers
- Classic description on gonio: Wide CBB

2) Cyclodialysis cleft

3) Iridodialysis

Open-angle Glaucoma: *Secondary*

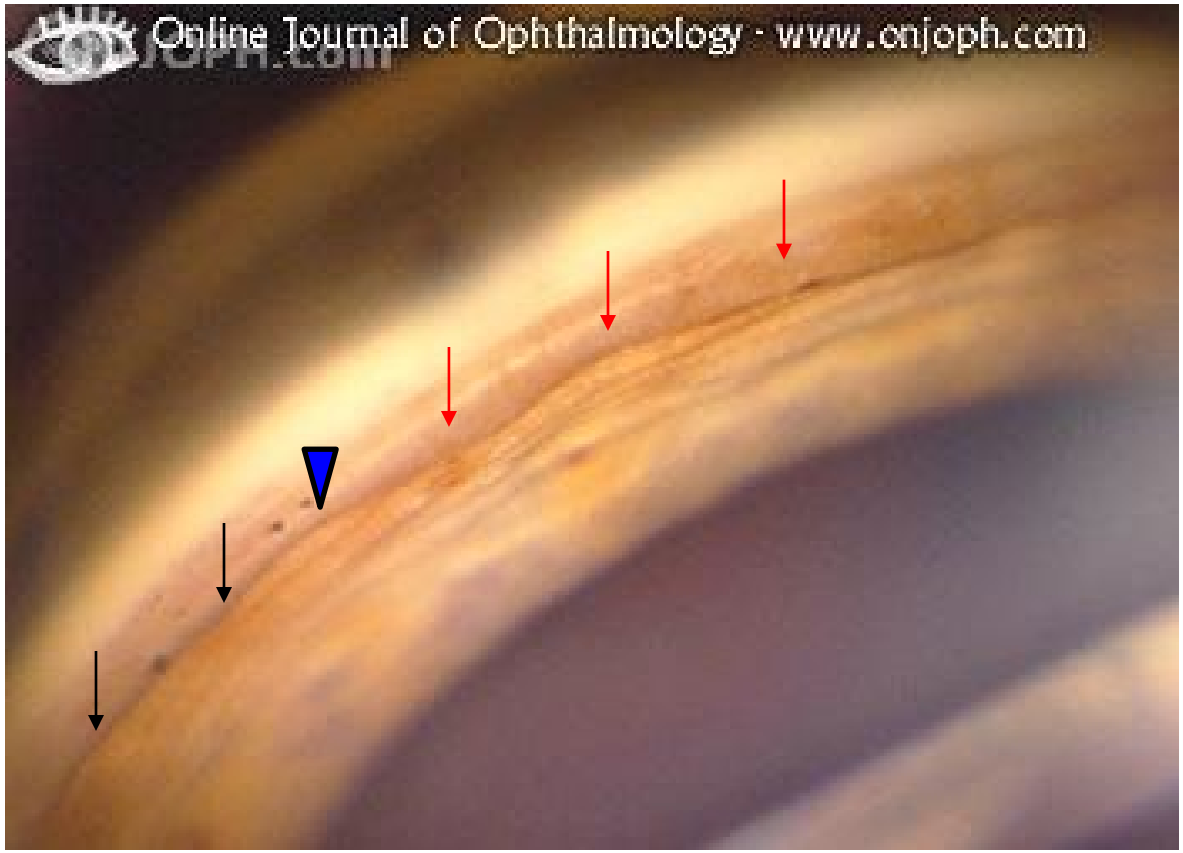

Angle recession. Note the portion of normal angle with narrow CBB (black arrows), the point at which the recession starts (arrowhead), and the subsequent segment of recessed angle with widened CBB (red arrows)

Q

Open-angle Glaucoma: *Secondary*

- Three types of post-trauma angle changes:

1) Angle recession

- Tear between longitudinal and circular CB fibers
- Classic description on gonio: Wide CBB

2) Cyclodialysis cleft

- structure separates from structure

3) Iridodialysis

A

Open-angle Glaucoma: *Secondary*

- Three types of post-trauma angle changes:

1) Angle recession

- Tear between longitudinal and circular CB fibers
- Classic description on gonio: Wide CBB

2) Cyclodialysis cleft

- CB separates from SS *(SS = scleral spur)*

3) Iridodialysis

Q

Open-angle Glaucoma: *Secondary*

- Three types of post-trauma angle changes:

1) Angle recession

- Tear between longitudinal and circular CB fibers
- Classic description on gonio: Wide CBB

2) Cyclodialysis cleft

- CB separates from SS
- Classic description on gonio: adjective SS

3) Iridodialysis

A

Open-angle Glaucoma: *Secondary*

- Three types of post-trauma angle changes:

  1) *Angle recession*
     - Tear between longitudinal and circular CB fibers
     - Classic description on gonio: Wide CBB

  2) *Cyclodialysis cleft*
     - CB separates from SS
     - Classic description on gonio: Glistening SS

  3) *Iridodialysis*

Open-angle Glaucoma: *Secondary*

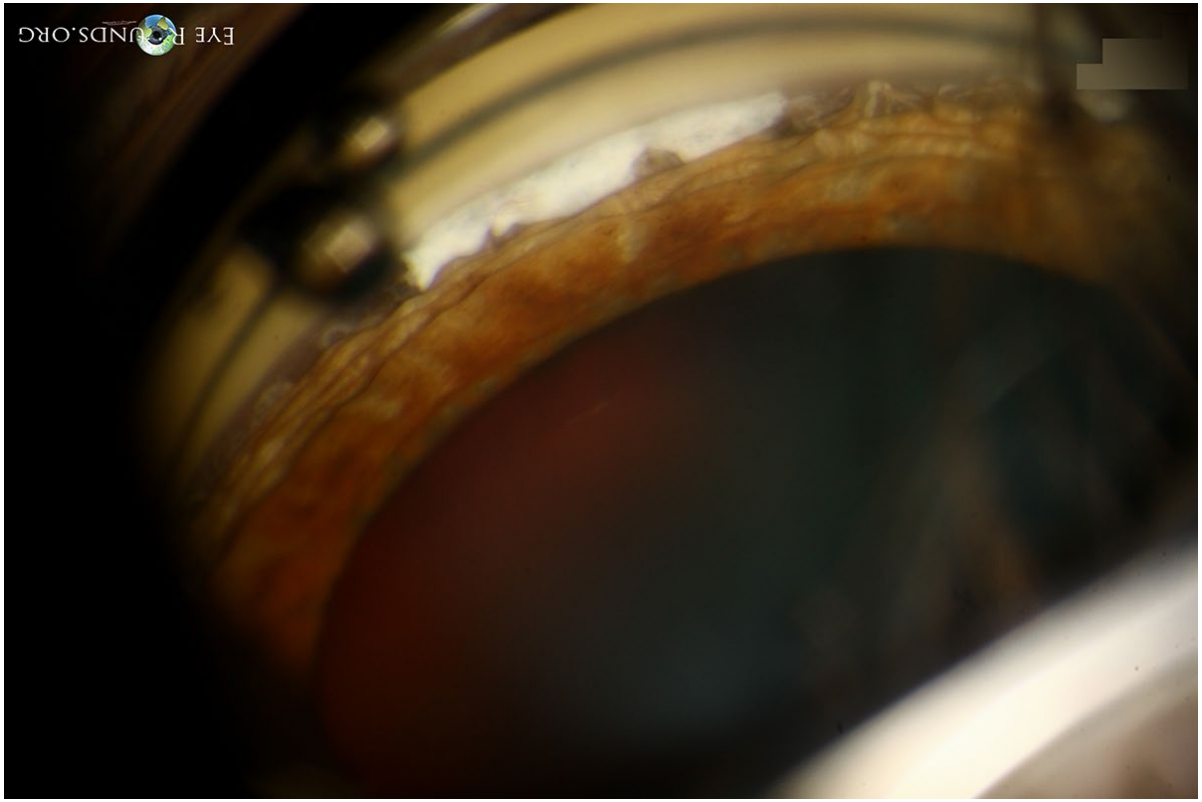

Cyclodialysis cleft. Racquetball vs eye. The broad white band is the cleft. Note the presence of angle recession on either side of the cleft.

Q

Open-angle Glaucoma: *Secondary*

- Three types of post-trauma angle changes:

1) Angle recession

- Tear between longitudinal and circular CB fibers
- Classic description on gonio: Wide CBB

2) Cyclodialysis cleft

- CB separates from SS
- Classic description on gonio: Glistening SS

3) Iridodialysis

- Tear at structure

A

Open-angle Glaucoma: *Secondary*

- Three types of post-trauma angle changes:

1) Angle recession

- Tear between longitudinal and circular CB fibers
- Classic description on gonio: Wide CBB

2) Cyclodialysis cleft

- CB separates from SS
- Classic description on gonio: Glistening SS

3) Iridodialysis

- Tear at iris root

Open-angle Glaucoma: *Secondary*

Iridodialysis

Q

Open-angle Glaucoma: *Secondary*

1) Angle recession glaucoma?

2) Cyclodialysis cleft glaucoma?

3) Iridodialysis glaucoma?

All three can be associated with the subsequent development of glaucoma, but for which of them is the association especially strong?

A

Open-angle Glaucoma: *Secondary*

Angle recession glaucoma

All three can be associated with the subsequent development of glaucoma, but for which of them is the association especially strong?
Angle recession

Q

Open-angle Glaucoma: *Secondary*

Angle recession glaucoma

What is the temporal relationship between the inciting trauma and the subsequent development of angle-recession glaucoma?

A

Open-angle Glaucoma: *Secondary*

Angle recession glaucoma

What is the temporal relationship between the inciting trauma and the subsequent development of angle-recession glaucoma?

It can be immediate, or delayed by months to many years

Q

Open-angle Glaucoma: *Secondary*

Angle recession glaucoma

What is the temporal relationship between the inciting trauma and the subsequent development of angle-recession glaucoma?

It can be immediate, or delayed by months to many years

What is the classic presentation?

A

Open-angle Glaucoma: *Secondary*

Angle recession glaucoma

What is the temporal relationship between the inciting trauma and the subsequent development of angle-recession glaucoma?
It can be immediate, or delayed by months to many years

What is the classic presentation?
A pt with what seems to be unilateral POAG

Q

Open-angle Glaucoma: *Secondary*

Angle recession glaucoma

What is the temporal relationship between the inciting trauma and the subsequent development of angle-recession glaucoma?
It can be immediate, or delayed by months to many years

What is the classic presentation?
A pt with what seems to be unilateral POAG

Is there a correlation between the extent of angle recession and the risk of developing glaucoma?

A

Open-angle Glaucoma: *Secondary*

Angle recession glaucoma

What is the temporal relationship between the inciting trauma and the subsequent development of angle-recession glaucoma?
It can be immediate, or delayed by months to many years

What is the classic presentation?
A pt with what seems to be unilateral POAG

Is there a correlation between the extent of angle recession and the risk of developing glaucoma?
Yes

Q

Open-angle Glaucoma: *Secondary*

Angle recession glaucoma

What is the temporal relationship between the inciting trauma and the subsequent development of angle-recession glaucoma?
It can be immediate, or delayed by months to many years

What is the classic presentation?
A pt with what seems to be unilateral POAG

Is there a correlation between the extent of angle recession and the risk of developing glaucoma?
Yes

Is there a correlation between angle-recession glaucoma in one eye and the development of elevated IOP in the fellow *eye?*

Q/A

Open-angle Glaucoma: *Secondary*

Angle recession glaucoma

What is the temporal relationship between the inciting trauma and the subsequent development of angle-recession glaucoma?
It can be immediate, or delayed by months to many years

What is the classic presentation?
A pt with what seems to be unilateral POAG

Is there a correlation between the extent of angle recession and the risk of developing glaucoma?
Yes

Is there a correlation between angle-recession glaucoma in one eye and the development of elevated IOP in the fellow *eye?*
Yes—it will occur in as many as % of fellow eyes

A

Open-angle Glaucoma: *Secondary*

Angle recession glaucoma

What is the temporal relationship between the inciting trauma and the subsequent development of angle-recession glaucoma?
It can be immediate, or delayed by months to many years

What is the classic presentation?
A pt with what seems to be unilateral POAG

Is there a correlation between the extent of angle recession and the risk of developing glaucoma?
Yes

Is there a correlation between angle-recession glaucoma in one eye and the development of elevated IOP in the fellow *eye?*
Yes—it will occur in as many as half of fellow eyes

Q

Open-angle Glaucoma: *Secondary*

Angle recession glaucoma

What is the temporal relationship between the inciting trauma and the subsequent development of angle-recession glaucoma?
It can be immediate, or delayed by months to many years

What is the classic presentation?
A pt with what seems to be unilateral POAG

Is there a correlation between the extent of angle recession and the risk of developing glaucoma?
Yes

Is there a correlation between angle-recession glaucoma in one eye and the development of elevated IOP in the fellow *eye?*
Yes—**it will occur in as many as half of fellow eyes**

What does this fact suggest about eyes with angle-recession glaucoma?

A

Open-angle Glaucoma: *Secondary*

Angle recession glaucoma

What is the temporal relationship between the inciting trauma and the subsequent development of angle-recession glaucoma?
It can be immediate, or delayed by months to many years

What is the classic presentation?
A pt with what seems to be unilateral POAG

Is there a correlation between the extent of angle recession and the risk of developing glaucoma?
Yes

Is there a correlation between angle-recession glaucoma in one eye and the development of elevated IOP in the fellow *eye?*
Yes—**it will occur in as many as half of fellow eyes**

What does this fact suggest about eyes with angle-recession glaucoma?
It suggests they live in the head of a person who was predisposed to develop glaucoma in the first place

Q

Open-angle Glaucoma: *Secondary*

Angle recession glaucoma

What is the temporal relationship between the inciting trauma and the subsequent development of angle-recession glaucoma?
It can be immediate, or delayed by months to many years

What is the classic presentation?
A pt with what seems to be unilateral POAG

Is there a correlation between the extent of angle recession and the risk of developing glaucoma?
Yes

Is there a correlation between angle-recession glaucoma in one eye and the development of elevated IOP in the fellow *eye?*
Yes—it will occur in as many as half of fellow eyes

How should angle-recession glaucoma be managed?

A

Open-angle Glaucoma: *Secondary*

Angle recession glaucoma

What is the temporal relationship between the inciting trauma and the subsequent development of angle-recession glaucoma?
It can be immediate, or delayed by months to many years

What is the classic presentation?
A pt with what seems to be unilateral POAG

Is there a correlation between the extent of angle recession and the risk of developing glaucoma?
Yes

Is there a correlation between angle-recession glaucoma in one eye and the development of elevated IOP in the fellow *eye?*
Yes—it will occur in as many as half of fellow eyes

How should angle-recession glaucoma be managed?
With the standard complement of topical hypotensives

Q

Open-angle Glaucoma: *Secondary*

Angle recession glaucoma

What is the temporal relationship between the inciting trauma and the subsequent development of angle-recession glaucoma?
It can be immediate, or delayed by months to many years

What is the classic presentation?
A pt with what seems to be unilateral POAG

Is there a correlation between the extent of angle recession and the risk of developing glaucoma?
Yes

Is there a correlation between angle-recessi
development of elevated IOP in the fellow ey
Yes—it will occur in as many as half of fello

What about SLT?

How should angle-recession glaucoma be managed?
With the standard complement of topical hypotensives, or SLT?

A

Open-angle Glaucoma: *Secondary*

Angle recession glaucoma

What is the temporal relationship between the inciting trauma and the subsequent development of angle-recession glaucoma?
It can be immediate, or delayed by months to many years

What is the classic presentation?
A pt with what seems to be unilateral POAG

Is there a correlation between the extent of angle recession and the risk of developing glaucoma?
Yes

Is there a correlation between angle-recessi
development of elevated IOP in the fellow ey
Yes—it will occur in as many as half of fello

What about SLT?
While not contraindicated, it is of limited usefulness in angle-recession eyes

How should angle-recession glaucoma be managed?
With the standard complement of topical hypotensives, or SLT? Nah

Open-angle Glaucoma: *Secondary*

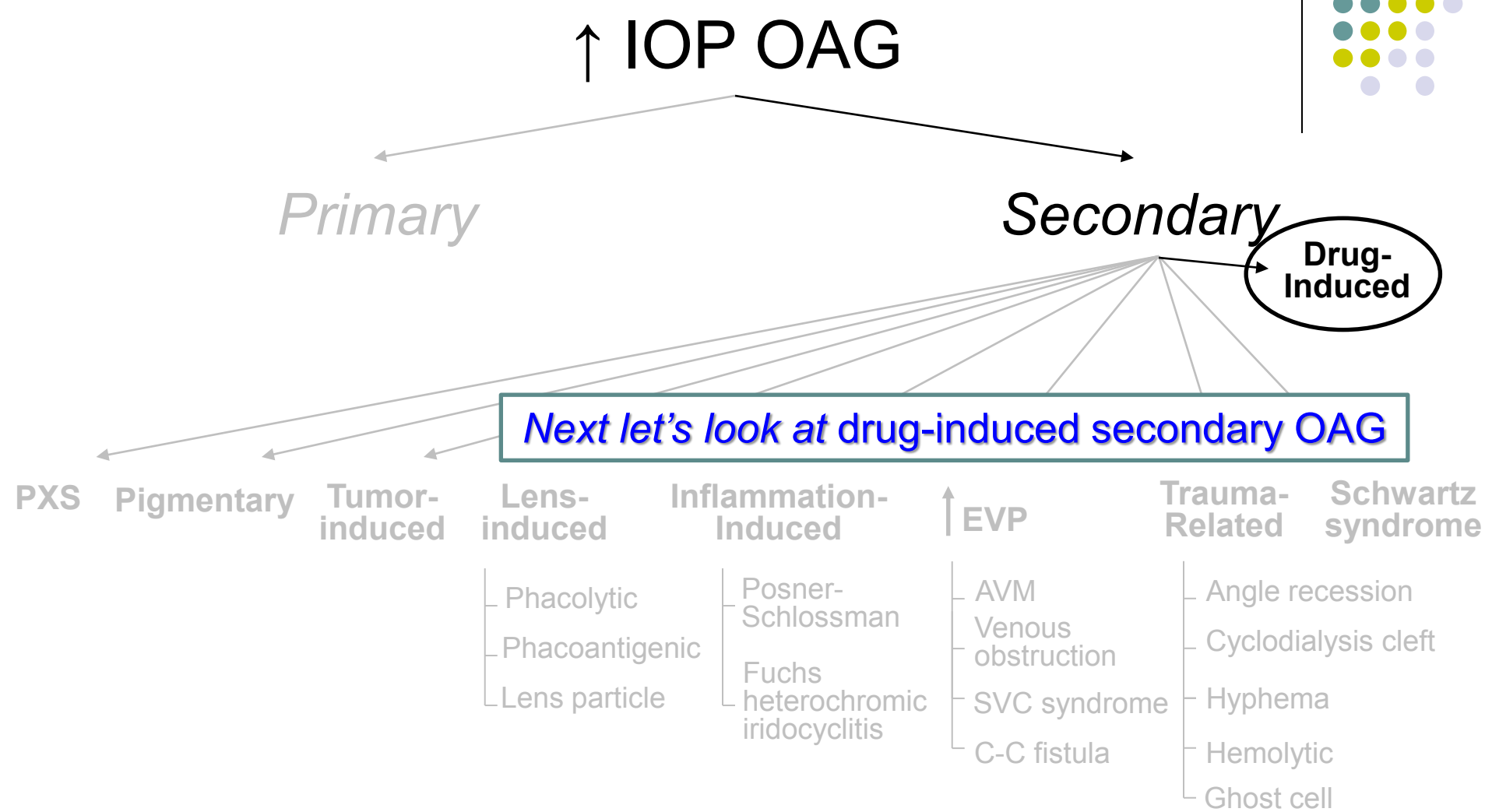

Q

Open-angle Glaucoma: *Secondary*

Which commonly-used compound is notorious for its propensity to elevate IOP?

A

Open-angle Glaucoma: *Secondary*

Which commonly-used compound is notorious for its propensity to elevate IOP?
Corticosteroids

Q

Open-angle Glaucoma: *Secondary*

Which commonly-used compound is notorious for its propensity to elevate IOP?
Corticosteroids

Which of the common routes of ocular administration have been implicated in IOP elevation?
--Topical?
--Intravitreal injection?
--Intravitreal implant?
--Sub-Tenon's/periocular depot?
--Periocular injection?

A

Open-angle Glaucoma: *Secondary*

Which commonly-used compound is notorious for its propensity to elevate IOP?
Corticosteroids

Which of the common routes of ocular administration have been implicated in IOP elevation?
--Topical!
--Intravitreal injection!
--Intravitreal implant!
--Sub-Tenon's/periocular depot!
--Periocular injection!

All *can cause elevated IOP!*

Q

Open-angle Glaucoma: *Secondary*

Which commonly-used compound is notorious for its propensity to elevate IOP?
Corticosteroids

Which of the common ro
IOP elevation?
--Topical!
--**Intravitreal injection**!
--Intravitreal implant!
--Sub-Tenon's/periocular
--Periocular injection!

What proportion of IVit steroid injection pts will develop at least a transient IOP spike?

A

Open-angle Glaucoma: *Secondary*

Which commonly-used compound is notorious for its propensity to elevate IOP?
Corticosteroids

Which of the common ro
IOP elevation?
--Topical!
--**Intravitreal injection**!
--Intravitreal implant!
--Sub-Tenon's/periocular
--Periocular injection!

What proportion of IVit steroid injection pts will develop at least a transient IOP spike?
About 50%!

Q

Open-angle Glaucoma: *Secondary*

Which commonly-used compound is notorious for its propensity to elevate IOP?
Corticosteroids

Which of the common ro
IOP elevation?
--Topical!
--**Intravitreal injection!**
--Intravitreal implant!
--Sub-Tenon's/periocular
--Periocular injection!

What proportion of IVit steroid injection pts will develop at least a transient IOP spike?
About 50%!

Of the 50% of IVit steroid injection pts who experience an IOP spike, what proportion will require topical therapy to control their IOP?

A

Open-angle Glaucoma: *Secondary*

Which commonly-used compound is notorious for its propensity to elevate IOP?
Corticosteroids

Which of the common ro
IOP elevation?
--Topical!
--**Intravitreal injection!**
--Intravitreal implant!
--Sub-Tenon's/periocular
--Periocular injection!

What proportion of IVit steroid injection pts will develop at least a transient IOP spike?
About 50%!

Of the 50% of IVit steroid injection pts who experience an IOP spike, what proportion will require topical therapy to control their IOP?
About 25%

Q

Open-angle Glaucoma: *Secondary*

Which commonly-used compound is notorious for its propensity to elevate IOP?
Corticosteroids

Which of the common ro
IOP elevation?
--Topical!
--**Intravitreal injection!**
--Intravitreal implant!
--Sub-Tenon's/periocular
--Periocular injection!

What proportion of IVit steroid injection pts will develop at least a transient IOP spike?
About 50%!

Of the 50% of IVit steroid injection pts who experience an IOP spike, what proportion will require topical therapy to control their IOP?
About 25%

Of the 50% of IVit steroid injection pts who experience an IOP spike, what proportion will require surgical (incisional) intervention?

A

Open-angle Glaucoma: *Secondary*

Which commonly-used compound is notorious for its propensity to elevate IOP?
Corticosteroids

Which of the common ro
IOP elevation?
--Topical!
--**Intravitreal injection!**
--Intravitreal implant!
--Sub-Tenon's/periocular
--Periocular injection!

What proportion of IVit steroid injection pts will develop at least a transient IOP spike?
About 50%!

Of the 50% of IVit steroid injection pts who experience an IOP spike, what proportion will require topical therapy to control their IOP?
About 25%

Of the 50% of IVit steroid injection pts who experience an IOP spike, what proportion will require surgical (incisional) intervention?
About 2%

Q

Open-angle Glaucoma: *Secondary*

Which commonly-used compound is notorious for its propensity to elevate IOP?
Corticosteroids

Which of the common routes of ocular administration have been implicated in IOP elevation?
--Topical!
--Intravitreal injection!
--**Intravitreal implant**!
--Sub-Tenon's/periocular
--Periocular injection!

*How do **intravitreal implants** compare to injections in terms of producing IOP elevation?*

A

Open-angle Glaucoma: *Secondary*

Which commonly-used compound is notorious for its propensity to elevate IOP?
Corticosteroids

Which of the common routes of ocular administration have been implicated in IOP elevation?
--Topical!
--Intravitreal injection!
--**Intravitreal implant**!
--Sub-Tenon's/periocular
--Periocular injection!

*How do **intravitreal implants** compare to injections in terms of producing IOP elevation?*
They're like intravitreal injections on steroids (if you'll pardon the expression). That is, everything is worse—a greater proportion of implant pts develop IOP spikes, a greater proportion need tx, and a greater proportion require incisional surgery.

Q

Open-angle Glaucoma: *Secondary*

Which commonly-used compound is notorious for its propensity to elevate IOP?
Corticosteroids

Which of the common routes of ocular administration have been implicated in IOP elevation? How about common routes of non-ocular *administration?*

Next Q

--Topical!
--Intravitreal injection!
--Intravitreal implant!
--Sub-Tenon's/periocular depot!
--Periocular injection!
--Systemic?
--Topical?
--Inhaled?
--Nasal?

A

Open-angle Glaucoma: *Secondary*

Which commonly-used compound is notorious for its propensity to elevate IOP?
Corticosteroids

Which of the common routes of ocular administration have been implicated in IOP elevation? How about common routes of non-ocular *administration?*
--Topical!
--Intravitreal injection!
--Intravitreal implant!
--Sub-Tenon's/periocular depot!
--Periocular injection!
--Systemic!
--Topical!
--Inhaled!
--Nasal!

Again, **all** *can cause elevated IOP!*

Q

Open-angle Glaucoma: *Secondary*

Which commonly-used compound is notorious for its propensity to elevate IOP?
Corticosteroids

Which of the common routes of ocular administration have been implicated in IOP elevation? How about common routes of non-ocular *administration?*
--Topical!
--Intravitreal injection!
--Intravitreal implant!
--Sub-Tenon's/periocular depot!
--Periocular injection!
--Systemic!
--Topical!
--Inhaled!
--Nasal!

What condition—very rare, but you know of it—is associated with inappropriately and chronically elevated corticosteroid levels?

A

Open-angle Glaucoma: *Secondary*

Which commonly-used compound is notorious for its propensity to elevate IOP?
Corticosteroids

Which of the common routes of ocular administration have been implicated in IOP elevation? How about common routes of non-ocular *administration?*
--Topical!
--Intravitreal injection!
--Intravitreal implant!
--Sub-Tenon's/periocular depot!
--Periocular injection!
--Systemic!
--Topical!
--Inhaled!
--Nasal!

What condition—very rare, but you know of it—is associated with inappropriately and chronically elevated corticosteroid levels?
Cushing syndrome

Q

Open-angle Glaucoma: *Secondary*

Which commonly-used compound is notorious for its propensity to elevate IOP?
Corticosteroids

Which of the common routes of ocular administration have been implicated in IOP elevation? How about common routes of non-ocular *administration?*
--Topical!
--Intravitreal injection!
--Intravitreal implant!
--Sub-Tenon's/periocular depot!
--Periocular injection!
--Systemic!
--Topical!
--Inhaled!
--Nasal!
--Endogenous?

What condition—very rare, but you know of it—is associated with inappropriately and chronically elevated corticosteroid levels?
Cushing syndrome

Are Cushing pts at risk for developing endogenous *steroid-response IOP elevation?*

A

Open-angle Glaucoma: *Secondary*

Which commonly-used compound is notorious for its propensity to elevate IOP?
Corticosteroids

Which of the common routes of ocular administration have been implicated in IOP elevation? How about common routes of non-ocular *administration?*
--Topical!
--Intravitreal injection!
--Intravitreal implant!
--Sub-Tenon's/periocular depot!
--Periocular injection!
--Systemic!
--Topical!
--Inhaled!
--Nasal!
--Endogenous!

What condition—very rare, but you know of it—is associated with inappropriately and chronically elevated corticosteroid levels?
Cushing syndrome

Are Cushing pts at risk for developing endogenous *steroid-response IOP elevation?*
Yes

Q

Open-angle Glaucoma: *Secondary*

Which commonly-used compound is notorious for its propensity to elevate IOP?
Corticosteroids

Which of the common routes of ocular administration have been implicated in IOP elevation? How about common routes of non-ocular *administration?*
--Topical!
--Intravitreal injection!
--Intravitreal implant!
--Sub-Tenon's/periocular depot!
--Periocular injection!
--Systemic!
--Topical!
--Inhaled!
--Nasal!

Broadly, three sorts of factors determine whether a pt will develop elevated IOP in response to steroid therapy. What are they?
--Factors related to…
--Factors related to…
--Factors related to…

A

Open-angle Glaucoma: *Secondary*

Which commonly-used compound is notorious for its propensity to elevate IOP?
Corticosteroids

Which of the common routes of ocular administration have been implicated in IOP elevation? How about common routes of non-ocular *administration?*
--Topical!
--Intravitreal injection!
--Intravitreal implant!
--Sub-Tenon's/periocular depot!
--Periocular injection!
--Systemic!
--Topical!
--Inhaled!
--Nasal!

Broadly, three sorts of factors determine whether a pt will develop elevated IOP in response to steroid therapy. What are they?
--Factors related to…the steroid itself
--Factors related to…the administration of the steroid
--Factors related to…the pt

Q

Open-angle Glaucoma: *Secondary*

Which commonly-used compound is notorious for its propensity to elevate IOP?
Corticosteroids

Which of the common routes of ocular administration have been implicated in IOP elevation? How about common routes of non-ocular *administration?*
--Topical!
--Intravitreal injection!
--Intravitreal implant!
--Sub-Tenon's/periocular depot!
--Periocular injection!
--Systemic!
--Topical!
--Inhaled!
--Nasal!

Which two properties of a steroid are key in determining whether it will cause an IOP spike?

Broadly, three sorts of factors determine w
in response to steroid therapy. What are th
--**Factors related to…the steroid itself**
--Factors related to…the administration of
--Factors related to…the pt

A

Open-angle Glaucoma: *Secondary*

Which commonly-used compound is notorious for its propensity to elevate IOP?
Corticosteroids

Which of the common routes of ocular administration have been implicated in IOP elevation? How about common routes of non-ocular *administration?*
--Topical!
--Intravitreal injection!
--Intravitreal implant!
--Sub-Tenon's/periocular depot!
--Periocular injection!
--Systemic!
--Topical!
--Inhaled!
--Nasal!

Broadly, three sorts of factors determine w
in response to steroid therapy. What are th
--**Factors related to…the steroid itself**
--Factors related to…the administration of
--Factors related to…the pt

Which two properties of a steroid are key in determining whether it will cause an IOP spike?
Its potency, and its ability to reach the AC

Q

Open-angle Glaucoma: *Secondary*

Which commonly-used compound is notorious for its propensity to elevate IOP?
Corticosteroids

Which of the common routes of ocular administration have been implicated in IOP elevation? How about common routes of non-ocular *administration?*
--Topical!
--Intravitreal injection!
--Intravitreal implant!
--Sub-Tenon's/periocular depot!
--Periocular injection!
--Systemic!
--Topical!
--Inhaled!
--Nasal!

Broadly, three sorts of factors determine w
in response to steroid therapy. What are th
--**Factors related to…the steroid itself**
--Factors related to…the administration of
--Factors related to…the pt

Which two properties of a steroid are key in determining whether it will cause an IOP spike?
Its potency, and its ability to reach the AC

Which steroid tops the list in this regard?

A

Open-angle Glaucoma: *Secondary*

Which commonly-used compound is notorious for its propensity to elevate IOP?
Corticosteroids

Which of the common routes of ocular administration have been implicated in IOP elevation? How about common routes of non-ocular *administration?*
--Topical!
--Intravitreal injection!
--Intravitreal implant!
--Sub-Tenon's/periocular depot!
--Periocular injection!
--Systemic!
--Topical!
--Inhaled!
--Nasal!

Broadly, three sorts of factors determine w
in response to steroid therapy. What are th
--**Factors related to…the steroid itself**
--Factors related to…the administration of
--Factors related to…the pt

Which two properties of a steroid are key in determining whether it will cause an IOP spike?
Its potency, and its ability to reach the AC

Which steroid tops the list in this regard?
Dexamethasone

Q

Open-angle Glaucoma: *Secondary*

Which commonly-used compound is notorious for its propensity to elevate IOP?
Corticosteroids

Which of the common routes of ocular administration have been implicated in IOP elevation? How about common routes of non-ocular *administration?*
--Topical!
--Intravitreal injection!
--Intravitreal implant!
--Sub-Tenon's/periocular depot!
--Periocular injection!
--Systemic!
--Topical!
--Inhaled!
--Nasal!

Broadly, three sorts of factors determine w
in response to steroid therapy. What are th
--**Factors related to…the steroid itself**
--Factors related to…the administration of
--Factors related to…the pt

Which two properties of a steroid are key in determining whether it will cause an IOP spike?
Its potency, and its ability to reach the AC

Which steroid tops the list in this regard?
Dexamethasone

What proportion of pts on topical dex will develop an IOP >30 after 6 weeks of therapy?

A

Open-angle Glaucoma: *Secondary*

Which commonly-used compound is notorious for its propensity to elevate IOP?
Corticosteroids

Which of the common routes of ocular administration have been implicated in IOP elevation? How about common routes of non-ocular *administration?*
--Topical!
--Intravitreal injection!
--Intravitreal implant!
--Sub-Tenon's/periocular depot!
--Periocular injection!
--Systemic!
--Topical!
--Inhaled!
--Nasal!

Broadly, three sorts of factors determine w
in response to steroid therapy. What are th
--**Factors related to…the steroid itself**
--Factors related to…the administration of
--Factors related to…the pt

Which two properties of a steroid are key in determining whether it will cause an IOP spike?
Its potency, and its ability to reach the AC

Which steroid tops the list in this regard?
Dexamethasone

What proportion of pts on topical dex will develop an IOP >30 after 6 weeks of therapy?
About 5%

Q

Open-angle Glaucoma: *Secondary*

Which commonly-used compound is notorious for its propensity to elevate IOP?
Corticosteroids

Which of the common routes of ocular administration have been implicated in IOP elevation? How about common routes of non-ocular *administration?*
--Topical!
--Intravitreal injection!
--Intravitreal implant!
--Sub-Tenon's/periocular depot!
--Periocular injection!
--Systemic!
--Topical!
--Inhaled!

Which administration-related factors play a role in determining whether a steroid-induced IOP rise will occur?
--?
--?
--?

E *will develop elevated IOP i*
--Factors related to…the steroid itself
--**Factors related to…the administration of the steroid**
--Factors related to…the pt

A

Open-angle Glaucoma: *Secondary*

Which commonly-used compound is notorious for its propensity to elevate IOP?
Corticosteroids

Which of the common routes of ocular administration have been implicated in IOP elevation? How about common routes of non-ocular *administration?*
--Topical!
--Intravitreal injection!
--Intravitreal implant!
--Sub-Tenon's/periocular depot!
--Periocular injection!
--Systemic!
--Topical!
--Inhaled!

Which administration-related factors play a role in determining whether a steroid-induced IOP rise will occur?
--The route
--The frequency
--The duration

will develop elevated IOP

--Factors related to…the steroid itself
--**Factors related to…the administration of the steroid**
--Factors related to…the pt

Q

Open-angle Glaucoma: *Secondary*

Which commonly-used compound is notorious for its propensity to elevate IOP?
Corticosteroids

Which of the common routes of ocular administration have been implicated in IOP elevation? How about common routes of non-ocular *administration?*
--Topical!
--Intravitreal injection!
--Intravitreal implant!
--Sub-Tenon's/periocular depot!
--Periocular injection!
--Systemic!
--Topical!
--Inhaled!

Which administration-related factors play a role in determining wh
--**The route**
--The frequenc
--The duration

Which route of admin is more likely to elevate IOP: Topical, or systemic?

elop elevated IOP

--Factors related to…the steroid itself
--**Factors related to…the administration of the steroid**
--Factors related to…the pt

A

Open-angle Glaucoma: *Secondary*

Which commonly-used compound is notorious for its propensity to elevate IOP?
Corticosteroids

Which of the common routes of ocular administration have been implicated in IOP elevation? How about common routes of non-ocular *administration?*
--Topical!
--Intravitreal injection!
--Intravitreal implant!
--Sub-Tenon's/periocular depot!
--Periocular injection!
--Systemic!
--Topical!
--Inhaled!

Which administration-related factors play a role in determining wh
--**The route**
--The frequenc
--The duration

Which route of admin is more likely to elevate IOP: Topical, or systemic?
Topical

elop elevated IOP i

--Factors related to…the steroid itself
--**Factors related to…the administration of the steroid**
--Factors related to…the pt

Q

Open-angle Glaucoma: *Secondary*

Which commonly-used compound is notorious for its propensity to elevate IOP?
Corticosteroids

Which of the common routes of ocular administration have been implicated in IOP elevation? How about common routes of non-ocular *administration?*
--Topical!
--Intravitreal injection!
--Intravitreal implant!
--Sub-Tenon's/periocular depot!
--Periocular injection!
--Systemic!
--Topical!
--Inhaled!

Which administration-related factors play a role in determining wh
--**The route**
--The frequenc
--The duration
--Factors related to…the steroid itself
--**Factors related to…the administration of the steroid**
--Factors related to…the pt

Which route
Topical, or s
Topical

Which route is even more likely than topical to elevate IOP?

A

Open-angle Glaucoma: *Secondary*

Which commonly-used compound is notorious for its propensity to elevate IOP?
Corticosteroids

Which of the common routes of ocular administration have been implicated in IOP elevation? How about common routes of non-ocular *administration?*
--Topical!
--Intravitreal injection!
--Intravitreal implant!
--Sub-Tenon's/periocular depot!
--Periocular injection!
--Systemic!
--Topical!
--Inhaled!

Which administration-related factors play a role in determining wh
--**The route**
--The frequenc
--The duration

Which route
Topical, or s
Topical

Which route is even more likely than topical to elevate IOP?
Intravitreal

--Factors related to…the steroid itself
--**Factors related to…the administration of the steroid**
--Factors related to…the pt

Q

Open-angle Glaucoma: *Secondary*

Which commonly-used compound is notorious for its propensity to elevate IOP?
Corticosteroids

Which of the common routes of ocular administration have been implicated in IOP elevation? How about common routes of non-ocular *administration?*
--Topical!
--Intravitreal injection!
--Intravitreal implant!
--Sub-Tenon's/periocular depot!
--Periocular injection!
--Systemic!
--Topical!
--Inhaled!

Which administration-related factors play a role in determining wh
--**The route**
--The frequenc
--The duration

Which route
Topical, or s
Topical

Which route is even more likely than topical to elevate IOP?
Intravitreal. At least % of pts receiving intravitreal steroids develop an IOP spike

--Factors related to…the steroid itself
--**Factors related to…the administration of the steroid**
--Factors related to…the pt

A

Open-angle Glaucoma: *Secondary*

Which commonly-used compound is notorious for its propensity to elevate IOP?
Corticosteroids

Which of the common routes of ocular administration have been implicated in IOP elevation? How about common routes of non-ocular *administration?*
--Topical!
--Intravitreal injection!
--Intravitreal implant!
--Sub-Tenon's/periocular depot!
--Periocular injection!
--Systemic!
--Topical!
--Inhaled!

Which administration-related factors play a role in determining wh
--**The route**
--The frequenc
--The duration

Which route
Topical, or s
Topical

Which route is even more likely than topical to elevate IOP?
Intravitreal. At least 50% of pts receiving intravitreal steroids develop an IOP spike

--Factors related to…the steroid itself
--**Factors related to…the administration of the steroid**
--Factors related to…the pt

Q

Open-angle Glaucoma: *Secondary*

Which commonly-used compound is notorious for its propensity to elevate IOP?
Corticosteroids

Which of the common routes of ocular administration have been implicated in IOP elevation? How about common routes of non-ocular *administration?*
--Topical!
--Intravitreal injection!
--Intravitreal implant!
--Sub-Tenon's/periocular depot!
--Periocular injection!
--Systemic!
--Topical!
--Inhaled!

Which administration-related factors play a role in determining wh

--**The route**
--The frequenc
--The duration
--Factors related to…the steroid itself
--**Factors related to…the administration of the steroid**
--Factors related to…the pt

Which route
Topical, or s

Topical

Which route is even more likely than topical to elevate IOP?
Intravitreal. At least 50% of pts receiving intravitreal steroids develop an IOP spike, and % will require IOP-lowering tx.

A

Open-angle Glaucoma: *Secondary*

Which commonly-used compound is notorious for its propensity to elevate IOP?
Corticosteroids

Which of the common routes of ocular administration have been implicated in IOP elevation? How about common routes of non-ocular *administration?*
--Topical!
--Intravitreal injection!
--Intravitreal implant!
--Sub-Tenon's/periocular depot!
--Periocular injection!
--Systemic!
--Topical!
--Inhaled!

Which administration-related factors play a role in determining wh

--**The route**
--The frequenc
--The duration
--Factors related to…the steroid itself
--**Factors related to…the administration of the steroid**
--Factors related to…the pt

Which route
Topical, or s

Topical

Which route is even more likely than topical to elevate IOP?
Intravitreal. At least 50% of pts receiving intravitreal steroids develop an IOP spike, and 25% will require IOP-lowering tx.

Q

Open-angle Glaucoma: *Secondary*

Which commonly-used compound is notorious for its propensity to elevate IOP?
Corticosteroids

Which of the common routes of ocular administration have been implicated in IOP elevation? How about common routes of non-ocular *administration?*
--Topical!
--Intravitreal injection!
--Intravitreal implant!
--Sub-Tenon's/periocular depot!
--Periocular injection!
--Systemic!
--Topical!
--Inhaled!

What is the relationship between the commencement of steroid therapy and the subsequent development of elevated IOP?

Which administrat
determining wheth
--The route
--The frequency
--**The duration**

--Factors related t
--**Factors related to…the administration of the steroid**
--Factors related to…the pt

Q/A

Open-angle Glaucoma: *Secondary*

Which commonly-used compound is notorious for its propensity to elevate IOP?
Corticosteroids

Which of the common routes of ocular administration have been implicated in IOP elevation? How about common routes of non-ocular *administration?*
--Topical!
--Intravitreal injection!
--Intravitreal implant!
--Sub-Tenon's/periocular depot!
--Periocular injection!
--Systemic!
--Topical!
--Inhaled!

Which administrat
determining wheth
--The route
--The frequency
--**The duration**

What is the relationship between the commencement of steroid therapy and the subsequent development of elevated IOP?
It essentially never occurs in less than time of use

--Factors related t
--**Factors related to…the administration of the steroid**
--Factors related to…the pt

A

Open-angle Glaucoma: *Secondary*

Which commonly-used compound is notorious for its propensity to elevate IOP?
Corticosteroids

Which of the common routes of ocular administration have been implicated in IOP elevation? How about common routes of non-ocular *administration?*
--Topical!
--Intravitreal injection!
--Intravitreal implant!
--Sub-Tenon's/periocular depot!
--Periocular injection!
--Systemic!
--Topical!
--Inhaled!
--

Which administrat
determining wheth
--The route
--The frequency
--**The duration**

What is the relationship between the commencement of steroid therapy and the subsequent development of elevated IOP?
It essentially never occurs in less than 5 days of use

--Factors related t
--**Factors related to…the administration of the steroid**
--Factors related to…the pt

Q

Open-angle Glaucoma: *Secondary*

Which commonly-used compound is notorious for its propensity to elevate IOP?
Corticosteroids

Which of the common routes of ocular administration have been implicated in IOP elevation? How about common routes of non-ocular *administration?*
--Topical!
--Intravitreal injection!
--Intravitreal implant!
--Sub-Tenon's/periocular depot!
--Periocular injection!
--Systemic!
--Topical!
--Inhaled!

Which administrat
determining wheth
--The route
--The frequency
--**The duration**

What is the relationship between the commencement of steroid therapy and the subsequent development of elevated IOP?
It essentially never occurs in less than 5 days of use, and is distinctly uncommon prior to at least time of use

--Factors related t
--**Factors related to…the administration of the steroid**
--Factors related to…the pt

A

Open-angle Glaucoma: *Secondary*

Which commonly-used compound is notorious for its propensity to elevate IOP?
Corticosteroids

Which of the common routes of ocular administration have been implicated in IOP elevation? How about common routes of non-ocular *administration?*
--Topical!
--Intravitreal injection!
--Intravitreal implant!
--Sub-Tenon's/periocular depot!
--Periocular injection!
--Systemic!
--Topical!
--Inhaled!
--

Which administrat
determining wheth
--The route
--The frequency
--**The duration**

--Factors related t
--**Factors related to…the administration of the steroid**
--Factors related to…the pt

What is the relationship between the commencement of steroid therapy and the subsequent development of elevated IOP?
It essentially never occurs in less than 5 days of use, and is distinctly uncommon prior to at least 2 weeks of use

Q

Open-angle Glaucoma: *Secondary*

Which commonly-used compound is notorious for its propensity to elevate IOP?
Corticosteroids

Which of the common routes of ocular administration have been implicated in IOP elevation? How about common routes of non-ocular *administration?*
--Topical!
--Intravitreal injection!
--Intravitreal implant!
--Sub-Tenon's/periocular depot!
--Periocular injection!
--Systemic!
--Topical!
--Inhaled!
--

Which administrat
determining wheth
--The route
--The frequency
--**The duration**

--Factors related t

--**Factors related to…the administration of the steroid**
--Factors related to…the pt

What is the relationship between the commencement of steroid therapy and the subsequent development of elevated IOP?
It essentially never occurs in less than 5 days of use, and is distinctly uncommon prior to at least 2 weeks of use

If IOP elevation does not occur by 6 weeks, is it reasonable to assume it isn't going to occur?

A

Open-angle Glaucoma: *Secondary*

Which commonly-used compound is notorious for its propensity to elevate IOP?
Corticosteroids

Which of the common routes of ocular administration have been implicated in IOP elevation? How about common routes of non-ocular *administration?*
--Topical!
--Intravitreal injection!
--Intravitreal implant!
--Sub-Tenon's/periocular depot!
--Periocular injection!
--Systemic!
--Topical!
--Inhaled!
--

Which administrat
determining wheth
--The route
--The frequency
--**The duration**

--Factors related t
--**Factors related to…the administration of the steroid**
--Factors related to…the pt

What is the relationship between the commencement of steroid therapy and the subsequent development of elevated IOP?
It essentially never occurs in less than 5 days of use, and is distinctly uncommon prior to at least 2 weeks of use

If IOP elevation does not occur by 6 weeks, is it reasonable to assume it isn't going to occur?
No! IOP elevation can occur at **any** point during extended steroid therapy.

Q

Open-angle Glaucoma: *Secondary*

Which commonly-used compound is notorious for its propensity to elevate IOP?
Corticosteroids

Which of the common routes of ocular administration have been implicated in IOP elevation? How about common routes of non-ocular *administration?*
--Topical!
--Intravitreal injection!
--Intravitreal implant!
--Sub-T
--Perio
--Syste
--Topic
--Inhal
--
--
--
--Factors related t
--**Factors related to…the administration of the steroid**
--Factors related to…the pt

Is steroid-induced IOP elevation a reversible condition, ie, does IOP return to baseline with cessation of steroid use?

therapy

stinctly

Which
deter
--The route
--The frequency
--**The duration**

If IOP elevation does not occur by 6 weeks, is it reasonable to assume it isn't going to occur?
No! IOP elevation can occur at **any** point during extended steroid therapy.

A

Open-angle Glaucoma: *Secondary*

Which commonly-used compound is notorious for its propensity to elevate IOP?
Corticosteroids

Which of the common routes of ocular administration have been implicated in IOP elevation? How about common routes of non-ocular *administration?*
--Topical!
--Intravitreal injection!
--Intravitreal implant!
--Sub-T
--Perio
--Syste
--Topic
--Inhal
--
--
--
--Factors related t
--**Factors related to…the administration of the steroid**
--Factors related to…the pt

Is steroid-induced IOP elevation a reversible condition, ie, does IOP return to baseline with cessation of steroid use?
Yes, provided the steroid is stopped in time

Which
deter
--The route
--The frequency
--**The duration**

If IOP elevation does not occur by 6 weeks, is it reasonable to assume it isn't going to occur?
No! IOP elevation can occur at **any** point during extended steroid therapy.

therapy

stinctly

Q

Open-angle Glaucoma: *Secondary*

Which commonly-used compound is notorious for its propensity to elevate IOP?
Corticosteroids

Which of the common routes of ocular administration have been implicated in IOP elevation? How about common routes of non-ocular *administration?*
--Topical!
--Intravitreal injection!
--Intravitreal implant!
--Sub-T
--Perio
--Syste
--Topic
--Inhal
--The route
--The frequency
--**The duration**
--Factors related t
--**Factors related to…the administration of the steroid**
--Factors related to…the pt

Is steroid-induced IOP elevation a reversible condition, ie, does IOP return to baseline with cessation of steroid use?
Yes, provided the steroid is stopped in time

What is the timeframe for stopping the steroid 'in time'?

Which
deter

If IOP elevation does not occur by 6 weeks, is it reasonable to assume it isn't going to occur?
No! IOP elevation can occur at **any** point during extended steroid therapy.

therapy
stinctly

Q/A

Open-angle Glaucoma: *Secondary*

Which commonly-used compound is notorious for its propensity to elevate IOP?
Corticosteroids

Which of the common routes of ocular administration have been implicated in IOP elevation? How about common routes of non-ocular *administration?*
--Topical!
--Intravitreal injection!
--Intravitreal implant!
--Sub-T
--Perio
--Syste
--Topic
--Inhal
--
--The route
--The frequency
--**The duration**
--Factors related t
--**Factors related to…the administration of the steroid**
--Factors related to…the pt

Is steroid-induced IOP elevation a reversible condition, ie, does IOP return to baseline with cessation of steroid use?
Yes, provided the steroid is stopped in time

What is the timeframe for stopping the steroid 'in time'?
If the steroid is stopped within time of onset, IOP will likely normalize.

Which
deter

If IOP elevation does not occur by 6 weeks, is it reasonable to assume it isn't going to occur?
No! IOP elevation can occur at **any** point during extended steroid therapy.

therapy
stinctly

A

Open-angle Glaucoma: *Secondary*

Which commonly-used compound is notorious for its propensity to elevate IOP?
Corticosteroids

Which of the common routes of ocular administration have been implicated in IOP elevation? How about common routes of non-ocular *administration?*
--Topical!
--Intravitreal injection!
--Intravitreal implant!
--Sub-T
--Perio
--Syste
--Topic
--Inhal
--The route
--The frequency
--**The duration**
--Factors related t
--**Factors related to…the administration of the steroid**
--Factors related to…the pt

Is steroid-induced IOP elevation a reversible condition, ie, does IOP return to baseline with cessation of steroid use?
Yes, provided the steroid is stopped in time

What is the timeframe for stopping the steroid 'in time'?
If the steroid is stopped within 1 year of onset, IOP will likely normalize.

Which
deter

If IOP elevation does not occur by 6 weeks, is it reasonable to assume it isn't going to occur?
No! IOP elevation can occur at **any** point during extended steroid therapy.

Q

Open-angle Glaucoma: *Secondary*

Which commonly-used compound is notorious for its propensity to elevate IOP?
Corticosteroids

Which of the common routes of ocular administration have been implicated in IOP elevation? How about common routes of non-ocular *administration?*
--Topical!
--Intravitreal injection!
--Intravitreal implant!
--Sub-T
--Perio
--Syste
--Topic
--Inhal
--The route
--The frequency
--**The duration**
--Factors related t
--**Factors related to…the administration of the steroid**
--Factors related to…the pt

Is steroid-induced IOP elevation a reversible condition, ie, does IOP return to baseline with cessation of steroid use?
Yes, provided the steroid is stopped in time

What is the timeframe for stopping the steroid 'in time'?
If the steroid is stopped within 1 year of onset, IOP will likely normalize.
OTOH, if it is continued longer than time, IOP elevation will likely be permanent.

Which
deter

If IOP elevation does not occur by 6 weeks, is it reasonable to assume it isn't going to occur?
No! IOP elevation can occur at **any** point during extended steroid therapy.

A

Open-angle Glaucoma: *Secondary*

Which commonly-used compound is notorious for its propensity to elevate IOP?
Corticosteroids

Which of the common routes of ocular administration have been implicated in IOP elevation? How about common routes of non-ocular *administration?*
--Topical!
--Intravitreal injection!
--Intravitreal implant!
--Sub-T
--Perio
--Syste
--Topic
--Inhal
--The route
--The frequency
--**The duration**
--Factors related t
--**Factors related to…the administration of the steroid**
--Factors related to…the pt

Is steroid-induced IOP elevation a reversible condition, ie, does IOP return to baseline with cessation of steroid use?
Yes, provided the steroid is stopped in time

What is the timeframe for stopping the steroid 'in time'?
If the steroid is stopped within 1 year of onset, IOP will likely normalize. OTOH, if it is continued longer than 18 months , IOP elevation will likely be permanent.

Which
deter

If IOP elevation does not occur by 6 weeks, is it reasonable to assume it isn't going to occur?
No! IOP elevation can occur at **any** point during extended steroid therapy.

therapy
stinctly

Q

Open-angle Glaucoma: *Secondary*

Which commonly-used compound is notorious for its propensity to elevate IOP?
Corticosteroids

Which of the common routes of ocular administration have been implicated in IOP elevation? How about common routes of non-ocular *administration?*
--Topical!
--Intravitreal injection!
--Intravitreal implant!
--Sub-Tenon's/periocular depot!
--Periocular injection!
--Systemic!
--Topical!

What common ocular condition is a risk factor for developing elevated IOP as a result of steroid use?

ated IOP

--**Factors related to…the pt**

A

Open-angle Glaucoma: *Secondary*

Which commonly-used compound is notorious for its propensity to elevate IOP?
Corticosteroids

Which of the common routes of ocular administration have been implicated in IOP elevation? How about common routes of non-ocular *administration?*
--Topical!
--Intravitreal injection!
--Intravitreal implant!
--Sub-Tenon's/periocular depot!
--Periocular injection!
--Systemic!
--Topical!

What common ocular condition is a risk factor for developing elevated IOP as a result of steroid use?
POAG

ated IOP

--**Factors related to…the pt**

Q

Open-angle Glaucoma: *Secondary*

Which commonly-used compound is notorious for its propensity to elevate IOP?
Corticosteroids

Which of the common routes of ocular administration have been implicated in IOP elevation? How about common routes of non-ocular *administration?*
--Topical!
--Intravitreal injection!
--Intravitreal implant!
--Sub-Tenon's/periocular depot!
--Periocular injection!
--Systemic!
--Topical!

What common ocular condition is a risk factor for developing elevated IOP as a result of steroid use?
POAG. Per the *Glaucoma* book, up to % of POAG pts are steroid responders!

ated IOP

--**Factors related to…the pt**

A

Open-angle Glaucoma: *Secondary*

Which commonly-used compound is notorious for its propensity to elevate IOP?
Corticosteroids

Which of the common routes of ocular administration have been implicated in IOP elevation? How about common routes of non-ocular *administration?*
--Topical!
--Intravitreal injection!
--Intravitreal implant!
--Sub-Tenon's/periocular depot!
--Periocular injection!
--Systemic!
--Topical!

What common ocular condition is a risk factor for developing elevated IOP as a result of steroid use?
POAG. Per the *Glaucoma* book, up to 95% of POAG pts are steroid responders!

ated IOP

--**Factors related to…the pt**

Q

Open-angle Glaucoma: *Secondary*

Which commonly-used compound is notorious for its propensity to elevate IOP?
Corticosteroids

Which of the common routes of ocular administration have been implicated in IOP elevation? How about common routes of non-ocular *administration?*
--Topical!
--Intravitreal injection!
--Intravitreal implant!
--Sub-Tenon's/periocular depot!
--Periocular injection!
--Systemic!
--Topical!

What common ocular condition is a risk factor for developing elevated IOP as a result of steroid use?
POAG. Per the *Glaucoma* book, up to 95% of POAG pts are steroid responders!

In terms of aqueous dynamics (ie, its production, outflow, etc), what is the cause of a steroid-induced IOP spike?

--**Factors related to…the pt**

Q/A

Open-angle Glaucoma: *Secondary*

Which commonly-used compound is notorious for its propensity to elevate IOP?
Corticosteroids

Which of the common routes of ocular administration have been implicated in IOP elevation? How about common routes of non-ocular *administration?*
--Topical!
--Intravitreal injection!
--Intravitreal implant!
--Sub-Tenon's/periocular depot!
--Periocular injection!
--Systemic!
--Topical!

What common ocular condition is a risk factor for developing elevated IOP as a result of steroid use?
POAG. Per the *Glaucoma* book, up to 95% of POAG pts are steroid responders!

ated IOP

In terms of aqueous dynamics (ie, its production, outflow, etc), what is the cause of a steroid-induced IOP spike?
Increased resistance to outflow at the

--**Factors related to…the pt**

A

Open-angle Glaucoma: *Secondary*

Which commonly-used compound is notorious for its propensity to elevate IOP?
Corticosteroids

Which of the common routes of ocular administration have been implicated in IOP elevation? How about common routes of non-ocular *administration?*
--Topical!
--Intravitreal injection!
--Intravitreal implant!
--Sub-Tenon's/periocular depot!
--Periocular injection!
--Systemic!
--Topical!

What common ocular condition is a risk factor for developing elevated IOP as a result of steroid use?
POAG. Per the *Glaucoma* book, up to 95% of POAG pts are steroid responders!

In terms of aqueous dynamics (ie, its production, outflow, etc), what is the cause of a steroid-induced IOP spike?
Increased resistance to outflow at the TM

--**Factors related to…the pt**

Q

Open-angle Glaucoma: *Secondary*

Which commonly-used compound is notorious for its propensity to elevate IOP?
Corticosteroids

Which of the common routes of ocular administration have been implicated in IOP elevation? How about common routes of non-ocular *administration?*
--Topical!
--Intravitreal injection!
--Intravitreal implant!
--Sub-Tenon's/periocular depot!
--Periocular injection!
--Systemic!
--Topical!

What common ocular condition is a risk factor for developing elevated IOP as a result of steroid use?
POAG. Per the *Glaucoma* book, up to 95% of POAG pts are steroid responders!

In terms of aqueous dynamics (ie ... *ated IOP of a steroid-induced IOP spike?*
Increased resistance to outflow a

A family hx of POAG is a risk factor for developing POAG. Is it also a risk factor for steroid-induced IOP spike?

--**Factors related to…the pt**, *including their family history?*

A

Open-angle Glaucoma: *Secondary*

Which commonly-used compound is notorious for its propensity to elevate IOP?
Corticosteroids

Which of the common routes of ocular administration have been implicated in IOP elevation? How about common routes of non-ocular *administration?*
--Topical!
--Intravitreal injection!
--Intravitreal implant!
--Sub-Tenon's/periocular depot!
--Periocular injection!
--Systemic!
--Topical!

What common ocular condition is a risk factor for developing elevated IOP as a result of steroid use?
POAG. Per the *Glaucoma* book, up to 95% of POAG pts are steroid responders!

In terms of aqueous dynamics (ie ... *ated IOP of a steroid-induced IOP spike?*
Increased resistance to outflow a

A family hx of POAG is a risk factor for developing POAG. Is it also a risk factor for steroid-induced IOP spike?
Indeed it is

--**Factors related to…the pt**, *including their family history? Yup!*

Q

Open-angle Glaucoma: *Secondary*

Which commonly-used compound is notorious for its propensity to elevate IOP?
Corticosteroids

Which of the common routes of ocular administration have been implicated in IOP elevation? How about common routes of non-ocular *administration?*
--Topical!
--Intravitreal injection!
--Intravitreal implant!
--Sub-Tenon's/periocular depot!
--Periocular injection!
--Systemic!
--Topical!

What common ocular condition is a risk factor for developing elevated IOP as a result of steroid use?
POAG. Per the *Glaucoma* book, up to 95% of POAG pts are steroid responders!

In terms of aqueous dynamics (ie
of a steroid-induced IOP spike?
Increased resistance to outflow a

A family hx of POAG is a risk factor for developing POAG. Is it also a risk factor for steroid-induced IOP spike?
Inde

What other pt factors increase the risk of a steroid-induced IOP spike?
--?
--?
--?

[Hints forthcoming]

--**Factors related to…the pt**,

Q/A

Open-angle Glaucoma: *Secondary*

Which commonly-used compound is notorious for its propensity to elevate IOP?
Corticosteroids

Which of the common routes of ocular administration have been implicated in IOP elevation? How about common routes of non-ocular *administration?*
--Topical!
--Intravitreal injection!
--Intravitreal implant!
--Sub-Tenon's/periocular depot!
--Periocular injection!
--Systemic!
--Topical!

What common ocular condition is a risk factor for developing elevated IOP as a result of steroid use?
POAG. Per the *Glaucoma* book, up to 95% of POAG pts are steroid responders!

In terms of aqueous dynamics (ie
of a steroid-induced IOP spike?
Increased resistance to outflow a

A family hx of POAG is a risk factor for developing POAG. Is it also a risk factor for steroid-induced IOP spike?
Inde

What other pt factors increase the risk of a steroid-induced IOP spike?
--Pt age *[but being very old, or very young?]*
--?
--?

--**Factors related to…the pt**,

A

Open-angle Glaucoma: *Secondary*

Which commonly-used compound is notorious for its propensity to elevate IOP?
Corticosteroids

Which of the common routes of ocular administration have been implicated in IOP elevation? How about common routes of non-ocular *administration?*
--Topical!
--Intravitreal injection!
--Intravitreal implant!
--Sub-Tenon's/periocular depot!
--Periocular injection!
--Systemic!
--Topical!

What common ocular condition is a risk factor for developing elevated IOP as a result of steroid use?
POAG. Per the *Glaucoma* book, up to 95% of POAG pts are steroid responders!

In terms of aqueous dynamics (ie
of a steroid-induced IOP spike?
Increased resistance to outflow a

A family hx of POAG is a risk factor for developing POAG. Is it also a risk factor for steroid-induced IOP spike?
Inde

What other pt factors increase the risk of a steroid-induced IOP spike?
--Pt age (being either very old ***or*** very young)
--?
--?

--**Factors related to…the pt**,

Q

Open-angle Glaucoma: *Secondary*

Which commonly-used compound is notorious for its propensity to elevate IOP?
Corticosteroids

Which of the common routes of ocular administration have been implicated in IOP elevation? How about common routes of non-ocular *administration?*
--Topical!
--Intravitreal injection!
--Intravitreal implant!
--Sub-Tenon's/periocular depot!
--Periocular injection!
--Systemic!
--Topical!

What common ocular condition is a risk factor for developing elevated IOP as a result of steroid use?
POAG. Per the *Glaucoma* book, up to 95% of POAG pts are steroid responders!

In terms of aqueous dynamics (ie ... *ated IOP of a steroid-induced IOP spike?*
Increased resistance to outflow a

A family hx of POAG is a risk factor for developing POAG. Is it also a risk factor for steroid-induced IOP spike?
Inde

What other pt factors increase the risk of a steroid-induced IOP spike?
--Pt age (being either very old ***or*** very young)
--*[Refractive status]*
--*?*

--**Factors related to…the pt**, (

A

Open-angle Glaucoma: *Secondary*

Which commonly-used compound is notorious for its propensity to elevate IOP?
Corticosteroids

Which of the common routes of ocular administration have been implicated in IOP elevation? How about common routes of non-ocular *administration?*
--Topical!
--Intravitreal injection!
--Intravitreal implant!
--Sub-Tenon's/periocular depot!
--Periocular injection!
--Systemic!
--Topical!

What common ocular condition is a risk factor for developing elevated IOP as a result of steroid use?
POAG. Per the *Glaucoma* book, up to 95% of POAG pts are steroid responders!

In terms of aqueous dynamics (ie
of a steroid-induced IOP spike?
Increased resistance to outflow a

A family hx of POAG is a risk factor for developing POAG. Is it also a risk factor for steroid-induced IOP spike?
Inde

What other pt factors increase the risk of a steroid-induced IOP spike?
--Pt age (being either very old ***or*** very young)
--Myopia
--*?*

--**Factors related to…the pt**,

Q

Open-angle Glaucoma: *Secondary*

Which commonly-used compound is notorious for its propensity to elevate IOP?
Corticosteroids

Which of the common routes of ocular administration have been implicated in IOP elevation? How about common routes of non-ocular *administration?*
--Topical!
--Intravitreal injection!
--Intravitreal implant!
--Sub-Tenon's/periocular depot!
--Periocular injection!
--Systemic!
--Topical!

What common ocular condition is a risk factor for developing elevated IOP as a result of steroid use?
POAG. Per the *Glaucoma* book, up to 95% of POAG pts are steroid responders!

In terms of aqueous dynamics (ie
of a steroid-induced IOP spike?
Increased resistance to outflow a

A family hx of POAG is a risk factor for developing POAG. Is it also a risk factor for steroid-induced IOP spike?
Inde

What other pt factors increase the risk of a steroid-induced IOP spike?
--Pt age (being either very old ***or*** very young)
--Myopia
--DM type I or II

--**Factors related to…the pt**,

A

Open-angle Glaucoma: *Secondary*

Which commonly-used compound is notorious for its propensity to elevate IOP?
Corticosteroids

Which of the common routes of ocular administration have been implicated in IOP elevation? How about common routes of non-ocular *administration?*
--Topical!
--Intravitreal injection!
--Intravitreal implant!
--Sub-Tenon's/periocular depot!
--Periocular injection!
--Systemic!
--Topical!

What common ocular condition is a risk factor for developing elevated IOP as a result of steroid use?
POAG. Per the *Glaucoma* book, up to 95% of POAG pts are steroid responders!

In terms of aqueous dynamics (ie
of a steroid-induced IOP spike?
Increased resistance to outflow a

A family hx of POAG is a risk factor for developing POAG. Is it also a risk factor for steroid-induced IOP spike?
Inde

What other pt factors increase the risk of a steroid-induced IOP spike?
--Pt age (being either very old ***or*** very young)
--Myopia
--DM type I

--**Factors related to…the pt**,

Q

Open-angle Glaucoma: *Secondary*

even more (in clinic) can

Which commonly-used compound is notorious for its propensity to elevate IOP?

Corticosteroids

What sort of compound—used a kajillion times a day in eye-dentist clinics around the world—can induce IOP elevation?

Which ... *ated in IOP el* ... *?*

--Topic

--Intrav

--Intrav

--Sub-T

--Periocular injection!

--Systemic!

--Topical!

--Inhaled!

--Nasal!

Broadly, three sorts of factors determine whether a pt will develop elevated IOP in response to steroid therapy. What are they?

--Factors related to…the steroid itself

--Factors related to…the administration of the steroid

--Factors related to…the pt, including their family history

A

Open-angle Glaucoma: *Secondary*

even more (in clinic) can

Which commonly-used compound is notorious for its propensity to elevate IOP?

Corticosteroids

What sort of compound—used a kajillion times a day in eye-dentist clinics around the world—can induce IOP elevation?

Cycloplegics

Which ... *ated in IOP el* ... *?*

--Topic

--Intrav

--Intrav

--Sub-T

--Periocular injection!

--Systemic!

--Topical!

--Inhaled!

--Nasal!

Broadly, three sorts of factors determine whether a pt will develop elevated IOP in response to steroid therapy. What are they?

--Factors related to…the steroid itself

--Factors related to…the administration of the steroid

--Factors related to…the pt, including their family history

Q

Open-angle Glaucoma: *Secondary*

even more (in clinic) can

Which commonly-used compound is notorious for its propensity to elevate IOP?

Corticosteroids

Which ... *ated in IOP el* ... *?*

--Topic

--Intrav

--Intrav

--Sub-T

--Periocular injection!

--Systemic!

--Topical!

--Inhaled!

--Nasal!

What sort of compound—used a kajillion times a day in eye-dentist clinics around the world—can induce IOP elevation?

Cycloplegics

Are POAG pts at greater risk, as they are with steroids?

Broadly, three sorts of factors determine whether a pt will develop elevated IOP in response to steroid therapy. What are they?

--Factors related to…the steroid itself

--Factors related to…the administration of the steroid

--Factors related to…the pt, including their family history

A

Open-angle Glaucoma: *Secondary*

even more (in clinic) can

Which commonly-used compound is notorious for its propensity to elevate IOP?

Corticosteroids

What sort of compound—used a kajillion times a day in eye-dentist clinics around the world—can induce IOP elevation?

Cycloplegics

Are POAG pts at greater risk, as they are with steroids?

Indeed they are

Which ... *ated in IOP el* ... *?*

--Topic

--Intrav

--Intrav

--Sub-

--Periocular injection!

--Systemic!

--Topical!

--Inhaled!

--Nasal!

Broadly, three sorts of factors determine whether a pt will develop elevated IOP in response to steroid therapy. What are they?

--Factors related to…the steroid itself

--Factors related to…the administration of the steroid

--Factors related to…the pt, including their family history

Q

Open-angle Glaucoma: *Secondary*

even more (in clinic) can

Which commonly-used compound is notorious for its propensity to elevate IOP?

Corticosteroids

Which *ated in*
IOP el *?*
--Topic
--Intrav
--Intrav
--Sub-
--Periocu
--System
--Topical
--Inhaled
--Nasal!

What sort of compound—used a kajillion times a day in eye-dentist clinics around the world—can induce IOP elevation?

Cycloplegics

What sort of compound—used a kajillion times a **year** *(note the change) in eye-dentist clinics around the world—can induce IOP elevation?*

Broadly, *vated IOP*
in respo
--Factors related to…the steroid itself
--Factors related to…the administration of the steroid
--Factors related to…the pt, including their family history

A

Open-angle Glaucoma: *Secondary*

even more (in clinic) can

Which commonly-used compound is notorious for its propensity to elevate IOP?

Corticosteroids

Which *ated in*
IOP ele *?*
--Topic
--Intrav
--Intrav
--Sub-T
--Periocu
--System
--Topical
--Inhaled
--Nasal!

What sort of compound—used a kajillion times a day in eye-dentist clinics around the world—can induce IOP elevation?

Cycloplegics

What sort of compound—used a kajillion times a **year** *(note the change) in eye-dentist clinics around the world—can induce IOP elevation?*

Intravitreal anti-VEGF (injections)

Broadly, *vated IOP*
in respon
--Factors related to…the steroid itself
--Factors related to…the administration of the steroid
--Factors related to…the pt, including their family history

Q

Open-angle Glaucoma: *Secondary*

even more (in clinic) can

Which commonly-used compound is notorious for its propensity to elevate IOP?

Corticosteroids

Which *ated in*
IOP el *?*
--Topic
--Intrav
--Intrav
--Sub-
--Periocu
--System
--Topical
--Inhalec
--Nasal!

What sort of compound—used a kajillion times a day in eye-dentist clinics around the world—can induce IOP elevation?

Cycloplegics

What sort of compound—used a kajillion times a **year** *(note the change) in eye-dentist clinics around the world—can induce IOP elevation?*

Intravitreal anti-VEGF (injections)

Are you talking about a transient IOP spike 2ndry to putting something in the eye, or a more sustained IOP elevation?

Broadly, *vated IOP*
in respo
--Factors related to…the steroid itself
--Factors related to…the administration of the steroid
--Factors related to…the pt, including their family history

A

Open-angle Glaucoma: *Secondary*

even more (in clinic) can

Which commonly-used compound is notorious for its propensity to elevate IOP?

Corticosteroids

Which ... *ated in*
IOP el ... *?*
--Topic
--Intrav
--Intrav
--Sub-
--Periocu
--System
--Topical
--Inhalec
--Nasal!

Broadly, ... *ated IOP*
in respo
--Factors related to…the steroid itself
--Factors related to…the administration of the steroid
--Factors related to…the pt, including their family history

What sort of compound—used a kajillion times a day in eye-dentist clinics around the world—can induce IOP elevation?
Cycloplegics

What sort of compound—used a kajillion times a **year** *(note the change) in eye-dentist clinics around the world—can induce IOP elevation?*
Intravitreal anti-VEGF (injections)

Are you talking about a transient IOP spike 2ndry to putting something in the eye, or a more sustained IOP elevation?
Both. And while a transient acute spike after injection is not unexpected, the sustained elevation that can occur after multiple injections is.

Q

Open-angle Glaucoma: *Secondary*

even more (in clinic) can

Which commonly-used compound is notorious for its propensity to elevate IOP?

Corticosteroids

Which ... *ated in*
IOP el ... *?*
--Topic
--Intrav
--Intrav
--Sub-
--Periocu
--System
--Topical
--Inhaled
--Nasal!

Broadly, ... *vated IOP*
in respo
--Fac
--Fac
--Factors related to…the pt, including their family history

What sort of compound—used a kajillion times a day in eye-dentist clinics around the world—can induce IOP elevation?
Cycloplegics

What sort of compound—used a kajillion times a **year** *(note the change) in eye-dentist clinics around the world—can induce IOP elevation?*
Intravitreal anti-VEGF (injections)

Are you talking about a transient IOP spike 2ndry to putting something in the eye, or a more sustained IOP elevation?
Both. And while a transient acute spike after injection is not unexpected, the sustained elevation that can occur after multiple injections is.

What is the mechanism of sustained IOP elevation after multiple injections?

A

Open-angle Glaucoma: *Secondary*

even more (in clinic) can

Which commonly-used compound is notorious for its propensity to elevate IOP?

Corticosteroids

Which ... *ated in*
IOP el ... *?*
--Topic
--Intrav
--Intrav
--Sub-
--Periocu
--System
--Topical
--Inhalec
--Nasal!

Broadly, ... *vated IOP*
in respo
--Fac
--Fac
--Factors related to…the pt, including their family history

What sort of compound—used a kajillion times a day in eye-dentist clinics around the world—can induce IOP elevation?
Cycloplegics

What sort of compound—used a kajillion times a **year** *(note the change) in eye-dentist clinics around the world—can induce IOP elevation?*
Intravitreal anti-VEGF (injections)

Are you talking about a transient IOP spike 2ndry to putting something in the eye, or a more sustained IOP elevation?
Both. And while a transient acute spike after injection is not unexpected, the sustained elevation that can occur after multiple injections is.

What is the mechanism of sustained IOP elevation after multiple injections?
It is unknown at this time

Open-angle Glaucoma: *Secondary*

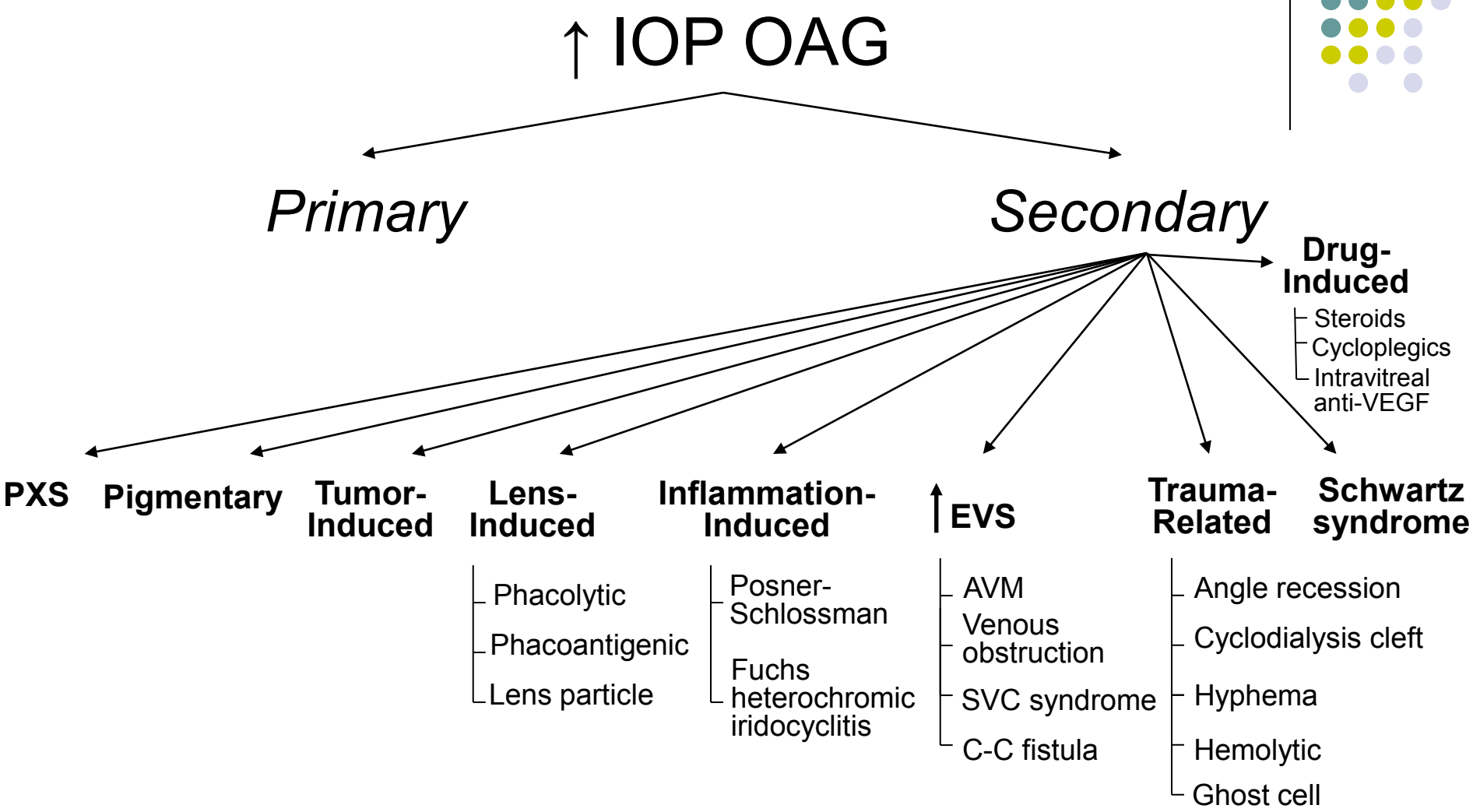

Summary slide of the major secondary open-angle glaucomas (no question)

Open-angle Glaucoma: *Secondary*

Secondary Open-Angle Glaucoma

Highlights

- Pseudoexfoliation syndrome is the most common cause of secondary open-angle glaucoma (OAG).
- The lens can initiate secondary OAG through a variety of inflammatory mechanisms.
- Ocular inflammatory syndromes may be linked to OAG through both inflammation and the eye's physiological response to steroids.
- Trauma, whether accidental or surgical, is an important cause of secondary OAG.
- Repeated intravitreal injections of anti–vascular endothelial growth factor agents may be associated with increased intraocular pressure.

This is a screenshot of the Highlights from the 2ndry OAG chapter in the latest (at the time of this writing) edition of the *Glaucoma* book. Prioritize your learning accordingly.