


MYSTERY IMAGE
BLINK



Sumana S. Kommana, MD

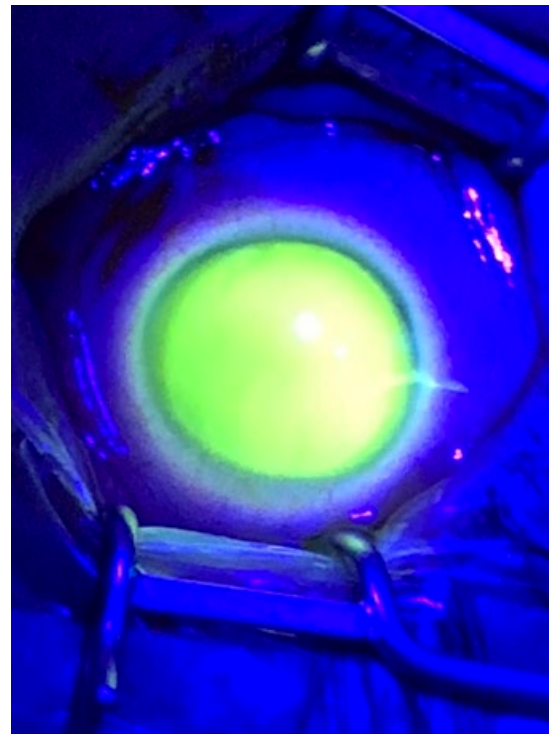
VIEW AN 8-SECOND VIDEO OF THIS CONDITION at aao.org/eyenet, then make your diagnosis in the comments.

LAST MONTH'S BLINK

Topotecan in the Anterior Chamber

Topotecan is a topoisomerase inhibitor that is a semisynthetic derivative of camptothecin, a plant alkaloid. It is used in treating retinoblastoma and has been successfully administered through intravenous, intra-arterial, periocular, and intravitreal routes. It fluoresces in ultraviolet light.

This child had unilateral retinoblastoma with anterior chamber seeding after primary treatment, thus was treated with intracameral topotecan. The drug (20 µg/0.05 cc) was injected into the anterior chamber with a 33-gauge needle. In this image, the entry site is visible temporally, and the drug in the anterior chamber fluoresces, as do the aqueous veins of Ascher. There was no corneal toxicity once the drug cleared.



WRITTEN BY **DAVID H. ABRAMSON, MD**, AND **JASMINE H. FRANCIS, MD**. PHOTO BY **DAVID H. ABRAMSON, MD**. DR. ABRAMSON AND DR. FRANCIS ARE AT MEMORIAL SLOAN KETTERING CANCER CENTER AND WEILL-CORNELL MEDICAL SCHOOL IN NEW YORK, N.Y.