



Sponsored Image

With a committed audience that reads each issue regularly and thoroughly, *EyeNet*—the official newsmagazine of the American Academy of Ophthalmology—delivers unparalleled reach and prestige. Take advantage of this positioning to showcase your imaging product with *EyeNet*'s Sponsored Image. Your image and case description is rotated in every month onto a dedicated page on aao.org/eyenet. Callouts and links on the *EyeNet* website provide extra exposure.

www.eyenet.org averages 155,000 visitors, 179,000 visits, and 210,000 page views per month.

HIGHLIGHT YOUR PRODUCT'S CAPABILITIES

Secure your spot as the sole sponsor of *EyeNet*'s latest opportunity. The Sponsored Image gives you the expanded space you need to showcase the capabilities of your imaging device to ophthalmologists. This high-visibility vehicle gives you the opportunity to deliver your message straight to *EyeNet*'s loyal readers. Make sure they get the latest news from you!

READERS ARE LED TO THIS DEDICATED PAGE IN 4 WAYS:


1. An announcement about the new Sponsored Image area to appear in the Feature box on the home page at aao.org/eyenet.
2. A special Sponsored Image tab (run of site) on the *EyeNet* menubar.
3. A mention within the Blink TOC entry on the home page at aao.org/eyenet.
4. A link on the Blink page.

RATES

1 year: \$40,000
2 year: \$55,000
3 year: \$70,000

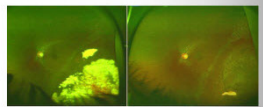
Note: Content and design are subject to review and approval by the American Academy of Ophthalmology and must comply with applicable regulatory requirements.

MYSTERY IMAGE
BLINK



WHAT IS THIS MONTH'S MYSTERY CONDITION? Join the conversation at www.aao.org/eyenet, where you can post a comment on this image.

LAST MONTH'S BLINK
Inadvertent Subretinal Triamcinolone Injection



At presentation **Two months later**

A 38-year-old phakic woman with intermediate uveitis was referred following inadvertent subretinal triamcinolone acetonide (TA) injection in her left eye. The intended injection site was the posterior sub-Tenon space. Prior to referral, her primary treating ophthalmologist had applied laser demarcation to reduce the likelihood of macular involvement by the secondary retinal detachment.

On examination, BCVA was 20/40 and intraocular pressure (IOP) was 14 mm Hg in the left eye. We did not find any retinal break. Given that the patient had received laser demarcation to prevent

macular damage, the fovea was not involved, and vision was good, we opted for observation and monitored the patient closely with serial fundus photos and OCT. The subretinal TA deposits spontaneously absorbed over a period of 2 months, and the patient had BCVA of 20/30 and IOP of 12 mm Hg at her last visit.

WRITTEN BY: Pooja Bansal, MD, Anand Gupta, MD, Reena Bansal, MD, AND PHOTOS BY: ARUN KAPIL, ADVANCED EYE CENTRE, POST GRADUATE INSTITUTE OF MEDICAL EDUCATION AND RESEARCH, CHANDIGARH, INDIA

122 • OCTOBER 2016

RESERVE YOUR SPACE

Kelly Miller • Mark Mrvica
mjmrsvica@mrsvica.com

M.J. Mrvica Associates
2 West Taunton Avenue
Berlin, New Jersey 08009
Phone: 856-768-9360
Fax: 856-753-0064