

# News in Review

COMMENTARY AND PERSPECTIVES

## Glaucoma Patients: How They See

**H**ow does the world appear through glaucomatous eyes? Nothing like the images in patient education brochures and on Internet sites, according to a team of British researchers.<sup>1</sup>

Popular belief holds that patients with advanced bilateral glaucoma see the world through a black tunnel or have black patches masking their field of view. But not one of the 50 participants in a clinic-based cross-sectional study reported seeing these effects. Rather, they reported seeing blur and missing areas.

**The study.** The participants, recruited from Moorfields Eye Hospital, had visual acuity better than 20/30 and a range of glaucomatous visual field defects in both eyes outside of normal limits on the Glaucoma Hemifield Test using the

Humphrey Field Analyzer (HFA). More than one-fifth had well-advanced visual field loss in both eyes, specifically, HFA mean deviation worse than -12 dB.

When asked to describe their visual loss, participants used words like “blur” and “missing.” They did not describe a narrowing of the peripheral visual field.

The researchers also asked participants to select one image from among six displayed on a computer monitor that corresponded to the way they see the world. All the images were of an identical outdoor scene, though five were al-



tered to simulate different ways of seeing: black tunnel, tunnel with blurred edges, black parts, blurred parts, and missing parts.

Nobody chose the black tunnel or black parts, and only 4 percent chose the blurred tunnel. Instead, 54 percent chose the image with blurred parts, and 16

percent chose the image with missing parts. Interestingly, 26 percent of the participants selected the image that was not altered, signifying that they were completely unaware of their visual loss.

Although participants had varying degrees of visual field loss, there was no

correlation between an individual's perception and clinically measured visual field. "The size and distribution of the sample wasn't broad enough to untangle any specific relationship between the type of visual field defect and reported symptoms," said David P. Crabb, PhD, professor of statistics and vision research, depart-

ment of optometry and visual science, City University of London.

**Practical application.**

The findings are relevant to the practitioner who is trying to determine whether a patient has glaucoma or correctable refractive error. "If a patient mentions a difficulty with 'blurry' vision, they should not be told that

it isn't a symptom of glaucoma," said Dr. Crabb.

The findings also suggest the need for a more realistic depiction of the disease. The researchers noted that current images may falsely reassure patients. If they don't have "tunnel vision," they may incorrectly assume that their glaucoma is under control. This could affect

adherence to treatment.

"We must make sure we depict the 'symptoms,' or lack of them, correctly," said Dr. Crabb.

—Miriam Karmel

1 Crabb DP et al. *Ophthalmology*. 2013;120(6):1120-1126.

*Dr. Crabb reports no related financial interests.*

**Cornea Update**

# A New Corneal Layer

Cornea subspecialists admitted to feeling a little sheepish this year when British researchers reported discovering what no one else had noticed: a thin, strong layer of collagen sandwiched between the posterior corneal stroma and Descemet's membrane (DM).

"One of my colleagues from Abu Dhabi told me, 'I'm not surprised that you found this layer. I'm disappointed that I didn't find it, because I see evidence of this layer's existence happening every day,'" said Harinder S. Dua, MD, PhD, professor of ophthalmology and visual sciences, University of Nottingham, United Kingdom.

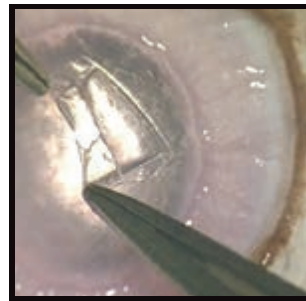
What Dr. Dua's research team found after several years of painstaking work was an airtight, acellular layer of tightly packed collagen bundles, five to eight lamellae thick, separating the deep stroma from the DM. Their findings were published online by *Ophthalmology* in May.<sup>1</sup>

Working with 31 human

corneoscleral rims (mean donor age, 77.7 years), the researchers used the "big bubble" technique of deep anterior lamellar keratoplasty (DALK) to separate the DM and deep stroma from the layer of collagen between them. It had a mean thickness of 10.15 μm (standard deviation, 3.6 μm; range, 6.3-15.83 μm), they reported. In work subsequent to publication in *Ophthalmology*, researchers have found that the layer's bursting pressure ranges from 750 to 950 mmHg, Dr. Dua said.

The researchers named it Dua's layer, "although it remains to be seen whether the name will stick," Dr. Dua said laughingly.

Reaction to the paper has fueled a de facto demonstration of the power and speed with which Internet-based collaboration "crowd sourcing" can move clinical science forward. "What has been for me the most rewarding experience has been that people from all over the world—people I don't even know—have



**NEW LAYER.** The Dua layer is visible below Descemet's membrane.

been sending me videos and slides that are confirming and extending my findings," Dr. Dua said.

The discovery of Dua's layer also is illuminating certain puzzling corneal phenomena and, in some cases, is suggesting solutions, Dr. Dua said.

**DALK.** Problem: After a big bubble procedure, occasionally aqueous bursts through the exposed DM. Explanation: When a pre-DM is formed, the much weaker DM is vulnerable to rupture. If the bubble is pre-Dua's layer, the wall is much stronger and less likely to rupture, he said. Solution: Repeated paracentesis of aqueous in the anterior chamber, to keep pressure on the DM very low during surgery, an approach Dr. Dua now is using.

**DMEK.** Problem: Sheets

of endothelial cells are difficult to handle and prepare. Solution: Include Dua's layer in the endothelial graft to stabilize the donor tissue. (This has been performed in vitro but is unconfirmed in patients.)

**Acute hydrops.** Problem: Sudden hydrops in keratoconic eyes, which has been believed to be caused by a rupture in the DM. An explanation, which is unconfirmed, said Dr. Dua: Acute hydrops occurs after rupture in both DM and Dua's layer and is associated with abnormal collagen in keratoconus.

**Corneal biomechanics.** The existence of Dua's layer raises questions about how its structure and strength influence posterior corneal shape, ocular refractive properties such as astigmatism, and biomechanical characteristics of the cornea.

—Linda Roach

1 Dua HS et al. *Ophthalmology*. 2013 May 28. [Epub ahead of print].

*Dr. Dua reports no related financial interests.*



**MORE ONLINE.** For a video showing Dua's layer, see the EyeNet home page at [www.eyenet.org](http://www.eyenet.org) after Sept. 15.

## Retina Report

## Preop IVB Benefits for PDR

A meta-analysis of eight randomized controlled trials with 394 participants appears to corroborate what physicians have observed in the clinic: Preoperative injection of intravitreal bevacizumab (IVB) reduces certain complications of vitrectomy in patients with proliferative diabetic retinopathy (PDR).<sup>1</sup>

“In our hospital, results improved with preoperative injection of bevacizumab,” said lead author Zhi-Hua Zhang, MD, department of ophthalmology, Shanghai First People’s Hospital, Shanghai, China. This prompted her to pursue a meta-analysis compar-

ing safety and functional outcomes of vitrectomy for PDR with and without preoperative IVB.

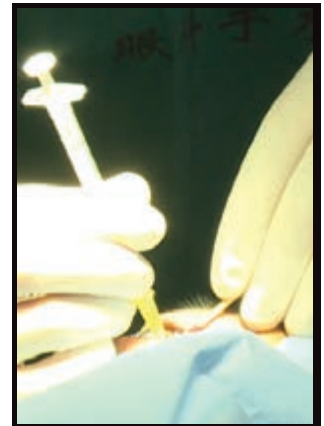
In addition to less intraoperative bleeding and a lower rate of recurrent vitreous hemorrhage within the first month of surgery, IVB pretreatment shortened overall surgical time by a mean of about 26 minutes. Less bleeding translated into easier observation and peeling of the fibrovascular membrane, possibly from shrinkage of neovascularization by IVB, Dr. Zhang said.

With the exception of iatrogenic retinal break—which occurred more fre-

quently with the vitrectomy-only group—there were no significant differences in other complication rates between the two groups. And, after the first postoperative month, the proportion of recurrent vitreous hemorrhage was also comparable between the two groups. “Lack of late significant effects in the IVB group is most likely due to washout of the drug from irrigation and suction during surgery,” said Dr. Zhang.

There were no differences in most secondary outcomes, including postoperative best-corrected visual acuity after three months. However, there was a smaller number of endodiathermy applications in the IVB group.

Given the study results, Dr. Zhang suggested that PDR patients undergoing



**PREOP PRECAUTION?** Injection of bevacizumab before vitrectomy.

vitrectomy might benefit from standardized dosage and timing of drug administration before surgery.

—Annie Stuart

1 Zhang ZH et al. *Am J Ophthalmol.* 2013;156(1):106-115.

*Dr. Zhang reports no related financial interests.*

## Cataract Surgery Update

## Trab Eyes May Yield Refractive Surprise

Determining the power of an intraocular lens (IOL) is trickier in eyes that have undergone trabeculectomy. That, at least, was the experience of Darrell WuDunn, MD, PhD, and colleagues, who had observed that patients with functioning trabeculectomy blebs tended to have more variable refractive results following cataract surgery. But why?

“Our hypothesis was that eyes with low intraocular pressures [IOP] after trab-

eculectomy that developed a significant increase in IOP would likely show a myopic refractive surprise,” said Dr. WuDunn, professor of ophthalmology, Glick Eye Institute, Indiana University, Indianapolis.

The group tested the hypothesis by retrospectively comparing eyes that underwent phacoemulsification and IOL placement at least three months post-trabeculectomy to eyes with medically controlled glaucoma or no glaucoma that

underwent the phaco/IOL procedure.<sup>1</sup>

IOP in eyes with filtering blebs increased on average from 8.7 mmHg to 10.7 mmHg following cataract surgery. These eyes also were more myopic than expected by  $-0.36$  D ( $p = 0.0004$ ). Eyes with low preoperative IOPs (less than 9 mmHg) that developed a significant postoperative jump in pressure yielded the biggest myopic refractive surprise. The authors noted that the rise in IOP may increase axial length, contributing to the unexpected refraction.

In both control groups, IOP decreased by about 2 mmHg. The nonglaucoma controls and glaucoma controls were more hyperopic, changing  $+0.23$  D

( $p = 0.035$ ) and  $+0.40$  D ( $p = 0.047$ ), respectively.

Dr. WuDunn advised surgeons who are calculating lens power for trabeculectomy patients to consider that axial length may increase after cataract surgery in eyes with low IOP. It may be useful, he added, to measure axial length of the fellow eye, provided that no trabeculectomy has been done on it. “This does require some hedging, since the increase in IOP, and presumably the increase in axial length, are somewhat unpredictable,” he said.

—Miriam Karmel

1 Zhang N et al. *Am J Ophthalmol.* 2013;155(5):858-863.

*Dr. WuDunn has received speaker honoraria from Alcon and Merck.*