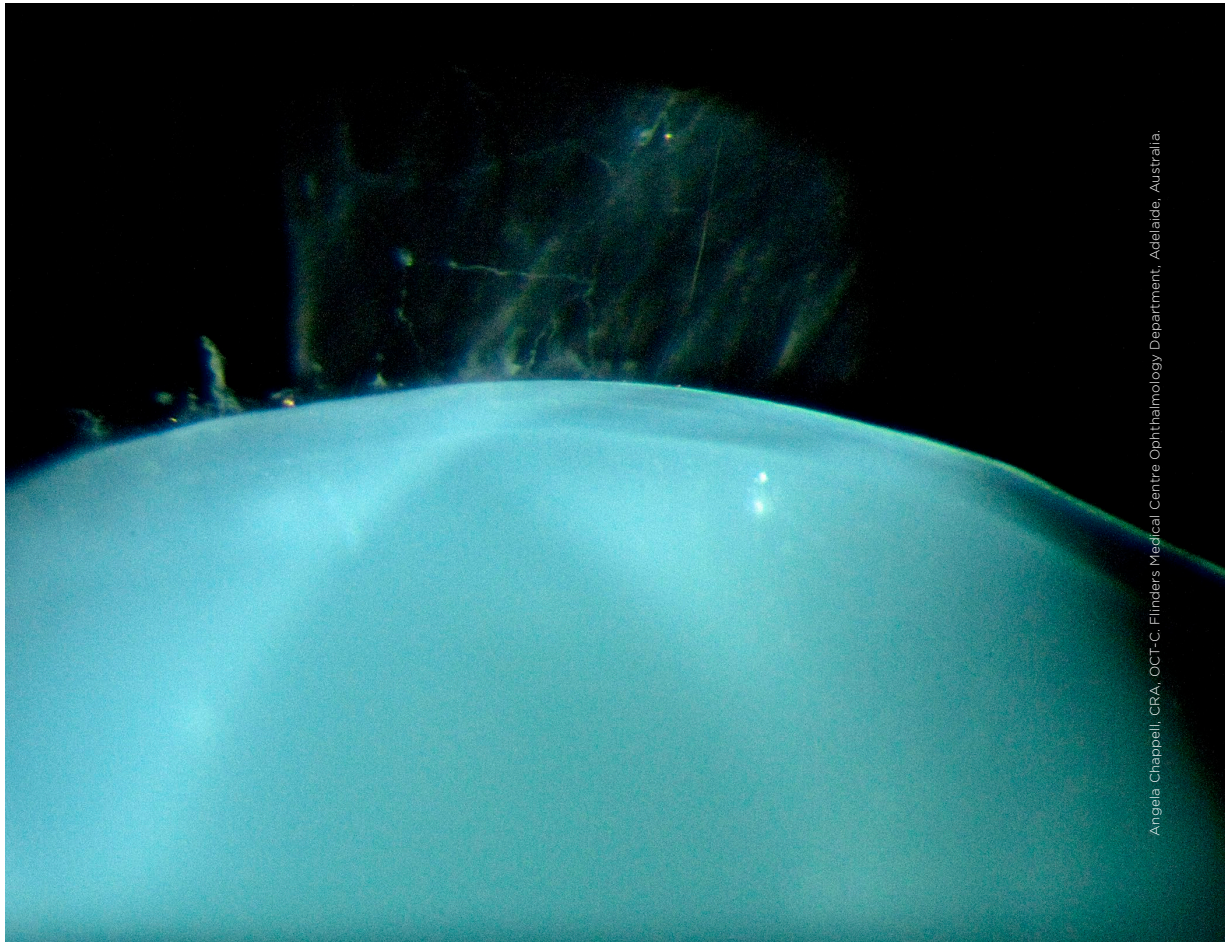


MYSTERY IMAGE

BLINK



Angela Chappell, CRA, OCT-C, Flinders Medical Centre Ophthalmology Department, Adelaide, Australia.

WHAT IS THIS MONTH'S MYSTERY CONDITION? Visit aao.org/eyenet to make your diagnosis in the comments.

LAST MONTH'S BLINK

Congenital Cataract

This patient is a member of a family that has congenital cataracts due to mutation in the *BFSP1* gene. The non-visually significant anterior and posterior sutural cataract appears in a configuration resembling the spokes of a bicycle wheel. The opacities are best seen in retroillumination during slit-lamp examination. None of the family members with such cataracts has impaired vision that requires surgical intervention.

WRITTEN BY DEEPA TARANATH, MBBS, MS, FRANZCO. PHOTO BY ANGELA CHAPPELL, CRA, OCT-C. BOTH ARE AT FLINDERS MEDICAL CENTRE OPHTHALMOLOGY DEPARTMENT, ADELAIDE, SOUTH AUSTRALIA, AUSTRALIA.

