Refractive Surgery Subspecialty Day 2021

How Can We Do Better?

Program Directors

Burkhard Dick MD and Deepinder K Dhaliwal MD

The Annual Meeting of the International Society of Refractive Surgery (ISRS)

Sponsored by the ISRS

Ernest N Morial Convention Center
New Orleans, Louisiana
Friday, Nov. 12, 2021

Presented by:
The American Academy of Ophthalmology

Refractive Surgery 2021 Planning Group
Burkhard Dick MD
Program Director

Deepinder K Dhaliwal MD LAc
Program Director

Renato Ambrósio Jr MD
Bonnie An Henderson MD
Jodhbir S Mehta MBBS PhD
J Bradley Randleman MD
George O Waring IV MD

Former Program Directors

2020 George O Waring IV MD
Burkhard Dick MD
2019 Marcony R Santhiago MD
George O Waring IV MD
2018 William B Trattler MD
Marcony R Santhiago MD
2017 Renato Ambrósio Jr MD
William B Trattler MD
2016 Bonnie A Henderson MD
Renato Ambrósio Jr MD
2015 A John Kanellopoulos MD
Bonnie A Henderson MD
2014 Sonia H Yoo MD
A John Kanellopoulos MD
2013 Michael C Knorz MD
Sonia H Yoo MD
2012 David R Hardten MD
Michael C Knorz MD
2011 Amar Agarwal MD
David R Hardten MD
2010 Ronald R Krueger MD
Amar Agarwal MD
2009 Gustavo E Tamayo MD
Ronald R Krueger MD
2008 Steven C Schallhorn MD
Gustavo E Tamayo MD
2007 Francesco Carones MD
Steven C Schallhorn MD
2006 Steven E Wilson MD
Francesco Carones MD
2005 Jorge L Alió MD PhD
Steven E Wilson MD
2004 John A Vukich MD
Jorge L Alió MD PhD
2003 Terrence P O'Brien MD
John A Vukich MD
2002 Daniel S Durrie MD
Terrence P O'Brien MD
2001 Douglas D Koch MD
Daniel S Durrie MD
2000 Richard L Lindstrom MD
Douglas D Koch MD
1999 Marguerite B McDonald MD
Richard L Lindstrom MD
1998 Peter J McDonnell MD
Marguerite B McDonald MD
1995– 1997 Peter J McDonnell MD

2021 ISRS Executive Committee
Renato Ambrósio Jr MD, President
R V Chan MD
John So-Min Chang MD
Deepinder K Dhaliwal MD LAc
Tamer Gamaly MD
Damien Gatinel MD
Angela Gutierrez MD
Soosan Jacob MS
Jodhbir S Mehta MD
Zoltan Nagy MD
J Bradley Randleman MD
David Smadja MD
Sonia H Yoo MD

Subspecialty Day Advisory Committee
R Michael Siatkowski MD
Chair

Bonnie An Henderson MD
Michael S Lee MD
Jennifer Irene Lim MD
Shahzad I Mian MD
Jody R Piltz MD

Maria M Aaron MD
Secretary for Annual Meeting

Staff
Melanie R Rafaty CMP, *Director, Scientific Meetings*
Ann L'Estrange, *Subspecialty Day Manager*
Debra Rosencrance CMP CAE, *Vice President, Meetings & Exhibits*
Patricia Heinicke Jr, *Copy Editor*
Mark Ong, *Designer*
Gina Comaduran, *Cover Design*

2021 Refractive Surgery Subspecialty Day Planning Group

On behalf of the American Academy of Ophthalmology and the International Society of Refractive Surgery, it is our pleasure to welcome you to New Orleans and **Refractive Surgery 2021: How Can We Do Better?**

Burkhard Dick MD
Program Director

Avedro, Inc.: C
Bausch + Lomb: L
Johnson & Johnson Vision: C
Johnson & Johnson: L
Oculus Surgical, Inc.: P
RxSight, Inc.: C

Deepinder K Dhaliwal MD LAc
Program Director

Allergan, Inc.: C
Avedro, Inc.: S
Haag-Streit Group: C
Horizon: C
Johnson & Johnson: C
Novartis: C,S
Noveome: S
Ocular Therapeutix: L,C
Staar Surgical: L
Trefoil: C

Renato Ambrósio Jr MD
Alcon Laboratories, Inc.: C
Allergan: L
Carl Zeiss, Inc.: L
Essilor Instruments: L
Genom: C
Mediphacos: L
Oculus, Inc.: C

Bonnie An Henderson MD
Alcon Laboratories, Inc.: C,L

Jodhbir S Mehta MBBS PhD
None

J Bradley Randleman MD
None

George O Waring IV MD
ACE Vision: C
Allergan: C,L
Avedro: C,L
Bausch + Lomb: C,L
Glaukos Corp.: C,L
Johnson & Johnson Vision: C,L
Novartis: C
Oculus, Inc.: C,L
Omega Ophthalmics: C
Omeros: C
Perfect Lens, LLC: C
SRD Vision: C
Strathspey Crown: O
Visiometrics: C,O
Zepto: C

2021 Subspecialty Day Advisory Committee

R Michael Siatkowski MD, Chair (Pediatric Ophthalmology)
National Eye Institute: S
OMIC-Ophthalmic Mutual Insurance Company: C

Maria M Aaron MD (Secretary for Annual Meeting)
None

Bonnie An Henderson MD (Refractive Surgery)
Alcon Laboratories, Inc.: C,L

Michael S Lee MD (Neuro-Ophthalmology)
Horizon: O
Springer: P
Sun Biopharma: C
UpToDate: P

Jennifer Irene Lim MD (Retina)
Aldeyra Therapeutics: S
Allergan, Inc.: C
Aura Biosciences: C
Chengdu Kanghong: S
Cognition Therapeutics: C
CRC Press/Taylor and Francis: P
Eyenuk: C
Genentech: C,S
Greybug: S
Iveric Bio: C
JAMA Ophthalmology Editorial Board: C
Luxa: C
NGM: S
Novartis Pharma AG: C
Ophthea: C
Quark: C
Regeneron Pharmaceuticals, Inc.: S,C
Santen, Inc.: C
Stealth: S
Unity: C
Viridian: C

Shahzad I Mian MD (Cornea)
Centrasight: S
Kowa American Corp.: S
National Eye Institute: S

Jody R Piltz MD (Glaucoma)
Aerie Pharmaceuticals: C,L,S

AAO Staff

Ann L'Estrange
None

Melanie Rafaty
None

Debra Rosencrance
None

Beth Wilson
None

Refractive Surgery 2021 Contents

CME Credit

The Academy's CME Mission Statement

The purpose of the American Academy of Ophthalmology's Continuing Medical Education (CME) program is to present ophthalmologists with the highest quality lifelong learning opportunities that promote improvement and change in physician practices, performance, or competence, thus enabling such physicians to maintain or improve the competence and professional performance needed to provide the best possible eye care for their patients.

2021 Refractive Surgery Subspecialty Day Meeting Learning Objectives

Upon completion of this activity, participants should be able to:

- Evaluate the latest techniques and technologies in refractive surgery
- Identify the current status and future of femtosecond laser, excimer laser, phakic IOL, and IOL refractive surgery
- Compare the pros and cons of various lens- and corneal-based modalities, including presbyopic and toric IOLs
- Describe the increasing importance of refractive surgery in any ophthalmology practice and the reasons to consider this subspecialty to improve patient care
- Explain complication avoidance, identification, and management in cornea- and lens-based surgery

2021 Refractive Surgery Subspecialty Day Meeting Target Audience

The intended audience for this program is comprehensive ophthalmologists; refractive, cataract, and corneal surgeons; and allied health personnel who are performing or assisting in refractive surgery.

Teaching at a Live Activity

Teaching instruction courses or delivering a scientific paper or poster is not an *AMA PRA Category 1 Credit*™ activity and should not be included when calculating your total *AMA PRA Category 1 Credits*™. Presenters may claim *AMA PRA Category 1 Credits*™ through the American Medical Association. To obtain an application form, please contact the AMA at www.ama-assn.org.

Scientific Integrity and Disclosure of Conflicts of Interest

The American Academy of Ophthalmology is committed to ensuring that all CME information is based on the application of research findings and the implementation of evidence-based medicine. It seeks to promote balance, objectivity, and absence of commercial bias in its content. All persons in a position to control the content of this activity must disclose any and all financial interests. The Academy has mechanisms in place to resolve all conflicts of interest prior to an educational activity being delivered to the learners.

Control of Content

The Academy considers presenting authors, not coauthors, to be in control of the educational content. It is Academy policy and traditional scientific publishing and professional courtesy to acknowledge all people contributing to the research, regardless of CME control of the live presentation of that content. This acknowledgment is made in a similar way in other Academy CME activities. Though coauthors are acknowledged, they do not have control of the CME content, and their disclosures are not published or resolved.

2021 Subspecialty Day CME Credit

The American Academy of Ophthalmology is accredited by the Accreditation Council for Continuing Medical Education (ACCME) to provide continuing medical education for physicians.

Friday Subspecialty Day Activity: Glaucoma, Neuro-Ophthalmology, Pediatric Ophthalmology, Refractive Surgery, and Retina (Day 1)

The Academy designates this Other (blended live and enduring material) activity for a maximum of *12 AMA PRA Category 1 Credits*™. Physicians should claim only the credit commensurate with the extent of their participation in the activity.

Saturday Subspecialty Day Activity: Cornea, Oculofacial Plastic Surgery, and Retina (Day 2)

The Academy designates this Other (blended live and enduring material) activity for a maximum of *12 AMA PRA Category 1 Credits*™. Physicians should claim only the credit commensurate with the extent of their participation in the activity.

Physicians registered as In Person and Virtual are eligible to claim the above CME credit.

How to Claim CME

Attendees can claim credits online.

For AAO 2021, you can claim CME credit multiple times, up to the 50-credit maximum, through Aug. 1, 2022. You can claim some in 2021 and some in 2022, or all in the same year.

For 2021 Subspecialty Day, you can claim CME credit multiple times, up to the 12-credit maximum per day, through Aug. 1, 2022. You can claim some in 2021 and some in 2022, or all in the same year.

You do not need to track which sessions you attend, just the total number of hours you spend in sessions for each claim.

Academy Members

CME transcripts that include AAOE Half-Day Coding Sessions, Subspecialty Day and/or AAO 2021 credits will be available to

Academy members through the Academy's CME Central web page.

The Academy transcript cannot list individual course attendance. It will list only the overall credits claimed for educational activities at AAOE Half-Day Coding Sessions, Subspecialty Day and/or AAO 2021.

Nonmembers

The Academy provides nonmembers with verification of credits earned and reported for a single Academy-sponsored CME activity.

Proof of Attendance

You will be able to obtain a CME credit reporting/ proof-of-attendance letter for reimbursement or hospital privileges, or for nonmembers who need it to report CME credit:

Academy Members

When you claim CME credits and complete the evaluation, you will be able to print a certificate/proof of attendance letter from your transcript page. Your certificate will also be emailed to you.

Nonmembers

When you claim CME credits and complete the evaluation, a new browser window will open with a PDF of your certificate. Please disable your pop-up blocker. Your certificate will also be emailed to you.

CME Questions

Send your questions about CME credit reporting to cme@aao.org.

For Continuing Certification questions, contact the American Board of Ophthalmology at MOC@abpo.org.

2021 Award Winners

Jose I Barraquer Lecture and Award

The Jose I Barraquer Lecture and Award honors a physician who has made significant contributions in the field of refractive surgery during his or her career. This individual exemplifies the character and scientific dedication of Jose I Barraquer MD—one of the founding fathers of refractive surgery.

Jose I Barraquer Lecture and Award—Steven E Wilson MD

Steven E Wilson MD

Steven E Wilson MD received a BA from California State University, Fullerton; an MS in molecular biology and biochemistry from the University of California, Irvine; and his MD from UC San Diego in 1984. He completed his ophthalmology residency at the Mayo Clinic in Rochester, Minnesota, in 1988 and was a fellow in cornea and refractive surgery at Louisiana State University Eye Center in New Orleans from 1988 to 1990. Dr. Wilson was assistant/associate professor at the University of Texas Southwestern in Dallas from 1990 to 1995. He was medical director of refractive surgery at the Cleveland Clinic from 1995 to 1998. From 1998 to 2003, he was chair of ophthalmology at University of Washington in Seattle. Since 2003 he's been professor of ophthalmology, staff refractive and corneal surgeon, and director of corneal research at the Cleveland Clinic.

Dr. Wilson's laboratory focuses on cellular and molecular interactions involved in corneal wound healing and has been funded by NEI from 1992 to 2021. Dr. Wilson has authored more than 250 peer-reviewed medical and scientific publications. He has received numerous other awards, including the Lans Distinguished Lecturer Award from the International Society of Refractive Surgery (ISRS)–American Academy of Ophthalmology in 2006, ARVO Gold Fellow in 2009, Lifetime Presidential Award from ISRS-AAO in 2009, the Richard L Lindstrom Contact Lens Association of Ophthalmologists Award Lecture at the American Society of Cataract and Refractive Surgery meeting in 2013, and an ISRS 2018 Recognition Award. He was ARVO cornea trustee from 2001 to 2006 and served on the ISRS Executive Board from 1999 to 2008. Wilson has published four adventure-thriller novels, most recently *The Benghazi Affair* in 2018, and his nonfiction memoir, *The Making, Breaking and Renewal of a Surgeon-Scientist*, in 2019, which was a Benjamin Franklin Award Audiobook of the Year Silver Awardee for 2020.

Casebeer Award

The Casebeer Award recognizes an individual for his or her outstanding contributions to refractive surgery through nontraditional research and development activities.

Casebeer Award—Jodhbir S Mehta MBBS PhD

Jodhbir S Mehta
MBBS PhD

Dr. Jodhbir S Mehta is head of the Corneal Service Singapore National Eye Center (SNEC), head of the Tissue Engineering and Cell therapy group at the Singapore Eye Research Institute, and professor at DUKE-NUS Medical School. He was named Professor of Clinical Innovation at SNEC/Singapore Eye Research Institute (SERI), where he is also director of Education, Singhealth Transplant, and deputy executive director.

Dr. Mehta has published over 380 peer-reviewed papers and 20 book chapters (current h-index, 51; citations, 9140). He has given over 250 invited plenary, symposium, and named lectures globally, with over 50 national and international awards. His research work has generated 15 patents, 5 of which have been licensed to companies. He has trained 26 international fellows, 5 masters students, and 8 PhD students. He leads a clinical service and runs a research program comprising clinical and translational studies. His work is focused on corneal transplantation, femtosecond laser technology, corneal imaging, corneal infections, corneal refractive surgery, keratoprosthesis surgery, and corneal genetics.

Founders' Award

The Founders' Award recognizes the vision and spirit of the Society's founders by honoring an ISRS member who has made extraordinary contributions to the growth and advancement of the Society and its mission.

Founders' Award—Andrzej Grzybowski MD PhD MBA

Andrzej Grzybowski MD PhD MBA

Andrzej Grzybowski MD PhD MBA is a professor of ophthalmology and chair of the Department of Ophthalmology, University of Warmia and Mazury, Olsztyn, Poland, and head of the Institute for Research in Ophthalmology, Foundation for Ophthalmology Development, Poznan, Poland.

He is active in international scientific societies including the American Academy of Ophthalmology (International Fellow; member of the Global ONE Advisory Board, Museum of Vision's Program Committee, and Task Force on Myopia), International Society of Refractive Surgery (member of the ISRS International Council), European Association for Vision and Eye Research (board member and chair of cataract section), European Society of Cataract and Refractive Surgeons (co-curator of ESCRS Archive), International Council of Ophthalmology (program coordinator for WCO in 2011-2018), and Cogan Society. He is a lifelong member (chair LIV) of the European Academy of Ophthalmology and its treasurer.

Dr. Grzybowski was awarded with the Knight's Cross of the Order of Polonia Restituta (by the president of Poland, 2014), honorary membership in the Association of Community Ophthalmologists of India (2015), Intraocular Implant & Refractive Surgery Society, India, Special Gold Medal (2016), the Academy's Achievement Award (2017), the Publons Peer Review Award (2017), the Academy's International Scholar Award (2018), the Asia-Pacific Academy of Ophthalmology Achievement Award (2018), and honorary membership in the Romanian Glaucoma Society (2018).

Dr. Grzybowski has been active editor, editor in chief, and author of more than 550 peer-reviewed international publications (total impact factor [IF] higher than 1000) and over 50 book chapters and reviewer for more than 20 journals. He is a member of the editorial boards of the *American Journal of Ophthalmology* (IF 4.795), *Acta Ophthalmologica* (IF 3.1), *PLOS One* (IF 2.8), *Graefe's Archive for Clinical and Experimental Ophthalmology* (IF 2,3), *Translational Vision Science & Technology* (TVST) (IF 2.2), *BMC Ophthalmology* (IF 1.5), *Clinics in Dermatology* (IF 2.2), *Journal of Clinical Medicine* (IF 5.8), *Current Pharmaceutical Design* (IF 2.4), *Frontiers in Neurology* (IF 3.5), *Saudi Journal of Ophthalmology*, *Asia Pacific Academy of Ophthalmology Journal*, *Annals of Eye Science*, *Open Ophthalmology Journal*, *Medicines*, and *Ophthalmology and Therapy* and editor in chief of *Archives of the History and Philosophy of Medicine* and *Historia Ophthalmologica Internationalis* (www.histoph.com). He is editor and coauthor of several books, including *Endophthalmitis in Clinical Practice* (Springer 2018), *Current Concepts in Ophthalmology* (Springer, 2019), *OCT and Imaging in Central Nervous System Diseases* (Springer 2020).

Kritzinger Memorial Award

The Kritzinger Memorial Award recognizes an individual who embodies the clinical, educational, and investigative qualities of Dr. Michiel Kritzinger, who advanced the international practice of refractive surgery.

Kritzinger Award—Arthur Cummings FCS(SA) FRCSEd MMed MBChB

Arthur Cummings FCS(SA) FRCSEd MMed MBChB

Arthur Cummings was born and trained in South Africa but since 1998 practices as a cataract and refractive surgeon at the Wellington Eye Clinic in Dublin, Ireland. Arthur is involved in clinical studies as investigator and serves on the medical advisory boards of more than 10 ophthalmic companies. He is a past-president of the American-European Congress of Ophthalmic Surgery Europe and the global ambassador of the Refractive Surgery Alliance, a group dedicated to growing refractive surgery through collaboration. He serves as associate chief medical editor of *Cataract & Refractive Surgery Today Europe* and is a reviewer for numerous journals, including *Journal of Refractive Surgery* and *Journal of Cataract and Refractive Surgery*.

Arthur has published more than 120 articles in peer-reviewed and trade journals and 12 book chapters, coedited two textbooks, and delivered more than 450 lectures at international meetings. He authored the Wellington nomogram that is used by WaveLight users worldwide. In 2018 he was ranked in the Top 100 most influential ophthalmologists worldwide by readers of *The Ophthalmologist*. In both 2019 and 2020 he was ranked in the Top 100 Ophthalmologists and among the Top 10 Emerging Leaders in Ophthalmology globally by the same publication. He was appointed to the Board of Directors of Alcon, Inc. in April 2019, when Alcon was spun off from Novartis. He has been married to Sandy for 34 years and they have two sons.

Lans Distinguished Lecturer Award

The Lans Distinguished Lecturer Award honors Dr. Leendert J Lans. Given annually, the award recognizes individuals who have made innovative contributions in the field of refractive surgery, especially in the correction of astigmatism.

Lans Distinguished Lecturer Award—John Berdahl MD

John Berdahl MD

Practicing in Sioux Falls, South Dakota, is board-certified ophthalmologist, John Berdahl MD, widely regarded as one of the world's leading international cataract surgeons. He is one of the very few surgeons in the United States who is also fellowship trained in cornea, glaucoma, and refractive surgery. Dr. Berdahl has already performed more than 25,000 eye surgeries around the globe. His published work has primarily focused on the fundamental causes of glaucoma, minimally invasive glaucoma surgery, and astigmatism management during and after cataract surgery.

Dr. Berdahl has been involved in numerous FDA-monitored clinical trials on some of the most exciting technologies in ophthalmology. He also founded Equinox, which is developing the first nonsurgical, nonpharmacologic way to lower eye pressure for glaucoma treatment. He coinvented the MKO Melt, which provides sedation during cataract surgery without the use of an IV. Additionally, he created astigmatismfix.com, which helps thousands of surgeons per month fix residual astigmatism after cataract surgery. Finally, in an effort to improve access to care, he cofounded ExpertOpinion.MD, which provides online opinions to patients from top doctors around the world.

Although Dr. Berdahl has many accomplishments, his primary driver is the trust that people place in him, as he meets his patients in their moments of vulnerability and puts their needs first. His commitment to the underserved is demonstrated by his leadership in EyeCare America, as well as in the Mission Vision program at Vance Thompson Vision, where he performs dozens of free surgeries every year. Dr. Berdahl also continues to serve the impoverished on mission trips worldwide.

Lifetime Achievement Award

The Lifetime Achievement Award honors an ISRS member who has made significant and internationally recognized contributions to the advancement of refractive surgery over his or her career.

Lifetime Achievement Award—Paolo Vinciguerra MD

Paolo Vinciguerra MD

Paolo Vinciguerra MD is a professor in Ophthalmology at Humanitas University, as well as chairman of the Eye Center of Humanitas Clinical and Research Center, Rozzano, Milan, Italy. He is the president of the Italian Society of Cataract and Refractive Surgery, and since 2003 he is also an advisor for the Italian Ministry of Health. He is part of the Editorial Board of the *Journal of Refractive Surgery* and board director of numerous national and international societies.

Dr. Vinciguerra's research interests range from cataract surgery with femtosecond laser to corneal biomechanics, corneal collagen crosslinking, phototherapeutic keratectomy, customized refractive surgery with novel treatment profiles and models of regression after the ablation, corneal transplant and vitreoretinal surgery. Dr. Vinciguerra has developed many innovative techniques, such as smoothing after therapeutic refractive surgery, crosscylinder ablation, and custom ablation transition zone (CATZ). He is one of the most productive researchers in the treatment of keratoconus with crosslinking, in the evaluation of corneal biomechanics, and in therapeutic and refractive laser surgery.

Among other recognitions, Dr. Vinciguerra received the Lans Award from the International Society of Refractive Surgery (ISRS) in 2003, the Senior Achievement Award from the American Academy of Ophthalmology in 2010, the Waring Medal Award in 2011 from the ISRS, and the Italian Ophthalmological Society's Gold Frezzotti medal.

Dr. Vinciguerra is the author of 159 original scientific articles, he has received 8 best-paper awards in international meetings, and his work has been cited more than 2600 times, with an h-index of 26. He is holder of 7 international patents.

Presidential Recognition Award

The Presidential Recognition Award is a special award that honors the recipient's dedication and contributions to the field of refractive surgery and to the ISRS.

Presidential Recognition Award—Dr. Tadeu Cvintal

Dr. Tadeu Cvintal

Tadeu Cvintal, ophthalmologist for the past 55 years, is based in São Paulo, Brazil, where he has worked to settle the pillars of modern ophthalmology as then taught in America.

Graduated from Universidade Federal do Paraná, Brazil, he went to the United States to pursue his specialization. In 1964 he became a fellow from the American Academy of Ophthalmology after completing his residency program at Harlem Eye and Ear Hospital, New York, and his Retina Fellowship at Boston City Hospital and becoming the first cornea fellow at Wills Eye Hospital, Philadelphia.

Back in Brazil, he became director of the Ophthalmology Department at the State Hospital in São Paulo, where he created the first ophthalmology residency program in the country.

In his private practice he introduced and popularized many innovations, such as keratoplasties, extracapsular cataract extraction, IOL implantation, radial keratotomy, and LASIK. In 1990 his laser center introduced LASIK in Brazil, where he trained many surgeons from Brazil and the United States.

Dr. Cvintal created the Eye Bank of São Paulo, the first in Brazil, and was cofounder of the Brazilian Cataract and Intraocular Lens Society, the Brazilian Refractive Society, and the Brazilian Contact Lens Society.

He settled his own Philanthropic Institution, where he trained over 390 residents and fellows who took care of over 180,000 patients, free of charge, over these last 50 years. Dr. Cvintal has delivered over 900 lectures worldwide and published a book, *Complications After Corneal Transplants* (2004).

Presently, in his private practice, where he has seen over 120,000 patients, he shares his days of work with his wife, Maria, who runs the place, his son, Victor, who is an anterior segment surgeon, and several colleagues. He has three granddaughters, from Aldo, who are trying to teach him TikTok.

Presidential Recognition Award

The Presidential Recognition Award is a special award that honors the recipient's dedication and contributions to the field of refractive surgery and to the ISRS.

Presidential Recognition Award—Dan Z Reinstein MD



Dan Z Reinstein MD

Professor Dan Z Reinstein is the founder and medical director of the London Vision Clinic and holds professorships at Columbia University Irving Medical Center, New York; Ulster University, UK; and Sorbonne University, France. He has been lead refractive surgery consultant for Carl Zeiss Meditec since 2001, created their EDoF Presbyond® Laser Blended Vision treatment module for presbyopia, and was a key investigator in developing SMILE. He was the first to develop corneal epithelial mapping and bring this to both keratoconus screening and the extensive applications in therapeutic refractive surgery.

Professor Reinstein's textbook *The Surgeon's Guide to SMILE* was published in April 2018. He is editor for the Therapeutic Refractive Surgery section of the *Journal of Refractive Surgery* and has published over 175 peer-reviewed papers, a majority in the area of corneal imaging and biometry with OCT and very high-frequency digital ultrasound scanning using the Artemis Insight 100 technology, which he coinvented while at Cornell University in the early 1990s. He was awarded the Waring Medal in 2006 and the Kritzinger Award in 2013.

29th Annual Richard C Troutman MD DSc (Hon) Prize

The Troutman Prize recognizes the scientific merit of a young author publishing in the *Journal of Refractive Surgery*. This prize honors Richard C Troutman MD DSc (Hon).

Richard C Troutman MD DSc (Hon) Prize—Pooja Khamar MBBS FRCS PhD

Pooja Khamar MBBS FRCS PhD

Dr. Pooja Khamar is currently employed as a consultant and lead trainer in cataract and refractive services at Narayana Nethralaya Eye Institute. In addition to her clinical role, she is actively working as a clinical and translational scientist at GROW Lab (Genes, Repair & Regeneration in Ophthalmic Workstation) and IBMS (Imaging Biomechanics and Mathematical Modelling Solutions). She defended her PhD dissertation, "Wound Healing in Refractive Surgery," at Maastricht University, The Netherlands, in November 2019.

Dr. Khamar's areas of interest include cataract and refractive surgery, specifically comparing and understanding the outcomes of refractive surgery and keratoconus disease from a molecular and imaging (tomography and biomechanics) perspective; areas of phakic IOLs; customized lasers; optics; and dry eye.

With a keen interest in connecting bench to clinic, Dr. Khamar's passion is to bridge the gap between basic science and clinical medicine and ultimately improve the quality of life for patients. Being a dynamic personality and a hard worker, she works to give back her acumen to society. She has numerous research publications in peer-reviewed journals and has been an invited faculty at conferences across the globe. She has been a recipient of awards at national and international podia.

My Belief as a Clinician and a Translational Scientist

Translational research is not for the faint-hearted. The constant churning of teaching, researching, publishing, and competing for limited sources of funding—coupled with pursuing career aims and ambitions—can seem challenging. It is also a deeply satisfying and exhilarating endeavour, especially when the fruits of the experimental laboratory are translated into improved health-care delivery to our patients.

Translational research has a central and pivotal role in harnessing significant discoveries in biomedical science for the benefit of our patients. To the sceptics who ask, "Where is the evidence that translational research matters?" we would answer, "As with Sir Christopher Wren's monuments, the evidence is all around us."

"If you want something you never had, then you have to do something that you have never done."

30th Annual Richard C Troutman MD DSc (Hon) Prize

The Troutman Prize recognizes the scientific merit of a young author publishing in the Journal of Refractive Surgery. This prize honors Richard C Troutman MD DSc (Hon).

Richard C Troutman MD DSc (Hon) Prize—Min Li MD

Min Li MD

Dr. Min Li is a key member of the Optometry Center and the Refractive Surgery Centre of Shanghai Tenth People's Hospital. Since 2015, she has been an attending ophthalmologist at the Hospital as an expert in refractive surgery including LASEK, FS-LASIK, SMILE and Phakic Intraocular Lens.

Dr. Li's topics of research include corneal wound healing and the influence factors after refractive surgery; the visual conducting pathway changes and the visual quality after refractive surgery; the reuse of the refractive lenticules from SMILE; and myopia prevention and control in school children.

Dr. Li has written more than 10 publications in SCI International peer review journals. In addition, she has given talks at the ophthalmology conference of the Chinese Medical Association and scientific meetings in China.

Waring Memorial Award for a Young Ophthalmologist

The Waring Memorial Award for a Young Ophthalmologist recognizes an ISRS member early in his/her career who has demonstrated a commitment to ISRS, as well as a commitment to the promulgation of knowledge and the practice of refractive surgery. This award honors George O Waring III MD for his commitment to the profession and to ISRS.

Waring Memorial Award—Fernando Faria-Correia MD

Fernando Faria-Correia MD

Dr. Faria-Correia received his medical degree from the Faculdade de Medicina da Universidade do Porto in 2007, followed by an ophthalmology residency training in Centro Hospitalar São João, Porto, Portugal. In 2012, he completed a corneal and refractive surgery fellowship led by Dr. Renato Ambrósio Jr. at Instituto de Olhos Renato Ambrósio and Visare Rio (Rio de Janeiro, Brazil). In 2013, Dr. Faria-Correia completed another fellowship in cataract and refractive surgery led by Dr. George O. Waring IV at Medical University of South Carolina, Storm Eye Institute (Charleston, South Carolina, USA).

Dr. Faria-Correia joined the Cataract, Cornea and Refractive Surgery Department of Hospital de Braga (Braga, Portugal) and Instituto CUF Porto (Porto, Portugal) in 2014. Since 2015, he also serves as assistant professor of ophthalmology at the Escola de Medicina da Universidade do Minho (Braga, Portugal).

Besides having a busy clinical practice, Dr. Faria-Correia is active in clinical research and integrates the activities of the Rio de Janeiro Corneal Tomography and Biomechanics Study Group. He has published more than 100 scientific works, including peer-reviewed publications, book chapters, and abstracts in scientific society meetings. In 2017, Dr. Faria-Correia defended his doctoral thesis in medicine, entitled "Scheimpflug-based lens densitometry for preoperative assessment of age-related nuclear cataracts." He also obtained the title of Fellow of the European Board of Ophthalmology – Specialist Diploma in Cataract and Refractive Surgery (FEBOS-CR) in 2018. During 2019, he completed the Physician CEO course at Kellogg School of Management at Northwestern University (Evanston, Illinois, USA).

Miradas Award

"Miradas" which means glances, is a contest in which artists from Spain, Latin America and the USA participate with artworks dealing with the topic of sight and the prevention of blindness. It was created by Jorge Alio in 1998 with the intention of using artistic sensibility to bring society's attention to the phenomenon of sight, vision and blindness and is sponsored by Mediphacos, Brazil. Selected paintings from the contest are featured on the cover page of the *Journal of Refractive Surgery*.

Please recognize the recipient of the Miradas Award – Natividad Pamies Diez.

Natividad Pamies Diez

Faculty

Amar Agarwal MD
Chennai, India

Renato Ambrósio Jr MD
Rio de Janeiro, RJ, Brazil

Shady T Awwad MD
Riad El Solh, Beirut, Lebanon

Ashvin Agarwal MD
Chennai, India

Robert Edward T Ang MD
Makati City, Philippines

Francesco Carones MD
Milan, Italy

Jorge L Alio MD PhD
Alicante, Spain

Gerd U Auffarth MD
Heidelberg, Germany

Lorenzo J Cervantes MD
Shelton, CT



David F Chang MD
Los Altos, CA

John F Doane MD
Leawood, KS

Nicole R Fram MD
Los Angeles, CA

Steven J Dell MD
Austin, TX

Eric D Donnenfeld MD
Garden City, NY

Ronald D Gerste MD
North Potomac, MD

Deepinder K Dhaliwal MD LAc
Pittsburgh, PA

Farideh Doroodgar MD
Tehran, Iran

Andrzej Grzybowski MD
Poznan, Poland

Burkhard Dick MD
Bochum, Germany

Daniel S Durrie MD
Kansas City, MO

Bonnie An Henderson MD
Waltham, MA

Luis Izquierdo Jr MD
Lima, Peru

Thomas Kohnen MD PhD FEBO
Frankfurt, Germany

Jennifer M Loh MD
Miami, FL

Omid Kermani MD
Koln, Germany

Min Li MD
Shanghai, China

Stephanie Jones Marioneaux MD
Chesapeake, VA

Pooja Khamar MBBS MS
Bengaluru, India

Richard L Lindstrom MD
Wayzata, MN

Jim V Mazzo
Laguna Beach, CA

Michael C Knorz MD
Mannheim, Germany

William Link PhD
Newport Beach, CA

Erik L Mertens MD FRACOphth
Antwerp, Belgium

Majid Moshirfar MD
Draper, UT



Dan Z Reinstein MD
London, England

No photo available

Theo Seiler MD PhD
Zurich, Switzerland

Priya Narang MS
Ahmedabad, India

Karolinne M Rocha MD
Mount Pleasant, SC

Rohit Shetty MBBS
Bangalore, India

No photo available

Rudy Nuijts MD
Maastricht, Netherlands

Marcony R Santhiago MD
Rio de Janeiro, Brazil



Priyanka Sood MD
Atlanta, GA

J Bradley Randleman MD
Cleveland, OH

Julie M Schallhorn MD
San Francisco, CA

No photo available

Zeba A Syed MD
Philadelphia, PA

Vance Michael Thompson MD
Sioux Falls, SD

George O Waring IV MD
Mount Pleasant, SC

Elizabeth Yeu MD
Norfolk, VA

William B Trattler MD
Miami, FL

Liliana Werner MD PhD
Salt Lake City, UT

Sonia H Yoo MD
Miami, FL

Ask a Question Live During the Meeting Using the Mobile Meeting Guide

To submit an answer to a poll or ask the moderator a question during the meeting, follow the directions below.

- Access at www.aao.org/mobile
- Select "Program," "Handouts & Evals"
- Filter by meeting: Refractive Surgery Meeting
- Select "Current Session"
- Select "Interact with this session (live)" link to open a new window
- Choose "Ask a Question"

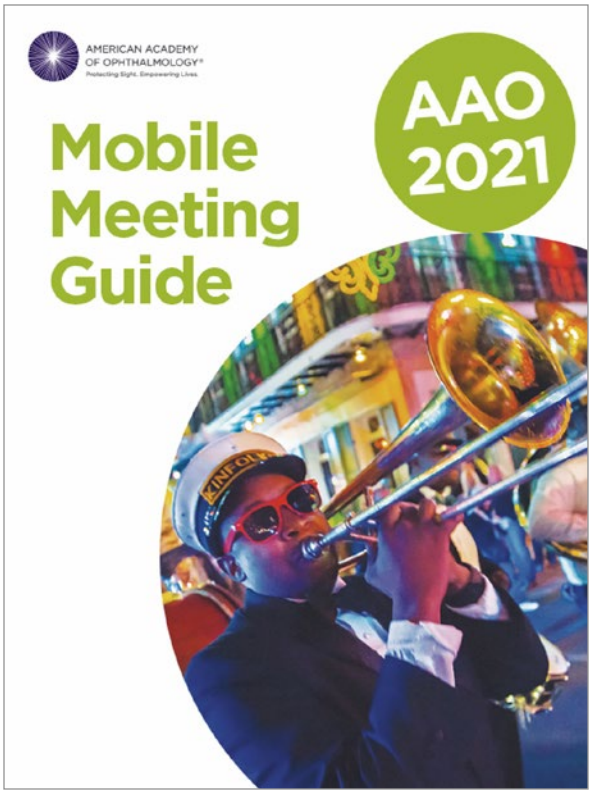

Refractive Surgery Subspecialty Day 2021: How Can We Do Better?

The Annual Meeting of the International Society of Refractive Surgery

Sponsored by the ISRS

FRIDAY, NOV. 12, 2021

7:00 AM	CONTINENTAL BREAKFAST		
8:00 AM	Welcome and Introductions	Burkhard Dick MD* Deepinder K Dhaliwal MD LAc*	

Keynote Lecture I

	Morning Session Virtual Moderator: Robert Edward T Ang MD		
8:04 AM	Introduction	Deepinder K Dhaliwal MD LAc*	
8:06 AM	State of the Union—Laser Vision Correction	Daniel S Durrie MD*	1
8:16 AM	Discussion		

Section I: Refractive Surgery Update

Moderator: Burkhard Dick MD*

Panelists: Lorenzo J Cervantes MD*, Nicole R Fram MD*, and Priyanka Sood MD*

8:21 AM	Introduction	Burkhard Dick MD*	
8:23 AM	'Tis the Time's Plague	Ronald D Gerste MD	2
8:33 AM	Introduction	Burkhard Dick MD*	
8:35 AM	Building on New Interest in Refractive Surgery and How to Keep Momentum Going	Michael C Knorz MD*	3
8:45 AM	Discussion		

Section II: Laser Vision Correction

Moderator: Sonia H Yoo MD*

8:55 AM	Therapeutic Custom Ablation: My Pearls	Dan Z Reinstein MD*	4
9:01 AM	PRK in KC	Renato Ambrosio Jr MD*	6
9:07 AM	LASIK	Karolinne M Rocha MD*	11
9:13 AM	SMILE	John F Doane MD*	12
9:19 AM	Discussion		

Section III: Phakic Lens Surgery

Moderator: George O Waring IV MD*

9:34 AM	Presbyopia Correction With Refractive IOLs: Pearls and Pitfalls	William B Trattler MD*	17
9:40 AM	Presbyopia Correction in the Plano Presbyope	Francesco Carones MD*	21
9:46 AM	Presbyopia Correction in the High Myope	Erik L Mertens MD FRACOphth*	22
9:52 AM	Surgical Management of the Pre-presbyopic High Hyperope	Steven J Dell MD*	23

* Indicates that the presenter has financial interest. No asterisk indicates that the presenter has no financial interest.

9:58 AM	Discussion		
10:13 AM	In These Unprecedented Times . . .	Stephanie Jones Marioneaux MD	24
10:18 AM	REFRESHMENT BREAK		

ISRS Awards

10:48 AM	ISRS Awards	Renato Ambrósio Jr MD*	

Keynote Lecture II

10:58 AM	Introduction	Burkhard Dick MD*	
11:00 AM	State of the Union—Thoughts on the Future of Refractive Lens Surgery and IOL Implants	Richard L Lindstrom MD*	26
11:10 AM	Discussion		

Section IV: *JRS*—Hot, Hotter, Hottest Late Breaking News

Moderator: J Bradley Randleman MD

11:15 AM	Introduction to the Troutman Prize	J Bradley Randleman MD	
11:17 AM	Troutman Prize I: Biomechanics of LASIK Flap and SMILE Cap: A Prospective, Clinical Study	Pooja Khamar MBBS MS	27
11:32 AM	Troutman Prize II: Metabolomic Analysis in Corneal Lenticules From Contact Lens Wearers	Min Li MD	36
11:47 AM	Tour of *Journal of Refractive Surgery* Papers	J Bradley Randleman MD	47
11:52 AM	Artificial Intelligence Efficiently Identifies Regional Differences in the Progression of Tomographic Parameters of Keratoconic Corneas	Rohit Shetty MBBS	48
11:57 AM	Mitomycin C Application After CXL for Keratoconus Increases Stromal Haze	Shady T Awwad MD*	58
12:02 PM	Customized Stromal Lenticule Implantation for Keratoconus	Farideh Doroodgar MD	66
12:07 PM	Discussion		
12:12 PM	LUNCH, Hall J ISRS Member Lunch, Keratoconus and Ectatic Corneal Diseases, Room 295 (ticket required)		

Section V: Video-Based Master Complications

Moderators: Amar Agarwal MD* and Deepinder K Dhaliwal MD LAc*

Afternoon Session Virtual Moderator: Gerd U Auffarth MD

Panelists: Jennifer M Loh MD*, Priya Narang MS, and Vance Michael Thompson MD*

1:42 PM	Polypseudophakia for High Hyperopia	Sonia H Yoo MD*	81
1:47 PM	Complications and Challenges With Intracorneal Ring for Corneal Ectasia	Renato Ambrósio Jr MD*	82
1:52 PM	Refractive Iris Repair	Amar Agarwal MD*	83
1:57 PM	Management of Toric IOL Surprises	Elizabeth Yeu MD*	86
2:02 PM	IOL Scaffold	Ashvin Agarwal MD*	87
2:07 PM	ISHF: Glued IOL – Yamane – Canabrava Techniques	Eric D Donnenfeld MD*	89
2:12 PM	Premium IOL Exchange for the Unhappy Patient	David F Chang MD*	91
2:17 PM	Panel Discussion		

* Indicates that the presenter has financial interest. No asterisk indicates that the presenter has no financial interest.

Section VI: Cataract & Refractive Lens Surgery—My Pearls

Moderator: Bonnie An Henderson MD*

2:27 PM	Refractive Lens Exchange: SIM vs. SEQ IOL Surgery	Julie M Schallhorn MD*	92
2:33 PM	Enhancement Strategy in Premium IOLs: My Best Pearls	Majid Moshirfar MD	93
2:39 PM	Premium IOL Implantation After Laser Vision Correction: My Greatest Errors and Solutions	Zeba A Syed MD*	94
2:45 PM	Zero Endophthalmitis With Zero Topical Antibiotics	Andrzej Grzybowski MD*	95
2:51 PM	My Decision Tree for Choosing the Type of Presbyopia-Correcting IOL	Luis Izquierdo Jr MD	96
2:57 PM	Optimizing Outcomes In Toric IOLs	Robert Ang MD*	97
3:03 PM	Discussion		

Section VII: ESCRS Symposium—Risk Mitigation in Refractive Surgery Using New Technology

Moderator: Rudy Nuijts MD*

3:18 PM	Has the Time Come for Spectacle Independency Without Optical Side Effects?	Rudy Nuijts MD*	98
3:24 PM	New Management Strategies for Cataract Surgery in the Post–Refractive Surgery Patient	Thomas Kohnen MD PhD FEBO*	102
3:30 PM	Where Is Refractive Surgery Going From Now?	Jorge L Alio MD PhD	104
3:36 PM	Monofocal+ IOL: The New Standard?	Gerd U Auffarth MD*	105
3:42 PM	Discussion		
3:49 PM	REFRESHMENT BREAK		

Keynote Lecture III (Not eligible for CME credit)

4:19 PM	Introduction	Burkhard Dick MD*	
4:21 PM	State of the Union—Innovation	William Link PhD*	106
4:31 PM	Discussion		

Section VIII: Innovation (Not eligible for CME credit)

Moderators: Burkhard Dick MD* and Deepinder K Dhaliwal MD LAc*

4:36 PM	Introduction & Global Challenges	Jim V Mazzo	107
4:42 PM	The Role of Artificial Intelligence in Refractive Surgery Diagnostics	Marcony R Santhiago MD*	108
4:48 PM	Pharmaceutical Treatment for Presbyopia	Jennifer M Loh MD*	109
4:54 PM	Femto Lenticular Corneal Shaping	Theo Seiler MD PhD*	110
5:00 PM	Femtosecond Laser–Induced Change of Refractive Index	Liliana Werner MD PhD*	111
5:06 PM	Laser-Generated Aperture to Extend Depth of Focus	Omid Kermani MD*	113
5:12 PM	Discussion		
5:30 PM	Closing Remarks	Burkhard Dick MD* Deepinder K Dhaliwal MD LAc*	

* Indicates that the presenter has financial interest. No asterisk indicates that the presenter has no financial interest.

State of the Union—Laser Vision Correction

Daniel S Durrie MD

I. Business S Curve
   A. All products, services, and procedures follow this curve of development.
   B. At startup, a tremendous amount of investment in time and money is needed.
II. Jumping S Curves – Transition
III. Is this a fad, or the future?
IV. Will LASIK join the other procedures we have left behind?
V. 2021 Company R&D Corneal Laser Spend
VI. Future of Refractive Surgery, 2030 and Beyond
   A. Corneal-based refractive surgery
      1. Advanced diagnostics like ray tracing, OCT, topography. and wavefront will all play a role.
      2. ASA/PRK will survive. Trans-epi treatment if the epithelium is healthy
   B. Femtolenticular corneal shaping (FLCS) will dominate.
      1. No epi defect, no flap
      2. Follow the corporate investment.
   C. Lens-based refractive surgery
      1. Phakic IOLs will flourish.
      2. Refractive lens exchange will grow.
         a. Presbyopia is a lens disease.
         b. Patients will share more of the costs. Patient-shared responsibility (Lindstrom)
      3. We will switch from *waiting* for cataracts to *preventing* cataracts.
VII. Femtolenticular Corneal Shaping (FLCS)
   A. The term
      1. Why do we need a new procedure term?
      2. Is this the right name?
      3. Surgeons should name the procedure. (Words matter.) Companies will brand their version.
   B. Over 4 million eyes treated with SMILE
   C. VisuMax: global glance
   D. Global market performance: Growth in annual SMILE numbers, worldwide
   E. SMILE in the military: accepted form of laser vision correction by all military branches
   F. SMILE: clinical outcomes & evidence
   G. Femtosecond laser companies
VIII. Conclusions: Future of Corneal Laser Surgery
   A. Tremendous advancements in the last 30 years
   B. Procedures are safe, effective, convenient, and cost-effective.
   C. We are in the middle of a technology transition, but we can handle it.
   D. The future looks great.
   E. It's a great time to be a comprehensive refractive surgeon.

’Tis the Time’s Plague

The (by Far) Most Common Affliction of the Human Body

Ronald D Gerste MD

A short and disturbing history of the pandemic of refractive error, and an equally short and comforting outlook

Currently living in an age where the daily lives of people, of societies, and of states are determined by an epidemic of high numbers and the ubiquity of epidemiological data of differing value—of “cases,” of “infected,” and of people dying “of” or possibly “with” a certain viral disease—published by experts, by governments, but most intensely (and influentially) by the media, it is rewarding to remind ourselves, as well as the public and the politicians, that ophthalmologists deal with pandemics that by the sheer count of the affected dwarf almost everything else known to medicine. While “our” pandemic is, fortunately, hardly ever fatal, it has mind-boggling individual, economic, and social consequences. Refractive errors are more common than any other affliction of the human body (except, perhaps, for caries). While from a short historic perspective we will be aware that refractive errors have always accompanied humans in the past, the increase during our time and the projections for the next decades are staggering.

The rise of myopia, not just in Southeast Asia but basically on a global scale, has led to about 1.4 billion people being myopic in 2000; it is predicted that there will be about 4.8 million shortsighted individuals on this Earth by 2050. While the planet’s human population is still growing, it is also ageing. Both contribute to a global prevalence of presbyopia that is expected to be about 2.1 billion in 2030. And then there is hyperopia. And astigmatism. . . . Equally gigantic is the commercial impact: the annual economic loss due to uncorrected refractive errors is estimated to be about 269 billion dollars worldwide.

Diving into the epidemiology of refractive errors makes obvious the challenges and the opportunities for ophthalmology in general, and refractive surgery in particular. Given that techniques have been developed in recent decades that for the most part are extremely effective and safe, the goal of helping people worldwide to conquer their refractive errors and empower them to live happily and productively is a realistic one for our profession. And in uncertain times it is almost a guarantee for a bright future—for the millions, if not billions of patients and for ophthalmology. To quote the bard once again (after the title above): “A victory is twice itself when the achiever brings home full numbers.”

Selected Readings

1. Berdahl J, Bala C, Dhariwal M, et al. Patient and economic burden of presbyopia: a systemic literature review. *Clin Ophthalmol*. 2020; 14:3439-3450.
2. Fricke T, Tahhan N, Resnikoff S, et al. Global prevalence of presbyopia and vision impairment from uncorrected presbyopia. *Ophthalmology* 2018; 125:1492-1499.
3. GBD 2019 Blindness and Vision Impairment Collaborators, et al. Trends in prevalence of blindness and distance and near vision impairment over 30 years: an analysis for the Global Burden of Disease Study. *Lancet Global Health*. 2021; 9:e130-143.
4. Grzybowski A, Kanclerz P, Tsubota K, et al. A review on the epidemiology of myopia in school children worldwide. *BMC Ophthalmol*. 2020; 20:27.
5. Hashemi H, Fotouhi A, Yekta A, et al. Global and regional estimates of prevalence of refractive errors: systematic review and meta-analysis. *J Curr Ophthalmol*. 2018; 30:3-22.
6. Holden BA, Fricke T, Wilson DA, et al. Global prevalence of myopia and high myopia and temporal trends from 2000 to 2050. *Ophthalmology* 2016; 123:1036-1042.
7. Katz JA, Karpecki PM, Dorca A, et al. Presbyopia: a review of current treatment options and emerging therapies. *Clin Ophthalmol*. 2021; 15:2167-2178.
8. Marques AP, Ramke J, Cairns J, et al. Global economic productivity loss from vision impairment and blindness. *EClinical Medicine* 2021; 35:100852.

Building on New Interest in Refractive Surgery and How to Keep Momentum Going

Michael C Knorz MD

Introduction

Refractive errors are the most common cause of visual impairment.[1] In younger people, myopia is surging with up to 95%[2] of students being myopic in some countries. Due to improved health, we also live a longer life, which leads to a large increase of presbyopia.[1] Refractive surgery, therefore, has tremendous growth potential. We must address the need of the younger population to get rid of their glasses, and we must offer the presbyopic group a return to a life without glasses.

We have a host of procedures available to aid us in this quest. How should we best use them? In this presentation I will try to evaluate the procedures available, with an emphasis on market development. To grow a market, we must select procedures with the least side effects possible and the fastest visual recovery. We must also not push these to their limits but stay inside the zone with the highest success rates.

Background Observations

For younger patients (younger than 40-50 years, before the age of presbyopia), surgery focuses on corneal laser surgery and phakic IOLs. Over the years we learned that laser corneal surgery can be done (and is FDA approved) for up to –12 D, but the higher the refractive correction, the lower the predictability and the higher the incidence and severity of optical side effects, such as halos and glare. One important lesson for the future, therefore, is to limit the amount of refractive correction performed by corneal laser surgery.

My experience in Germany suggests that the upper limit of corneal refractive surgery should be between –5 and –6 D of myopia correction, and that except in special cases, hyperopia should not be treated with corneal laser surgery. The better results achieved by this limited approach translate into higher patient satisfaction, which in turn increases market share for refractive laser surgery. Another reason to limit the amount of laser correction on the cornea is the option to perform refractive lens exchange with a multifocal IOL once our patients become presbyopic. If corneal laser surgery is performed for high myopia, the optical quality of the cornea is frequently degraded too far to use a multifocal IOL in later life, and the predictability of IOL power calculation is too low.

Which laser procedure should we use? To drive market growth, the procedure should be the one with the least side effects and the fastest visual recovery. LASIK, PRK/LASEK, and SMILE all provide excellent results, but visual recovery in PRK/LASEK takes too long, which means PRK/LASEK is for selected cases only. LASIK has the stigma of microkeratome complications, so it should be performed only with a femtosecond laser. Patient satisfaction seems similar in both procedures.[3] SMILE, however, has the advantage of fewer dry eye symptoms, faster surgery, and the perception that it is the least invasive procedure, so in the future it may be the predominant procedure from the perspective of market growth.

For the younger higher myopes (more than –5 D, or lower myopia with thin corneas), we should use phakic IOLs, which have an excellent safety record and are, for example, recommended in Germany for myopia of –3 D and higher. Results are more predictable with phakic IOLs, and there are fewer visual side effects in this group than in refractive laser surgery. In addition, once patients become presbyopic, a refractive lens exchange combined with explantation of the phakic IOL can easily be performed, as the cornea has not been altered by the surgery. From a marketing perspective, phakic IOLs are therefore the first choice in younger high myopes.

For younger hyperopes, phakic IOLs are also first choice, as the optical quality of the cornea is not compromised by a phakic IOL, which means we can safely perform a refractive lens exchange combined with the explantation of the phakic IOL once the patient becomes presbyopic. However, in many hyperopes the anterior chamber is too shallow to implant a phakic IOL, which leaves us with the options of either an early refractive lens exchange or no surgery at all. From a marketing perspective, I recommend against refractive lens exchange in hyperopia up to +3 D in pre-presbyopic patients. For hyperopia over +3 D, I think refractive lens exchange is a valid option even in pre-presbyopic patients, but its results are not as good as those after phakic IOL implantation, and we should therefore not push this option in our marketing.

The second patient group is presbyopic patients. As a general rule, in this group refractive lens exchange with a multifocal IOL should be our default procedure. Presbyopic patients want to see clearly at distance and near without any glasses, and they want a stable result. Laser surgery cannot provide normal reading. Monovision is an option, but it does not provide normal reading, and correction is not stable, as the human lens remains inside the eye and continues to age until a full cataract develops in later life. In addition, corneal laser surgery causes dry eye symptoms for many months, which decreases patient satisfaction. We should therefore exchange the aging lens and replace it with a multifocal lens. Modern trifocal or multifocal IOLs provide 20/25 to 20/20 vision from 33 cm to full distance. There are side effects, such as halos, but they affect a small percentage of patients only. Refractive lens exchange with a multifocal IOL provides full spectacle independence for the long term and therefore is the best option in all presbyopic patients from a marketing perspective. It also seems the logical choice, as it avoids the need for cataract surgery later in life.

References

1. Parwez H, Ramez B. The future of refractive surgery: presbyopia treatment, can we dispend with our glasses? *Eye* 2021; 35:359-361.
2. Wang J, Li Y, Zhao Z. et al. School-based epidemiology study of myopia in Tianjin, China. *Int Ophthalmol.* 2020; 40:2213-2222.
3. Damgaard IB, Ang M, Farook M, Htoon HM, Mehta JS. Intraoperative patient experience and postoperative visual quality after SMILE and LASIK in a randomized, paired-eye, controlled study. *J Refract Surg.* 2018; 34:92-99.

Therapeutic Custom Ablation: My Pearls

Dan Z Reinstein MD

Corneal refractive surgery is associated with various potential complications that may result in irregular astigmatism, causing visual symptoms such as reduced corrected distance visual acuity (CDVA) and contrast sensitivity, halos and starbursts, ghosting, and diplopia. Irregular astigmatism can be classified in two categories: *regularly* irregular astigmatism and *irregularly* irregular astigmatism. The main examples of regularly irregular astigmatism after SMILE are high spherical aberration (ie, a small achieved optical zone) and decentration. In these situations, there is effectively one large "global" irregularity, but the topographic optical zone is otherwise symmetrical and round. In cases of irregularly irregular astigmatism, on the other hand, the irregularities are localized to small regions, such that the topography appears asymmetric or distorted, often within the boundary of the optical zone.

The most important aspect of treating complications is to first make a confident diagnosis of the problem since some treatment options could actually be detrimental in certain circumstances. The introduction of custom ablation based on either topography or wavefront promised to be the answer to postop complications. However, neither topography nor wavefront can measure the true source of the irregularity, the stromal surface. The natural compensatory mechanism of epithelial remodeling acts to mask a proportion of the stromal surface irregularity from front surface corneal topography (or from the wavefront).[1-5] If there is irregular astigmatism on the topography, then by definition there will be irregular epithelium; the epithelium overlying bumps in the stromal surface becomes progressively thinner and the epithelium overlying troughs in the stromal surface becomes progressively thicker. Further, the amount of epithelial remodeling has been shown to be correlated to the local curvature gradient of the stromal surface, with greater epithelial compensation for more localized irregularities.[1,6-8]

Therefore, in cases of local irregularities (irregularly irregular astigmatism) the majority of the stromal irregularity will be masked from topography by epithelial remodeling. In contrast, the stromal curvature gradient is more gradual for global irregularities, which reduces the amount of compensatory epithelial remodeling such that the majority of the stromal irregularity will be detectable on front surface corneal topography. Therefore, a topography-guided treatment can be expected to be effective only when used to treat global irregularities and to be minimally effective in irregularly irregular astigmatism.[9] In some cases of irregularly irregular astigmatism, a topography-guided treatment can even make the irregularity worse.[1,2,4]

For this reason, an epithelial thickness profile is vital for an accurate diagnosis in cases of irregular astigmatism. In cases with localized irregularities where the epithelium has compensated for the majority of the irregularity, a different treatment option is required. Transepithelial phototherapeutic keratectomy offers a solution by using the epithelium as a natural masking agent to focus the ablation onto the relative peaks in the stromal surface.

Thus, the decision process for irregular astigmatism can be summarized as follows:

- "Global" regularly irregular astigmatism: dominant irregularity on topography; topography-guided custom ablation
- "Local" irregularly irregular astigmatism: dominant irregularity masked by epithelium; trans-epithelial phototherapeutic keratectomy

Since the introduction of topography-guided custom ablation in the late 1990s,[10,11] most modern excimer laser platforms include a topography-guided option.[9,12-14] As described above, topography-guided custom ablation has proved to be very effective for treating global irregularities such as small optical zone and decentration. Topography-guided algorithms import the front surface corneal topography and calculate the ablation profile that would result in a smooth aspheric surface with a large optical zone.

When performing a topography-guided treatment, the most important part is the planning—of which the most important part is the topography acquisition. The efficacy of the treatment depends entirely on the quality and reliability of the topography exam that the treatment was based on. The following factors should be considered:

- Ensure that the scans are well focused.
- Ensure that the scans are well centered.
- Carefully review the quality of the mires rings to check for any distortion due to tear film discontinuities (artificial tear drops may be used).
- Select the scan with the largest area of continuous data.
- Obtain numerous scans to verify that the irregularity is repeatable.
- Ensure that the data are continuous.
- A large optical zone should be used (within tissue constraints) to incorporate the irregularity in full.
- The surgeon should carefully review the final ablation profile to confirm that it makes sense in the context of the topography and other diagnostic data available.

The manifest refraction can be treated in the same treatment as regularizing the cornea. However, there are some different opinions on what value to enter for the cylinder correction in cases where the manifest cylinder axis is not aligned with the corneal astigmatism or there is a difference in magnitude, ie, eyes with a large ocular residual astigmatism (ORA).[15] Treating the refractive cylinder will induce corneal astigmatism equal to the ORA, that should balance the ORA coming from the posterior corneal surface and the lens. However, in eyes with irregular astigmatism, the corneal higher-order aberrations, in particular coma, may be contributing to the refractive cylinder measurement—effectively a pseudo-cylinder from the coma.[16] Therefore, treating the coma in the topography-guided ablation will correct for the pseudo-cylinder. If the treatment also includes the refractive cylinder, this can lead to a significant overcorrection. Planning the best cylinder to use should there-

fore aim to evaluate the cylinder component that is due to coma and how much is true refractive cylinder.

In our experience using the MEL 80 topography-guided system in retreatments after LASIK, we achieved an 11% increase in the topographic optical zone diameter, which contributed a 46% reduction in spherical aberration, and decentration from the corneal vertex was also reduced by 64%.[9,17] These results were significantly more effective than in our experience with wavefront-guided custom ablation,[18] likely due to the higher resolution afforded by topography and centration on the corneal vertex rather than the pupil center (as required for wavefront).

References

1. Reinstein DZ, Archer TJ, Dickeson ZI, Gobbe M. Trans-epithelial phototherapeutic keratectomy protocol for treating irregular astigmatism based on population epithelial thickness measurements by Artemis very high-frequency digital ultrasound. *J Refract Surg.* 2014; 30:380-387.
2. Reinstein DZ, Archer TJ, Gobbe M. Improved effectiveness of trans-epithelial phototherapeutic keratectomy versus topography-guided ablation degraded by epithelial compensation on irregular stromal surfaces [plus video]. *J Refract Surg.* 2013; 29:526-533.
3. Reinstein DZ, Archer T. Combined Artemis very high-frequency digital ultrasound-assisted transepithelial phototherapeutic keratectomy and wavefront-guided treatment following multiple corneal refractive procedures. *J Cataract Refract Surg.* 2006; 32:1870-1876.
4. Reinstein DZ, Archer TJ, Gobbe M. Refractive and topographic errors in topography-guided ablation produced by epithelial compensation predicted by three-dimensional Artemis very high-frequency digital ultrasound stromal and epithelial thickness mapping. *J Refract Surg.* 2012; 28:657-663.
5. Vinciguerra P, Camesasca FI. Custom phototherapeutic keratectomy with intraoperative topography. *J Refract Surg.* 2004; 20:S555-563.
6. Reinstein DZ, Archer TJ, Gobbe M. Rate of change of curvature of the corneal stromal surface drives epithelial compensatory changes and remodeling. *J Refract Surg.* 2014; 30:800-802.
7. Vinciguerra P, Azzolini C, Vinciguerra R. Corneal curvature gradient determines corneal healing process and epithelial behavior. *J Refract Surg.* 2015; 31:281-282.
8. Vinciguerra P, Roberts CJ, Albe E, et al. Corneal curvature gradient map: a new corneal topography map to predict the corneal healing process. *J Refract Surg.* 2014; 30:202-207.
9. Reinstein DZ, Archer TJ, Gobbe M. Combined corneal topography and corneal wavefront data in the treatment of corneal irregularity and refractive error in LASIK or PRK using the Carl Zeiss Meditec MEL 80 and CRS Master. *J Refract Surg.* 2009; 25:503-515.
10. Kymionis GD, Panagopoulou SI, Aslanides IM, Plainis S, Astyrakakis N, Pallikaris IG. Topographically supported customized ablation for the management of decentered laser in situ keratomileusis. *Am J Ophthalmol.* 2004; 137:806-811.
11. Wiesinger-Jendritza B, Knorz MC, Hugger P, Liermann A. Laser in situ keratomileusis assisted by corneal topography. *J Cataract Refract Surg.* 1998; 24:166-174.
12. Lin DT, Holland SR, Rocha KM, Krueger RR. Method for optimizing topography-guided ablation of highly aberrated eyes with the Allegretto Wave excimer laser. *J Refract Surg.* 2008; 24:S439-445.
13. Alio J, Galal A, Montalban R, Pinero D. Corneal wavefront-guided LASIK retreatments for correction of highly aberrated corneas following refractive surgery. *J Refract Surg.* 2007; 23:760-773.
14. Toda I, Yamamoto T, Ito M, Hori-Komai Y, Tsubota K. Topography-guided ablation for treatment of patients with irregular astigmatism. *J Refract Surg.* 2007; 23:118-125.
15. Alpins N, Stamatelatos G. Clinical outcomes of laser in situ keratomileusis using combined topography and refractive wavefront treatments for myopic astigmatism. *J Cataract Refract Surg.* 2008; 34:1250-1259.
16. Zhou W, Stojanovic F, Reinstein DZ, et al. Coma influence on manifest astigmatism in coma-dominant irregular corneal optics. *J Refract Surg.* 2021; 37:274-282.
17. Reinstein DZ, Archer TJ, Carp GI, et al. Incidence and outcomes of optical zone enlargement and recentration after previous myopic LASIK by topography-guided custom ablation. *J Refract Surg.* 2018; 34:121-130.
18. Reinstein DZ, Archer TJ, Couch D, Schroeder E, Wottke M. A new night vision disturbances parameter and contrast sensitivity as indicators of success in wavefront-guided enhancement. *J Refract Surg.* 2005; 21:S535-540.

PRK in KC

Renato Ambrosio Jr MD

NOTES

NOTES

NOTES

NOTES

NOTES

LASIK

How Can We Do Better?

Karolinne Maia Rocha MD PhD

I. A Stepwise Approach: Cumulative Benefits
   A. Preoperative
   B. Intraoperative
   C. Postoperative
   D. Teaching
   E. Patient Experience

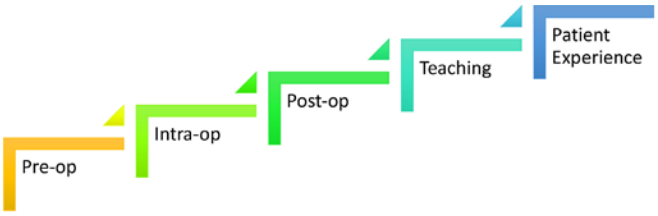

Figure 1. A stepwise approach.

II. Preoperative
   A. Prevention
   B. Substantial global increases in myopia prevalence and its associated complications[1]
   C. Risk of ectasia: Assessment strategies
      1. Genetic mutations in the TGBFI gene are responsible for 5 dystrophies.
         a. Granular type I
         b. Granular type II
         c. Lattice
         d. Reis Bucklers
         e. Thiel Behnke
      2. Corneal biomechanics[2]
      3. Algorithms for topographic/tomographic detection[2]
      4. Corneal epithelial mapping[3]

III. Intraoperative
   A. Newer technologies: Aberrometry
   B. Nomograms
   C. Artificial intelligence
      1. Phorcides planned topography guidance: Visual results[4,5]
      2. PRK
      3. Power selection for spherical and toric IOLs
   D. Extremes
   E. Myopes/hyperopes: DLS classification to guide the decision-making process (eg, surgery on the lens vs. cornea)

IV. Postoperative
   A. Marketing
      1. LASIK benefits
      2. Satisfaction with LASIK vs. contact lenses[6]

V. Teaching
   A. Society courses
   B. Wet labs
   C. Virtual reality

VI. Patient Experience
   A. Holistic approach
   B. Refractive surgery for a lifetime plan

References

1. Modjtahedi BS, Abbott RL, Fong DS, Lum F, Tan D; Task Force on Myopia. Reducing the global burden of myopia by delaying the onset of myopia and reducing myopic progression in children: the Academy's Task Force on Myopia. *Ophthalmology* 2021; 128(6):816-826.
2. Roberts CJ, Dupps WJ Jr. Biomechanics of corneal ectasia and biomechanical treatments. *J Cataract Refract Surg.* 2014; 40(6):991-998.
3. Zhou W, Reinstein DZ, Chen X, et al. Transepithelial topography-guided ablation assisted by epithelial thickness mapping for treatment of regression after myopic refractive surgery. *J Refract Surg.* 2019; 35(8):525-533.
4. US FDA. Allegretto Wave Eye-Q addendum procedure manual T-CAT topography-guided treatments. www.accessdata.fda.gov/cdrh_docs/pdf2/P020050S012d.pdf.
5. Lobanoff M, Stonecipher K, Tooma T, Wexler S, Potvin R. Clinical outcomes after topography-guided LASIK: comparing results based on a new topography analysis algorithm with those based on manifest refraction. *J Cataract Refract Surg.* 2020; 46(6):814-819.
6. Price MO, Price DA, Bucci FA Jr, Durrie DS, Bond WI, Price FW Jr. Three-year longitudinal survey comparing visual satisfaction with LASIK and contact lenses. *Ophthalmology* 2016; 123(8):1659-1666.

SMILE

John F Doane MD

Starting SMILE Vision Correction Surgery for the U.S. Surgeon

Femtosecond laser small-incision lenticule extraction (SMILE) was FDA approved for spherical myopia in September 2016 and compound myopic astigmatism in October 2018. SMILE will be explained in histological terms. Evaluation of patients for SMILE, range of correction, procedure concerns, and postoperative management will be addressed. Patient experience and appropriate expectations will be reviewed. The attendee should be completely comfortable discussing the technology after the course.

Learning Objectives

I. Understand SMILE Procedure, Patient Selection, and Postoperative Management
   A. Lamellar corneal surgery
   B. Development of SMILE
   C. Patient selection for SMILE
   D. Potential benefits of SMILE vs. LASIK
      1. Faster recovery of postop dry eye
      2. Quicker reinnervation of corneal nerves
      3. Biomechanical advantages.
      4. SMILE enhancement 1/3 that of LASIK
   E. Surgical technique of SMILE
      1. Lenticule or refractive cut
      2. Lenticule side cut
      3. Cap cut
      4. Side cut
   F. Refractive outcomes of SMILE
      1. Example: U.S. outcomes
      2. FDA trial results
   G. Complications of SMILE
      1. Epithelial abrasions
      2. Incision tears
      3. Retained lenticule fragments
   H. Enhancement of SMILE
      1. PRK
      2. LASIK
      3. Circle technique
      4. Repeat SMILE

Small Incision Lenticule Extraction (SMILE)

Introduction

Conceptually, SMILE was thought of in the year 2000 by researchers at Carl Zeiss in Jena, Germany. The first nonsighted eyes were treated in 2007. SMILE commercially has been available outside the U.S. since 2011 and inside the U.S. since 2017. To date, spherical myopia and compound myopic astigmatism have been treated. Clinical research on treating hyperopia and hyperopic astigmatism are ongoing. The procedure involves using a femtosecond laser to create a corneal lenticule that is extracted whole through a small incision without the use of an excimer laser. Visual recovery occurs the day of the surgery, and outcomes are equal to LASIK.

Background/Overview

Starting in 2007, an intrastromal lenticule method was reintroduced as an alternative to LASIK called femtosecond lenticule extraction (FLEx), intended for patients with myopia. With FLEx a flap was created and the lenticule was peeled off the stromal bed. After improvements to scan modes and energy parameters, improved visual recovery times were noted, with refractive results similar to LASIK. Following the implementation of FLEx, a procedure called small-incision lenticule extraction (SMILE) was developed. SMILE is a flap-less procedure and involves creating a 2-3 mm incision used to allow for extraction of the whole corneal lenticule without the need to create a flap.[1]

SMILE achieves visual results equivalent to those of LASIK. Peer-reviewed reports reveal faster recovery of postop dry eye, reinnervation of corneal nerves, potential biomechanical advantage, and 1/3 the enhancement rate of LASIK. SMILE became commercially available worldwide in September 2011. Clinical trial in the U.S. began in June 2012 for spherical myopia and 2014 for compound myopic astigmatism. To date (July 2021), over 4,000,000 procedures have been performed on 1300 lasers by 2500 surgeons. There have been over 700 peer-reviewed articles published on SMILE.

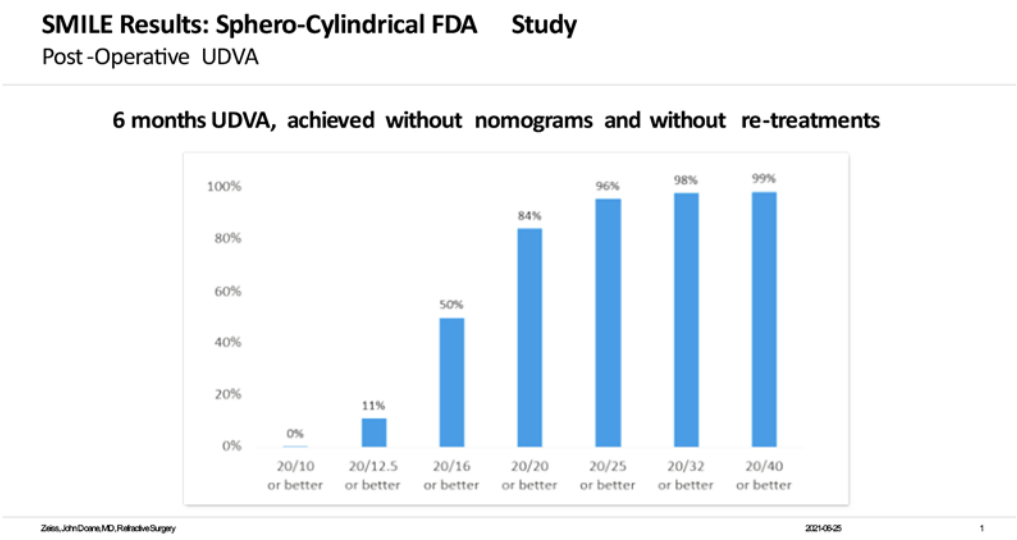

Figure 1. SMILE results, sphero-cylindrical FDA study, postoperative uncorrected distance visual acuity (UDVA).

Surgical Technique and History of Procedure

During the SMILE procedure, the patient is raised to the contact glass of the femtosecond laser and suction ports are activated to keep the patient's eye fixated in the correct position while the lenticule is created. The lower interface of the intrastromal lenticule is created first (using an out-to-in direction with the laser to maximize the time without blurring the patient's central vision), followed by the upper interface of the lenticule (using an in-to-out direction), known as the *cap*, and finally a 2-3 mm tunnel incision (usually superotemporal) that links the cap interface to the corneal surface. To avoid any undesirable effects in the cornea such as haziness, the 2 interfaces (lower and upper) are created from the endothelial side of the cornea to the epithelial side. The patient is then moved to the surgical microscope for the lenticule separation and extraction part of the procedure. The layers of the lenticule are outlined, and the lenticule is removed from the cornea using a pair of retinal microforceps, or it can be extracted directly from within the pocket with the latest versions of the lenticule stripper, one of many instruments being developed for the SMILE procedure specifically.[3]

When planning the treatment, the following parameters can be selected by the surgeon: cap thickness, cap diameter, cap side cut angle, refractive correction, lenticule diameter (optical zone), lenticule side cut angle, and the minimum lenticule thickness (so that the lower lenticule interface can be easily differentiated from the upper interface).

Outcomes

In a group consisting of 88 eyes, Ang et al (2014) found that 95.5% of the eyes were within ±1.00 D of the attempted correction and 78.4% were within ±0.50 D of the attempted correction. Additionally it was found that uncorrected visual distance acuity (UDVA) of 20/40 or better was seen in 100% of eyes at 3 months postop and 76.5% were 20/20 or better, up to 12 months postop.[4] There was no significant difference between the efficacy, predictability, or safety between low myopia eyes and eyes of -5.00 D or greater.

Figure 2

SMILE Results: Comparison to Most Recent LASIK Approvals

Predictability and Accuracy of MRSE Correction

UDVA results after SMILE are comparable to results after LASIK

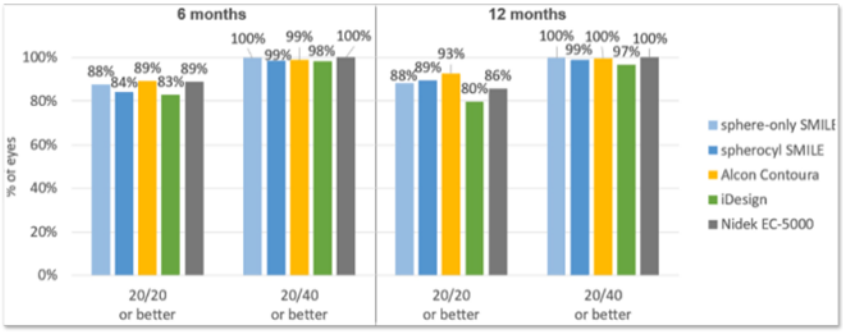

Zeiss, John Doane, MD, Refractive Surgery 2021-05-25 13

Figure 3

SMILE Results: Comparison to Most Recent LASIK Approvals

Predictability and Accuracy of Astigmatic Correction

Predictability and accuracy of the cylinder correction 6 months after surgery is comparable to or better than LASIK results

Cylinder	Spherocyl SMILE	Alcon Contoura	iDesign	Nidek EC-5000
Preoperative mean ± SD	-1.53 ± 0.67 D	-1.19 ± 1.23 D	-1.77 ± 1.65 D	-1.03 ± 0.64 D
Postoperative mean ± SD	-0.22 ± 0.33 D	-0.19 ± 0.30 D	-0.33 ± 0.36 D	-0.24 ± 0.27 D
Within ± 0.50 D	88%	90%	85%	91%
Within ± 1.00 D	97%	97%	94%	100%

Zeiss, John Doane, MD, Refractive Surgery 2021-05-25 15

Figure 4

SMILE Results: Comparison to Most Recent LASIK Approvals

Predictability and Accuracy of MRSE Correction

Predictability and accuracy of the MRSE correction is comparable or better than LASIK (6 months after surgery)

MRSE	Sphere-only SMILE	Spherocyl SMILE	Alcon Contoura	iDesign	Nidek EC-5000
Preoperative mean ± SD	-4.86 ± 2.21 D	-5.46 ± 2.35 D	-4.61 ± 2.43 D	-6.21 ± 2.78 D	-3.57± 1.45 D
Postoperative mean ± SD (deviation from attempted MRSE*)	-0.14 ± 0.33 D (-0.04 ± 0.32 D)	-0.03 ± 0.28 D (-0.02 ± 0.28 D)	0.01 ± 0.35 D	-0.46 ± 0.42 D	-0.08 ± 0.33 D
Within ± 0.50 D	93%	94%	93%	69%	91%
Within ± 1.00 D	99%	99%	99%	93%	99%

Zeiss, John Doane, MD, Refractive Surgery 2021-05-25 14

Figure 5

SMILE Results: Comparison to Most Recent LASIK Approvals

Predictability and Accuracy of MRSE Correction

Predictability and accuracy of the MRSE correction is comparable or better than LASIK (6 months after surgery)

MRSE	Sphere-only SMILE	Spherocyl SMILE	Alcon Contoura	iDesign	Nidek EC-5000
Preoperative mean ± SD	-4.86 ± 2.21 D	-5.46 ± 2.35 D	-4.61 ± 2.43 D	-6.21 ± 2.78 D	-3.57± 1.45 D
Postoperative mean ± SD (deviation from attempted MRSE*)	-0.14 ± 0.33 D (-0.04 ± 0.32 D)	-0.03 ± 0.28 D (-0.02 ± 0.28 D)	0.01 ± 0.35 D	-0.46 ± 0.42 D	-0.08 ± 0.33 D
Within ± 0.50 D	93%	94%	93%	69%	91%
Within ± 1.00 D	99%	99%	99%	93%	99%

Zeiss, John Doane, MD, Refractive Surgery 2021-05-25 14

Complications

Complications arising during the SMILE procedure have been reported at low frequency. Studies using SMILE found epithelial abrasions and small tears at the incision as the most frequent complications. Other lamellar surgical technique complications are also possible, including diffuse lamellar keratitis or infection. The loss of suction during the refractive pass of the femtosecond laser portion of the procedure is one of the primary complications with SMILE and likely will necessitate abortion of the procedure. The incidence in an experienced surgeon's hands is less than 0.5% of cases.

Dry eye has been shown repeatedly in peer-reviewed studies to be of lesser amount and shorter duration than in LASIK.

Conclusions

The SMILE procedure is now well entrenched as a commercially viable corneal refractive procedure. At present one manufacturer has provided a commercially available system, although this is likely to change in time. As a flapless technique, with visual results similar to those of LASIK and quicker reinnervation of corneal nerves, less dry eye, greater biomechanical preservation, and less frequent enhancements than LASIK, it appears to have staying power as a refractive surgery option for spherical myopia and compound myopic astigmatism.

References

1. Reinstein DZ, Archer TJ, Gobbe M. Small incision lenticule extraction (SMILE) history, fundamentals of a new refractive surgery technique and clinical outcomes. *Eye Vis*. 2014; 1:3.
2. Innovative SMILE procedure from ZEISS successfully performed on more than 80,000 eyes [press release]. Feb. 4, 2014. Web: Mar. 10, 2015. http://www.zeiss.com/content/dam/Meditec/downloads/pdf/press-releases/czm_pi_smile_80000_procedures_20140204_en.pdf
3. Liu Y-C, Pujara T, Mehta JS. New instruments for lenticule extraction in small incision lenticule extraction (SMILE). *PLoS ONE* 2014; 9(12): e113774.
4. Ang M, Mehta JS, Chan C, et al. Refractive lenticule extraction: transition and comparison of 3 surgical techniques. *J Cataract Refract Surg*. 2014; 40(9):1415-1424.
5. Denoyer A, Landman E, Trinh L, Faure J-F, Auclin F, Baudouin C. Dry eye disease after refractive surgery: comparative outcomes of small incision lenticule extraction versus LASIK. *Ophthalmology* 2015; 122(4):669-676.
6. Vestergaard AH, Grauslund J, Ivarsen AR, Hjortdal JØ. Efficacy, safety, predictability, contrast sensitivity and aberrations after femtosecond laser lenticule extraction. *J Cataract Refract Surg*. 2014; 40(3):403-411.
7. Wong CW, Chan C, Tan D, Mehta JS. Incidence and management of suction loss in refractive lenticule extraction. *J Cataract Refract Surg*. 2014; 40(12):2002-2010.
8. Shah R, Shah S, Sengupta S. Results of small incision lenticule extraction: all-in-one femtosecond laser refractive surgery. *J Cataract Refract Surg*. 2011; 37:127-137.
9. Sekundo W, Kunert KS, Blum M. Small incision corneal refractive surgery using the small incision lenticule extraction (SMILE) procedure for the correction of myopia and myopic astigmatism: results of a 6 month prospective study. *Br J Ophthalmol*. 2011; 95:335-339.
10. Vestergaard A, Ivarsen AR, Asp S, Hjortdal JO. Small-incision lenticule extraction for moderate to high myopia: predictability, safety, and patient satisfaction. *J Cataract Refract Surg*. 2012, 38:2003-2010.
11. Hjortdal JO, Vestergaard AH, Ivarsen A, Ragunathan S, Asp S. Predictors for the outcome of small-incision lenticule extraction for myopia. *J Refract Surg*. 2012; 28:865-871.
12. Wang Y, Bao XL, Tang X, Zuo T, Geng WL, Jin Y. Clinical study of femtosecond laser corneal small incision lenticule extraction for correction of myopia and myopic astigmatism. *Zhonghua Yan Ke Za Zhi* 2013; 49:292-298.
13. Kamiya K, Shimizu K, Igarashi A, Kobashi H: Visual and refractive outcomes of femtosecond lenticule extraction and small-incision lenticule extraction for myopia. *Am J Ophthalmol*. 2014; 157:128-134.e122.
14. Sekundo W, Gertnere J, Bertelmann T, Solomatin I. One-year refractive results, contrast sensitivity, high-order aberrations and complications after myopic small-incision lenticule extraction

(ReLEx SMILE). *Graefes Arch Clin Exp Ophthalmol*. 2014; 252(5):837-843.

15. Agca A, Demirok A, Cankaya KI, et al. Comparison of visual acuity and higher-order aberrations after femtosecond lenticule extraction and small-incision lenticule extraction. *Cont Lens Anterior Eye*, 2014; 37(4):292-296.

16. Lin F, Xu Y, Yang Y. Comparison of the visual results after SMILE and femtosecond laser-assisted LASIK for myopia. *J Refract Surg*. 2014; 30:248-254.

17. Xu Y, Yang Y. Dry eye after small incision lenticule extraction and LASIK for myopia. *J Refract Surg*. 2014; 30:186-190.

Presbyopia Correction With Refractive IOLs: Pearls and Pitfalls

William Trattler MD

I. Preoperative Pearls

A. Determine the refractive goals for the patient interested in reducing their need for glasses.

B. Preop evaluation for dry eye and meibomian gland dysfunction (MGD)/blepharitis: Dry eye/MGD/blepharitis are very common in patients interested in presbyopia-correcting IOLs. If present, treat and have patient return for repeat testing.

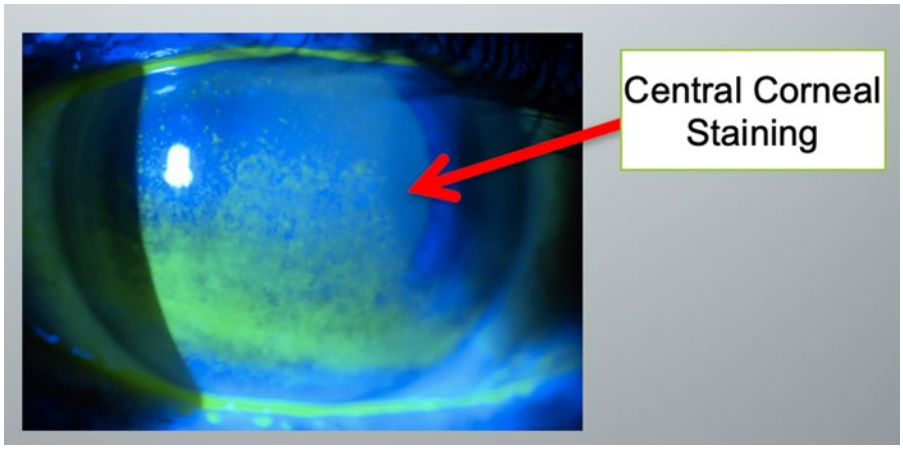

Figure 1

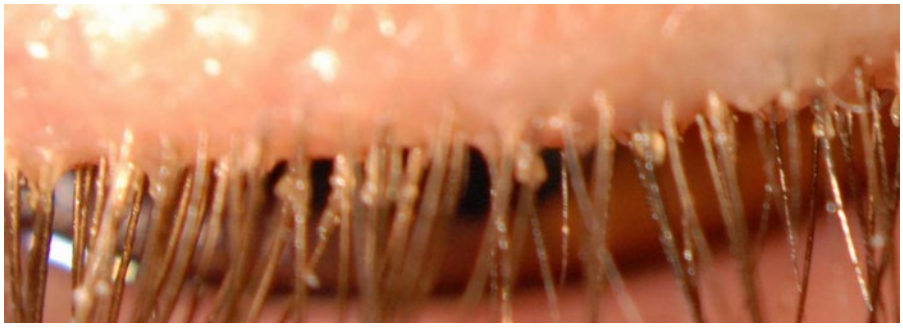

Figure 2

C. Preop OCT of the macula: Macular conditions such as epiretinal membrane, vitreomacular traction syndrome, lamellar holes, and other conditions can significantly reduce the success of presbyopia-correcting IOLs.

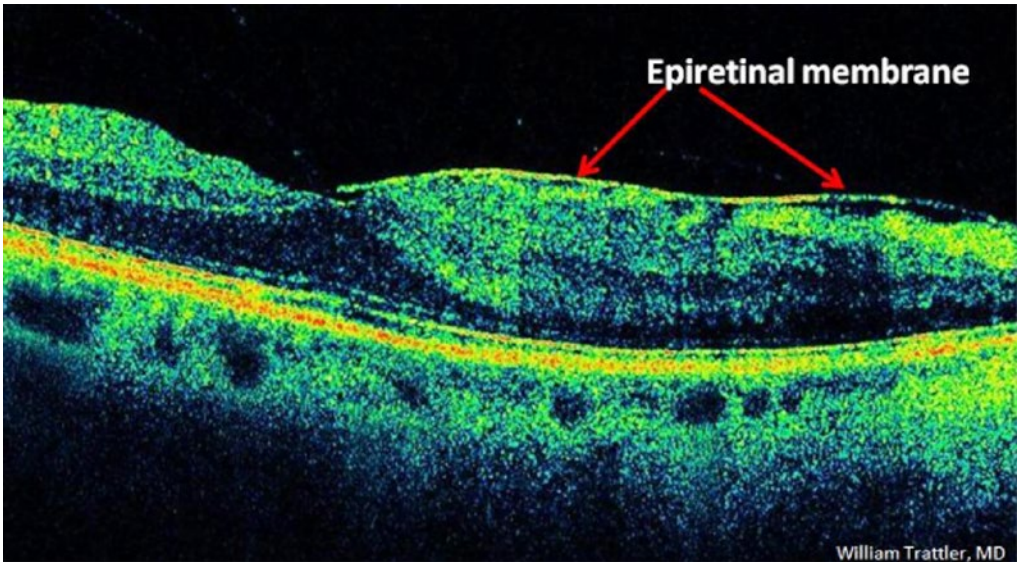

Figure 3

D. Preop topography/tomography: Irregular corneal shape can be seen in 25% of patients. The most common causes:

1. Irregular astigmatism due to dry eye/MGD/blepharitis, as these cause corneal staining and rapid tear breakup time. Treatment can often improve the regularity of the topography.

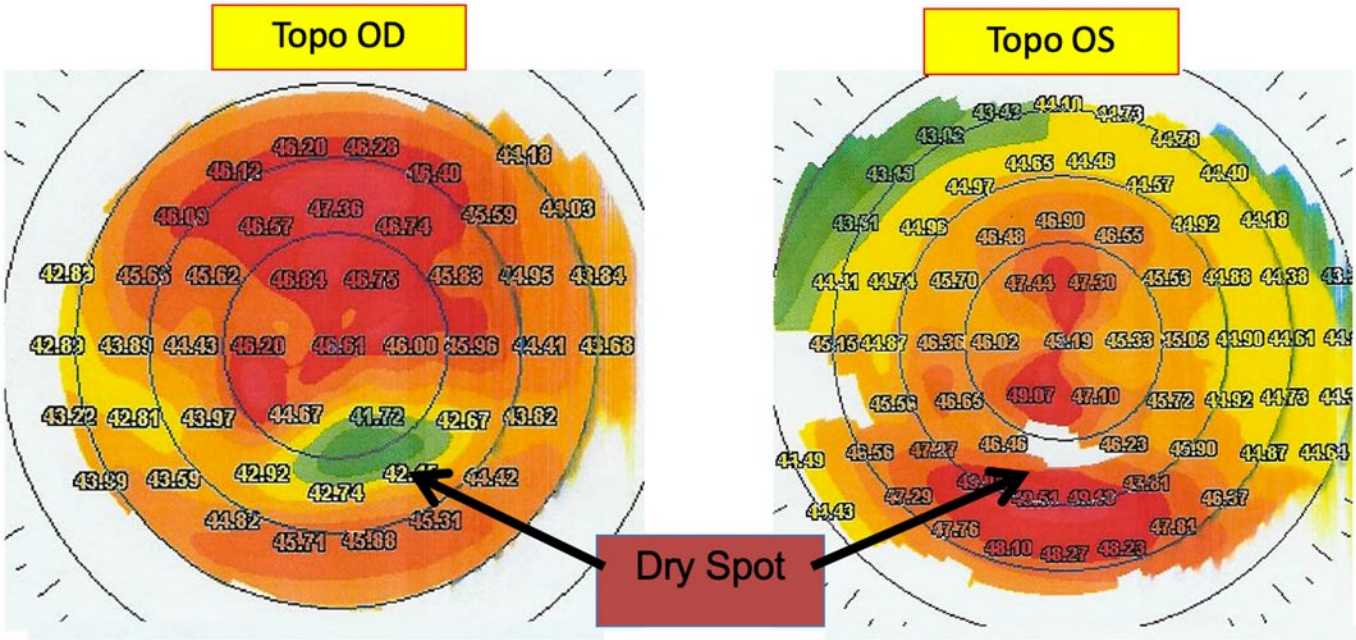

Figure 4

2. Keratoconus/pellucid: Mild cases can be discovered when screening patients prior to presbyopic-correcting IOLs.

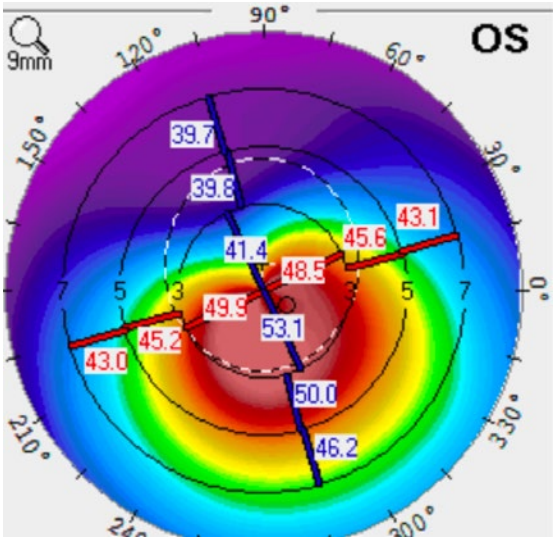

Figure 5

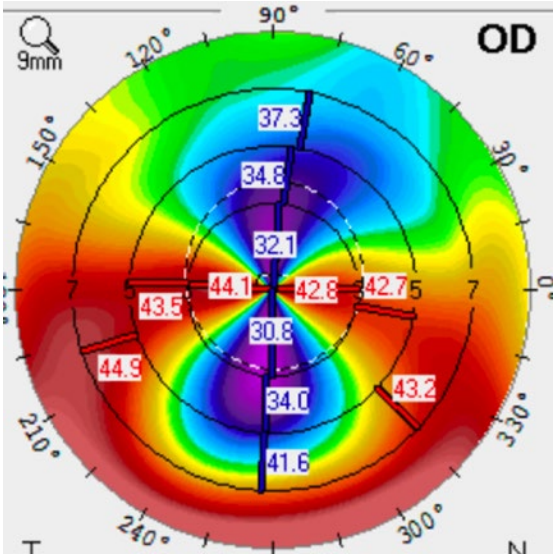

Figure 6

3. Epithelial basement membrane dystrophy (EBMD)/Salzmann nodular degeneration: Some cases can be subtle on slit-lamp exam, but topography will identify irregular astigmatism. Treatment with epithelial debridement, phototherapeutic keratectomy, or other procedures can improve the regularity of the corneal shape.

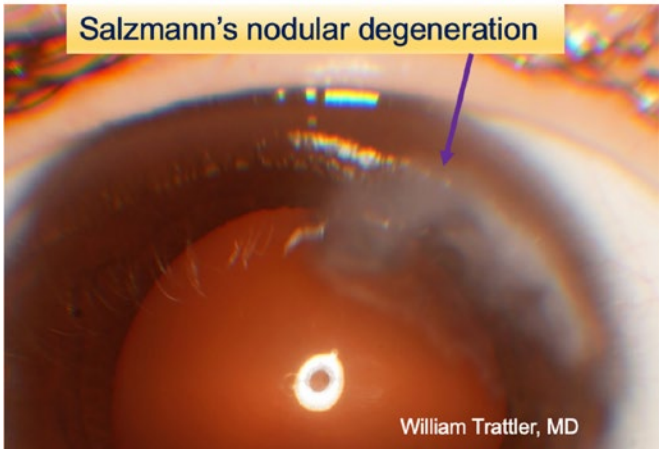

Figure 7

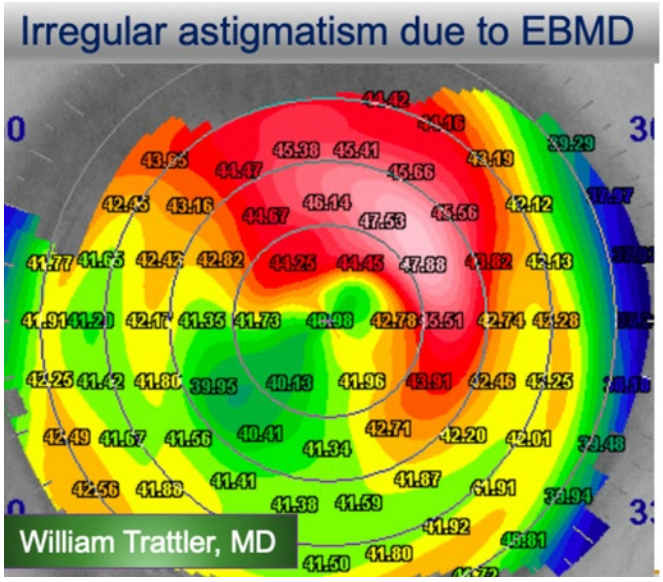

Figure 8

4. Irregular astigmatism with no obvious cause visible on slit lamp exam: Some patients just have irregular astigmatism.

5. Irregular astigmatism in patients with a history of corneal refractive procedures, such as LASIK, PRK, SMILE, radial keratotomy, and astigmatic keratotomy (AK).

E. Slit-lamp exam: Evaluate for common corneal conditions that could impact the success of presbyopia-correcting IOLs.

1. Fuchs corneal dystrophy
2. Signs of dry eye/MGD/blepharitis
3. EBMD or other corneal dystrophies

F. Determine the optimal refractive plan with refractive IOLs

1. Blended vision/monovision with monofocal or monofocal toric IOLs
   a. Nonaspheric or neutral aspheric IOLs can provide increased range of vision in the blended vision/monovision eye compared to an IOL with negative asphericity.
   b. Patients with steep corneas or small pupils when looking at near objects will have increased range of vision.
   c. Potential role of miotic eye drops being developed for treatment of presbyopia
2. Blended vision/monovision with adjustable IOLs
3. Bilateral presbyopic IOLs
   a. EDOF IOLs
   b. Multifocal IOLs
   c. Trifocal IOLs
4. Small-aperture IOL (unilateral or bilateral)
5. Accommodating IOLs

II. Postoperative Pearls

Note: Despite careful preoperative evaluation and advanced IOL planning, not all patients will report 100% satisfaction with their experience/outcome, even with monofocal/toric IOLs.

A. Evaluate for dry eye/MGD that has developed postoperatively; if present, treat.

B. OCT of the macula: Identify cystoid macular edema or other abnormalities of the macula that have developed following presbyopic-correcting IOLs.

C. Topography: Identify irregular astigmatism that may have developed following presbyopia-correcting IOLs.

D. Evaluate UCVA for distance, intermediate, and near to determine how well the patient is seeing at each distance.

E. Perform refraction and determine if there is residual refractive error that may benefit from future surgical treatments. Treatment options include:

1. Corneal refractive surgery: LASIK/PRK/SMILE/AK
2. IOL exchange
3. Piggyback IOL

III. Pitfalls

IOL surgery with the presbyopia-correcting IOLs has risks, and while preoperative selection of optimal candidates can lead to a high success rate, some patients can still report reduced satisfaction/dissatisfaction due to a variety of conditions.

A. Floaters/vitreous opacities

Surprisingly, vitreous opacities can impact quality of vision in some patients with presbyopia-correcting IOLs. Floaters/vitreous opacities may have been pre-existing, or they may worsen after intraocular surgery. Treatment of opacities with laser or surgery can improve patient satisfaction with presbyopia-correcting IOLs in some cases. However, these procedures have their own set of risks

B. Exacerbation of dry eye following presbyopia-correcting IOLs

C. Under- or overcorrection: While advanced IOL formulas are present, the refractive target is not achieved in all patients.

D. Cystoid macular edema/exacerbation of epiretinal membrane

E. Endophthalmitis (thankfully uncommon)

F. Negative dysphotopsia

G. Night vision complaints: These are more common with presbyopia-correcting IOLs than with monofocal IOLs.

IV. Overall

A. Presbyopia-correcting IOLs can provide excellent patient satisfaction.

B. Preoperative screening is important to help identify patients with the highest chance for an excellent visual result.

C. Determining the strategy for presbyopia-correcting IOLs is important.

1. Monovision/blended vision with monofocal/toric or adjustable IOLs can potentially provide excellent visual outcomes, especially for patients with a history of monovision CTL wear. *Note*: A small percentage of patients can report dissatisfaction with the vision achieved with their monofocal IOL/toric IOL or adjustable IOL and may end up requesting replacement of their IOL with a different technology.
2. Presbyopia-correcting IOLs can provide high patient satisfaction. *Note*: A small percentage of patients can report bothersome visual aberrations and may end up requesting replacement of their IOL with a different technology.
3. Small-aperture IOLs are available internationally and will soon be available in the United States.

Presbyopia Correction in the Plano Presbyope

Franceso Carones MD

NOTES

Presbyopia Correction in the High Myope

Erik L Mertens MD FRCOphth

Introduction

The demand for presbyopia-correcting procedures increases year after year, and the surgical options keep expanding as a result. When the gradual loss of vision interferes with simple everyday tasks, including reading, looking at a smartphone or tablet, and working on a computer, many patients find that it is time to seek a more permanent and convenient solution than reading glasses. This is especially true today, when wearing a face mask in public aggravates the drawbacks associated with wearing glasses.[1]

Posterior Chamber Phakic IOLs for the Correction of Presbyopia in Myopes

Patients typically experience fast visual recovery and good refractive stability.[1] Further, the lenses can be removed when patients are not satisfied with the result. Some available options include the implantable phakic contact lens (IPCL, Care Group), which has a diffractive optical zone of 5.8 mm and is available with near additions between +1.50 and 4.00 D, and the extended depth of focus (EDOF) implantable collamer lens (ICL) (EVO Viva, Staar Surgical), an EDOF posterior chamber phakic lens that uses higher-order aberrations to smooth out the dips in the defocus curve. Early clinical results are encouraging.[2] The best solution for presbyopia correction depends on the patient's age, lifestyle, status of distance vision, and personal preferences.[1]

Performance and Safety of the EDOF ICL in Phakic Subjects With Presbyopia: EU Multicenter Study[2]

Results

A total of 34 subjects completed the study. Investigators targeted emmetropia in all eyes. Mean binocular uncorrected near, intermediate, and distance visual acuities measured logMAR −0.01 ± 0.05 (20/20), −0.02 ± 0.08 (20/19), and 0.07 ± 0.10 (20/23), respectively. Mean monocular uncorrected near, intermediate, and distance visual acuities measured logMAR 0.068 ± 0.09 (20/23), 0.062 ± 0.10 (20/23), and 0.16 ± 0.12 (20/29). There were no clinically or statistically significant differences in contrast sensitivity between baseline and 6 months under any testing conditions. Subjects reported significant improvements in measures of vision-related quality of life and ability to perform tasks at all distances without glasses or contact lenses. Overall, satisfaction with the EDOF ICL was high; postoperatively, 91.2% of subjects were satisfied with their vision.

Conclusion

This multicenter, prospective clinical investigation demonstrated the ability of the EDOF ICL to correct myopia and presbyopia, resulting in improvement of uncorrected near, intermediate, and distance visual acuity without compromising the quality of vision. The EDOF ICL allowed subjects to perform tasks of daily living without glasses or contact lenses. Subjects reported significant improvements in quality of life with high levels of spectacle independence and satisfaction.

My Initial Experience With the EDOF ICL in Myopic Phakic Subjects With Presbyopia and Case Studies

References

1. Mertens E. Strategies for correcting presbyopia: the demand for presbyopia correction is growing. *CRST Europe*, Jan 2021.
2. Packer M, Alfonso JF, Aramberri J, Elies D, Fernandez J, Mertens E. Performance and safety of the extended depth of focus implantable collamer lens (EDOF ICL) in phakic subjects with presbyopia. *Clin Ophthalmol*. 2020; 14:2717-2730.

Surgical Management of the Pre-presbyopic High Hyperope

Steven J Dell MD

NOTES

In These Unprecedented Times . . .

2021 Refractive Surgery Subspecialty Day

Stephanie J Marioneaux MD

The COVID-19 pandemic has impacted us in many ways, including our ability to effectively raise critical funds used to protect sight and empower lives. This objective requires active participation and commitment to advocacy from every ophthalmologist. Contributions to the following three critical funds are a part of that commitment:

- OPHTHPAC®
- Surgical Scope Fund (SSF)
- State Eye PAC

During AAO 2021 in New Orleans, invest in OPHTHPAC and Surgical Scope Fund at one of our two booths in the convention center or online. You may also invest via phone by texting MDEYE to 41444 for OPHTHPAC and SCOPE to 51555 for the Surgical Scope Fund.

We also encourage you to stop by our booth in the Hall B Lobby to learn more about OPHTHPAC Direct, a unique program that lets you decide who receives your political support.

Please help us in these unprecedented times to continue to protect quality patient eye care for everybody. Two Academy committees made up of your ophthalmology colleagues are working hard on your behalf to ensure this outcome. The OPHTHPAC Committee continues to identify Congressional Advocates in each state to maintain close relationships with federal legislators to advance ophthalmology and patient causes. The Surgical Scope Fund Committee is raising funds to be used to protect Surgery by Surgeons during scope battles at the state level.

Our mission of "protecting sight and empowering lives" requires robust funding of both OPHTHPAC and the Surgical Scope Fund. Each of us has a responsibility to ensure that these funds are strong so that ophthalmology continues to strive, especially in these unprecedented times.

OPHTHPAC®

OPHTHPAC represents the profession of ophthalmology to the U.S. Congress. OPHTHPAC's most recent victories include the following:

Physician Relief

- ✓ Securing access to COVID-19 relief, including Provider Relief Funds and forgivable small business loans
- ✓ Pushing Congress to enact a provider-friendly "surprise" medical billing law

Medicare Payment

- ✓ Mitigating drastic Medicare cuts
- ✓ Obtaining a one-year moratorium extension on the 2% Medicare budget sequestration cut

Research & Relationships

- ✓ Increasing vision research funding by $11.6 million
- ✓ Helping get three new physicians elected to Congress, including an ophthalmologist

However, facing ophthalmology's federal issues is a continuous battle, and OPHTHPAC is always under pressure to ensure we have strong political connections in place to help protect ophthalmology, its members, and their patients.

The support OPHTHPAC receives from invested U.S. Academy members helps build the federal relationships that advance ophthalmology's agenda on Capitol Hill. These relationships allow us to have a seat at the table with legislators willing to work on issues important to us and our patients. We also use these congressional relationships to help shape the rules and regulations being developed by federal health agencies.

Get engaged with OPHTHPAC and help strengthen ophthalmology's voice on Capitol Hill as we address the following legislative and regulatory issues this year:

- Improving Medicare physician payments
- Fighting optometric scope expansion in the Veterans' Health Administration
- Obtaining relief from prior authorization and step therapy requirements that delay patient care
- Seeking solutions for rising drug prices and access to drugs in shortage
- Ensuring fair reimbursements for Part B drugs

At the Academy's annual Congressional Advocacy Day, the Academy and the **American Society of Cataract and Refractive Surgery (ASCRS)** ensure a strong presence of cataract and refractive specialists to support ophthalmology's priorities. The ASCRS also supports participation of young ophthalmologists via the Academy's Advocacy Ambassador Program. Ophthalmologists visit members of Congress and their key health staff to discuss ophthalmology priorities as part of Congressional Advocacy Day. The ASCRS remains a crucial partner with the Academy in its ongoing federal and state advocacy initiatives.

Surgical Scope Fund (SSF)

The Surgical Scope Fund (SSF) provides grants to state ophthalmology societies to support their efforts to protect patient safety from dangerous optometric surgery proposals. Since its inception, the Surgery by Surgeons campaign and the SSF, in partnership with state ophthalmology societies, has helped 41 state/territorial ophthalmology societies reject optometric scope-of-practice expansions into surgery.

If you already have made a SSF contribution, please go to safesurgerycoalition.org to see the impact of your gift.

Dollars from the SSF are critical to building complete, cutting-edge political campaigns, including media efforts (TV, radio, and social media), educating and building relationships with legislators, and educating the voting public to contact their legislators. These political campaigns help the SSF to protect patient safety by defeating optometry's surgical initiatives.

Each of these endeavors is very expensive, and no one state has the critical resources to battle big optometry on their own. Ophthalmologists must join together and donate to the SSF and to fight for patient safety.

The Secretariat for State Affairs thanks the American Society of Cataract and Refractive Surgery, who has joined state ophthalmology societies in the past in contributing to the SSF, and looks forward to its 2021 contribution. These ophthalmic organizations complete the necessary SSF support structure for the protection of our patients' sight.

State Eye PAC

It is increasingly important for all ophthalmologists to support their respective State Eye PACs because campaign contributions to legislators at the state level must come from individual ophthalmologists and cannot come from the Academy, OPHTHPAC, or the Surgical Scope Fund. The presence of a strong State Eye PAC providing financial support for campaign contributions and legislative education to elect ophthalmology-friendly candidates to the state legislature is critical, as scope-of-practice battles and many regulatory issues are all fought on the state level.

ACTION REQUESTED: Support ophthalmology's advocacy efforts

Academy Surgical Scope Fund contributions are used to support the infrastructure necessary in state legislative/regulatory battles and for public education. State PAC and OPHTHPAC contributions are necessary at the state and federal level, respectively, to help elect officials who will support the interests of our patients. Contributions to each of these three funds are necessary and help us protect sight and empower lives. Surgical Scope Fund contributions are completely confidential and may be made with corporate checks or credit cards. PAC contributions may be subject to reporting requirements.

Please respond to your Academy colleagues and be part of the community that contributes to OPHTHPAC, the Surgical Scope Fund, and your State Eye PAC. Please be part of the community that ensures ophthalmology has a strong voice in advocating for patients.

OPHTHPAC Committee

Jeffrey S Maltzman, MD (AZ)—Chair
Janet A Betchkal, MD (FL)
Mark J Gallardo MD (TX)
Thomas A Graul MD (NE)
Sohail J Hasan MD PhD (IL)
S Anna Kao MD (GA)
Julie S Lee MD (KY)
Stephanie J Marioneaux MD (VA)
Dorothy M Moore MD (DE)
Stephen H Orr MD (OH)
Niraj Patel MD (WA)
Michelle K Rhee MD (NY)
Linda Schumacher-Feero MD (ME)
Frank A Scotti MD (CA)
Jeffrianne S Young MD (IA)

Ex-Officio Members:

Tamara R Fountain MD (IL)
David B Glasser MD (MD)
David W Parke II MD (CA)
Michael X Repka MD MBA (MD)
George A Williams MD (MI)

Surgical Scope Fund Committee

Lee A Snyder MD (MD)—Chair
Vineet ("Nick") Batra MD (CA)
Robert L Bergren MD (PA)
Gareth M Lema MD PhD (NY)
Darby D Miller MD MPH (FL)
Amalia Miranda MD (OK)
Christopher C Teng MD (CT)

Ex-Officio Members:

John D Peters MD (NE)
George A Williams MD (MI)

Surgical Scope Fund	OPHTHPAC®	State EyePAC
To protect patient safety by defeating optometric surgical scope-of-practice initiatives that threaten quality surgical care	Working across the political spectrum to advance ophthalmology and protect its members and patients at the federal level. Support for candidates for U.S. Congress.	Support for candidates for state House, Senate, and governor
Political grassroots activities, government relations, PR and media campaigns	Campaign contributions, legislative education	Campaign contributions, legislative education
No funds may be used for campaign contributions or PACs.		
Contributions: Unlimited.	Contributions: Limited to $5,000	Contribution limits vary based on state regulations.
Individual, practice, corporate, and organization	Personal and corporate contributions are accepted.	
Contributions are 100% confidential.	Contributions $200 and above are on the public record.	Contributions are on the public record depending upon state statutes.

State of the Union—Thoughts on the Future of Refractive Lens Surgery and IOL Implants

Richard L Lindstrom MD

I. Definition of Refractive Cataract Surgery
   A. Enhancements of standard cataract surgery targeting superior vision when compared to standard post-cataract vision
      1. Correction of pre-existing astigmatism
      2. Targeting uncorrected vision in multiple distance ranges
      3. Targeting reduction of higher-order aberration or corneal irregularities
   B. Includes advanced diagnostics and specialty therapeutic devices

II. Patient Advantages
   A. Increased visual performance and quality of life
   B. Reduced spectacle dependence

III. Societal Advantages
   A. Higher functioning elderly population
   B. Improved surgeon skills

IV. Ophthalmologist Advantages
   A. Improved skills
   B. Improved patient outcomes
   C. Increased revenue

V. Industry Advantages
   A. Technology and innovation driven
   B. Revenue opportunity

VI. Economics: Patient and Surgeon
   A. Patient shared responsibility for charges
   B. Average additional out-of-pocket patient cost: $2441
   C. Limbal relaxing incisions: $700, toric IOL: $1419, posterior chamber IOL: $2400

VII. Economics: Surgeon and Industry
   A. $12.1 billion in 2021 provider revenue
   B. $2.2 billion in 2021 manufacturer revenue

VIII. Incidence and Prevalence, USA
   A. 2013: 10.8%
   B. 2020: 15.7%
   C. 2021: 16.2% (projected)

IX. Steady Stream of New Premium IOLs

X. Reduced dependence on glasses
   A. Trifocal: 97.5%
   B. Monofocal: 28.2%

XI. Femtosecond Laser Cataract Surgery
   A. Offered by 34.2% of doctors today
   B. Do not plan to offer: 51.9%

XII. Advanced Diagnostics Also Added

XIII. Surgery

The refractive laser surgery and IOL implant sector of ophthalmology is robust and supporting investment and innovation.

BIOMECHANICS

Biomechanics of LASIK Flap and SMILE Cap: A Prospective, Clinical Study

Pooja Khamar, MD; Rohit Shetty, MD, PhD, FCRS; Ravish Vaishnav, MD; Mathew Francis, MTech; Rudy M.M.A. Nuijts, MD, PhD; Abhijit Sinha Roy, PhD

ABSTRACT

PURPOSE: To analyze the acute effect of flap cut in laser in situ keratomileusis (LASIK) eyes and cap cut in small incision lenticule extraction (SMILE) eyes on corneal biomechanical properties of patients undergoing surgery.

METHODS: This was a prospective, interventional, longitudinal case series. Forty-eight eyes of 24 patients underwent contralateral LASIK and SMILE. Corvis ST (Oculus Optikgeräte GmbH, Wetzlar, Germany) measurements were performed preoperatively, intraoperatively, and 1 week and 1 month after surgery. In LASIK eyes, the flap was cut but not lifted before intraoperative measurements. In SMILE eyes, the cap and side cut incision were made before intraoperative measurement. Thirty biomechanical variables were analyzed, assuming multiple comparisons.

RESULTS: In LASIK and SMILE eyes, 36.7% and 13.3% of the total number of variables detected biomechanical weakening after flap and cap cuts (P = .02), respectively. Further, 13.3% and 40% of the total variables detected no biomechanical changes after flap and cap cut, respectively (P = .03). These acute biomechanical effects of flap and cap cuts did not influence 1-week and 1-month measurements (P > .05) because both LASIK and SMILE eyes showed similar biomechanical weakening.

CONCLUSIONS: Flap and cap cuts induced biomechanical weakening in patient corneas. The flap caused more weakening than the cap intraoperatively. However, biomechanical differences between LASIK and SMILE eyes were similar after removal of tissue and ongoing wound healing.

[*J Refract Surg*. 2019;35(5):324-332.]

Laser in situ keratomileusis (LASIK) has delivered safe and efficacious outcomes for correction of refractive error.[1] Despite superior screening methods and biomechanical analyses, ectasia remains an unwanted complication after LASIK.[2,3] The flap cut and tissue ablation in LASIK can cause ectasia in biomechanically compromised or suspect corneas, even in patients with low refractive error.[4] On the other hand, the cap cut in small incision lenticule extraction (SMILE) requires a smaller cut (not a near 360° flap) in the anterior stroma of the cornea. Therefore, theoretical models suggested that SMILE would have a biomechanical advantage over LASIK.[5,6] However, clinical investigations with the Ocular Response Analyzer (ORA, Reichert Inc., Depew, NY) and dynamic Scheimpflug analyzer (Corvis ST; Oculus Optikgeräte GmbH, Wetzlar, Germany) reported mostly similar biomechanical changes after SMILE and LASIK.[7-19] Therefore, theoretical models and patient measurements were not in complete agreement.

Unfortunately, none of the above biomechanical studies investigated the fundamental biomechanical differences between flap cut in LASIK and cap cut in SMILE because postoperative measurements were performed after the cuts and tissue removal were completed.[7-19] This would require an alternate study design. In this study, we conducted a contralateral biomechanical comparison of LASIK and SMILE. Corvis ST measurements were performed preoperatively and 1 week and 1 month postoperatively. We added an additional

From the Department of Cornea and Refractive Surgery, Narayana Nethralaya, Bangalore, India (PK, RS, RV); Imaging, Biomechanics and Mathematical Modeling Solutions Lab, Narayana Nethralaya Foundation, Bangalore, India (MF, ASR); and University Eye Clinic Maastricht, Maastricht University Medical Center, Maastricht, the Netherlands (RMMAN).

Submitted: November 8, 2018; Accepted: March 19, 2019

Supported in part by the Indo-German Science and Technology Center, India.

Dr. Nuijts serves as a consultant for Alcon, Asico, Chiesi, and Theapharma and a speaker for Abbott, Alcon, Bausch & Lomb, Carl Zeiss, Chiesi, HumanOptics, Ophtec, Oculentis, and Gebauer. Dr. Sinha Roy has intellectual property on biomechanical modeling of the eye through Cleveland Clinic Innovations. The remaining authors have no financial or proprietary interest in the materials presented herein.

Correspondence: Abhijit Sinha Roy, PhD, Narayana Nethralaya, #258A Hosur Road, Bommasandra, Bangalore 560099, India. E-mail: asroy27@yahoo.com

doi:10.3928/1081597X-20190319-01

measurement after flap cut in LASIK eyes and cap cut (along with the side incision) in SMILE eyes, which was performed intraoperatively before the completion of LASIK and SMILE. To our knowledge, this would be the first report of "true" biomechanical changes induced by the flap or the cap alone in corneas undergoing myopic refractive surgery. This study attempted to establish the biomechanical differences between SMILE cap and LASIK flap cut before the cornea underwent structural change caused by tissue removal. Further comparisons were performed with follow-up measurements and earlier studies.[7-19]

PATIENTS AND METHODS

This was a prospective, interventional, longitudinal case series. The study was approved by the Narayana Nethralaya Ethics Committee, Bangalore, India. Written informed consent was obtained from the patients after detailed explanation of the intraoperative measurements with the Corvis ST. The study followed the tenets of the Declaration of Helsinki. Forty-eight eyes of 24 patients underwent LASIK in one eye and SMILE in the fellow eye. Each eye was assigned to either LASIK or SMILE by a coin toss. Inclusion criteria were stable refraction (less than -10.00 diopters [D] equivalent refraction with astigmatism of not more than -3.00 D) for a period of 1 year (change less than 0.25 D) and a calculated minimum residual stromal bed thickness of 250 µm. Patients with central corneal thickness of less than 480 µm or a history of keratoconus, diabetes mellitus, collagen vascular disease, pregnancy, breastfeeding, and any prior ocular surgery or trauma were excluded from the study. Contact lens use was discontinued for at least 2 weeks before measurements.

Corvis ST measurements were performed before surgery, after flap/cap cut, and after surgery. In LASIK eyes, the flap was cut with a femtosecond laser but the flap was not lifted. In the fellow eye undergoing SMILE, only the side cut incision and three-dimensional geometry of the lenticule was cut but not separated from the surrounding stroma. The patient waited in the surgical area for 3 hours because the area had controlled temperature and humidity for surgical procedures such as LASIK (as recommended by the manufacturer). The Corvis ST measurement was repeated in both eyes. After the measurement, the patient's eye was redocked to the excimer laser and LASIK was completed by lifting the flap and ablating the underlying stroma. SMILE was completed by separating the lenticule from the stroma and extracting it through the side cut in the fellow eye. Corvis ST measurements were repeated at 1 week and 1 month postoperatively. In LASIK eyes, Corvis ST measurements were not repeated after flap lifting due to possible challenges in centering the patient cornea for LASIK and the risk of infections/inflammations. Intraoperative use of the Corvis ST also had the added risk of flap dislocation if it was performed immediately after completion of LASIK. Similar risks of infection/inflammation were also possible in SMILE eyes. Therefore, no measurements were performed after either flap lifting or lenticule separation from the surrounding tissue or immediately after completion of surgeries.

A single experienced surgeon (RS) performed all surgeries under topical anesthesia using 0.5% proparacaine hydrochloride (Paracain; Sunways Pvt. Ltd., Mumbai, India) instilled two or three times. The WaveLight FS200 femtosecond laser and WaveLight EX500 excimer laser platform (Alcon Laboratories, Inc., Fort Worth, TX) cut the flap and ablated the tissue in one eye. The flap had a 9-mm diameter, 110-µm thickness, side cut angle of 70°, canal width of 1.5 mm, and hinge position at 90°. The optical zone diameter was 6 mm. The VisuMax femtosecond laser system (Carl Zeiss Meditec AG, Jena, Germany) cut the cap and lenticule in the fellow eye. Cap thickness was 110 µm. Lenticule and cap diameter was 6 and 7.7 mm, respectively. After creation of the refractive lenticule, it was dissected and extracted manually through a superior 3-mm side cut. The cornea was remoistened with a wet Merocel sponge (Beaver-Vistec International, Waltham, MA) at the end of the procedure. After the surgery, one drop of moxifloxacin hydrochloride 0.5% (Vigamox; Alcon Laboratories, Inc.) was applied to both eyes. The routine postoperative regimen was followed for both eyes. This included moxifloxacin hydrochloride 0.5% eye drops (Vigamox) four times a day for 1-week, tapering doses of topical 1% fluorometholone eye drops (Flarex; Alcon Laboratories, Inc.), and topical lubricants (Optive; Allergan, Inc., Parsippany, NJ) four times a day for 3 months.

Thirty Corvis ST variables were analyzed. The variables were either machine derived or determined from waveform analyses of the entire deformation amplitude signal.[19,20] The analyzed primary variables were as follows:

1. Arc length of the cornea (Arc length), time (Time), velocity (Velocity), deformation amplitude (DA), deflection amplitude, and horizontal length (Deflection length) of the cornea between the two peripheral corneal bends of 1st applanation (A1), 2nd applanation (A2), and highest concavity (HC);
2. Maximum deformation amplitude (DA Max), deflection amplitude (Deflection amplitude Max) and its time (Deflection amplitude Max Time), and arc length (Arc length Max);

TABLE 1
Preoperative Demographics (Median [95% CI])

Parameter	LASIK (n = 24)	SMILE (n = 24)	*P*
Intraocular pressure (bIOP, mm Hg)	16 (14 to 17.7)	16.1 (14.4 to 17.1)	.69
Central corneal thickness (μm)	528.4 (509.2 to 546.3)	521.0 (503.4 to 542)	.12
Sphere (D)	-4.25 (-5.50 to -3.00)	-4.00 (-5.31 to -3.00)	.83
Cylinder (D)	-0.88 (-1.06 to -0.44)	-0.50 (-0.81 to -0.25)	.29
Spherical equivalent (D)	-4.56 (-6.13 to -3.69)	-4.44 (-5.47 to -3.47)	.57

CI = confidence interval; LASIK = laser in situ keratomileusis; SMILE = small incision lenticule extraction; D = diopters

3. Ratio of DA between the center and periphery (1 mm and 2 mm) designated as DA Ratio Max 1mm and DA Ratio Max 2mm, respectively
4. Integrated radius and maximum inverse of concave radius of curvature (Max Inverse radius);
5. Stiffness parameter at A1 (SP-A1);
6. Corneal stiffnesses [Kc (constant) and Kc (mean)] derived from waveform analyses of deformation amplitude signal with a biomechanical model[19,20];
7. Maximum whole eye movement and its time.

Two other variables, ARTh (Ambrósio relational thickness) and the Corvis Biomechanical Index (CBI), were also assessed. ARTh described the distribution of corneal thickness relative to its minimum value in a given cornea. The CBI included ARTh in its derivation. Therefore, ARTh and the CBI were analyzed as a secondary set of variables because reduced thickness artificially affected their measurements. Also, it was assumed that the surgery, having a greater proportion of variables indicating biomechanical change (weakening) after flap/cap cut, caused a greater biomechanical weakening of the cornea overall. Thus, the proportion of variables indicating biomechanical change versus no biomechanical change after flap/cap cut was statistically compared between the LASIK and SMILE eyes.

Statistical Analyses

All continuous variables were assessed for normality of distribution with the Kolmogorov–Smirnov test. Because some variables were non-parametric in distribution, the Friedman test for repeated measures was used. For a non-parametric distribution, the median with 95% confidence interval (CI) was calculated for each variable. Repeated measures analyzed each variable (in a paired manner) between time points simultaneously for a given eye. The "N-1" chi-square test was used to compare the proportions. MedCalc software (version 18.7; MedCalc Inc., Ostend, Belgium) was used for statistical analyses. The software adjusted the *P* value for repeated measures. These repeated measures were preoperative (1), flap/cap cut (2), 1 week (3), and 1 month (4). A *P* value of less than .05 was considered statistically significant.

RESULTS

Table 1 lists the preoperative features of LASIK and SMILE eyes. All features were similar between the two groups ($P > .05$). The median corrected distance visual acuity was 0.0 logMAR (95% CI: 0.0 to 0.0 logMAR) preoperatively. At 1 month postoperatively, the median uncorrected distance visual acuity was 0.0 logMAR (95% CI: -0.13 to 0.13 logMAR). **Table 2** lists the Corvis ST variables of the LASIK eyes. The last column describes the results of the statistical comparisons. Some of the variables indicated reduction in corneal strength (eg, lower stiffness, shorter lengths, earlier A1 and later A2 times, greater deformation and deflection amplitudes, and lower inverse radius and greater integrated radius). Among the 31 variables, 4 (13.3% of the total number of variables) were similar between preoperative and flap cut but differed ($P < .01$) from 1 week and 1 month [(1),(2) versus (3),(4) in **Table 2**]. Eleven (36.7%) variables were such that both preoperative and flap cut differed significantly ($P < .01$) from each other and from 1 week and 1 month [(1) versus rest, (2) versus rest in **Table 2**]. Nine (30.0%) variables were similar among all time points ($P > .05$, not significant in **Table 2**). Five (13.3%) variables were similar among flap cut, 1 week, and 1 month timepoints but differed significantly ($P < .01$) from preoperative [(1) versus rest in **Table 2**].

Table 3 lists the Corvis ST variables of the SMILE eyes. The last column describes the results of the statistical comparisons. Similar to LASIK eyes, some of the variables indicated a decrease in corneal strength after SMILE. However, the proportion of variables was different. For preoperative, cap cut versus 1 week and 1 month [(1),(2) versus (3),(4) in **Table 3**], 12 (40.0%) met the significance criteria. For preoperative versus rest, cap cut versus rest [(1) versus rest, (2) versus rest in

TABLE 2
Biomechanical Parameters of LASIK Patients[a]

Parameter	Preoperative (1)	Flap Cut (2)	1 Week (3)	1 Month (4)	P[b]
A1					
Arc length (mm)	-0.017 (-0.02 to 0.013)	-0.015 (-0.022 to -0.014)	-0.013 (-0.014 to -0.01)	-0.011 (-0.013 to -0.007)	All
Deflection amplitude (mm)	0.095 (0.086 to 0.10)	0.093 (0.086 to 0.107)	0.083 (0.070 to 0.088)	0.079 (0.067 to 0.084)	(1) to (2) vs (3) to (4)
Deflection length (mm)	2.25 (2.14 to 2.38)	2.23 (2.11 to 2.37)	2.02 (1.75 to 2.09)	1.90 (1.54 to 2.06)	(1),(2) vs (3),(4)
DA (mm)	0.135 (0.12 to 0.14)	0.13 (0.12 to 0.15)	0.12 (0.10 to 0.13)	0.11 (0.10 to 0.12)	(1),(2) vs (3),(4)
Time (ms)	7.40 (7.23 to 7.61)	7.30 (7.20 to 7.5)	7.06 (6.95 to 7.25)	7.12 (7.02 to 7.24)	(1) vs rest, (2) vs rest
Velocity (m/s)	0.15 (0.138 to 0.158)	0.15 (0.143 to 0.162)	0.16 (0.153 to 0.166)	0.157 (0.147 to 0.164)	NS
A2					
Arc length (mm)	-0.025 (-0.029 to 0.022)	-0.024 (-0.029 to -0.017)	-0.015 (-0.019 to -0.013)	-0.014 (-0.017 to 0.011)	(1) to (2) vs (3) to (4)
Deflection amplitude (mm)	0.11 (0.10 to 0.12)	0.12 (0.11 to 0.13)	0.092 (0.08 to 0.1)	0.088 (0.081 to 0.095)	(1),(2) vs (3),(4)
Deflection length (mm)	3.0 (2.66 to 3.16)	2.93 (2.71 to 3.12)	2.31 (2.02 to 3.49)	2.21 (1.67 to 3.36)	NS
DA (mm)	0.36 (0.35 to 0.40)	0.35 (0.33 to 0.42)	0.36 (0.32 to 0.38)	0.36 (0.32 to 0.38)	NS
Time (ms)	21.50 (21.34 to 21.67)	21.54 (21.24 to 21.70)	21.74 (21.60 to 21.87)	21.77 (21.54 to 21.86)	(1) vs rest, (2) vs rest
Velocity (m/s)	-0.29 (-0.30 to -0.27)	-0.30 (-0.32 to -0.28)	-0.30 (-0.32 to -0.29)	-0.29 (-0.31 to -0.28)	NS
DA ratio max 1mm	1.60 (1.58 to 1.62)	1.58 (1.55 to 1.61)	1.69 (1.65 to 1.71)	1.70 (1.67 to 1.75)	(1) vs rest, (2) vs rest
DA ratio max 2mm	4.34 (4.15 to 4.50)	4.45 (4.17 to 4.82)	5.24 (4.82 to 5.53)	5.19 (4.88 to 5.39)	(1) vs rest, (2) vs rest
Arc length max (mm)	-0.19 (-0.20 to 0.17)	-0.17 (-0.19 to -0.16)	-0.13 (-0.15 to -0.10)	-0.12 (-0.15 to -0.095)	(1) vs rest to (2) vs rest
DA max (mm)	1.14 (1.04 to 1.16)	1.17 (1.07 to 1.25)	1.16 (1.12 to 1.22)	1.19 (1.12 to 1.28)	(1) vs rest
Deflection amplitude max (mm)	0.98 (0.94 to 1.03)	1.02 (0.96 to 1.08)	1.06 (1.01 to 1.10)	1.05 (1.02 to 1.15)	(1) vs rest, (2) vs (4)
Deflection amplitude max time (ms)	16.11 (16.06 to 16.27)	15.91 (15.70 to 16.08)	16.14 (15.94 to 16.31)	16.17 (15.76 to 16.50)	NS
HC					
Arc length (mm)	-0.153 (-0.163 to -0.147)	-0.141 (-0.15 to -0.12)	-0.105 (-0.130 to -0.089)	-0.092 (-0.108 to -0.069)	(1) vs rest, (2) vs rest
Deflection amplitude (mm)	0.98 (0.93 to 1.02)	1.01 (0.95 to 1.05)	1.04 (1.0 to 1.1)	1.04 (1.0 to 1.11)	(1) vs rest, (2) vs rest
Deflection length (mm)	6.76 (6.42 to 6.83)	6.72 (6.54 to 6.89)	6.64 (6.53 to 6.89)	6.71 (6.55 to 6.74)	NS
DA (mm)	1.14 (1.04 to 1.16)	1.17 (1.07 to 1.25)	1.16 (1.12 to 1.22)	1.19 (1.12,1.28)	(1) vs rest
Time (ms)	15.86 (15.21 to 16.49)	15.55 (15.02 to 16.63)	15.29 (15.09 to 16.63)	15.42 (15.12 to 16.78)	NS
Integrated radius (mm)	7.69 (7.28 to 7.94)	8.18 (7.40 to 8.58)	9.76 (9.08 to 10.53)	9.88 (9.10 to 10.60)	(1) vs rest, (2) vs rest
Kc (constant) [N/m]	105.6 (99.8 to 108.9)	101.68 (95.75 to 106.59)	95.34 (92.40 to 100.83)	98.94 (88.97 to 102.08)	(1) vs rest, (2) vs rest
Kc (mean) [N/m]	96.1 (91.3 to 103.1)	90.09 (86.45 to 97.26)	81.78 (77.03 to 89.91)	85.74 (77.07 to 90.92)	(1) vs rest, (2) vs rest
Max inverse radius (mm-1)	0.167 (0.158 to 0.176)	0.186 (0.165 to 0.207)	0.195 (0.183 to 0.204)	0.194 (0.186 to 0.205)	(1) vs rest, (2) vs rest
SP_A1	102.9 (91.5 to 112.4)	94.69 (87.18 to 103.31)	95.06 (72.93 to 103.74)	98.93 (78.92 to 103.63)	(1) vs rest
Whole eye movement max (mm)	0.258 (0.243 to 0.293)	0.265 (0.236 to 0.319)	0.245 (0.206 to 0.277)	0.277 (0.227 to 0.295)	NS
Whole eye movement max time (ms)	21.78 (21.53 to 22.47)	21.61 (21.31 to 22.49)	21.46 (21.17 to 21.84)	21.62 (21.02 to 22.02)	NS

LASIK = laser in situ keratomileusis; A1 = 1st applanation; A2 = 2nd applanation; HC = highest concavity; DA = deformation amplitude; Kc = keratoconus; SP-A1 = is the stiffness parameters at A1 time; NS = not significant
[a]Values are presented as median (95% confidence interval).
[b]Significant differences between the time-points [(1),(2),(3),(4)]. For example, (1)(2) vs (3),(4) indicates that (1) and (2) were similar but differed significantly from both (3) and (4). P < *.01.*

Table 3], only 4 (13.3%) met the criteria. Five variables (16.7%) were not significant among all time-points ($P > .05$, not significant). Seven (20.0%) met the criteria of preoperative versus rest [(1) versus rest in **Table 3**]. For preoperative cap cut versus 1 week and 1 month [(1),(2) versus (3),(4)], the proportion of variables was significantly different ($P = .02$) between the LASIK and SMILE eyes. For preoperative versus rest, cap cut versus rest criteria [(1) versus rest, (2) versus rest], the proportion of variables also was significantly different ($P = .02$) between the LASIK and SMILE eyes ($P = .03$). Overall, corneal stiffness parameters decreased after creation of flap/cap and reduced further after completion of LASIK/SMILE procedures. These decreases in

TABLE 3
Biomechanical Parameters of SMILE Patients[a]

Parameter	Preoperative (1)	Cap Cut (2)	1 Week (3)	1 Month (4)	P[b]
A1					
Arc length (mm)	-0.015 (-0.019 to 0.012)	-0.017 (-0.019 to -0.014)	-0.012 (-0.014 to -0.007)	-0.010 (-0.012 to -0.008)	(1),(2) vs (3),(4)
Deflection amplitude (mm)	0.090 (0.084 to 0.099)	0.099 (0.089 to 0.101)	0.076 (0.073 to 0.086)	0.077 (0.071 to 0.084)	(1),(2) vs (3),(4)
Deflection length (mm)	2.17 (2.07 to 2.29)	2.20 (2.09 to 2.36)	1.91 (1.65 to 2.04)	1.92 (1.79 to 2.01)	(1),(2) vs (3),(4)
DA (mm)	0.13 (0.12 to 0.14)	0.13 (0.125 to 0.139)	0.11 (0.10 to 0.13)	0.11 (0.10 to 0.12)	(1),(2) vs (3),(4)
Time (ms)	7.41 (7.25 to 7.51)	7.25 (7.09 to 7.40)	7.04 (6.96 to 7.17)	7.08 (6.90 to 7.17)	(1) vs rest, (2) vs rest
Velocity (m/s)	0.151 (0.145 to 0.156)	0.16 (0.155 to 0.165)	0.161 (0.155 to 0.164)	0.159 (0.151 to 0.166)	(1) vs rest
A2					
Arc length (mm)	-0.025 (-0.027 to 0.020)	-0.022 (-0.025 to -0.014)	-0.014 (-0.018 to -0.008)	-0.013 (-0.017 to -0.006)	(1),(2) vs (3),(4)
Deflection amplitude (mm)	0.116 (0.109 to 0.119)	0.116 (0.106 to 0.129)	0.093 (0.086 to 0.108)	0.089 (0.075 to 0.100)	(1),(2) vs (3),(4)
Deflection length (mm)	3.48 (3.12 to 3.75)	3.80 (2.98 to 3.96)	2.97 (2.15 to 3.60)	3.08 (2.65 to 3.62)	(1),(2) vs (3),(4)
DA (mm)	0.36 (0.35 to 0.39)	0.40 (0.37 to 0.45)	0.35 (0.30 to 0.39)	0.37 (0.30 to 0.38)	NS
Time (ms)	21.55 (21.41 to 21.67)	21.72 (21.59 to 21.81)	21.78 (21.63 to 21.85)	21.80 (21.67 to 21.96)	(1) vs rest, (2) vs (4)
Velocity (m/s)	-0.292 (-0.312 to 0.288)	-0.311 (-0.317 to -0.302)	-0.305 (-0.326 to -0.294)	-0.300 (-0.311 to -0.283)	(1) vs (2),(3)
DA ratio max 1mm	1.60 (1.56 to 1.62)	1.60 (1.56 to 1.63)	1.70 (1.66 to 1.74)	1.70 (1.69 to 1.75)	(1),(2) vs (3),(4)
DA ratio max 2mm	4.29 (4.15 to 4.57)	4.44 (4.30 to 4.76)	5.13 (4.98 to 5.68)	5.44 (5.10 to 5.80)	(1) vs rest, (2) vs rest
Arc length max (mm)	-0.18 (-0.19 to -0.16)	-0.18 (-0.19 to -0.16)	-0.11 (-0.15 to -0.10)	-0.11 (-0.15 to -0.10)	(1),(2) vs (3),(4)
DA max (mm)	1.12 (1.09 to 1.18)	1.18 (1.12 to 1.23)	1.19 (1.12 to 1.23)	1.22 (1.11 to 1.27)	(1) vs rest
Deflection amplitude max (mm)	0.99 (0.96 to 1.06)	1.02 (0.99 to 1.06)	1.04 (1.00 to 1.14)	1.07 (1.01 to 1.16)	(1),(2) vs (3),(4)
Deflection amplitude max time (ms)	15.96 (15.67 to 16.18)	16.03 (15.75 to 16.15)	16.0 (15.90 to 16.14)	15.8 (15.4 to 16.14)	NS
HC					
Arc length (mm)	-0.148 (-0.159 to -0.137)	-0.141 (-0.155 to -0.107)	-0.092 (-0.100 to -0.080)	-0.089 (-0.099 to -0.065)	(1),(2) vs (3),(4)
Deflection amplitude (mm)	0.98 (0.94 to 1.04)	1.0 (0.98 to 1.05)	1.03 (0.99 to 1.13)	1.06 (0.99 to 1.12)	(1) vs rest, (2) vs (3)
Deflection length (mm)	6.66 (6.48 to 6.72)	6.80 (6.67 to 6.94)	6.65 (6.52 to 6.91)	6.64 (6.37 to 6.80)	NS
DA (mm)	1.12 (1.09 to 1.18)	1.18 (1.12 to 1.23)	1.19 (1.12 to 1.23)	1.22 (1.11 to 1.27)	(1) vs rest
Time (ms)	15.59 (15.35 to 16.76)	16.0 (15.32 to 16.65)	15.67 (15.25 to 16.43)	15.94 (15.48 to 16.51)	NS
Integrated radius (mm)	7.99 (7.07 to 8.37)	8.46 (7.82 to 9.15)	9.61 (9.17 to 10.50)	10.05 (9.45 to 10.76)	(1) vs rest, (2) vs rest
Kc (constant) [N/m]	102.4 (97.7 to 106.9)	96.9 (94.7 to 101.9)	96.3 (90.8 to 100.8)	93.3 (89.3 to 98.2)	(1) vs rest, (2) vs (4)
Kc (mean) [N/m]	94.0 (85.9 to 97.6)	86.6 (82.8 to 89.4)	82.2 (76.2 to 88.3)	80.9 (75.8 to 86.6)	(1) vs rest, (2) vs rest
Max inverse radius (mm^{-1})	0.174 (0.162 to 0.184)	0.185 (0.168 to 0.195)	0.195 (0.182 to 0.203)	0.202 (0.193 to 0.214)	(1),(2) vs (3),(4)
SP_A1	104.5 (101.5 to 111.1)	96.9 (83.7 to 103.1)	85.5 (76.2 to 100.1)	86.1 (74.1 to 98.1)	(1) vs rest, (2) vs (4)
Whole eye movement max (mm)	0.264 (0.24 to 0.29)	0.308 (0.269 to 0.332)	0.262 (0.220 to 0.300)	0.29 (0.222 to 0.307)	(2) vs rest
Whole eye movement max time (ms)	21.85 (21.31 to 22.56)	21.83 (21.33 to 22.60)	21.66 (21.28 to 22.04)	21.48 (21.30 to 22.00)	NS

SMILE = small incision lenticule extraction; A1 = 1st applanation; A2 = 2nd applanation; HC = highest concavity; DA = deformation amplitude; Kc = keratoconus; SP-A1 = is the stiffness parameters at A1 time; NS = not significant
[a]Values are presented as median (95% confidence interval).
[b]Significant differences between the time-points [(1),(2),(3),(4)]. For example, (1)(2) vs (3),(4) indicates that (1) and (2) were similar but differed significantly from both (3) and (4). P < *.01.*

magnitudes of stiffnesses up to 1 week and 1 month were similar between the two procedures ($P > .20$).

In LASIK eyes, median ARTh was 442.8, 368.6, 201.4, and 193.1 at preoperative (1), flap cut (2), 1 week (3), and 1 month (4), respectively [(1),(2) versus (3),(4), $P < .01$]. The CBI was 0.016, 0.22, 0.99, and 0.98, respectively [(1) versus rest, (2) versus rest, $P < .01$]. In SMILE eyes, ARTh was 388.7, 409.1, 190.9, and 193.9, respectively [(1),(2) versus (3),(4), $P < .01$]. The corresponding CBI was 0.029, 0.027, 0.99, and 0.99, respectively [$P <$ .01; (1) versus rest, (2) versus rest]. At later follow-up visits (1 week and 1 month), no significant differences were observed between LASIK and SMILE eyes with respect to change in the variables ($P > .05$). **Tables 4-5** show the change in the indices: 1 week minus preoperative and 1 month minus preoperative, respectively.

TABLE 4
Change in Biomechanical Parameters (1 Week Minus Preoperative)[a]

Parameter	LASIK	SMILE
A1		
Arc length (mm)	0.004 (0.001 to0.007)	0.005 (0.002 to 0.007)
Deflection amplitude (mm)	-0.013 (-0.021 to -0.006)	-0.013 (-0.017 to -0.007)
Deflection length (mm)	-0.32 (-0.45 to -0.16)	-0.21 (-0.44 to -0.073)
DA (mm)	-0.016 (-0.021 to -0.01)	-0.012 (-0.023 to -0.007)
Time (ms)	-0.33 (-0.41 to -0.26)	-0.35 (-0.38 to -0.22)
Velocity (m/s)	0.01 (0.0 to 0.022)	0.012 (0.0 to 0.017)
A2		
Arc length (mm)	0.01 (0.005 to 0.014)	0.01 (0.006 to 0.015)
Deflection amplitude (mm)	-0.02 (-0.033 to -0.007)	-0.021 (-0.031 to -0.013)
Deflection length (mm)	-0.42 (-0.65 to 0.08)	-0.55 (-0.74 to -0.03)
DA (mm)	-0.041 (-0.08 to 0.01)	-0.025 (-0.054 to 0.022)
Time (ms)	0.27 (0.19 to 0.33)	0.24 (0.14 to 0.32)
Velocity (m/s)	-0.020 (-0.028 to 0.0)	-0.013 (-0.023 to 0.0)
DA ratio max 1mm	0.09 (0.06 to 0.13)	0.11 (0.07 to 0.14)
DA ratio max 2mm	0.83 (0.67 to 1.05)	1.0 (0.77 to 1.22)
Arc length max (mm)	0.059 (0.039 to 0.075)	0.053 (0.036 to 0.064)
DA max (mm)	0.065 (0.02 to 0.09)	0.058 (0.044 to 0.091)
Deflection amplitude max (mm)	0.072 (0.05 to 0.11)	0.055 (0.040 to 0.078)
Deflection amplitude max time (ms)	0.020 (-0.16 to 0.22)	-0.033 (-0.19 to 0.24)
HC		
Arc length (mm)	0.05 (0.025 to 0.065)	0.059 (0.033 to 0.088)
Deflection amplitude (mm)	0.077 (0.049 to 0.106)	0.067 (0.046 to 0.081)
Deflection length (mm)	0.056 (-0.089 to 0.155)	0.073 (-0.109 to 0.323)
DA (mm)	0.065 (0.021 to 0.09)	0.058 (0.044 to 0.091)
Time (ms)	0.039 (-0.20 to 0.25)	-0.154 (-0.35 to 0.09)
Integrated radius (mm)	1.79 (1.64 to 2.41)	2.04 (1.66 to 2.28)
Kc (constant) [N/m]	-7.55 (-11.48 to -5.61)	-6.36 (-9.09 to -2.86)
Kc (mean) [N/m]	-14.06 (-18.16 to -8.78)	-10.15 (-12.91 to -7.98)
Max inverse radius (mm^{-1})	0.024 (0.015 to 0.03)	0.020 (0.016 to 0.024)
SP_A1	-13.56 (-22.81 to -7.71)	-16.857 (-25.7 to -11.44)
Whole eye movement max (mm)	-0.032 (-0.054 to -0.0)	0.0 (-0.029 to 0.027)
Whole eye movement max time (ms)	-0.203 (-0.484 to 0.179)	-0.180 (-0.883 to 0.64)

LASIK = laser in situ keratomileusis; SMILE = small incision lenticule extraction; A1 = 1st applanation; A2 = 2nd applanation; HC = highest concavity; DA = deformation amplitude; Kc = keratoconus; SP-A1 = is the stiffness parameters at A1 time
[a]Values are presented as median (95% confidence interval).

At 1 month, median intraocular pressure (bIOP in Corvis ST) was 16.1 mm Hg (95% CI: 14.2 to 16.6 mm Hg) and 15 mm Hg (95% CI: 14.1 to 16.1 mm Hg) in LASIK and SMILE eyes, respectively (P = .52). Also, median central corneal thickness was 459.5 µm (95% CI: 442.2 to 508.3 µm) and 457.7 µm (95% CI: 437.7 to 499 µm) in LASIK and SMILE eyes, respectively (P = .45). Thus, intraocular pressure and central corneal thickness were not confounders affecting the variables differentially between the groups postoperatively.

DISCUSSION

A recent study tested the difference in corneal elastic modulus of human corneal samples ex vivo (two-dimensional stretch testing) after LASIK and SMILE.[21] The study showed that the modulus of SMILE corneas was 1.47 times that of LASIK corneas.[21] Another ex vivo study on LASIK flap with Brillouin scattering implied reduced Brillouin modulus after flap creation in the anterior (one-third region) stroma of porcine eyes.[22] Thus, severing of the fibers by either flap or cap should lead to

TABLE 5
Change in Biomechanical Parameters (1 Month Minus Preoperative)[a]

Parameter	LASIK	SMILE
A1		
Arc length (mm)	0.006 (0.003 to 0.009)	0.005 (0.003 to 0.008)
Deflection amplitude (mm)	-0.016 (-0.025 to -0.009)	-0.009 (-0.019 to-0.004)
Deflection length (mm)	-0.44 (-0.64 to -0.23)	-0.22 (-0.35 to-0.12)
DA (mm)	-0.017 (-0.024 to -0.009)	-0.018 (-0.027 to-0.009)
Time (ms)	-0.36 (-0.44 to -0.23)	-0.34 (-0.42 to-0.28)
Velocity (m/s)	0.01 (0.0 to 0.019)	0.006 (0.0 to 0.011)
A2		
Arc length (mm)	0.01 (0.007 to 0.013)	0.013 (0.008 to 0.015)
Deflection amplitude (mm)	-0.02 (-0.033 to-0.019)	-0.027 (-0.040 to -0.019)
Deflection length (mm)	-0.33 (-0.83 to 0.29)	-0.32 (-0.80 to 0.22)
DA (mm)	-0.020 (-0.038 to 0.007)	-0.027 (-0.040 to 0.019)
Time (ms)	0.29 (0.15 to 0.40)	0.29 (0.12 to 0.40)
Velocity (m/s)	0.0 (-0.025 to 0.01)	-0.006 (-0.019 to 0.006)
DA ratio max 1mm	0.10 (0.07 to 0.14)	0.12 (0.07 to 0.15)
DA ratio max 2mm	0.96 (0.64 to 1.08)	1.05 (0.89 to 1.24)
Arc length max (mm)	0.063 (0.041 to 0.074)	0.059 (0.033 to 0.078)
DA max (mm)	0.088 (0.05 to 0.12)	0.070 (0.030 to 0.094)
Deflection amplitude max (mm)	0.085 (0.055 to 0.11)	0.081 (0.05 to 0.10)
Deflection amplitude max time (ms)	0.058 (-0.41 to 0.31)	-0.087 (-0.47 to 0.24)
HC		
Arc length (mm)	0.06 (0.053 to 0.074)	0.059 (0.036 to 0.084)
Deflection amplitude (mm)	0.067 (0.032 to 0.086)	0.058 (0.008 to 0.12)
Deflection length (mm)	0.058 (-0.188 to 0.14)	0.068 (-0.162 to 0.157)
DA (mm)	0.088 (0.049 to 0.118)	0.067 (0.030 to 0.094)
Time (ms)	0.27 (-0.11 to 0.38)	0.17 (-0.23 to 0.44)
Integrated radius (mm)	2.27 (1.56 to 2.76)	2.29 (1.62 to 2.50)
Kc (constant) [N/m]	-7.73 (-11.13 to-4.65)	-6.99 (-10.07 to-3.64)
Kc (mean) [N/m]	-11.87 (-16.02 to-11.11)	-10.47 (-13.74 to-7.16)
Max inverse radius (mm^{-1})	0.021 (0.018 to 0.027)	0.032 (0.019 to 0.040)
SP_A1	-9.641 (-24.77 to -7.45)	-11.251 (-25.7 to-8.44)
Whole eye movement max (mm)	0.021 (-0.018 to 0.04)	0.0 (-0.015 to 0.018)
Whole eye movement max time (ms)	-0.21 (-0.846 to 0.01)	-0.249 (-0.831 to 0.237)

LASIK = laser in situ keratomileusis; SMILE = small incision lenticule extraction; A1 = 1st applanation; DA = deformation amplitude; A2 = 2nd applanation; HC = highest concavity; Kc = keratoconus; SP-A1 = is the stiffness parameters at A1 time
[a]Values are presented as median (95% confidence interval).

some biomechanical weakening. However, no clinical study on patients had quantified exclusively the biomechanical effect of flap and cap in patients undergoing refractive surgery. The novel aspect of this study was the exclusive assessment of flap- and cap-induced deformation changes in the patient corneas intraoperatively. The Corvis ST allowed exclusive assessment of deformation of the cornea in response to air-puff applanation. A salient finding of this study was that flap and cap cut differences were actually detected by the Corvis ST. In **Tables 2-3**, two statistical inferences were key. First, (1),(2) versus (3),(4) indicated a significant difference between the first two and the last two time-points but (1) and (2) were similar (**Tables 2-3**). Second, (1) versus rest, (2) versus rest indicated that significant differences existed between preoperative and flap/cap cut but changes at 1 week and 1 month were similar. Using the above definitions, the salient findings of the study were as follows:

1. As expected, some of the deformation variables indicated biomechanical weakening after flap and

cap creation (eg, decrease in stiffness, earlier 1st applanation).

2. Temporal assessment of these variables also showed increased weakening of the cornea after tissue removal (ablation and lenticule extraction) (eg, Kc [constant] and Kc [mean]).
3. In LASIK, 36.7% of the variables belonged to preoperative versus rest [(1) versus rest], flap cut versus rest [(2) versus rest], indicating significant biomechanical changes after flap creation. This changed to 13.3% in SMILE eyes (P = .02), indicating that the LASIK flap caused a greater biomechanical change in the cornea than the SMILE cap.
4. The above observation was also supported by the percentage of variables in the preoperative, flap/cap cut versus 1 week, 1 month [(1),(2) versus (3),(4)] significance group.
5. In LASIK and SMILE eyes, 50% and 46.7% of the variables were unchanged after surgery at all timepoints, respectively. Transient corneal deformation by applanation is three-dimensional, but only two-dimensional variables were either reported by the device or calculated by waveform analyses. Thus, not all variables were affected by the surgery and this proportion was nearly the same in both LASIK and SMILE eyes. Only those variables, altered due to surgery, were of interest.
6. Interestingly, the variables reported similar magnitude of change between LASIK and SMILE eyes up to 1 week and 1 month. This indicated that the biomechanical effect of tissue removal was the primary determinant of the change in deformation variables 1 week and 1 month after surgery despite the differences seen after flap/cap cut.

The link between the intraoperative and the follow-up measurements was analyzed in this study for the first time. It was possible that some acute edema in the cornea intraoperatively may have led to inaccuracies in the detection of the posterior edge and corneal thickness. Therefore, a sharp decrease in ARTh was noted from preoperative (1) to flap cut (2), which was not observed clinically. This new effect was not reported earlier. ARTh is representative of corneal thickness distribution from the center to the periphery of a cornea.[23] Because no tissue was removed after flap/cap cut, significant changes in ARTh from preoperative to flap/cap cut were probably artifactual. The CBI included ARTh and its results were also affected.[23] Neither quality assessment of posterior edge detection nor occurrence of flap/cap interface edema was possible because optically distorted corrected Scheimpflug images were not available to us. Thus, the CBI and ARTh may not be useful to assess the flap/cap effects on corneal deformation relative to the preoperative state. However, ARTh and the CBI may still be useful to detect progressive onset of ectasia in the long term after surgery.[23] The variables in **Tables 2-3** were derived exclusively from the anterior edge of the cornea (interface of air and epithelium) and did not suffer from either the limitations of posterior edge detection or edema.

Among the ORA studies, 6 reported no difference between LASIK and SMILE eyes and 4 reported a better biomechanical outcome after SMILE than LASIK.[7-16] Among the Corvis ST studies, 3 reported that some biomechanical variables reported better outcomes after SMILE than LASIK.[7,10,19] The other studies (2) reported no biomechanical differences between LASIK and SMILE eyes.[17,18] Thus, similar biomechanical outcomes after LASIK and SMILE in the long term may be the logical conclusion because definitive trends were obtained. These findings were similar to the 1-week (3) and 1-month (4) outcomes (**Tables 2-3**). Our earlier study also showed similar biomechanical changes after LASIK and SMILE up to 6 months of follow-up with the Corvis ST.[19] Thus, extending this study to a longer follow-up beyond 1 month was not essential.

Other than biomechanical outcomes, SMILE and LASIK have differences in temporal wound healing and visual recovery.[24,25] Currently, no clinical device directly quantifies viscoelastic relaxation,[26] collagen crimping,[19] and tissue hydration[26] in patients. This limits the scope of the analyses that could be performed by us or in future studies. However, our results indicated that temporal wound healing of the cornea minimized the acute biomechanical differences between cap and flap to an extent that no significant biomechanical differences between LASIK and SMILE eyes were detected at 1 week and 1 month. Refined techniques such as inverse finite element modeling of patient corneal biomechanical properties with applanation may shed more light on the finer differences between LASIK and SMILE eyes.[27,28] SMILE cap appeared to cause less biomechanical change in the cornea than LASIK flap in patient corneas. This is a unique finding. Further, temporal healing of the cornea and tissue appeared to dominate the biomechanical differences induced in the acute phase by the flap and cap cuts. Thus, safety criteria established for recommending LASIK to patients should also be followed for recommending SMILE. This requires further evaluation in future studies.

AUTHOR CONTRIBUTIONS

Study concept and design (RS, RMMAN, ASR); data collection (RS); analysis and interpretation of

data (PK, RV, MF, ASR); writing the manuscript (PK, RV, MF, ASR); critical revision of the manuscript (RS, RMMAN); statistical expertise (ASR)

REFERENCES

1. Bailey MD, Zadnik K. Outcomes of LASIK for myopia with FDA-approved lasers. *Cornea*. 2007;26:246-254.
2. Moshirfar M, Albarracin JC, Desautels JD, Birdsong OC, Linn SH, Hoopes PC Sr. Ectasia following small-incision lenticule extraction (SMILE): a review of the literature. *Clin Ophthalmol*. 2017;11:1683-1688.
3. Khamar P, Dalal R, Chandapura R, et al. Corneal tomographic features of postrefractive surgery ectasia [published online ahead of print September 24, 2018]. *J Biophotonics*. doi:10.1002/jbio.201800253
4. Amoils SP, Deist MB, Gous P, Amoils PM. Iatrogenic keratectasia after laser in situ keratomileusis for less than -4.0 to -7.0 diopters of myopia. *J Cataract Refract Surg*. 2000;26:967-977.
5. Reinstein DZ, Archer TJ, Randleman JB. Mathematical model to compare the relative tensile strength of the cornea after PRK, LASIK, and small incision lenticule extraction. *J Refract Surg*. 2013;29:454-460.
6. Sinha Roy A, Dupps WJ Jr, Roberts CJ. Comparison of biomechanical effects of small-incision lenticule extraction and laser in situ keratomileusis: finite-element analysis. *J Cataract Refract Surg*. 2014;40:971-980.
7. Pedersen IB, Bak-Nielsen S, Vestergaard AH, Ivarsen A, Hjortdal J. Corneal biomechanical properties after LASIK, ReLEx flex, and ReLEx smile by Scheimpflug-based dynamic tonometry. *Graefes Arch Clin Exp Ophthalmol*. 2014;252:1329-1335.
8. Xia L, Zhang J, Wu J, Yu K. Comparison of corneal biological healing after femtosecond LASIK and small incision lenticule extraction procedure. *Curr Eye Res*. 2016;41:1202-1208.
9. Li H, Wang Y, Dou R, et al. Intraocular pressure changes and relationship with corneal biomechanics after SMILE and FS-LASIK. *Invest Ophthalmol Vis Sci*. 2016;57:4180-4186.
10. Osman IM, Helaly HA, Abdalla M, Shousha MA. Corneal biomechanical changes in eyes with small incision lenticule extraction and laser assisted in situ keratomileusis. *BMC Ophthalmol*. 2016;16:123.
11. Zhang J, Zheng L, Zhao X, Xu Y, Chen S. Corneal biomechanics after small-incision lenticule extraction versus Q-value-guided femtosecond laser-assisted in situ keratomileusis. *J Curr Ophthalmol*. 2016;28:181-187.
12. Wang B, Zhang Z, Naidu RK, et al. Comparison of the change in posterior corneal elevation and corneal biomechanical parameters after small incision lenticule extraction and femtosecond laser-assisted LASIK for high myopia correction. *Cont Lens Anterior Eye*. 2016;39:191-196.
13. Wu W, Wang Y. The correlation analysis between corneal biomechanical properties and the surgically induced corneal high-order aberrations after small incision lenticule extraction and femtosecond laser in situ keratomileusis. *J Ophthalmol*. 2015;2015:758196.
14. Wang D, Liu M, Chen Y, et al. Differences in the corneal biomechanical changes after SMILE and LASIK. *J Refract Surg*. 2014;30:702-707.
15. Wu D, Wang Y, Zhang L, Wei S, Tang X. Corneal biomechanical effects: small-incision lenticule extraction versus femtosecond laser assisted laser in situ keratomileusis. *J Cataract Refract Surg*. 2014;40:954-962.
16. Agca A, Ozgurhan EB, Demirok A, et al. Comparison of corneal hysteresis and corneal resistance factor after small incision lenticule extraction and femtosecond laser-assisted LASIK: a prospective fellow eye study. *Cont Lens Anterior Eye*. 2014;37:77-80.
17. Shen Y, Chen Z, Knorz MC, Li M, Zhao J, Zhou X. Comparison of corneal deformation parameters after SMILE, LASEK, and femtosecond laser-assisted LASIK. *J Refract Surg*. 2014;30:310-318.
18. Sefat SM, Wiltfang R, Bechmann M, Mayer WJ, Kampik A, Kook D. Evaluation of changes in human corneas after femtosecond laser assisted LASIK and small-incision lenticule extraction (SMILE) using non-contact tonometry and ultra-high-speed camera (Corvis ST). *Curr Eye Res*. 2016;41:917-922.
19. Shetty R, Francis M, Shroff R, et al. Corneal biomechanical changes and tissue remodeling after SMILE and LASIK. *Invest Ophthalmol Vis Sci*. 2017;58:5703-5712.
20. Francis M, Pahuja N, Shroff R, et al. Waveform analysis of deformation amplitude and deflection amplitude in normal, suspect, and keratoconic eyes. *J Cataract Refract Surg*. 2017;43:1271-1280.
21. Spiru B, Kling S, Hafezi F, Sekundo W. Biomechanical properties of human cornea tested by two-dimensional extensiometry ex vivo in fellow eyes: femtosecond laser-assisted LASIK versus SMILE. *J Refract Surg*. 2018;34:419-423.
22. Randleman JB, Su JP, Scarcelli G. Biomechanical changes after LASIK flap creation combined with rapid cross-linking measured with Brillouin microscopy. *J Refract Surg*. 2017;33:408-414.
23. Vinciguerra R, Ambrósio R Jr, Elsheikh A, et al. Detection of keratoconus with a new biomechanical index. *J Refract Surg*. 2016;3:803-810.
24. Ivarsen A, Asp S, Hjortdal J. Safety and complications of more than 1500 small-incision lenticule extraction procedures. *Ophthalmology*. 2014;121:822-828.
25. Damgaard IB, Ang M, Farook M, Htoon HM, Mehta JS. Intraoperative patient experience and postoperative visual quality after SMILE and LASIK in a randomized, paired-eye, controlled study. *J Refract Surg*. 2018;34:92-99.
26. Dupps WJ Jr, Wilson SE. Biomechanics and wound healing in the cornea. *Exp Eye Res*. 2006;83:709-720.
27. Sinha Roy A, Kurian M, Matalia H, Shetty R. Air-puff associated quantification of non-linear biomechanical properties of the human cornea in vivo. *J Mech Behav Biomed Mater*. 2015;48:173-182.
28. Francis M, Khamar P, Shetty R, et al. In vivo prediction of air-puff induced corneal deformation using LASIK, SMILE, and PRK finite element simulations. *Invest Ophthalmol Vis Sci*. 2018;59:5320-5328.

ORIGINAL ARTICLE

Metabolomic Analysis in Corneal Lenticules From Contact Lens Wearers

Min Li, MD; Lin Liu, MM; Chen Qu, BM; Yuehui Shi, BM; Lina Sun, BM; Xingtao Zhou, MD, PhD; Jun Zou, MD, PhD

ABSTRACT

PURPOSE: To investigate the mechanisms of pathological changes in corneal stroma and the wearing time of soft contact lenses using the metabolomic method.

METHODS: Laser scanning confocal microscopy was used to evaluate the pathological changes of corneal stroma between wearing time groups before small incision lenticule extraction. After small incision lenticule extraction, 190 corneal stroma samples were obtained, and a metabolomic method using high performance liquid chromatography coupled with time of flight mass spectrometry was established to analyze the changes in metabolites between wearing time groups.

RESULTS: Laser scanning confocal microscope results demonstrated that the corneal nerve fiber length, the number of corneal anterior stromal cells, and the number of corneal posterior stromal cells were reduced gradually with increasing wearing time. The metabolomic study demonstrated that 11 biomarkers were identified between patients who did and did not wear soft contact lenses and 6 biomarkers were identified between less than 5 years and more than 5 years of wearing time. These biomarkers participate in energy metabolism, lipid metabolism, inflammatory reactions, and neuroprotecton processes, and partially lead to the pathology of dry eyes, eye inflammation, and corneal nerve fiber length decrease. Five biomarkers in the citrate cycle metabolism pathway were found demonstrating that energy metabolism was seriously disturbed.

CONCLUSIONS: This study systematically revealed the metabolite mechanism for eye discomfort and related disease after wearing soft contact lenses. The identified biomarkers and related physiology pathways supply a new direction for avoiding the side effects of wearing soft contact lenses.

[*J Refract Surg*. 2020;36(5):317-325.]

Vision correction methods include refractive surgery and wearing spectacles or soft contact lenses. Considering motivating factors such as aesthetics and cosmetics, soft contact lenses are becoming increasingly popular. Soft contact lenses currently are among the most commonly used medical devices, with an estimated 150 million soft contact lens users worldwide.[1] The value of the soft contact lens market is predicted to reach $13.5 billion by the end of 2020.[2] Of course, soft contact lenses are foreign bodies for eyes. They swim within the tear film, thereby having a direct impact on tear film and tissues with potential side effects.[3] According to the reports, microbial keratitis is still the most severe complication associated with wearing soft contact lenses, and dry eye symptoms remain despite the advanced technology improvements in soft contact lens materials and care systems.[4,5] In addition, wearing soft contact lenses reduces tear film thickness, decreases the number of functional meibomian glands, and alters meibomian gland morphology and function.[6-8] It also can decrease the entire corneal thickness, increase the corneal cur-

From the Department of Ophthalmology, Shanghai Tenth People's Hospital, Tongji University School of Medicine, Shanghai, People's Republic of China (ML, LL, CQ, YS, LS, JZ); and the Department of Ophthalmology, Myopia Key Laboratory of the Health Ministry, Eye and ENT Hospital of Fudan University, Shanghai, People's Republic of China (XZ).

Submitted: July 15, 2019; Accepted: March 10, 2020

Supported by National Natural Science Foundation of China (Grant No. 81500727), the Fundamental Research Funds for the Central Universities (Grant Nos. 22120180053 and 22120170254), Shanghai Municipal Natural Science Foundation (Grant No. 16ZR1426700), and Project of Shanghai Science and Technology (Grant No. 17411950207).

The authors have no financial or proprietary interest in the materials presented herein.

Correspondence to Xingtao Zhou, MD, PhD (doctzhouxingtao@163.com), and Jun Zou, MD, PhD (zoujun70@126.com), Department of Ophthalmology, Shanghai Tenth People's Hospital, Tongji University, Shanghai, People's Republic of China.

doi:10.3928/1081597X-20200312-01

Reprinted with permission from SLACK Incorporated, Li M, Liu L, Qu C, Shi Y, Sun L, Zhou X, Zou J. Metabolomic Analysis in Corneal Lenticules From Contact Lens Wearers. *J Refract Surg*. 2020;36(5):317-325. doi:10.3928/1081597X-20200312-01

TABLE 1
Characteristics of Participants Before SMILE

Variable	NW Group	5W Group	5-10W Group	O10W Group	*P*
Gender (% female)	55.6	57.4	59.7	58.3	.978
Age (years, mean ± SD)	25.98 ± 3.63	26.72 ± 3.53	27.31 ± 3.48	27.04 ± 3.65	.275
MRSE (D, mean ± SD)	-4.23 ± 1.04	-4.22 ± 0.99	-4.50 ± 0.91	-4.30 ± 0.99	.372
Optical zone (mm, mean ± SD)	6.63 ± 0.09	6.64 ± 0.09	6.64 ± 0.09	6.63 ± 0.10	.971
Time of wearing SCL per day (hours, mean ± SD)	7.93 ± 1.12	7.87 ± 0.83	7.76 ± 0.43	7.75 ± 0.44	.617
Time of wearing SCL (silicone hydrogel ratio)	–	5.88%	5.28%	3.82%	.001
CCT (μm, mean ± SD)	565.78 ± 21.22	568.00 ± 16.21	569.72 ± 20.53	572.42 ± 18.02	.592
Eyes with SPK ratio (number of eyes)	5% (2)	7.84% (4)	8.89% (4)	9.26% (5)	.085
Eyes with severe dry eye ratio (number of eyes)	5% (2)	5.88% (3)	8.89% (4)	7.41% (4)	.202
Eyes with conjunctivitis ratio (number of eyes)	0% (0)	1.96% (1)	2.22% (1)	1.85% (1)	.599

SMILE = small incision lenticule extraction; NW = no wearing of soft contact lenses; 5W = less than 5 years of wearing soft contact lenses; 5-10W = 5 to 10 years of wearing soft contact lenses; O10W = more than 10 years of wearing soft contact lenses; SD = standard deviation; MRSE = manifest refraction spherical equivalent; D = diopters; SCL = soft contact lens; CCT = central corneal thickness; SPK = superficial punctate keratitis

vature and surface irregularity, and promote squamous metaplasia of superficial conjunctival surface cells.[9,10]

Some traditional studies partly explained the reasons for side effects such as the changes in the ocular microbiome, the differential expression of inflammatory cytokines and the lipid oxidation, and deposition caused by wearing soft contact lenses.[11-13] Although some pathological changes in corneal stroma were found after wearing soft contact lenses, a systematic study to evaluate the effects and mechanism of wearing soft contact lenses is still needed. Metabolomics supplies a holistic approach to biomarker discovery and mechanistic insights into disease onset and progression.[14] Some metabolomic studies have been used in the donor corneal, keratoconic corneal, and diabetic corneal stroma.[15-17] To our knowledge, there has been no study using a metabolomic method to evaluate the effects on corneal stroma after wearing soft contact lenses.

In this study, we used the laser scanning confocal microscope to evaluate the pathology changes between soft contact lens wearing time groups before small incision lenticule extraction (SMILE). After surgery, 190 corneal stroma samples were analyzed using the metabolomic method to identify the seriously changed metabolites (biomarkers) and related pathways. This can reveal the mechanisms of pathological changes in corneal stroma after wearing soft contact lenses.

PATIENTS AND METHODS

Materials and Reagents

Acetonitrile and methanol (HPLC grade) was purchased from Honeywell. Formic acid (MS grade) was purchased from Sigma-Aldrich. Ultrapure water was obtained by a Milli-Q water purification system. HPLC n-butanol, acetoacetate (EA), and methanol were purchased from Sinopharm Chemical Reagent Co., Ltd. Commercial standards used for biomarker identification were purchased from Sigma-Aldrich. The laser confocal microscope was purchased from Heidelberg (HRTIII).

Participants

A total of 102 participants (190 corneal stroma samples) were recruited for this study. All samples were divided into four groups according to the wearing time: the no wearing of contact lenses group (NW group, 40 eyes); the less than 5 years of wearing contact lenses group (5W group, 51 eyes); the 5 to 10 years of wearing contact lenses group (5-10W group, 45 eyes); and the more than 10 years of wearing contact lenses group (O10W group, 54 eyes). The inclusion criteria were age 18 to 40 years, manifest refraction spherical equivalent refraction (MRSE) of more than -3.00 diopters (D) and less than -6.00 D, stable myopia for 2 or more years, myopic spherical equivalent increment of less than -0.50 D in 1 year, and corrected distance visual acuity of 20/25 or better. The material of the contact lenses was hydrogel. The average time of wearing soft contact lenses was 8 to 10 hours per day. The average wearing time of each group and the ratios of wearing time of silicone hydrogel soft contact lenses in every group are listed in **Table 1**. The breakdown of eyes with dry eye, conjunctivitis, and superficial punctate keratitis is also shown in **Table 1** and these patients were treated and cured before refractive examination. Patients with any ocular or systemic disease that would present a contraindication to laser refractive surgery were excluded. The characteristics of participants are shown in **Table 1**. The study was approved by the ethics committee of

Shanghai Tenth People's Hospital and conformed to the tenets of the Declaration of Helsinki.

Laser Confocal Microscope Detection

The participants were all detected first using laser scanning confocal microscopy, with ×400 magnification and 400 × 400 µm (384 × 384 pixels) to evaluate the number of basal cells in the corneal epithelium, the number of corneal endothelial cells, central corneal subcutaneous nerve fiber density (CNFL), and the number of corneal anterior and posterior stromal cells (NCASC and NCPSC). Twenty-five percent of corneal stroma above was the depth of acquiring the NCASC images, whereas 75% depth of corneal stroma was the depth of acquiring the NCPSC images. Before examination, a drop of proparacaine hydrochloride 0.5% (Alcaine; Alcon Laboratories) was delivered to the conjunctival sac. All examinations were performed along the sagittal axis in the central cornea. All patients were examined by the same operator (ML). Three people calculated keratocyte densities and acquired the average results.

Sample Treatment and Analysis

All samples were collected from the participants undergoing small incision lenticule extraction (SMILE). All surgeries were conducted by one surgeon (JZ), were uneventful, and had no severe complications. The corneal stroma samples were then transferred to Eppendorf tubes. The samples were stored at -80 °C until analysis. Corneal stroma samples were defrosted on ice and weighed separately, then the samples were added in liquid nitrogen and ground. Methanol was used for the extraction and the volumes were different from one another according to the sample's weight (1 mL of methanol added in 50 mg of corneal stroma sample). Extraction was performed by vortex-mixing for 5 minutes, and centrifugation at 10,000 rpm for 10 minutes at 4 °C to remove protein precipitation. The supernatants were filtered through 0.22 µm nylon filters and 100 µL filtrates were used for subsequent high performance liquid chromatography coupled with time of flight mass spectrometry (HPLC-TOF-MS) analysis.

A quality control sample was made by pooling the same volume (10 µL) of each corneal stroma sample's filtrate. The quality control sample was injected to monitor experiment stability. A blank sample of methanol, prepared in the same way as corneal stroma samples, was injected after every corneal stroma sample to minimize the carry-over.

HPLC-TOF-MS Analysis

All samples were analyzed on an Agilent-1200 HPLC system coupled with an Agilent-6520 TOF-MS (Agilent Technologies). Separation was performed on a ZORBAX eclipse XDB-C18 column (1.8 µm, 2.1 × 100 mm) with the column temperature at 35 °C. The mobile phases consisting of ultrapure water with 0.1% formic acid (A) and acetonitrile with 0.1% formic acid (B) with gradient change are shown in **Table 2**. The sample injection volume was 15 µL.

TABLE 2
HPLC Gradient Elution Program

Time (min)	A%	B%
0	98	2
4	78	22
10	40	60
12	60	40
15	98	2

The Agilent-1200 HPLC system coupled with an Agilent-6520 TOF-MS is manufactured by Agilent Technologies.

Both positive and negative ion modes were used for the TOF-MS detection. The parameters of mass detection were set as follows: the flow rate of drying gas (N_2) was 9 L min^{-1} with 350 °C gas temperature; the nebulizer gas pressure was 35 psig; Vcap was 3,800 V in positive and 3,700 V in negative mode; the fragmentor was 160 V; the skimmer was 65 V; and the scan range of mass was 50 to 1,000 m/z. The MS/MS data were acquired in targeted MS/MS mode with three collision energies of 15, 20, and 30 eV.

Data Processing

All raw data from HPLC-TOF-MS were analyzed using Agilent Mass Hunter Qualitative Analysis Software (Agilent Technologies), then the data were output to Agilent Mass Profiler Software (Agilent Technologies), which cleaned the background noises and unrelated ions. In data filtering, the parameters were set as follows: retention time ranging from 0 to 10 minutes with retention time tolerance of 0.1 minute; mass ranging from 50 to 1,000 m/z with mass tolerance of 0.05 Da; and peak relative height of 1.5% or greater. The ion intensities were normalized (linear function transformation) to control the MS response shift through the whole analysis. The output data included retention time, molecular mass, and the corresponding abundance. Principal components analysis (PCA) and partial least squares discriminate analysis (PLS-DA) in the SIMCA-P software (version 11; Umetrics) were used for metabolite profile analysis.

A one-way analyses of variance with a Bonferroni correction using SPSS 13.0 for Windows software (SPSS, Inc.) was used for significance analysis. Differences were considered significant at a P value of

.05 or less. The metabolites were preliminary identified at the Scripps Center for Metabolomics and Mass Spectrometry, then were confirmed by MS/MS data and standard compounds. The biochemical pathways and reactions of identified metabolites were obtained through the Kyoto Encyclopedia of Genes and Genomes and the Human Metabolome Database.

RESULTS

Laser Confocal Microscope Results

The number of wing cells in corneal epithelium and corneal endothelial cells showed no significant differences in the NW, 5W, 5-10W, and O10W groups before surgery (P = .30 and .80, respectively). The CNFL is shown in **Figures 1A-1D** and **Figure 1M**. The CNFL in the NW group was significantly higher than those of the other three groups (P < .01). The CNFL in the 5W group was not significantly different from that of the 5-10W group, but was higher than that of the O10W group (P < .01). The CNFL of the O10W group was also substantially less than that of the 5-10W group (P < .01). The value of CNFL showed a significantly downward trend with extension of wearing time.

NCASC in these four groups (**Figures 1E-1H**, **Figure 1N**) exhibited significant changes. The NCASC in the NW group was significantly higher than that of the other three groups (P < .01). The NCASC of the 5W group was significantly higher than that of the 5-10W (P = .01) and O10W (P < .01) groups. The NCASC in the O10W group was significantly less than that of the 5-10W group (P < .01). The NCASC also showed a significantly downward relation with the extension of wearing time. **Figures 1I-1L** and **Figure 1O** show the NCPSC in these four groups. NCPSC in the O10W group was significantly less than those of the other three groups (P = .01). However, there were no significant differences in the NW, 5W, and 5-10W groups.

Laser scanning confocal microscope data suggested that there were pathological changes that occurred in corneal stroma after wearing soft contact lenses. The decreased CNFL suggested that growth of nerve fibers was altered in the central corneal subcutaneous region. Longer wearing time correlated with more significant impact. Furthermore, the number of corneal anterior stromal cells and corneal posterior stromal cells were substantially altered in groups of soft contact lens wearers along with wearing time.

Metabolic Profiling and Method Validation of HPLC-TOF-MS

To obtain more information regarding metabolites from corneal stroma samples, various polar solvents were compared to optimize extraction results. The separation and detection conditions were also optimized in terms of peak shape and abundance. Typical HPLC-TOF-MS total ion current in both positive and negative mode profiles of the corneal stroma samples are shown in **Figure 2**.

To confirm the repeatability of the proposed method, six parallel samples were extracted from a random corneal stroma sample using the preparation method mentioned above. Six parallel samples were injected continuously. The stability of the instrument was demonstrated by the data obtained from quality control samples. Because there were 190 corneal stroma samples, 19 stability data sets were acquired from quality control samples. The relative standard deviations of repeatability and stability of this metabolomic study are shown in **Table 3**. The data showed that the proposed analysis method could be used in large-scale sample analysis with high repeatability and stability.

Multivariate Statistical Analysis of HPLC-TOFMS Data

Because 15,340 ions in both positive and negative modes were detected in the HPLC-TOF-MS analysis, it was difficult to identify similarities and differences among the NW, 5W, 5-10W, and O10W groups using traditional statistical methods. Multivariate statistical analysis such as PCA or PLS-DA are important tools for exhibiting patterns of metabolites in various corneal stroma samples. In this study, PCA was first performed using SIMCA-P software. The PCA plot of **Figure A** (available in the online version of this article) showed that the samples from the NW, 5W, 5-10W, and O10W group samples could be substantially distinguished. The samples of the 5-10W and O10W groups overlapped. The PCA result demonstrated that metabolites among the NW, 5W, 5-10W, and O10W groups were substantially different.

To identify those metabolites (biomarkers) that contributed to group differences, the supervised multivariate statistical analysis method PLS-DA was used for further analysis. First, to identify the various metabolites between the NW and soft contact lens wearing groups (5W, 5-10W, and O10W), a PLS-DA method was established (R2X = 0.848, R2Y = 0.986, and Q2Y = 0.831). As **Figure BA** (available in the online version of this article) shows, there was a distinguished classification between the clustering of the NW group samples and other groups' samples. In **Figure BB**, the corresponding loading plot shows several triangles, and each triangle represents an ion (variable). An ion away from the center indicates that the ion abundance was substantially altered between these two groups. The ability of contribution for the group classification was evaluated using variable importance projection (VIP)

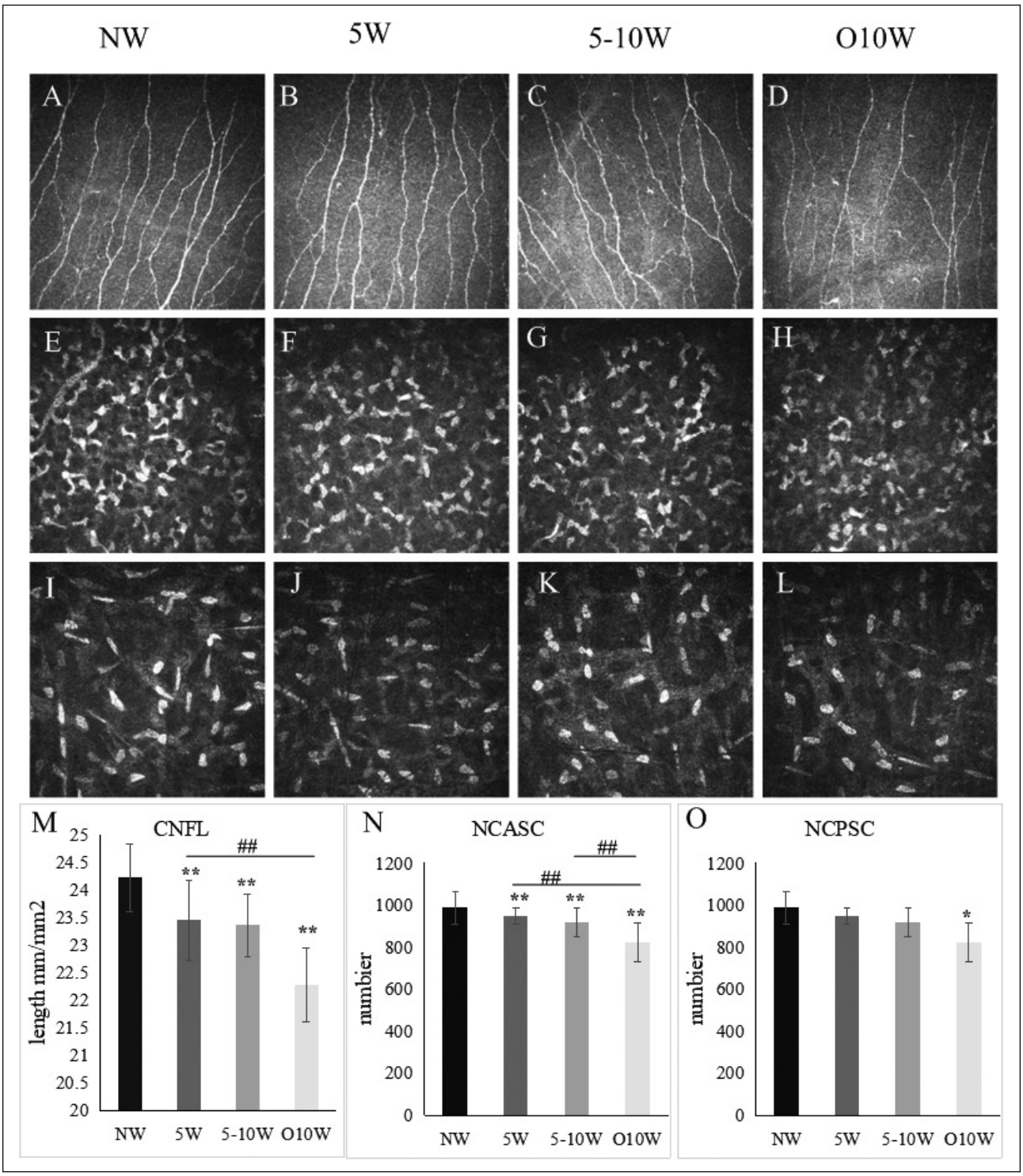

Figure 1. (A-D, M) Central corneal subcutaneous nerve fiber density (CNFL), (E-H, N) the number of corneal anterior stromal cells (NCASC), and (I-L, O) the number of corneal posterior stromal cells (NCPSC) of the central cornea in the four groups (NW = no wearing of soft contact lenses; 5W = less than 5 years of wearing soft contact lenses; 5-10W = 5 to 10 years of wearing soft contact lenses; O10W = more than 10 years of wearing soft contact lenses). * Represents the significant difference comparing to the NW group with $P \leqslant .05$. ** Represents the significant difference comparing to the NW group with $P \leqslant .01$. ## Represents the significant difference between the two groups with $P \leqslant .01$.

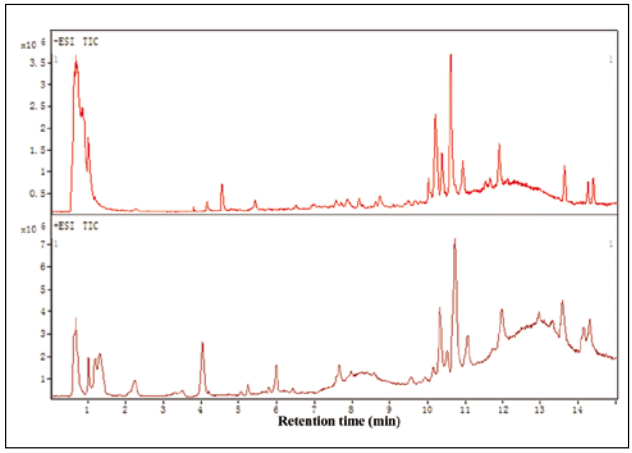

Figure 2. Typical high performance liquid chromatography coupled with time of flight mass spectrometry total ion current (TIC) profiles of corneal stroma samples in both positive and negative modes.

in Simca P software. When the VIP is 1.0 or greater, the ion could be considered a potential metabolite biomarker between the NW group and all other groups.

A total of 20 ions (VIP of 1.0 or greater) of 15,340 were shown to contribute to the classification of the groups. The 20 substantially altered variables[11] were presumed according to accurate MS and MS/MS fragments by searching in metabolite databases (http://metlin.scripps.edu, http://www.hmdb.ca/) and then confirming using commercial standards (**Table 4**).

Using the same processes mentioned above, the classification of the 5W, 5-10W, and O10W groups are shown in **Figure C** (available in the online version of this article). In the end, six potential biomarkers were identified as contributors for group classification. Biomarker information is shown in **Table 5**.

Related Pathological Process of the Identified Biomarkers and Their Functions

Table 4 displays the metabolites that were significantly altered between the NW group and the other groups. These metabolites are divided into three classes: short chain organic acids, long chain unsaturated fatty acids, and lipids, suggesting that short chain organic acids metabolism, fatty acid metabolism, and lipid metabolism in the corneal stroma were dysfunctional in soft contact lens wearers.

Citrate, oxaloacetate, succinate, pyruvate, and glutamate are all short chain organic acids that were significantly upregulated in our study. The related biological pathways of these five metabolites all participate in the citrate cycle process, suggesting that citrate cycle metabolism was severely disturbed by wearing soft contact lenses. Corneal health relies on a well-balanced avascular oxygen supply. Wearing soft contact lenses reduces the aerobic respiration of glucose. Therefore, the cornea resorts to anaerobic respiration for its energy needs.[18] Dysfunction of aerobic respiration of the citrate cycle then occurs. The high levels of citrate, oxaloacetate, succinate, and pyruvate in this study further demonstrate that aerobic respiration of the cornea was inhibited, leading to citrate cycle metabolite accumulation.

TABLE 3
Repeatability and Stability Data for the Proposed Method

Parameter	Positive	Negative
Selected ions (m/z)	131.1	346.1
Repeatability (n = 6)		
Retention time (min)		
Mean	0.84	8.02
RSD (%)	0.38	0.55
Peak area		
Mean	1,834	5,573
RSD (%)	9.21	6.98
Stability (n = 19)		
Retention time (min)		
Mean	0.85	8.05
RSD (%)	0.52	0.56
Peak area		
Mean	1,527	5,127
RSD (%)	8.84	4.79

RSD = relative standard deviation

Behenyl palmitate, cholesteryl oleate, oleyl palmitate, and oleyl oleate are all lipids. These lipids contribute to form the outermost layer of tear film and help to slow evaporation of the aqueous layer in tear film. After wearing soft contact lenses, lipid metabolism is affected. The low levels of behenyl palmitate, cholesteryl oleate, oleyl palmitate, and oleyl oleate suggest that the synthesis of lipids after wearing soft contact lenses was inhibited. The resulting reduction in the protective function of the lipid layer leads to eye discomfort.

Taurine is the most abundant short chain organic acid found in ocular tissue.[19] It inhibits the proliferation and migration of corneal stromal cells and protects against retinal and optic nerve damage.[20,21] In this study, the level of taurine was significantly downregulated, thereby enhancing the proliferation and migration ability of corneal stromal cells. Conversely, low levels of taurine in soft contact lens wearers may reduce an important nutrient substrate for the corneal nerve. This will be verified in a future study.

Arachidonic acid is an inflammatory factor. It is converted to downstream mediators such as prostaglan-

TABLE 4
Eleven Identified Biomarkers in Corneal Stroma Between Patients Not Wearing and Wearing Contact Lenses Using LC–Q-TOF-MS

Mode	Retention Time (min)	Precise Molecular	Molecular Formular	Compound Name	Trend	Related Pathway
Positive						
1	0.80	214.0192	C5H11O7P	Citrate	Up	Citrate cycle metabolism
2	0.91	131.0762	C4H9N3O2	Oxaloacetate	Up	Citrate cycle metabolism
3	1.18	244.0777	C9H12N2O6	Succinate	Up	Citrate cycle metabolism
4	3.52	204.0965	C11H12N2O2	Taurine	Down	Taurine and hypotaurine metabolism
5	6.07	254.0354	C7H14N2O4S2	Pyruvate	Down	Citrate cycle metabolism and pyruvate metabolism
6	1.03	147.0597	C5H9NO4	Arachidonic acid	Up	Arachidonic acid metabolism
7	1.17	219.1180	C9H17NO5	Glutamate	Down	Glutamatergic synapse
Negative						
8	1.18	190.0179	C6H6O7	Behenyl palmitate	Down	Lipid metabolism
9	1.21	193.0799	C10H11NO3	Cholesteryl oleate	Down	Lipid metabolism
10	1.93	179.0648	C9H9NO3	Oleyl palmitate	Down	Lipid metabolism
11	3.48	344.2074	C21H28O4	Oleyl oleate	Down	Lipid metabolism

LC-Q-TOF-MS = high performance liquid chromatography coupled with time of flight mass spectrometry

TABLE 5
Six Identified Biomarkers in Corneal Stroma Between Patients Wearing Contact Lenses for > 5 Years and < 5 Years Using LC–Q-TOF-MS

Mode	Retention Time (min)	Precise Molecular	Molecular Formular	Compound Name	Trend	Related Pathway
Positive						
1	0.80	214.0192	C5H11O7P	Sphinganine	Down	Sphingolipid metabolism
2	0.91	131.0762	C4H9N3O2	L-carnitine	Down	Lysine degradation
3	1.18	244.0777	C9H12N2O6	Linoleic acid	Down	Linoleic acid metabolism
Negative						
4	1.17	219.1180	C9H17NO5	Palmitoleic acid	Down	Fatty acid metabolism
5	1.18	190.0179	C6H6O7	Docosahexaenoic acid	Down	Biosynthesis of unsaturated fatty acids
6	1.21	193.0799	C10H11NO3	Glucose	Up	Glycolysis, pyruvate metabolism, and energy metabolism

LC–Q-TOF-MS = high performance liquid chromatography coupled with time of flight mass spectrometry

dins and leukotrienes that further fuel the inflammatory cycle.[22] The high levels of arachidonic acid in this study suggest that inflammatory activity existed in the corneal stroma of soft contact lens wearers.

Table 5 shows that metabolites were significantly altered between the 5W, 5-10W, and O10W groups. L-carnitine plays an important role in maintaining the ocular surface microenvironment. Khandekar et al[23] reported that L-carnitine regulated human corneal epithelial cell volume and ameliorated apoptosis under hyperosmotic stress. Hua et al[24] demonstrated that L-carnitine protected human corneal epithelial cells from oxidative stress by reducing declines in antioxidant enzymes and suppressing reactive oxygen species production. The inhibitory effects further reduce membrane lipid oxidative damage and protect the integrity of the tear film lipid layer. The substantially lower levels of L-carnitine in this study suggest that the corneal stroma or ocular surface lacked protective substances, possibly resulting in ocular surface diseases.

In the ocular surface, the glucose content is approximately 40%. High glucose levels in the ocular surface may facilitate the growth of pathogenic microorganisms and alter the stability of the precorneal tear film.[25] In this study, high levels of glucose in the 5W, 5-10W, and O10W groups suggested that pathogen invasion risk was greater.

Prolonged use of soft contact lenses can alter corneal innervations.[26] Neuroprotectin D1, biosynthesized from docosahexaenoic acid, which was downregulated in this study, has anti-inflammatory and neuroprotective actions.[27,28] In this study, with decreased docosahexaenoic acid levels, the synthesis of neuroprotectin D1 will be affected. Therefore, the anti-inflammatory and neuroprotective effects would be weakened in those wearing contact lenses for more than 5 years.

Sphinganine participates in sphingolipid metabolism. Sphingosine 1-phosphate is a metabolite of sphinganine that participates in neuroactive ligand-receptor interactions. The low levels of sphinganine in this study further suggest that the neuroprotective effect was weakened after wearing soft contact lenses.

Palmitoleic acid and linoleic acid are both long chain unsaturated fatty acids. Linoleic acid is the precursor of arachidonic acid. Because high levels of arachidonic acid are markers of inflammation,[22] low levels of linoleic acid will help reduce the development of inflammation.

DISCUSSION

In this study, the laser scanning confocal microscope analysis results showed decreased CNFL, NCASC, and NPCSC in the corneal stroma of patients wearing soft contact lenses that changed with wearing time. The metabolomic study identified 11 biomarkers between the NW and other groups, and 6 biomarkers between the 5W, 5-10W, and O10W groups. The biological function revealed some metabolism mechanism of the eye's discomfort symptoms. For example, the low level expression of lipid metabolites such as behenyl palmitate, cholesteryl oleate, oleyl palmitate, and oleyl oleate may help the development of dry eye symptoms after wearing soft contact lenses. The neuroprotection metabolites such as taurine, docosahexaenoic acid, and sphinganine may play an important role in maintaining normal CNFL. With the downregulation of these metabolites, the CNFL of patients wearing soft contact lenses for long periods is decreased. On the other hand, the high expression level of arachidonic acid, glucose, and linoleic acid may facilitate the inflammation reaction of eyes after wearing soft contact lenses. In addition, the energy metabolism (citrate, oxaloacetate, succinate, pyruvate, and glutamate all participate in the citrate cycle process) dysfunction is another problem worthy of attention. Some intervention methods for regulating the dysfunction of energy metabolism would be a benefit for the population of soft contact lens wearers.

We systematically revealed the significant metabolite changes in energy metabolism, lipid metabolism, inflammation reaction, and neuroprotection process dysfunction in the corneal stroma after wearing soft contact lenses. This metabolism dysfunction partially explained the eyes' discomfort after wearing soft contact lenses and provides a new direction for prevention and treatment of related corneal disease.

AUTHOR CONTRIBUTIONS

Study concept and design (ML, XZ, JZ); data collection (ML, LL, CQ, YS, LS); analysis and interpretation of data (ML, LL); writing the manuscript (ML); critical revision of the manuscript (LL, CQ, YS, LS, XZ, JZ)

REFERENCES

1. Patel NB, Hinojosa JA, Zhu M, Robertson DM. Acceleration of the formation of biofilms on contact lens surfaces in the presence of neutrophil-derived cellular debris is conserved across multiple genera. *Mol Vis*. 2018;24:94-104.
2. Hexa Research. Contact lenses market analysis, market size, application analysis, regional outlook, competitive strategies and forecasts, 2016 to 2024. http://www.hexaresearch.com/research-report/contact-lenses-industry/
3. Knop E. Contact lens and ocular surface—After all, it's still a foreign body. *Acta Ophthalmologica*. 2017;95:1. doi:10.1111/j.1755-3768.2017.03571
4. Verhelst D, Koppen C, Van Looveren J, Meheus A, Tassignon MJ; Belgian Keratitis Study Group. Clinical, epidemiological and cost aspects of contact lens related infectious keratitis in Belgium: results of a seven-year retrospective study. *Bull Soc Belge Ophtalmol*. 2005;12(297):7-15.
5. Itokawa T, Okajima Y, Suzuki T, et al. Association between ocular surface temperature and tear film stability in soft contact lens wearers. *Invest Ophthalmol Vis Sci*. 2018;59(2):771-775. doi:10.1167/iovs.17-23173
6. Arita R, Itoh K, Inoue K, Kuchiba A, Yamaguchi T, Amano S. Contact lens wear is associated with decrease of meibomian glands. *Ophthalmology*. 2009;116(3):379-384. doi:10.1016/j.ophtha.2008.10.012
7. Nichols JJ, King-Smith PE. Contact lens and tear film thickness measures associated with different multipurpose care solutions. *Ocul Surf*. 2005;3:S97-S97. doi:10.1016/S1542-0124(12)70508-6
8. Alghamdi WM, Markoulli M, Holden BA, Papas EB. Impact of duration of contact lens wear on the structure and function of the meibomian glands. *Ophthalmic Physiol Opt*. 2016;36(2):120-131. doi:10.1111/opo.12278
9. Liu Z, Pflugfelder SC. The effects of long-term contact lens wear on corneal thickness, curvature, and surface regularity. *Ophthalmology*. 2000;107(1):105-111. doi:10.1016/S0161-6420(99)00027-5
10. Doughty MJ. Objective assessment of squamous metaplasia of conjunctival epithelial cells as associated with soft contact lens wear versus non-lens wearers. *Cornea*. 2014;33(10):1095-1102. doi:10.1097/ICO.0000000000000203

11. Zhang H, Zhao F, Hutchinson DS, et al. Conjunctival microbiome changes associated with soft contact lens and orthokeratology lens wearing. *Invest Ophthalmol Vis Sci*. 2017;58(1):128-136. doi:10.1167/iovs.16-20231
12. Pisella PJ, Malet F, Lejeune S, et al. Ocular surface changes induced by contact lens wear. *Cornea*. 2001;20(8):820-825. doi:10.1097/00003226-200111000-00009
13. Schuett BS, Millar TJ. An experimental model to study the impact of lipid oxidation on contact lens deposition in vitro. *Curr Eye Res*. 2017;42(9):1220-1227. doi:10.1080/02713683.2017.1307416
14. Ivanisevic J, Want EJ. From samples to insights into metabolism: uncovering biologically relevant information in lc-hrms metabolomics data. *Metabolites*. 2019;9(12):E308. doi:10.3390/metabo9120308
15. Priyadarsini S, McKay TB, Sarker-Nag A, et al. Complete metabolome and lipidome analysis reveals novel biomarkers in the human diabetic corneal stroma. *Exp Eye Res*. 2016;153:90-100. doi:10.1016/j.exer.2016.10.010
16. McKay TB, Hjortdal J, Sejersen H, Asara JM, Wu J, Karamichos D. Endocrine and metabolic pathways linked to keratoconus: implications for the role of hormones in the stromal microenvironment. *Sci Rep*. 2016;6(1):25534. doi:10.1038/srep25534
17. Kryczka T, Szaflik JP, Szaflik J, Midelfart A. Influence of donor age, post-mortem time and cold storage on metabolic profile of human cornea. *Acta Ophthalmol*. 2013;91(1):83-87. doi:10.1111/j.1755-3768.2011.02271.x
18. Leung BK, Bonanno JA, Radke CJ. Oxygen-deficient metabolism and corneal edema. *Prog Retin Eye Res*. 2011;30(6):471-492. doi:10.1016/j.preteyeres.2011.07.001
19. Heinämäki AA, Muhonen AS, Piha RS. Taurine and other free amino acids in the retina, vitreous, lens, iris-ciliary body, and cornea of the rat eye. *Neurochem Res*. 1986;11(4):535-542. doi:10.1007/BF00965323
20. Zhou WY, Qi HU, Zhang YG. Effect of taurine on the proliferation and migration of corneal keratocytes. *Chinese Journal of Trauma and Disability Medicine*. 2007;15:20-21.
21. Nor Arfuzir NN, Agarwal R, Iezhitsa I, Agarwal P, Sidek S, Ismail NM. Taurine protects against retinal and optic nerve damage induced by endothelin-1 in rats via antioxidant effects. *Neural Regen Res*. 2018;13(11):2014-2021. doi:10.4103/1673-5374.239450
22. Thakur A, Willcox MD, Stapleton F. The proinflammatory cytokines and arachidonic acid metabolites in human overnight tears: homeostatic mechanisms. *J Clin Immunol*. 1998;18(1):61-70. doi:10.1023/A:1023291921695
23. Khandekar N, Willcox MD, Shih S, Simmons P, Vehige J, Garrett Q. Decrease in hyperosmotic stress-induced corneal epithelial cell apoptosis by L-carnitine. *Mol Vis*. 2013;19:1945-1956.
24. Hua X, Deng R, Li J, et al. Protective effects of L-carnitine against oxidative injury by hyperosmolarity in human corneal epithelial cells. *Invest Ophthalmol Vis Sci*. 2015;56(9):5503-5511. doi:10.1167/iovs.14-16247
25. David MK, Jennifer L, Robert S, Carol M, Jeanie HS. Correlation of glucose levels in the tear film and blood in normals and diabetics. *The Ocular Surface*. 2005;3:S84.
26. Kenchegowda S, He J, Bazan HE. Involvement of pigment epithelium-derived factor, docosahexaenoic acid and neuroprotectin D1 in corneal inflammation and nerve integrity after refractive surgery. *Prostaglandins Leukot Essent Fatty Acids*. 2013;88(1):27-31. doi:10.1016/j.plefa.2012.03.010
27. Bazan NG, Calandria JM, Serhan CN. Rescue and repair during photoreceptor cell renewal mediated by docosahexaenoic acid-derived neuroprotectin D1. *J Lipid Res*. 2010;51(8):2018-2031. doi:10.1194/jlr.R001131
28. Calandria JM, Bazan NG. Neuroprotectin D1 modulates the induction of pro-inflammatory signaling and promotes retinal pigment epithelial cell survival during oxidative stress. *Adv Exp Med Biol*. 2010;664:663-670. doi:10.1007/978-1-4419-1399-9_76

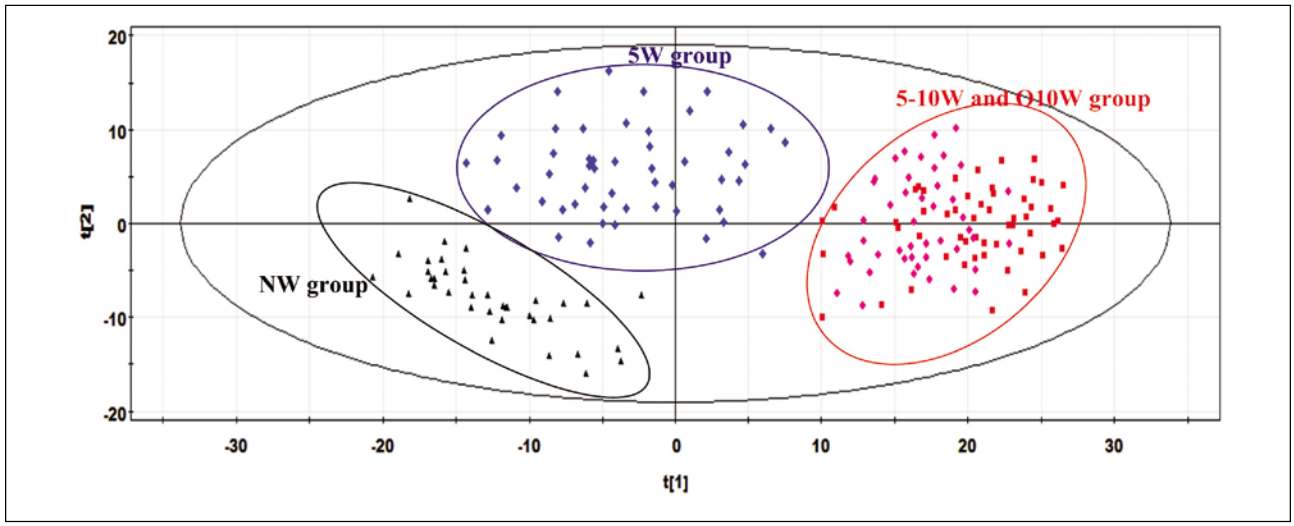

Figure A. Principal components analysis plot of NW (black triangle), 5W (blue diamond), 5-10W (purple diamond), and O10W (red square) groups. NW = no wearing of soft contact lenses; 5W = less than 5 years of wearing soft contact lenses; 5-10W = 5 to 10 years of wearing soft contact lenses; O10W = more than 10 years of wearing soft contact lenses

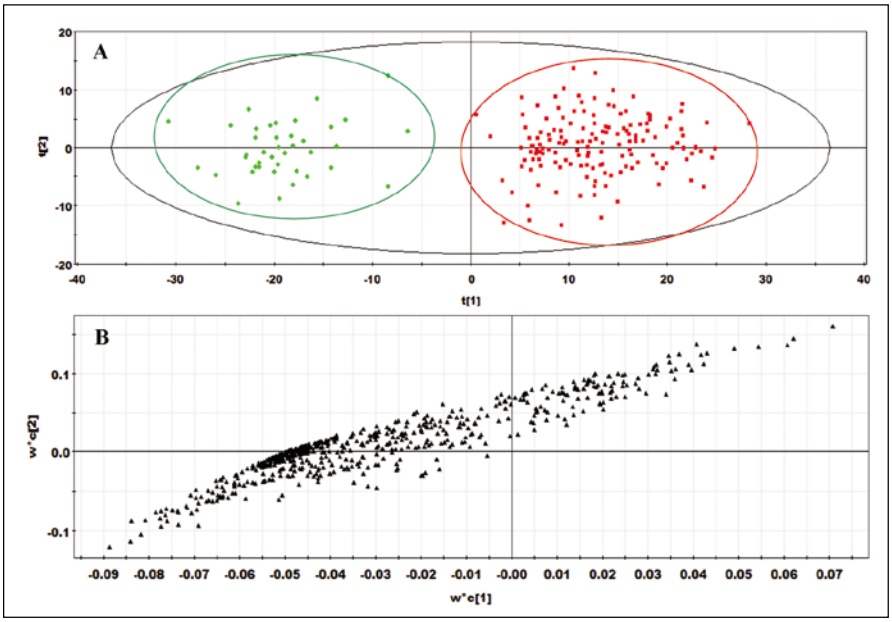

Figure B. Partial least squares discriminate analysis plot obtained from the four groups (NW = no wearing of soft contact lenses; 5W = less than 5 years of wearing soft contact lenses; 5-10W = 5 to 10 years of wearing soft contact lenses; O10W = more than 10 years of wearing soft contact lenses). A represents the score plot (red square represents the soft contact lens wearing group sample and green square represents the NW group sample) and B represents the loading plot.

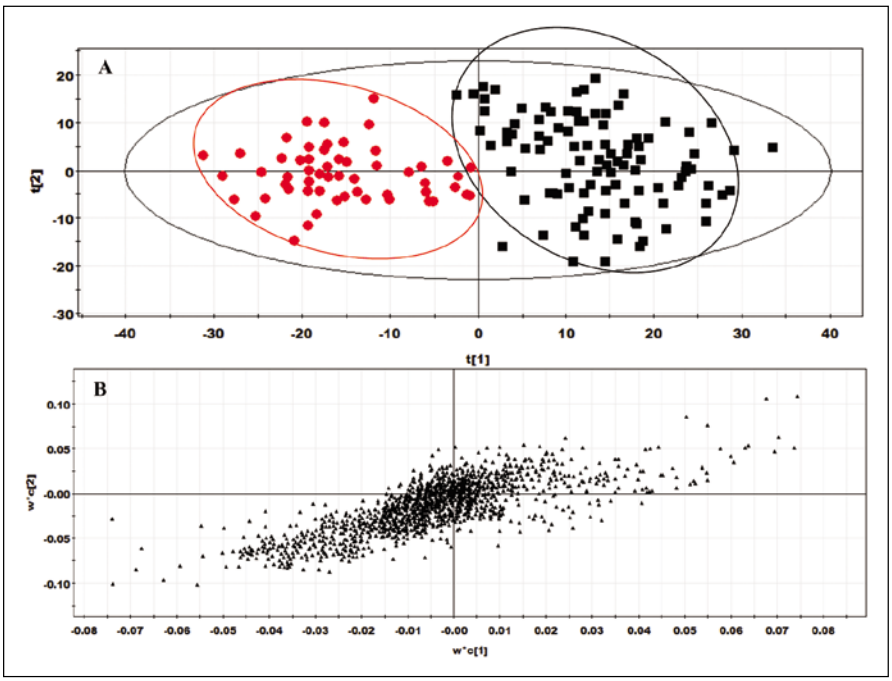

Figure C. Partial least squares discriminate analysis plot obtained from the four groups (NW = no wearing of soft contact lenses; 5W = less than 5 years of wearing soft contact lenses; 5-10W = 5 to 10 years of wearing soft contact lenses; O10W = more than 10 years of wearing soft contact lenses) (up). A represents the score plot (black square represents over 5 years wearing soft contact lenses group sample and red dot represents 5W group sample) and B represents the loading plot.

Tour of *Journal of Refractive Surgery* Papers

J Bradley Randleman MD

NOTES

ORIGINAL ARTICLE

Artificial Intelligence Efficiently Identifies Regional Differences in the Progression of Tomographic Parameters of Keratoconic Corneas

Rohit Shetty, MD, PhD; Gairik Kundu, MD; Raghav Narasimhan, MTech; Pooja Khamar, MD, PhD; Krati Gupta, MD; Niharika Singh, MD; Rudy M.M.A. Nuijts, MD, PhD; Abhijit Sinha Roy, PhD

ABSTRACT

PURPOSE: To develop an artificial intelligence (AI) model to effectively assess local versus global progression of keratoconus using multiple tomographic parameters.

METHODS: This was a retrospective review of medical records of patients diagnosed as having keratoconus. A total of 1,884 Pentacam (Oculus Optikgeräte GmbH) scans of 366 eyes (296 patients) were analyzed. Based on an increase in maximum anterior curvature (Kmax), the eyes were classified as actual "progression" and "no progression." The corresponding changes in other Pentacam parameters were incorporated to train and cross-validate (five-fold) the AI models. Three AI models were trained (an increase in Kmax by A = 0.75 diopters [D], B = 1.00 D, and C = 1.25 D). The area under the curve (AUC), sensitivity, specificity, and classification accuracy, along with other metrics, were evaluated.

RESULTS: The AUC, sensitivity, specificity, and classification accuracy were 0.90, 85%, 82%, and 83%, respectively, for Model A; 0.91, 86%, 82%, and 88%, respectively, for Model B; and 0.93, 89%, 81%, and 91%, respectively, for Model C. All models also predicted that 60% to 62% of the actual progression eyes had concomitant progression-associated changes in the other Pentacam parameters (global progression). However, there was discordance between increase in Kmax and concomitant associated changes in the other parameters in 38.8% to 40% of the eyes (local progression).

CONCLUSIONS: The AI models identified the eyes where the increase in Kmax and corresponding progression-associated changes in the other parameters were in agreement. These eyes may require corneal cross-linking earlier than the rest.

[*J Refract Surg*. 2021;37(4):240-248.]

Several advanced tomographic tools are available for cross-sectional diagnosis of keratoconus.[1] These tools enable assessment of the corneal interfaces (eg, anterior corneal surface) and intracorneal layers (eg, epithelium or Bowman's layer).[2-5] The prevalence of keratoconus depends on geography and ethnic differences.[6,7] India generally has a much greater prevalence of keratoconus,[6-8] as high as 2.3% among the general population and 1.4% among patients with allergic eye disease.[6-8] These numbers are far greater than the numbers reported from other populations.[6] Therefore, early diagnosis of keratoconus with advanced tomography and image processing is important.[1] Interestingly, no studies on refined assessment of progression of keratoconus using multiple tomographic indices exist in the literature. This is particularly important because progression of keratoconus is the primary reason for corneal cross-linking (CXL),

From the Department of Corneal and Refractive Services, Narayana Nethralaya, Bangalore, India (RS, GK, PK, KG, NS); University Eye Clinic Maastricht, Maastricht University Medical Center, Maastricht, the Netherlands (RN, RMMAN); and Imaging, Biomechanics and Mathematical Modeling Solutions, Narayana Nethralaya Foundation, Bangalore, India (ASR).

Submitted: May 28, 2020; Accepted: December 7, 2020

Supported in part by an Indo-Dutch Collaborative Research Grant from the Department of Biotechnology, India.

Drs. Shetty and Sinha Roy have a pending patent application on assessing progression of disease using tomography and other methods. The remaining authors have no financial or proprietary interest in the materials presented herein.

Correspondence: Abhijit Sinha Roy, PhD, Narayana Nethralaya Foundation, #258/A Hosur Road, Bommasandra, Bangalore 560099, India. Email: asroy27@yahoo.com

doi:10.3928/1081597X-20210120-01

as emphasized by a recent review.[9] Considering the disease burden in India, a refined assessment of progression of keratoconus is vital to effectively prioritize patients who may require CXL earlier than the others.

Among tomography devices, the Pentacam (Oculus Optikgeräte GmbH) is the most widely used. The Pentacam has a wide range of indices available to assess the shape of the anterior corneal surface. These indices undergo considerable change if there is progression of keratoconus.[10,11] Although cut-offs for some of the indices are known,[10] a singular multivariate model to assess progression of keratoconus using all of the indices simultaneously is lacking. This makes visual examination of progression using several tomographic indices challenging for clinicians. Therefore, it is not surprising that most randomized control trials for assessing CXL continue to use an increase in maximum or steep axis curvature by 1.00 diopter (D) as the only indicator of progression.[12-15] Therefore, the objective of this study was to develop an artificial intelligence (AI) model using several indices simultaneously from the Pentacam to assess the longitudinal progression of keratoconus. The initial classification of "progression" and "no progression" was built using change in maximum anterior curvature (Kmax) because Kmax may be considered the current gold standard to confirm progression.[16]

PATIENTS AND METHODS

This was a retrospective review of hospital records of patients with keratoconus who visited the outpatient department of Narayana Nethralaya from January 2014 to January 2019. The study was approved by the Narayana Nethralaya ethics committee. The study followed the tenets of the Declaration of Helsinki.

All eyes had undergone a comprehensive ocular examination and corneal tomography (Pentacam) to confirm the diagnosis of keratoconus. Exclusion criteria were other corneal degeneration (eg, pellucid marginal degeneration, post-refractive surgery ectasia, or autoimmune disorders), any ocular or corneal surgery prior to the first visit of the patient or during the course of disease follow-up, patients receiving topical drops other than allergy and lubricants, patients with corneal scarring, patients using contact lenses, and patients with fewer than four follow-up visits after the first visit. Only Pentacam scans that did not have any blinking or motion artifacts were used. These scans are automatically classified as "OK" by the Pentacam software. Further, the detected anterior and posterior edges of the corneal scans were manually confirmed so that no missing portions of the detected edges confounded the tomography of the cornea.[17]

The maximum anterior curvature from Scheimpflug imaging was commonly used to evaluate the progression of keratoconus.[12-15] Therefore, we chose the maximum curvature of the anterior surface (Kmax) for the clinical (actual) classification of eyes into "progression" and "no progression." Most studies used a cut-off of 1.00 D to define progression.[12-15] Here, Kmax is simply one local measurement on the anterior corneal surface. Therefore, it cannot be assumed as an indicator of global progression where several other corneal parameters would also indicate concomitant progression. Based on this assumption, we devised a longitudinal classification of progression and no progression for each eye. We provide an example to explain this classification. Let us assume that a given eye had five follow-up time points available after the first visit and a cut-off of 1.00 D increase in Kmax was assumed as progression. We treat the first visit as the reference. At the second follow-up visit, let us assume that Kmax increased by 0.50 D. Therefore, the second follow-up visit was classified as no progression relative to the first visit. At the third follow-up visit, let us assume that Kmax increased further by 0.50 D. Therefore, the third follow-up visit was classified as progression relative to the first visit. Now, the third follow-up visit was assumed to be the updated reference because progression had occurred based on the cut-off. Let us assume that by the fourth and fifth follow-up visits, there was no further increase in Kmax relative to the updated reference (ie, the third follow-up visit). Therefore, the changes in tomography up to the fourth and fifth follow-up visits relative to the third follow-up visit were classified as no progression. Overall, there were four no progression and one progression follow-up visits in the example described above. Thus, each eye may have had multiple no progression and progression changes depending on the number of follow-up visits available.

For each progression and no progression follow-up visit, the corresponding changes in the tomographic parameters other than Kmax were calculated relative to their respective reference. In the above example, the change by the second and third follow-up visits was calculated with reference to the first visit. For the fourth and fifth follow-up visits, the change in the tomographic parameters was calculated with reference to the third follow-up visit. The underlying hypothesis was that a true increase in steepness of the cornea due to progression of the disease would be indicated by a majority of the Pentacam tomographic parameters (ie, a global progression and not just by Kmax alone [a local progression]). For example, index of surface variance is a measure of irregularity of anterior surface curvature. Similarly, index of vertical asymmetry is a measure of degree of asymmetry between the anterior curvatures of the superior and inferior cornea. Howev-

er, Kmax is only a measurement at one location. Thus, an increase in a measurement at one location (Kmax) may not be accompanied by an increase in index of surface variance and index of vertical asymmetry in every eye. Such a scenario was considered as a local progression only. The corollary to this scenario would be a global progression where several parameters increase in magnitude and not just Kmax. The concept of global versus local progression here should not be associated with change in the spatial spread of biomechanical degeneration of the cornea because we used only Pentacam tomographic parameters and no associations of these parameters with the spatial spread are known.

The Pentacam parameters were exported from each measurement as a comma separated value (csv) file. If at a certain time point multiple scans were present, then the average of parameters from repeat scans were used for that time point. The following Pentacam parameters were incorporated in the AI model:

1. Flat and steep axis curvature, mean curvature, axis and magnitude of astigmatism, and asphericity (Q-factor) of the anterior and posterior corneal surface (a total of 12 parameters).
2. Central and minimum corneal thickness and Belin-Ambrósio overall deviation (BAD-D) index (a total of 3 parameters). The BAD-D index is an aggregate parameter of all D indices calculated by the Pentacam.
3. Index of surface variance (ISV), index of height asymmetry (IHA), index of vertical asymmetry (IVA), index of height decentration (IHD), keratoconus index (KI), and center of keratoconus index (CKI) (a total of 6 parameters).
4. Root mean square of coma, lower order (LOA) and higher order (HOA) aberrations, along with defocus and spherical aberration of the anterior and posterior corneal surface (a total of 10 parameters). These aberrations were evaluated for the central 6-mm cornea and a Zernike order up to order 6.
5. Scores A, B, and C of the ABCD score in the Pentacam.[18] We did not consider D in the analyses because it was related to visual acuity only.

All of the above parameters were expected to increase in magnitude by definition with the progression of keratoconus expected for thicknesses. Further, these parameters evaluate different regions of the anterior and posterior corneal surface along with the change in thicknesses. The Pentacam parameters were previously evaluated with a random forest classifier for cross-sectional diagnosis of keratoconus.[5] Further, the random forest classifier was observed to be a highly efficient AI classifier for analyses of tomographic parameters of keratoconic eyes.[5] Therefore, we used the same to train and cross-validate our AI model using all of the above parameters. Each AI model consisted of 10 trees, underwent five-fold cross validation, and the average of the five folds was reported. Three different groups of progression and no progression follow-up visits were evaluated as the target classes in the AI models:

1. Model A: An increase in Kmax by 0.75 D was the cut-off for eyes classified (actual) as progression and the rest as no progression.
2. Model B: An increase in Kmax by 1.00 D was the cut-off for eyes classified (actual) as progression and the rest as no progression.
3. Model C: An increase in Kmax by 1.25 D was the cut-off for eyes classified (actual) as progression and the rest as no progression.

Different cut-offs were chosen to assess the variation in the predictions of the AI models to variations in different cut-off magnitudes of increase in Kmax. If at a certain time point multiple scans were present, then the average of Kmax from the repeat scans was used for that time point to assess progression.

Statistical Analyses

The top 10 parameters identified by each model were evaluated further. The mean ± standard deviation was calculated after assessing for normality of distribution with the Kolmogorov-Smirnov test. If normality was not met, then the median and its 95% CI was calculated. For each AI model, the area under the curve, sensitivity, specificity, classification accuracy, precision, recall, F1-score, and 95% CI were calculated. Bootstrapping was used to estimate the CI. The Orange[3] version 3.25.0 data mining package (University of Ljubljana) was used for the AI analyses. The five-fold cross-validation was automatically performed by the data mining package via randomized selection of eyes from the available population without causing overlap of eyes between the groups. Post-hoc assessment of sample size was performed using the area under the curve. A type I and II error of 0.05 (P value) and 0.2 (80% power) were used. MedCalc software version 19.0.4 (MedCalc, Inc) was used for sample size assessment.

RESULTS

After assessing for quality of the scans, a total of 1,518 follow-up and 366 first visit Pentacam scans of 366 eyes (296 patients) were included in the study. In Models A, B, and C, the number of follow-up visits

TABLE 1
Confusion Matrix Showing the Proportion of Actual Follow-up States Reclassified by the AI Models and Represented by the Predicted States[a]

	Predicted	
Model	**Progression**	**No Progression**
Model A Actual		
Progression	61.20% (0.79 ± 0.15)	38.80% (0.29 ± 0.14)
No progression	8.00% (0.65 ± 0.12)	92.00% (0.13 ± 0.11)
Model B Actual		
Progression	62.10% (0.81 ± 0.16)	37.90% (0.26 ± 0.14)
No progression	4.60% (0.65 ± 0.12)	95.40% (0.09 ± 0.12)
Model C Actual		
Progression	60.00% (0.81 ± 0.16)	40.00% (0.23 ± 0.16)
No progression	2.90% (0.62 ± 0.12)	97.10% (0.07 ± 0.10)

[a]The mean ± standard deviation of the random forest scores is shown within parentheses.

TABLE 2
AUC, Sensitivity, Specificity, Accuracy, F1-score, Precision, and Recall of the 3 Models[a]

Model	AUC	Sensitivity	Specificity	Accuracy	F1-score	Precision	Recall
Model A	0.90 (0.87 to 0.92)	85% (82 to 87)	82% (79 to 85)	83% (80 to 85)	0.82 (0.79 to 0.85)	0.823 (0.80 to 0.85)	0.83 (0.80 to 0.86)
Model B	0.91 (0.89 to 0.93)	86% (83 to 88)	82% (80 to 85)	88% (86 to 91)	0.88 (0.85 to 0.90)	0.878 (0.85 to 0.90)	0.88 (0.86 to 0.91)
Model C	0.93 (0.91 to 0.95)	89% (87 to 91)	81% (78 to 84)	91% (89 to 93)	0.90 (0.88 to 0.93)	0.904 (0.88 to 0.93)	0.91 (0.89 to 0.93)

AUC = area under the curve
[a]The 95% CI is shown within parentheses.

classified as progression was 224, 161, and 125, respectively. The remaining were classified as no progression, and both groups were used for training and cross-validating the AI model. Each Pentacam scan consisted of 50 radial semi-meridians. Each eye had a minimum of 4 follow-up visits after the first visit to assess progression based on the example described previously. The median follow-up period was 240 days (95% CI: 56 to 350 days). The minimum and maximum follow-up periods were 56 and 1,035 days, respectively. **Table 1** shows the confusion matrices for the three AI models. In Model A, 61.2% of the actual progression eyes were predicted as progression by the AI model. This indicated that a local increase in Kmax by 0.75 D was also indicated as progression by the other parameters. Similarly, 92% of the actual no progression eyes were also predicted as no progression by the AI model. Interestingly, approximately 38.8% of the actual progression eyes were predicted as no progression by the AI model. This indicated a discordance between local increase in Kmax and corresponding increases in the other Pentacam parameters. The proportion of eyes reclassified by the AI model was virtually the same between all three AI models (eg, models B and C had 62.1% and 60.0%, respectively, of the actual progression eyes predicted as progression by the model). **Table 1** also shows the mean ± standard deviation of the random forest scores (range: 0 to 1) for each of the predicted groups of eyes.

We also evaluated the performance indices of the three AI models. **Table 2** provides a summary of the indices. Overall, Model C had the best performance. For Model A, the minimum sample sizes required in the no progression and progression groups were 24 and 4, respectively, using a null hypothesis value of 0.5. Similar sample sizes were required for Models B and C, respectively. Thus, the sample sizes were adequate for this study. **Figure 1** shows a plot of the receiver operator characteristic curve for the three models. Using the information gain derived from the AI models, the top 10 parameters from each model were ranked. Interestingly, the same 10 parameters were ranked as the top 10 by each of the models. These included root mean square of LOAs, flat curvature, mean curvature,

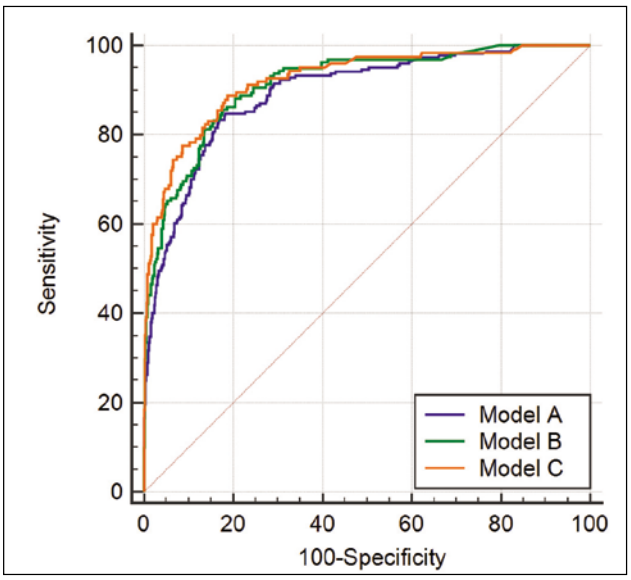

Figure 1. Receiver operator characteristic curve of the three artificial intelligence models. Model A = increase in maximum anterior curvature by 0.75 diopters (D). Model B = increase in maximum anterior curvature by 1.00 D. Model C = increase in maximum anterior curvature by 1.25 D.

root mean square of HOAs, and spherical aberration of the anterior corneal surface. Other parameters included in the top 10 were ISV, CKI, IVA, KI, and IHD. Interestingly, neither the BAD-D nor the A, B, and C scores were identified by the AI model as significant discriminants. **Table 3** shows the mean ± standard deviation of the top 10 parameters for Model A. We have also included the BAD-D and A, B, and C scores in the table. The trends were evident; for example, the increase in flat curvature of the anterior surface (K2) was significantly greater in the actual progression eyes predicted as progression eyes (61.2% in **Table 1** for Model A). However, the actual progression eyes predicted as no progression (38.8% in **Table 1** for Model A) and actual no progression eyes predicted as progression (92% in **Table 1** for Model A) had a similar magnitude of mean increase in K2. Similarly, **Tables 4-5** shows the mean ± standard deviation of the top 10 parameters for Models B and C, respectively.

Figure A (available in the online version of this article) shows the axial curvatures of two sample eyes. **Figure AA** shows the axial curvature of a follow-up and **Figure AB** shows the axial curvature of the reference time point for the same eye. **Figure AC** shows the difference in axial curvature between the follow-up time point and reference time point. This difference was an actual progression also predicted as a progression by the AI models. It was clear that not only Kmax increased, but other corneal parameters such as flat

TABLE 3
Mean ± Standard Deviation of the Top 10 Parameters With the Highest Information Gain in Model A

Parameter	"prog" as "prog"	"no prog" as "prog"	"prog" as "no prog"	"no prog" as "no prog"
RMS LOA	1.98 ± 2.12	0.61 ± 1.67	0.42 ± 1.55	-0.20 ± 1.00
K2	1.75 ± 1.97	0.44 ± 1.40	0.47 ± 1.25	-0.08 ± 0.79
RMS HOA	0.49 ± 0.59	0.17 ± 0.75	0.02 ± 0.60	-0.04 ± 0.32
ISV	11.79 ± 14.38	6.67 ± 14.63	0.54 ± 10.03	-1.07 ± 7.55
Km	1.47 ± 1.83	0.39 ± 1.13	0.29 ± 1.05	-0.08 ± 0.75
SA	-0.28 ± 0.42	-0.10 ± 0.26	-0.01 ± 0.24	0.03 ± 0.17
CKI	0.02 ± 0.03	0.01 ± 0.02	0.00 ± 0.01	0.00 ± 0.01
IVA	0.1 ± 0.20	0.07 ± 0.22	-0.01 ± 0.17	-0.01 ± 0.11
KI	0.03 ± 0.06	0.02 ± 0.05	0.00 ± 0.05	0.00 ± 0.03
IHD	0.02 ± 0.03	0.01 ± 0.03	0.00 ± 0.03	0.00 ± 0.02
BAD-D	1.33 ± 2.08	-1.36 ± 40.10	2.80 ± 25.07	-0.28 ± 5.35
A	0.08 ± 0.69	0.07 ± 0.51	0.08 ± 0.55	0.10 ± 0.59
B	0.04 ± 0.66	0.02 ± 0.27	0.07 ± 0.62	0.11 ± 0.61
C	0.07 ± 0.53	-0.05 ± 0.49	0.10 ± 0.51	0.02 ± 0.51

"prog" as "prog" = actual "progression" eyes predicted as "progression"; "no prog" as "prog" = actual "no progression" eyes predicted as "progression"; "prog" as "no prog" = actual "progression" eyes predicted as "no progression"; "no prog" as "no prog" = actual "no progression" eyes predicted as "no progression"; RMS LOA = root mean square of lower order aberrations of anterior corneal surface; K2 = flat curvature of anterior corneal surface; RMS HOA = root mean square of higher order aberrations of the anterior corneal surface; ISV = index of surface variance; Km = mean curvature of anterior corneal surface; SA = spherical aberration of anterior corneal surface; CKI = center of keratoconus index; IVA = index of vertical asymmetry; KI = keratoconus index; IHD = index of height decentration; BAD-D = Belin-Ambrósio Overall Deviation Index; A,B, and C = ABCD score of the Pentacam (Oculus Optikgeräte GmbH)

TABLE 4
Mean ± Standard Deviation of the Top 10 Parameters With the Highest Information Gain in Model B

Parameter	"prog" as "prog"	"no prog" as "prog"	"prog" as "no prog"	"no prog" as "no prog"
RMS LOA	2.38 ± 2.11	0.96 ± 1.2	0.42 ± 0.8	-0.05 ± 0.82
K2	2.29 ± 2.33	-0.08 ± 2.45	0.78 ± 1.65	-0.07 ± 1.02
RMS HOA	0.57 ± 0.66	-0.18 ± 1.11	0.09 ± 0.59	0.00 ± 0.31
ISV	2.00 ± 1.95	0.96 ± 1.09	0.16 ± 0.89	-0.06 ± 0.74
Km	0.02 ± 0.03	0.01 ± 0.02	0.00 ± 0.02	0.00 ± 0.01
SA	13.83 ± 16.37	1.93 ± 22.28	1.49 ± 7.94	-0.19 ± 7.55
CKI	-0.37 ± 0.44	-0.18 ± 0.28	0.00 ± 0.27	0.03 ± 0.17
IVA	-0.42 ± 0.55	-0.36 ± 6.87	-0.03 ± 0.27	0.01 ± 0.32
KI	-1.74 ± 2.54	-0.89 ± 2.10	-0.08 ± 1.63	0.13 ± 0.99
IHD	0.39 ± 0.63	-0.17 ± 0.97	0.05 ± 0.54	0.00 ± 0.33
BAD-D	1.39 ± 2.37	-8.01 ± 48.53	0.60 ± 2.53	0.48 ± 11.26
A	0.06 ± 0.75	0.04 ± 0.19	0.10 ± 0.44	0.10 ± 0.6
B	0.01 ± 0.75	0.07 ± 0.27	0.10 ± 0.44	0.10 ± 0.61
C	0.04 ± 0.55	0.00 ± 0.39	0.10 ± 0.44	0.03 ± 0.52

"prog" as "prog" = actual "progression" eyes predicted as "progression"; "no prog" as "prog" = actual "no progression" eyes predicted as "progression"; "prog" as "no prog" = actual "progression" eyes predicted as "no progression"; "no prog" as "no prog" = actual "no progression" eyes predicted as "no progression"; RMS LOA = root mean square of lower order aberrations of anterior corneal surface; K2 = flat curvature of anterior corneal surface; RMS HOA = root mean square of higher order aberrations of the anterior corneal surface; ISV = index of surface variance; Km = mean curvature of anterior corneal surface; SA = spherical aberration of anterior corneal surface; CKI = center of keratoconus index; IVA = index of vertical asymmetry; KI = keratoconus index; IHD = index of height decentration; BAD-D = Belin-Ambrósio Overall Deviation Index; A,B, and C = ABCD score of the Pentacam (Oculus Optikgeräte GmbH)

TABLE 5
Mean ± Standard Deviation of the Top 10 Parameters With the Highest Information Gain in Model C

Parameter	"prog" as "prog"	"no prog" as "prog"	"prog" as "no prog"	"no prog" as "no prog"
RMS LOA	2.70 ± 2.14	1.32 ± 1.41	0.86 ± 1.51	-0.02 ± 0.81
K2	2.39 ± 1.93	1.06 ± 1.01	0.35 ± 1.44	-0.02 ± 0.75
RMS HOA	2.70 ± 2.36	-0.11 ± 1.57	1.08 ± 1.98	-0.03 ± 1.11
ISV	0.03 ± 0.03	0.01 ± 0.03	0.00 ± 0.02	0.00 ± 0.01
Km	-0.47 ± 0.44	-0.15 ± 0.40	0.01 ± 0.32	0.02 ± 0.17
SA	0.64 ± 0.60	0.01 ± 0.81	0.18 ± 0.83	0.00 ± 0.37
CKI	15.75 ± 16.36	6.44 ± 14.58	3.44 ± 13.33	-0.08 ± 8.37
IVA	-2.31 ± 2.58	-0.33 ± 2.40	0.13 ± 1.97	0.07 ± 1.01
KI	-0.42 ± 0.40	-0.16 ± 2.03	-0.15 ± 0.71	-0.01 ± 1.42
IHD	0.04 ± 0.07	0.01 ± 0.08	0.01 ± 0.07	0.00 ± 0.03
BAD-D	1.7 ± 2.22	0.83 ± 79.93	0.56 ± 3.24	0.10 ± 6.51
A	0.03 ± 0.61	0.17 ± 0.38	0.14 ± 0.83	0.09 ± 0.58
B	0.00 ± 0.74	-0.06 ± 0.64	0.08 ± 0.70	0.10 ± 0.58
C	0.04 ± 0.42	-0.17 ± 0.38	0.14 ± 0.61	0.03 ± 0.52

"prog" as "prog" = actual "progression" eyes predicted as "progression"; "no prog" as "prog" = actual "no progression" eyes predicted as "progression"; "prog" as "no prog" = actual "progression" eyes predicted as "no progression"; "no prog" as "no prog" = actual "no progression" eyes predicted as "no progression"; RMS LOA = root mean square of lower order aberrations of anterior corneal surface; K2 = flat curvature of anterior corneal surface; RMS HOA = root mean square of higher order aberrations of the anterior corneal surface; ISV = index of surface variance; Km = mean curvature of anterior corneal surface; SA = spherical aberration of anterior corneal surface; CKI = center of keratoconus index; IVA = index of vertical asymmetry; KI = keratoconus index; IHD = index of height decentration; BAD-D = Belin-Ambrósio Overall Deviation Index; A,B, and C = ABCD score of the Pentacam (Oculus Optikgeräte GmbH)

and steep axis curvature and aberrations had also increased in the central and mid cornea (**Figure AC**). **Figure AD** shows the axial curvature of a follow-up and **Figure AE** shows the axial curvature of the reference time point for another eye. **Figure AF** shows the difference in axial curvature between the follow-up time point and reference time point. This difference was an actual progression but predicted as no progression by the AI models. In **Figure AF**, it is clear that only a local increase in Kmax was noted in the inferior zone of the cornea. whereas the central and superior cornea had a much smaller change in curvature.

DISCUSSION

Perhaps the most widely discussed study on progression of keratoconus is the Collaborative Longitudinal Evaluation of Keratoconus (CLEK) study, which reported an average 8-year increase in flat axis curvature of 1.60 D, with 24% demonstrating increases of 3.00 D or more.[19] The CLEK study identified the increase in corneal curvature as one of the predominant reasons for decrease in the scores for Dependency, Mental Health, Ocular Pain, and Role Difficulties.[19] However, there is no robust algorithm for stratification of progression of keratoconus using corneal tomography. In India, a prevalence of 2.3% itself translated to several million patients suffering from keratoconus and enough donor tissue for transplantation is lacking.[7,20,21] We speculate that eyes with severe keratoconus with continued global progression (indicated by the AI model) may be preferred for keratoplasty earlier than those with local progression to reduce the failure rates of keratoplasty,[21] because by definition global progression indicates greater remodeling of the cornea than local progression. This would require a prospective study in the future. In some regions of the world, the prevalence of keratoconus could be as high as 18.7% of the general population.[22] It should be noted here that the primary objective of this study was to use AI to assess progression in keratoconic eyes and not to develop another AI classifier to diagnose keratoconic eyes.

An interesting study using Placido topography on progression of keratoconus noted a significant increase in mean Kmax (0.30 ± 1.21 D), steep curvature (0.27 ± 0.90 D), flat curvature (0.34 ± 1.12 D), and inferior-superior ratio (0.26 ± 0.82 D) between baseline and final review.[23] Further, 18.6% to 25.6% of eyes had a 1.00 D or greater increase in one or more of the four parameters (Kmax, flat and steep curvature, inferior-superior ratio), whereas 18.5% to 37.0% of the patients had a 1.00 D or greater increase in these parameters in at least one eye over the study period.[23] However, less than 10% of eyes exhibited a greater than 1.00 D increase/year in all topographic parameters.[23] Remarkably, this heterogenous change in topographic parameters was similar to the observations from the current study because a change in some or all parameters indicates the concept of local versus global progression. A study using the Pentacam identified only two parameters, the BAD-D and keratoconus prediction index, as significant indicators of progression over a period of 1 year with a sensitivity of 70.6% and 84.7%, respectively.[10] The specificity was relatively better at 90%.[10]

Another study showed that the Kmax of eyes left untreated tended to progress by a mean of 1.18 ± 1.37 D when the age of the patients was younger than 18 years compared to older patients.[11] The study concluded that the age of the patient should be considered while assessing the risk of progression.[11] However, the study did not evaluate other Pentacam parameters.[11] This was a possible limitation of the study because younger patients (< 18 years of age) may be associated with allergies, eye rubbing, and other factors,[8] which could significantly influence changes in the corneal tomographic parameters other than just Kmax. Therefore, a comprehensive evaluation of tomographic parameters via a single model could assist in stratification of the magnitude of progression. We believe that this study effectively provides such a strategy using just corneal tomography.

To better explain this, a recent study introduced the DUCK score to identify patients better suited for CXL.[16] The study concluded that the DUCK score was able to identity eyes that would not progress if CXL was withheld by nearly 35% despite an increase in Kmax by 1.00 D.[16] This result was remarkably similar to ours. In **Table 1**, approximately 60% to 62% of the eyes classified as actual progression were predicted as progression by the models, whereas approximately 38% to 40% of the eyes were predicted as no progression. This implied that approximately 38% to 40% of the eyes had only a local change indicated by Kmax, whereas the other Pentacam parameters underwent changes similar to the eyes classified as actual no progression. The DUCK score used visual acuity and quality of vision, both of which are highly subjective and can vary depending on the questionnaire posed to assess vision-specific quality of life. However, our AI models rely solely on device parameters and can be easily replicated using data from other tomography devices reporting the same parameters. Thus, our analyses were minimally affected by neither the patient nor the observer. We propose that CXL of actual progression eyes predicted as no progression may be

delayed until the parameters of these eyes actually meet the criteria of global progression predicted by the AI models. It is possible that these actual progression eyes predicted as no progression by the AI models may not progress similar to the outcomes of DUCK study.[16] Thus, these eyes could be kept on a watch-list for progression instead of undergoing CXL solely based on increase in Kmax. This needs to be evaluated in future prospective studies. We further propose that Model B be used mostly because historically the selection of CXL was guided primarily by the definition of an increase in Kmax by 1.00 D. If Kmax alone was sufficient to confirm progression of disease, then none of the progression eyes would be predicted as no progression by the AI model (**Table 1**) and a perfect area under the curve (approximately 1 with 100% sensitivity and specificity) will be obtained. It was possible that the progression eyes predicted as no progression by the AI model had changes in the other parameters within their repeatability limits despite a significant change in Kmax (eg, Model C used a Kmax increase of 1.25 D as a cut-off). Thus, the AI model was effectively able to combine all Pentacam parameters to assess progression of the disease better by overcoming repeatability issues of the scans. Practically, it would be virtually impossible for an ophthalmologist to perform isolated assessment of change in every Pentacam parameter on every follow-up visit without such an AI.

Figures AA-AC showed an example of global progression, whereas **Figures AD-AF** showed an example of local progression. The central cornea is the thinnest region. Thus, the feed forward cycle of progressive thinning in keratoconic eyes can lead to progressively increasing mechanical stress in the stroma. This could lead to further biomechanical degeneration.[24] This concept was highlighted in **Figure A** where the differential progression between regions of the cornea indicated a differential grade of progression between keratoconic eyes. A limitation of our study was that the analyses relied entirely on our Asian-Indian population of keratoconic eyes. However, the tomographic changes are virtually identical in all populations as healthy corneas progress to keratoconus (eg, high coma, high Kmax, and thin cornea). Therefore, any clinical practice using the Pentacam or any other device having the same parameters as the Pentacam could rely on these models to assess whether the keratoconic cornea underwent a local or global change in corneal tomography.

Another limitation of the study was that the outcomes of the study may be impacted by the repeatability of Kmax in keratoconic eyes. In an earlier study, the within-subject standard deviation and test–retest variability of the Pentacam for Kmax was 0.36 and 1.00 D for keratoconic eyes, respectively.[25] This was significantly better than the corresponding measurements from the Orbscan (Bausch & Lomb).[25] Thus, the use of the Pentacam in this study was justified in comparison to Placido imaging because its repeatability in keratoconic eyes was also the best relative to other clinical tomographers.[26] A meta-analysis of published data on progression of keratoconus showed a significant increase in Kmax by 0.70 D at 12 months (P = .003). However, our population of 366 eyes had a significantly greater increase in Kmax with a mean follow-up time of 240 days. Thus, geographical differences were an obvious confounder of the conclusions from the meta-analyses.[27]

Another limitation was that the study did not include any measures of change in parameters of inflammation in the AI models because effective control of inflammation may also prevent disease progression.[28] Future studies need to investigate whether these inflammatory parameters could also be included in the decision-making process. Future studies may also include layer-specific corneal changes in the AI model, which could be effectively quantified by imaging methods with better axial resolution.[29] This is also one of the limitations of this study because layer-specific information was not included. Another limitation of the study was that we could not incorporate rate of progression as a parameter in the AI model due to heterogenous distribution of follow-up periods among the study eyes. However, this limitation is a practical challenge because the patients are advised to have regular follow-up visits but compliance is found wanting. In concept, this study can be replicated with other imaging modalities such as Placido and optical coherence tomography, and needs further investigation.

This study showed a novel application of AI to better use corneal tomographic parameters to differentiate between local versus global changes in the cornea such that the eyes undergoing a global change may preferentially undergo CXL first.

AUTHOR CONTRIBUTIONS

Study concept and design (RS, RMMAN, ASR); data collection (GK, RN, PK, KG, NS); analysis and interpretation of data (GK, RN, PK, KG, NS); writing the manuscript (GK, RN, PK, KG, NS); critical revision of the manuscript (RS, RMMAN, ASR)

REFERENCES

1. Masiwa LE, Moodley V. A review of corneal imaging methods for the early diagnosis of pre-clinical keratoconus. *J Optom*. 2020;13(4):269-275. doi:10.1016/j.optom.2019.11.001
2. Reinstein DZ, Archer TJ, Urs R, Gobbe M, RoyChoudhury A, Sil-

verman RH. Detection of keratoconus in clinically and algorithmically topographically normal fellow eyes using epithelial thickness analysis. *J Refract Surg*. 2015;31(11):736-744. doi:10.3928/1081597X-20151021-02

3. Abou Shousha M, Perez VL, Fraga Santini Canto AP, et al. The use of Bowman's layer vertical topographic thickness map in the diagnosis of keratoconus. *Ophthalmology*. 2014;121(5):988-993. doi:10.1016/j.ophtha.2013.11.034
4. Matalia H, Francis M, Gangil T, et al. Noncontact quantification of topography of anterior corneal surface and Bowman's layer with high-speed OCT. *J Refract Surg*. 2017;33(5):330-336. doi:10.3928/1081597X-20170201-01
5. Chandapura R, Salomão MQ, Ambrósio R Jr, Swarup R, Shetty R, Sinha Roy A. Bowman's topography for improved detection of early ectasia. *J Biophotonics*. 2019;12(10):e201900126. doi:10.1002/jbio.201900126
6. Gokhale NS. Epidemiology of keratoconus. *Indian J Ophthalmol*. 2013;61(8):382-383. doi:10.4103/0301-4738.116054
7. Jonas JB, Nangia V, Matin A, Kulkarni M, Bhojwani K. Prevalence and associations of keratoconus in rural Maharashtra in central India: the Central India Eye and Medical Study. *Am J Ophthalmol*. 2009;148(5):760-765. doi:10.1016/j.ajo.2009.06.024
8. Das AV, Donthineni PR, Sai Prashanthi G, Basu S. Allergic eye disease in children and adolescents seeking eye care in India: electronic medical records driven big data analytics report II. *Ocul Surf*. 2019;17(4):683-689. doi:10.1016/j.jtos.2019.08.011
9. Jeng BH, Farid M, Patel SV, Schwab IR. Corneal cross-linking for keratoconus: a look at the data, the Food and Drug Administration, and the future. *Ophthalmology*. 2016;123(11):2270-2272. doi:10.1016/j.ophtha.2016.08.006
10. Shajari M, Steinwender G, Herrmann K, et al. Evaluation of keratoconus progression. *Br J Ophthalmol*. 2019;103(4):551-557. doi:10.1136/bjophthalmol-2017-311651
11. Romano V, Vinciguerra R, Arbabi EM, et al. Progression of keratoconus in patients while awaiting corneal cross-linking: a prospective clinical study. *J Refract Surg*. 2018;34(3):177-180. doi:10.3928/1081597X-20180104-01
12. Wittig-Silva C, Chan E, Islam FMA, Wu T, Whiting M, Snibson GR. A randomized, controlled trial of corneal collagen cross-linking in progressive keratoconus: three-year results. *Ophthalmology*. 2014;121(4):812-821. doi:10.1016/j.ophtha.2013.10.028
13. O'Brart DPS, Chan E, Samaras K, Patel P, Shah SP. A randomised, prospective study to investigate the efficacy of riboflavin/ultraviolet A (370 nm) corneal collagen cross-linkage to halt the progression of keratoconus. *Br J Ophthalmol*. 2011;95(11):1519-1524. doi:10.1136/bjo.2010.196493
14. Hersh PS, Stulting RD, Muller D, et al; United States Crosslinking Study Group. United States multicenter clinical trial of corneal collagen crosslinking for keratoconus treatment. *Ophthalmology*. 2017;124(9):1259-1270. doi:10.1016/j.ophtha.2017.03.052
15. Lombardo M, Serrao S, Lombardo G, Schiano-Lomoriello D. Two-year outcomes of a randomized controlled trial of transepithelial corneal crosslinking with iontophoresis for keratoconus. *J Cataract Refract Surg*. 2019;45(7):992-1000. doi:10.1016/j.jcrs.2019.01.026
16. Wisse RPL, Simons RWP, van der Vossen MJB, et al. Clinical evaluation and validation of the Dutch crosslinking for keratoconus score. *JAMA Ophthalmol*. 2019;137(6):610-616. doi:10.1001/jamaophthalmol.2019.0415
17. Matalia H, Narasimhan R, Chinnappaiah N, Kumar V, Sinha Roy A. An interesting case of data gaps in measurement of corneal curvature with Scheimpflug tomography. *J Refract Surg*. 2020;36(5):350-351. doi:10.3928/1081597X-20200325-02
18. Belin MW, Duncan JK. Keratoconus: the ABCD grading system. *Klin Monatsbl Augenheilkd*. 2016;233(6):701-707. doi:10.1055/s-0042-100626
19. Wagner H, Barr JT, Zadnik K; Collaborative Longitudinal Evaluation of Keratoconus (CLEK) Study Group. Collaborative Longitudinal Evaluation of Keratoconus (CLEK) Study: methods and findings to date. *Cont Lens Anterior Eye*. 2007;30(4):223-232. doi:10.1016/j.clae.2007.03.001
20. Kennedy RH, Bourne WM, Dyer JA. A 48-year clinical and epidemiologic study of keratoconus. *Am J Ophthalmol*. 1986;101(3):267-273. doi:10.1016/0002-9394(86)90817-2
21. Das AV, Basu S. Indications and prognosis for keratoplasty in eyes with severe visual impairment and blindness due to corneal disease in India. *Br J Ophthalmol*. 2021;105(1):17-21. doi:10.1136/bjophthalmol-2019-315361
22. Al-Amri AM. Prevalence of keratoconus in a refractive surgery population. *J Ophthalmol*. 2018;2018:5983530. doi:10.1155/2018/5983530
23. Gokul A, Patel DV, Watters GA, McGhee CNJ. The natural history of corneal topographic progression of keratoconus after age 30 years in non-contact lens wearers. *Br J Ophthalmol*. 2017;101(6):839-844. doi:10.1136/bjophthalmol-2016-308682
24. Roberts CJ, Dupps WJ Jr. Biomechanics of corneal ectasia and biomechanical treatments. *J Cataract Refract Surg*. 2014;40(6):991-998. doi:10.1016/j.jcrs.2014.04.013
25. Meyer JJ, Gokul A, Vellara HR, Prime Z, McGhee CN. Repeatability and agreement of Orbscan II, Pentacam HR, and Galilei Tomography systems in corneas with keratoconus. *Am J Ophthalmol*. 2017;175:122-128. doi:10.1016/j.ajo.2016.12.003
26. Shetty R, Arora V, Jayadev C, et al. Repeatability and agreement of three Scheimpflug-based imaging systems for measuring anterior segment parameters in keratoconus. *Invest Ophthalmol Vis Sci*. 2014;55(8):5263-5268. doi:10.1167/iovs.14-15055
27. Ferdi AC, Nguyen V, Gore DM, Allan BD, Rozema JJ, Watson SL. Keratoconus natural progression: a systematic review and meta-analysis of 11,529 eyes. *Ophthalmology*. 2019;126(7):935-945. doi:10.1016/j.ophtha.2019.02.029
28. Shetty R, Kaweri L, Pahuja N, et al. Current review and a simplified "five-point management algorithm" for keratoconus. *Indian J Ophthalmol*. 2015;63(1):46-53. doi:10.4103/0301-4738.151468
29. Khamar P, Chandapura R, Shetty R, et al. Epithelium Zernike indices and artificial intelligence can differentiate epithelial remodeling between flap and flapless refractive procedures. *J Refract Surg*. 2020;36(2):97-103. doi:10.3928/1081597X-20200103-01

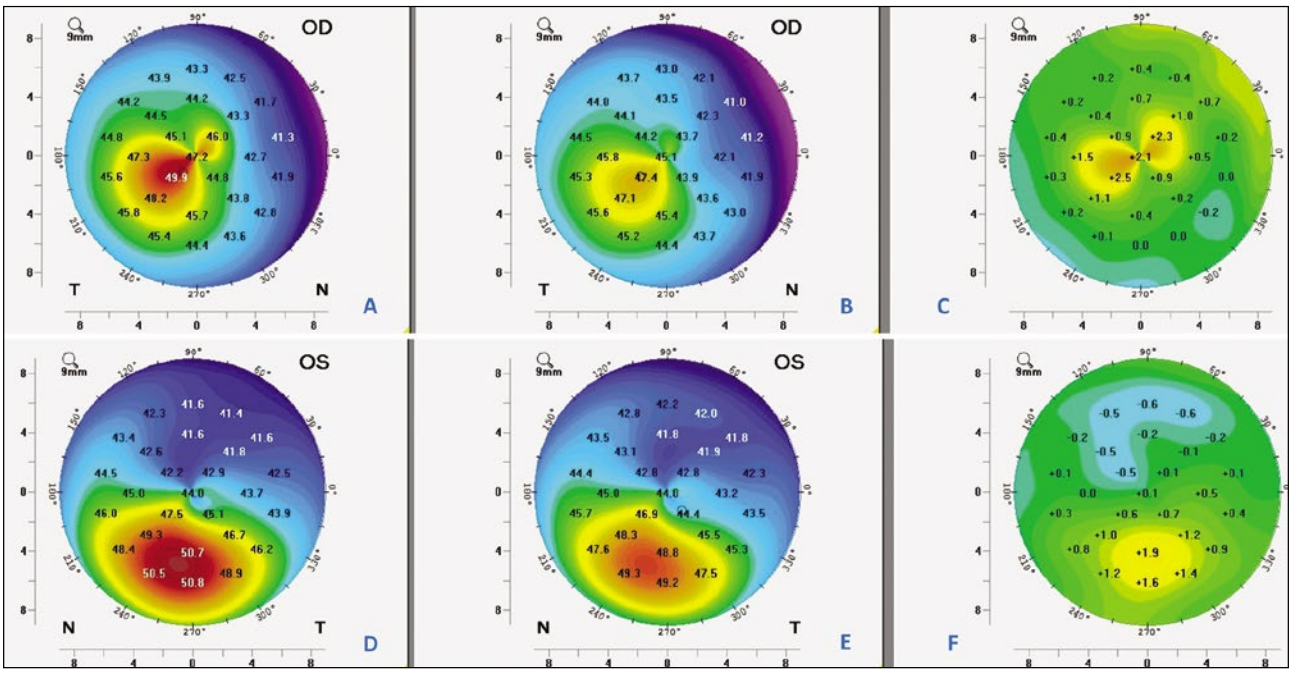

Figure A. (A) Follow-up anterior curvature of an actual progression eye predicted as progression by the artificial intelligence (AI) models. (B) Reference anterior curvature of the same eye shown in A. (C) Difference in axial curvature or A minus B. (D) Follow-up anterior curvature of an actual progression eye predicted as no progression by the AI models. (E) Reference anterior curvature of the same eye shown in D. (F) Difference in axial curvature or D minus E. OD = right eye; OS = left eye; N = nasal; T = temporal

ORIGINAL ARTICLE

Mitomycin C Application After Corneal Cross-linking for Keratoconus Increases Stromal Haze

Shady T. Awwad, MD; Lily M. Chacra, MD; Chadi Helwe, MSc; Ahmad R. Dhaini, PhD; Talar Telvizian, MD; Julien Torbey, MD; Maamoun Abdul Fattah, MD; Emilio A. Torres-Netto, MD; Farhad Hafezi, MD, PhD; Rohit Shetty, MD, PhD

ABSTRACT

PURPOSE: To evaluate and compare corneal haze as determined by optical coherence tomography (OCT) after corneal cross-linking (CXL) for the treatment of mild to moderate keratoconus with or without mitomycin C (MMC) application.

METHODS: This was a retrospective analysis of 87 eyes of 72 patients with mild to moderate keratoconus. The first group (n = 44 eyes) underwent CXL between June 2013 and January 2015 and the second group (n = 43 eyes) underwent CXL with MMC (CXL+MMC) between February and December 2015, both following the Dresden protocol. Patients were evaluated preoperatively and at 1, 3, 6, and 12 months postoperatively. Main outcome measures were corneal reflectivity and haze reflectivity measured by a specially developed OCT image analysis software.

RESULTS: Anterior corneal reflectivity at 1 month and 1 year postoperatively was 14.79 ± 4.68 and 25.97 ± 15.01 ($P < .001$), and 13.88 ± 4.39 and 18.41 ± 9.25 ($P = .025$) for the CXL and CXL+MMC groups, respectively. The reflectivity of the anterior stromal haze region at 1 month and 1 year postoperatively was 23.15 ± 5.91 and 33.14 ± 16.58 ($P = .005$), and 20.58 ± 7.88 and 27.14 ± 12.80 ($P = .049$) for both groups, respectively. The changes in simulated keratometry from preoperatively to postoperatively were similar in both groups. The CXL+MMC group showed larger maximum keratometry flattening: 53.41 ± 6.88 diopters (D) preoperatively and 49.44 ± 5.66 D 1 year postoperatively versus 52.27 ± 5.78 and 50.91 ± 4.25 D for CXL alone ($P = .008$).

CONCLUSIONS: MMC application following CXL significantly increases corneal haze. Similar studies need to be performed on simultaneous CXL and photorefractive keratectomy to evaluate the role of MMC in haze formation in such procedures.

[*J Refract Surg*. 2021;37(2):83-90.]

Corneal cross-linking (CXL) is a widely performed therapeutic technique for the treatment of ectasias such as keratoconus and postoperative ectasia that has been proven to successfully halt its progression and potentially improve topographic and visual outcomes.[1,2] A common complication after CXL is corneal haze development,[3] which can affect postoperative visual acuity. Corneal haze after CXL in patients with keratoconus usually develops in the first 3 months postoperatively, peaking at 1 month and clearing between 6 and 12 months.[4-6] Eyes with more advanced disease tend to have a higher likelihood of developing more severe and permanent haze.[1,7]

It is believed that CXL-induced keratocyte apoptosis leads to gradual repopulation by unaffected keratocytes between 2 and 3 months postoperatively, returning to baseline by 12 months postoperatively.[6-8]

From the Departments of Ophthalmology (STA, LMC, TT, JT, MAF) and Computer Sciences (CH, ARD), American University of Beirut Medical Center, Beirut, Lebanon; ELZA Institute, Dietikon/Zurich, Switzerland (EAT-N, FH); Laboratory of Ocular Cell Biology, CABMM, University of Zurich, Switzerland (EAT-N, FH); the Department of Ophthalmology, Federal University of São Paulo, São Paulo, Brazil (EAT-N); the Department of Ophthalmology, University of Wenzhou, Wenzhou, China (FH); Medical Faculty, University of Geneva, Geneva, Switzerland (FH); and Narayana Nethralaya Eye Institute, Bangalore, India (RS).

Submitted: May 14, 2020; Accepted: November 9, 2020

Dr. Hafezi holds a patent on a UV light source (PCT/CH 2012/000090). The remaining authors have no financial or proprietary interest in the materials presented herein.

Drs. Awwad and Chacra contributed equally to this work and should be considered as equal first authors.

Correspondence: Shady T. Awwad, MD, Department of Ophthalmology, American University of Beirut Medical Center, Cairo Street, P.O. Box 110236, Beirut 110236, Lebanon. Email: sawwad@gmail.com

doi:10.3928/1081597X-20201124-01

Reprinted with permission from SLACK Incorporated, Awwad ST, Chacra LM, Helwe C, et al. Mitomycin C Application After Corneal Cross-linking for Keratoconus Increases Stromal Haze. *J Refract Surg*. 2021;37(2):83-90. doi:10.3928/1081597X-20201124-01

TABLE 1
CXL Methods

Parameter	Conventional CXL	CXL+MMC
Treatment target	Keratoconus	Keratoconus
Fluence (total) (J/cm^2)	5.4	5.4
Soak time and interval (minutes)	30(q2)	30(q2)
Intensity (mW)	3	3
Treatment time (minutes)	30	30
Epithelium status	Off	Off
Chromophore	Riboflavin (IROC Innocross AG)	Riboflavin (IROC Innocross AG)
Chromophore carrier	Dextran	Dextran
Chromophore osmolarity	Iso-osmolar	Iso-osmolar
Chromophore concentration	0.1%	0.1%
Light source	UV-X (IROC AG)	UV-X (IROC AG)
Irradiation mode (interval)	Continuous	Continuous
Protocol modifications	None	0.02% MMC applied to stromal bed, soaking time 45 seconds after CXL
Protocol abbreviation in manuscript	CXL	CXL+MMC

CXL = corneal cross-linking; MMC = mitomycin C

These keratocytes repopulate the corneal stroma in an activated state such as myofibroblasts, and proceed with increased and disorganized collagen deposition, which manifests as haze.[9] Mitomycin C (MMC) is an alkylating antibiotic that blocks DNA and RNA replication and protein synthesis.[10,11] It was shown to have both antiproliferative and cytotoxic effects on human keratocytes, as well as time- and dose-related inhibitory effects on human keratocyte proliferation.[12]

The main purpose of this study was to evaluate the benefit of using 0.02% MMC at the end of the CXL procedure to decrease the incidence and severity of postoperative corneal stromal haze by inhibiting the activation of incoming keratocytes.

PATIENTS AND METHODS

This was a retrospective study that included 87 myopic eyes of 72 patients who underwent CXL using the standard Dresden protocol between June 2013 and January 2015 at the American University of Beirut Medical Center in Lebanon. MMC was applied at the end of each CXL procedure as a routine protocol from February to December 2015. The group of patients that underwent CXL alone was compared to the group that underwent CXL with MMC. This study (BIO-2017-0280) was approved by the Institutional Review Board at the American University of Beirut and adhered to the principles of the Declaration of Helsinki.

PATIENT SELECTION

All patients underwent a complete ophthalmic examination as part of their routine work-up before CXL, including Placido-Scheimpflug imaging and corneal optical coherence tomography (OCT). All patients included in the study completed all follow-up examinations through the first postoperative year. Inclusion criteria were patients aged 18 years and older who underwent CXL at the American University of Beirut Medical Center for keratoconus progression. Keratoconus progression was defined as three consecutive tomographic measurements demonstrating an increase of at least 1.00 diopter (D) in the steepest anterior keratometric value (Kmax) in 1 year, and/or a 5% or greater decrease in mean central corneal thickness in 6 months. Exclusion criteria were corneal thickness values less than 400 µm at the thinnest point, intraocular pressure of greater than 21 mm Hg, advanced keratoconus necessitating corneal transplant, active ocular pathology, history of intraocular and/or corneal surgeries, history of herpetic keratitis, and autoimmune and/or connective tissue disease. Other exclusion criteria were preexisting corneal opacification/scars, severe dry eyes, and peripheral marginal degeneration.

CXL TECHNIQUE

All CXL procedures (**Table 1**) were performed according to the Dresden protocol.[13] The eye to be treated was anesthetized by applying proparacaine hydrochloride 0.5% drops on two occasions at 5-minute intervals. An

eyelid speculum was inserted between the eyelids and the central 9-mm corneal epithelium was removed with a blunt spatula. For corneal soaking, a solution of 0.1% riboflavin and 20% dextran (IROC Innocross AG) was instilled every 2 minutes for 30 minutes. An ultraviolet-A lamp with irradiance of 3 mW/cm^2 (UV-X; IROC AG), calibrated between each treatment, was focused on the corneal apex at a distance of 5 cm for 30 minutes (total energy of 5.4 J/cm^2). Meanwhile, during that time, the riboflavin drops were applied to the cornea every 2 minutes. In one of the groups, 0.02% MMC was applied to the stromal bed and left for 45 seconds. At the end of the procedure, in both groups, the eye was copiously irrigated with a balanced salt solution and a drop of 0.3% gatifloxacin followed by placement of a bandage soft contact lens, which was kept for at least 4 days until complete epithelialization ensued as judged by slit-lamp microscopy.

Postoperatively, patients were instructed to instill one drop of 0.3% gatifloxacin four times daily for 2 weeks with one drop of tobramycin–dexamethasone 0.1% four times daily for 1 week, and then one drop of 0.1% fluorometholone four times daily, tapered over 6 weeks.

OCT Measurements and Software Analysis

Using Cirrus high-definition optical coherence tomography (Cirrus HD-OCT; Carl Zeiss Meditec AG) on anterior segment cube 512 × 128 mode,[14] tomographic images and measurements were taken at baseline and at 1, 3, 6, and 12 months after CXL. All images were then evaluated by a dedicated corneal OCT image analysis software, with pending patent, which was developed in conjunction with the computer science department at the American University of Beirut and used by the authors in previous publications.[4,15,16] The software allows the automated and objective detection and classification of corneal haze and demarcation line on OCT images using machine learning (**Figure 1**).

The software measures cross-sectional haze surface area, corneal reflectivity, and haze reflectivity of the anterior, middle, and posterior stroma and total cornea. Corneal haze area is calculated as the percentage of pixels in the haze area of a particular region over the total number of pixels in that region. Haze reflectivity is calculated as the intensity of each pixel in a particular corneal region over the total number of pixels in the region, divided over 255 to obtain the grayscale and then converted into percentage. Gamma decoding was then applied to the reflectivity of the OCT images to restore the initial reflectivity parameters.

Placido and Scheimpflug Measurements

Topographic and tomographic measurements were obtained preoperatively, and at 1, 3, 6, and 12 months postoperatively, using a dual Scheimpflug and Placido system (Galilei; Ziemer). Accordingly, corneal thickness and preoperative and postoperative Kmax and mean keratometry values were extracted.

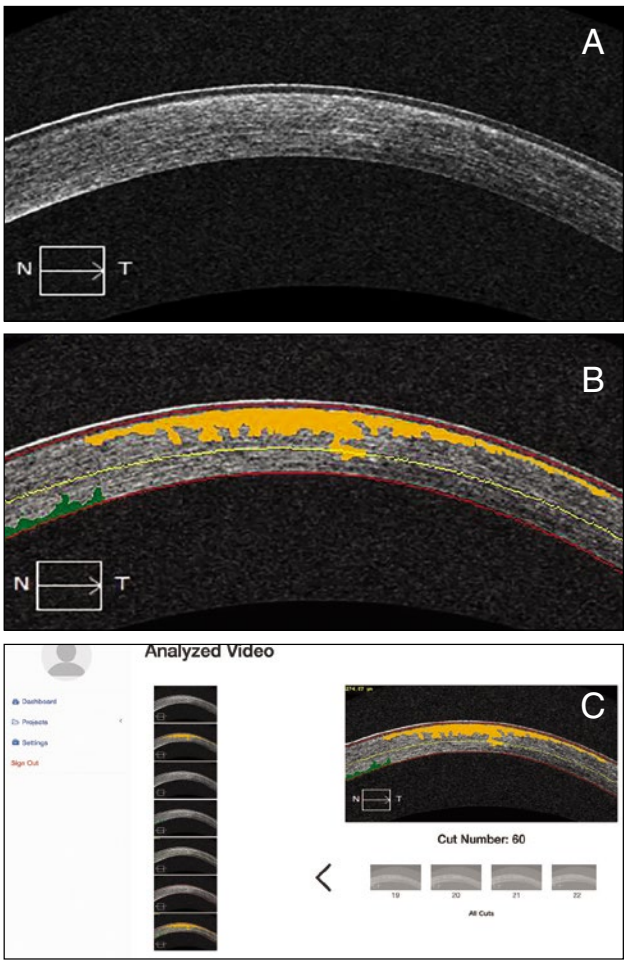

Figure 1. (A) Corneal optical coherence tomography (OCT) section of an eye 6 months after corneal cross-linking and mitomycin C application. (B) The software automatically detects and classifies the stromal haze on OCT images based on location, size, and reflectivity. Additionally, it identifies the demarcation line (in yellow) and its depth. (C) Screenshot of the software display.

Visual Measurements

Visual acuity testing was performed 4 m from the visual acuity chart. Uncorrected and corrected distance visual acuity were measured preoperatively and at 1, 3, 6, and 12 months postoperatively.

Statistical Analysis

Using a 95% confidence interval and a margin of error of 1.25 grayscale units (GSU), the minimum calculated sample size was 40 eyes based on a previously

TABLE 2
Visual and Tomographic Results of Eyes That Underwent CXL or CXL+MMC[a]

	CXL				CXL+MMC			
Parameter	UDVA (logMAR)	CDVA (logMAR)	SimK	Kmax	UDVA (logMAR)	CDVA (logMAR)	SimK	Kmax
Preoperative	0.35 ± 0.31	0.17 ± 0.20	46.6 ± 3.55	52.27 ± 5.78	0.37 ± 0.34	0.20 ± 0.19	47.49 ± 5.12	53.41 ± 6.88
Last follow-up	0.27 ± 0.18	0.14 ± 0.16	45.92 ± 3.71	50.91 ± 4.25	0.39 ± 0.37	0.20 ± 0.20	46.41 ± 4.60	49.44 ± 5.66
Within-group *P* value	.08	.18	< .001[b]	.01[b]	.67	.89	< .001[b]	< .001[b]

CXL = corneal cross-linking; MMC = mitomycin C; UDVA = uncorrected distance visual acuity; CDVA = corrected distance visual acuity; SimK = simulated keratometry; Kmax = steepest anterior keratometric value
[a]Values are presented as mean ± standard deviation.
[b]Statistically significant.

TABLE 3
Percentage of Corneal Reflectivity in Each Corneal Region After Conventional CXL and CXL+MMC[a]

	Anterior Stroma		Middle Stroma		Posterior Stroma	
Time	CXL	CXL+MMC	CXL	CXL+MMC	CXL	CXL+MMC
Baseline	11.91 ± 2.75 (6.71 to 22.76)	11.56 ± 2.21 (6.71 to 15.48)	9.85 ± 3.31 (3.39 to 19.39)	9.51 ± 2.94 (3.80 to 19.39)	7.76 ± 3.51 (1.93 to 16.90)	7.09 ± 2.69 (2.32 to 15.30)
P	.547		.636		.351	
1 month	14.79 ± 4.68 (0.99 to 24.21)	25.97 ± 15.01 (4.33 to 68.51)	14.65 ± 5.48 (6.13 to 31.58)	17.67 ± 11.54 (2.15 to 48.29)	10.59 ± 4.01 (4.24 to 19.13)	10.87 ± 7.57 (2.33 to 34.81)
P	< .001[b]		.219		.864	
3 months	16.14 ± 4.99 (8.18 to 27.99)	24.76 ± 16.47 (5.55 to 53.01)	13.30 ± 5.86 (5.24 to 27.04)	18.47 ± 14.62 (4.68 to 55.95)	9.41 ± 4.62 (3.39 to 20.92)	11.41 ± 9.94 (2.33 to 40.11)
P	.015[b]		.109		.372	
6 months	13.95 ± 3.77 (7.60 to 23.79)	21.83 ± 11.04 (3.87 to 38.39)	11.04 ± 3.53 (4.41 to 19.08)	14.68 ± 10.13 (2.84 to 38.05)	8.38 ± 3.00 (2.69 to 14.17)	11.35 ± 9.98 (0.95 to 41.70)
P	.002[b]		.113		.182	
12 months	13.88 ± 4.39 (1.58 to 23.78)	18.41 ± 9.25 (4.56 to 44.56)	10.60 ± 3.85 (1.47 to 21.25)	15.46 ± 10.26 (3.36 to 43.61)	8.19 ± 3.55 (1.98 to 18.12)	10.39 ± 8.38 (1.43 to 35.52)
P	.025[b]		.024[b]		.212	

CXL = corneal cross-linking; MMC = mitomycin C
[a]Values are presented as mean ± standard deviation (range).
[b]Statistically significant.

calculated standard deviation of 4.03 GSU for central corneal haze after CXL using Scheimpflug tomography.[17] SPSS software version 21.0 (SPSS, Inc) was used to perform statistical analysis, whereas data management and analysis were performed by Microsoft Office Excel version 16.16.6 (Microsoft Corporation). Descriptive statistics were reported as mean and standard deviations for continuous variables. Haze area and intensity at different time points were compared using the paired *t* test. Two-way repeated-measures analysis of variance with the Bonferroni correction for post-hoc analysis was used to compare the change in haze after CXL. A *P* value less than .05 was considered statistically significant unless stated otherwise.

RESULTS

Demographics

A total of 84 myopic eyes of 70 patients were analyzed by OCT. A total of 44 eyes underwent CXL alone (26 males and 13 females, mean age: 22 years), whereas 40 eyes had CXL with MMC (26 males and 14 females, mean age: 26 years).

According to the Amsler-Krumeich classification, 86.4% of eyes had grade 1 or grade 2 keratoconus and 13.6% had grade 3 keratoconus in the CXL group, whereas 85% of eyes had grade 1 or 2 keratoconus and 15% had grade 3 keratoconus in the CXL+MMC group. The recruited eyes had average preoperative Kmax values of 52.27 ± 5.78 and 53.71 ± 7.00 D (*P* =

TABLE 4
Percentage of Haze Reflectivity in Each Corneal Region After Conventional CXL and CXL+MMC[a]

	Anterior Stroma		Middle Stroma		Posterior Stroma	
Time	CXL	CXL+MMC	CXL	CXL+MMC	CXL	CXL+MMC
Baseline	16.66 ± 5.59 (7.78 to 27.68)	16.30 ± 5.12 (7.78 to 27.65)	18.82 ± 6.68 (7.01 to 35.89)	18.61 ± 6.85 (7.01 to 35.89)	19.18 ± 7.60 (9.30 to 42.40)	18.06 ± 6.00 (9.30 to 27.65)
P	.852		.916		.595	
1 month	23.15 ± 5.91 (13.97 to 42.27)	33.14 ± 16.58 (6.54 to 69.73)	21.51 ± 6.09 (11.42 to 39.88)	28.45 ± 14.09 (5.54 to 59.45)	20.60 ± 7.54 (8.14 to 41.06)	27.07 ± 16.92 (0.00 to 58.51)
P	.005[b]		.021[b]		.105	
3 months	24.18 ± 6.66 (14.97 to 37.31)	34.09 ± 19.30 (13.02 to 64.18)	20.67 ± 7.85 (9.53 to 39.69)	30.05 ± 17.47 (9.58 to 68.62)	20.37 ± 7.77 (4.47 to 34.50)	24.55 ± 16.69 (10.60 to 58.51)
P	.014[b]		.020[b]		.316	
6 months	22.56 ± 6.16 (10.79 to 35.56)	28.13 ± 12.52 (6.63 to 48.14)	20.92 ± 6.48 (9.57 to 38.10)	25.55 ± 12.96 (5.69 to 48.18)	21.03 ± 7.11 (7.82 to 38.12)	22.93 ± 11.55 (6.18 to 43.39)
P	.074		.141		.592	
12 months	20.58 ± 7.88 (2.90 to 38.22)	27.14 ± 12.80 (7.09 to 49.28)	22.93 ± 12.16 (2.87 to 50.30)	24.95 ± 12.72 (7.00 to 51.04)	22.31 ± 12.88 (3.14 to 47.99)	25.17 ± 12.61 (6.70 to 45.15)
P	.049[b]		.562		.492	

CXL = corneal cross-linking; MMC = mitomycin C
[a]Values are presented as mean ± standard deviation (range).
[b]Statistically significant.

.47), simulated keratometry values of 46.33 ± 3.15 and 47.49 ± 5.12 D (P = .29), and a central corneal thickness of 477.02 ± 40.84 and 485.85 ± 42.25 µm (P = .36) in the CXL and CXL+MMC groups, respectively.

Demarcation line depth between 1 and 3 months postoperatively was 337.15 ± 95.62 and 329.96 ± 71.09 µm for the CXL and CXL+MMC groups, respectively (P = .75).

Visual and Tomographic Results

The visual and topographic results are summarized in **Table 2**. Simulated keratometry and Kmax values decreased postoperatively in both groups (P < .01), with the decrease in Kmax being more significant in the CXL+MMC group (P < .001).

Refractive Results

The manifest refraction spherical equivalent was -3.34 ± 3.13 preoperatively and -2.97 ± 2.74 postoperatively (P = .72) in CXL and -2.65 ± 3.26 preoperatively and -2.89 ± 4.23 postoperatively (P = .84) in the CXL+MMC group. The change in manifest refraction spherical equivalent was not statistically significant between the two groups (P = .70).

Corneal Haze Measurements

Eyes undergoing CXL with MMC showed higher stromal reflectivity compared to CXL alone (Dresden protocol), especially in the anterior stroma at 1 and 6 months (**Table 3**). Eyes that had CXL and MMC showed more haze area reflectivity than CXL alone in all regions of the cornea throughout the follow-up period, but mainly in the anterior stroma at 1 and 3 months (**Table 4**). The percentage of haze area represents the ratio of cross-sectional haze surface area over the rest of the stromal surface area in a given corneal region (anterior, middle, or posterior), multiplied by 100. The anterior stromal haze area was 48.24 ± 12.65 and 61.46 ± 17.80 at 1 month postoperatively for the CXL and CXL+MMC groups, respectively (P = .013), 46.03 ± 11.13 and 54.41 ± 12.94 at 3 months postoperatively (P = .027), 42.53 ± 11.27 and 48.98 ± 10.37 at 6 months postoperatively (P = .038), and 47.58 ± 12.00 and 42.00 ± 11.14 at 12 months postoperatively (P = .048). The middle and posterior stromal haze areas were also measured at 1, 3, 6, and 12 months postoperatively with a significant value only in the middle stromal haze area at 1 month; 26.21 ± 6.10 and 32.41 ± 6.19 for the CXL and CXL+MMC groups, respectively (P = .045).

DISCUSSION

The safety and efficacy of corneal CXL in the treatment and long-term stabilization of progressive keratoconus has been well documented.[18-20] A recognized complication of CXL is the development of postopera-

tive haze,[3,8] especially affecting eyes with advanced keratoconus and steeper corneas.[1] Postoperative haze peaks at 1 month and usually stabilizes between 3 and 6 months,[5,6,15] with subsequent improvement in corneal transparency between 6 and 12 months after surgery.[4] Corneal transparency is attributed to the regular spacing and diameter of collagen fibrils,[21] as well as the structure and organization of stationary keratocytes.[22] The new covalent bonds established between the collagen lamellae after CXL[18,23] may affect the organization of the stromal structure responsible for corneal transparency.[3]

CXL-induced keratocyte apoptosis is typically restricted to a corneal stromal depth of approximately 350 µm, followed by repopulation of the anterior stroma by activated keratocytes between 1 and 3 months postoperatively.[6-8] The activation and repopulation of keratocytes belongs to a complex process of corneal wound healing intended to recover normal tissue function.

Understanding the corneal wound healing response after photorefractive keratectomy (PRK) may provide a clearer understanding of the process that occurs after CXL. Several studies have been performed on the corneal wound healing process after PRK, showing that PRK greatly diminishes the distribution and quantity of keratocytes in the anterior stroma by inducing apoptosis.[24] Also, the cytokines released by the upper, injured cell layers activate the viable, quiescent keratocytes along the wound borders.[25] The activated keratocytes repopulate the anterior stroma and generate myofibroblast-precursor cells.[26] These myofibroblasts are slightly opaque due to reduced crystallin protein production and they deposit disorganized extracellular matrix,[25] resulting in increased scattering of light and peaked haze formation in the first 3 months postoperatively.[22] Cytokines are necessary for the development and persistence of myofibroblast.[27] The decline in cytokine levels and the myofibroblast apoptosis, both brought about by the regeneration of the epithelial membrane, and the removal of the disorganized collagen by the repopulating keratocytes, are responsible for the late haze regression occurring between 3 and 6 months postoperatively.[25,28]

Interestingly, haze induced by PRK is different from that induced by CXL: corneal hyperreflectivity is more restricted to subepithelial areas following PRK, whereas in CXL areas of opacity can reach deeper layers of the corneal stoma.[3] As mentioned above, keratocytes have a central role in the cellular wound healing response. Remaining keratocytes adjacent to wound borders are activated by cytokines, and under particular mediation of the growth factor beta, there is a transformation of active keratocytes into myofibroblasts.[24] However, unlike PRK, the keratocyte apoptosis following CXL occurs in a much deeper extension of the corneal stroma, and therefore much of the inflammatory response that would be mediated by keratocytes, paradoxically, would not take place due such cellular shortages.

MMC, an antineoplastic alkylating agent,[29] has been successfully used in the prevention of subepithelial haze after PRK.[30] Although there was an early concern about the safety of MMC in PRK, studies have shown that it is relatively safe even when evaluated in the long term.[31] MMC is associated with the diminished presence of haze-related myofibroblasts within the wound.[32] It has been shown that the application of MMC after PRK on rabbit corneas triggers keratocyte and myofibroblast apoptosis.[10] Secondary to this observation, we wanted to test the role of MMC application in haze reduction after CXL. Surprisingly, the results of our study have shown a clinically significant increase in haze after the use of MMC as opposed to the CXL alone group.

Studies have shown that for months after the use of MMC, fewer keratocytes undergo mitosis in the anterior stroma.[10,28,32] This is attributable to MMC's prolonged apoptotic effect[29] and MMC-induced DNA damage in resident keratocytes that inhibits their entry into the cell cycle.[10,32] It has also been shown that MMC-induced DNA damage prevents keratocytes from responding to cytokines, hindering their repopulation of the anterior corneal stroma.[32] We believe that MMC's apoptotic effect on the resident quiescent keratocyte population, synergistic with that of CXL, results in a major cell drop-out in the treated area. The reduced density and mitotic activity of keratocytes interferes with their reparatory role, resulting in a diminished capacity to repopulate the injured area and a diminished removal of the unorganized collagen laid down by the myofibroblasts.[33] We also postulate that the larger magnitude of apoptosis induced by the concomitant use of MMC with CXL may result in a larger amount of cytokine release. These cytokines play an important role in the differentiation and maturation of myofibroblasts.[25] Apart from being opaque themselves, the increased quantity of myofibroblasts will lead to a greater deposition of disorganized collagen that can no longer be cleared out by the apoptotic keratocytes.[25] This can account for the clinical observation of increased haze peaking between 1 and 3 months postoperatively in our series.

The relationship between increased haze after CXL and flattening of the anterior cornea is well known: Hafezi et al[34] were the first to describe massive flattening in patients with marked permanent stromal haze

following standard CXL. Interestingly, the flattening effect of the haze may lead to an improvement in visual acuity in certain patients, where the positive effect of flattening on visual acuity might outweigh the negative effect of loss of transparency. Currently, it is not possible to predict the amount of induced haze and flattening after CXL. If it were possible to actively control the amount of haze, then a planned induction of such haze and flattening might be of benefit in selected cases of keratoconus, especially in cases with a myopic refraction.

This study has some limitations, including the retrospective character of the study. A further limitation is that the study results may not apply equally in all regions of the world. The Middle East, where this study was performed, not only has one of the highest prevalences of keratoconus,[35] but also, according to the observation of the authors, has a higher incidence of clinical haze after CXL than what has been reported in European and North American patients. It has been shown that corneal haze after PRK is more common in patients with darker skin, darker irides,[36] and higher exposure to environmental ultraviolet light.[37] Whether these risk factors apply to CXL still needs to be further elucidated. Finally, our study evaluated mild to moderate forms of keratoconus. The effect of MMC on more advanced forms of the disease, which have been associated with more severe haze, is yet to be evaluated.[1]

Instead of reducing postoperative haze as in its use after PRK, the application of MMC following CXL induced more postoperative haze, and therefore should be avoided. Based on the results of this study, we also recommend caution in using MMC in combined PRK and CXL procedures.

AUTHOR CONTRIBUTIONS

Study concept and design (STA, EAT-N, FH); data collection (LMC, CH, ARD, TT, JT, MAF); analysis and interpretation of data (STA, LMC, CH, ARD, MAF, RS); writing the manuscript (STA, LMC, TT, JT, EAT-N, FH); critical revision of the manuscript (STA, LMC, CH, ARD, MAF, EAT-N, FH, RS); statistical expertise (LMC, ARD, MAF); administrative, technical, or material support (LMC, CH, ARD); supervision (STA)

REFERENCES

1. Raiskup F, Hoyer A, Spoerl E. Permanent corneal haze after riboflavin-UVA-induced cross-linking in keratoconus. *J Refract Surg*. 2009;25(9):S824-S828. doi:10.3928/1081597X-20090813-12
2. Richoz O, Mavrakanas N, Pajic B, Hafezi F. Corneal collagen cross-linking for ectasia after LASIK and photorefractive keratectomy: long-term results. *Ophthalmology*. 2013;120(7):1354-1359. doi:10.1016/j.ophtha.2012.12.027
3. Gutiérrez R, Lopez I, Villa-Collar C, González-Méijome JM. Corneal transparency after cross-linking for keratoconus: 1-year follow-up. *J Refract Surg*. 2012;28(11):781-786. doi:10.3928/1081597X-20121011-06
4. Dhaini AR, Abdul Fattah M, El-Oud SM, Awwad ST. Automated detection and classification of corneal haze using optical coherence tomography in patients with keratoconus after cross-linking. *Cornea*. 2018;37(7):863-869. doi:10.1097/ICO.0000000000001570
5. Greenstein SA, Fry KL, Bhatt J, Hersh PS. Natural history of corneal haze after collagen crosslinking for keratoconus and corneal ectasia: Scheimpflug and biomicroscopic analysis. *J Cataract Refract Surg*. 2010;36(12):2105-2114. doi:10.1016/j.jcrs.2010.06.067
6. Mazzotta C, Hafezi F, Kymionis G, et al. In vivo confocal microscopy after corneal collagen crosslinking. *Ocul Surf*. 2015;13(4):298-314. doi:10.1016/j.jtos.2015.04.007
7. Mazzotta C, Balestrazzi A, Traversi C, et al. Treatment of progressive keratoconus by riboflavin-UVA-induced cross-linking of corneal collagen: ultrastructural analysis by Heidelberg Retinal Tomograph II in vivo confocal microscopy in humans. *Cornea*. 2007;26(4):390-397. doi:10.1097/ICO.0b013e318030df5a
8. Mazzotta C, Traversi C, Baiocchi S, et al. Corneal healing after riboflavin ultraviolet-A collagen cross-linking determined by confocal laser scanning microscopy in vivo: early and late modifications. *Am J Ophthalmol*. 2008;146(4):527-533. doi:10.1016/j.ajo.2008.05.042
9. Kim TI, Tchah H, Lee SA, Sung K, Cho BJ, Kook MS. Apoptosis in keratocytes caused by mitomycin C. *Invest Ophthalmol Vis Sci*. 2003;44(5):1912-1917. doi:10.1167/iovs.02-0977
10. Netto MV, Mohan RR, Sinha S, Sharma A, Gupta PC, Wilson SE. Effect of prophylactic and therapeutic mitomycin C on corneal apoptosis, cellular proliferation, haze, and long-term keratocyte density in rabbits. *J Refract Surg*. 2006;22(6):562-574. doi:10.3928/1081-597X-20060601-08
11. Kim TI, Pak JH, Lee SY, Tchah H. Mitomycin C-induced reduction of keratocytes and fibroblasts after photorefractive keratectomy. *Invest Ophthalmol Vis Sci*. 2004;45(9):2978-2984. doi:10.1167/iovs.04-0070
12. Sadeghi HM, Seitz B, Hayashi S, LaBree L, McDonnell PJ. In vitro effects of mitomycin-C on human keratocytes. *J Refract Surg*. 1998;14(5):534-540.
13. Wollensak G, Spoerl E, Seiler T. Riboflavin/ultraviolet-a-induced collagen crosslinking for the treatment of keratoconus. *Am J Ophthalmol*. 2003;135(5):620-627. doi:10.1016/S0002-9394(02)02220-1
14. Rodrigues EB, Johanson M, Penha FM. Anterior segment tomography with the cirrus optical coherence tomography. *J Ophthalmol*. 2012;2012:806989. doi:10.1155/2012/806989
15. Awwad ST, Fattah MA, Shokr M, Dhaini AR. Automated detection of the stromal demarcation line using optical coherence tomography in keratoconus eyes after corneal cross-linking. *Am J Ophthalmol*. 2019;199:177-183. doi:10.1016/j.ajo.2018.11.017
16. Dhaini AR, Abdul Fattah M, El-Oud SM, Awwad ST. Automated detection and measurement of corneal haze and demarcation line in spectral-domain optical coherence tomography images. *IEEE Access*. 2018;6:3977-3991. doi:10.1109/ACCESS.2018.2789526
17. Antonios R, Fattah MA, Maalouf F, Abiad B, Awwad ST. Central corneal thickness after cross-linking using high-definition optical coherence tomography, ultrasound, and dual Scheimpflug tomography: a comparative study over one year. *Am J Ophthalmol*. 2016;167:38-47. doi:10.1016/j.ajo.2016.04.004
18. Raiskup F, Theuring A, Pillunat LE, Spoerl E. Corneal collagen crosslinking with riboflavin and ultraviolet-A light in pro-

gressive keratoconus: ten-year results. *J Cataract Refract Surg*. 2015;41(1):41-46. doi:10.1016/j.jcrs.2014.09.033

19. Shafik Shaheen M, Lolah MM, Piñero DP. The 7-year outcomes of epithelium-off corneal cross-linking in progressive keratoconus. *J Refract Surg*. 2018;34(3):181-186. doi:10.3928/1081597X-20180123-01
20. Caporossi A, Mazzotta C, Baiocchi S, Caporossi T. Long-term results of riboflavin ultraviolet a corneal collagen cross-linking for keratoconus in Italy: the Siena Eye Cross Study. *Am J Ophthalmol*. 2010;149(4):585-593. doi:10.1016/j.ajo.2009.10.021
21. Maurice DM. The structure and transparency of the cornea. *J Physiol*. 1957;136(2):263-286. doi:10.1113/jphysiol.1957.sp005758
22. Jester JV, Moller-Pedersen T, Huang J, et al. The cellular basis of corneal transparency: evidence for 'corneal crystallins'. *J Cell Sci*. 1999;112(Pt 5):613-622.
23. Raiskup-Wolf F, Hoyer A, Spoerl E, Pillunat LE. Collagen crosslinking with riboflavin and ultraviolet-A light in keratoconus: long-term results. *J Cataract Refract Surg*. 2008;34(5):796-801. doi:10.1016/j.jcrs.2007.12.039
24. Tomás-Juan J, Murueta-Goyena Larrañaga A, Hanneken L. Corneal regeneration after photorefractive keratectomy: a review. *J Optom*. 2015;8(3):149-169. doi:10.1016/j.optom.2014.09.001
25. Marino GK, Santhiago MR, Torricelli AA, Santhanam A, Wilson SE. Corneal molecular and cellular biology for the refractive surgeon: the critical role of the epithelial basement membrane. *J Refract Surg*. 2016;32(2):118-125. doi:10.3928/1081597X-20160105-02
26. Wilson SE, Mohan RR, Hong JW, Lee JS, Choi R, Mohan RR. The wound healing response after laser in situ keratomileusis and photorefractive keratectomy: elusive control of biological variability and effect on custom laser vision correction. *Arch Ophthalmol*. 2001;119(6):889-896. doi:10.1001/archopht.119.6.889
27. Wilson SE, Chaurasia SS, Medeiros FW. Apoptosis in the initiation, modulation and termination of the corneal wound healing response. *Exp Eye Res*. 2007;85(3):305-311. doi:10.1016/j.exer.2007.06.009
28. Wilson SE. Corneal myofibroblast biology and pathobiology: generation, persistence, and transparency. *Exp Eye Res*. 2012;99:78-88. doi:10.1016/j.exer.2012.03.018
29. Lai YH, Wang HZ, Lin CP, Chang SJ. Mitomycin C alters corneal stromal wound healing and corneal haze in rabbits after argon-fluoride excimer laser photorefractive keratectomy. *J Ocul Pharmacol Ther*. 2004;20(2):129-138. doi:10.1089/108076804773710803
30. Coelho LM, Sieiro RO. Mitomycin C 0.02 and 0.002% efficacy in preventing haze after photorefractive keratectomy. *Int Ophthalmol*. 2019;39(2):341-345. doi:10.1007/s10792-017-0817-7
31. Gambato C, Miotto S, Cortese M, Ghirlando A, Lazzarini D, Midena E. Mitomycin C-assisted photorefractive keratectomy in high myopia: a long-term safety study. *Cornea*. 2011;30(6):641-645. doi:10.1097/ICO.0b013e31820123c8
32. Jester JV, Nien CJ, Vasiliou V, Brown DJ. Quiescent keratocytes fail to repair MMC induced DNA damage leading to the long-term inhibition of myofibroblast differentiation and wound healing. *Mol Vis*. 2012;18:1828-1839.
33. Salomao MQ, Wilson SE. Corneal molecular and cellular biology update for the refractive surgeon. *J Refract Surg*. 2009;25(5):459-466. doi:10.3928/1081597X-20090422-09
34. Hafezi F, Koller T, Vinciguerra P, Seiler T. Marked remodelling of the anterior corneal surface following collagen cross-linking with riboflavin and UVA. *Br J Ophthalmol*. 2011;95(8):1171-1172. doi:10.1136/bjo.2010.184978
35. Torres Netto EA, Al-Otaibi WM, Hafezi NL, et al. Prevalence of keratoconus in paediatric patients in Riyadh, Saudi Arabia. *Br J Ophthalmol*. 2018;102(10):1436-1441. doi:10.1136/bjophthalmol-2017-311391
36. Tabbara KF, El-Sheikh HF, Sharara NA, Aabed B. Corneal haze among blue eyes and brown eyes after photorefractive keratectomy. *Ophthalmology*. 1999;106(11):2210-2215. doi:10.1016/S0161-6420(99)90507-9
37. Stojanovic A, Nitter TA. Correlation between ultraviolet radiation level and the incidence of late-onset corneal haze after photorefractive keratectomy. *J Cataract Refract Surg*. 2001;27(3):404-410. doi:10.1016/S0886-3350(00)00742-2

ORIGINAL ARTICLE

Customized Stromal Lenticule Implantation for Keratoconus

Farideh Doroodgar, MD; Mahmoud Jabbarvand, MD; Sana Niazi, MS; Farid Karimian, MD; Feizollah Niazi, MD; Azad Sanginabadi, MSc; Mohammad Ghoreishi, MD; Cyrus Alinia, MSc, PhD; Hassan Hashemi, MD; Jorge L. Alió, MD, PhD

ABSTRACT

PURPOSE: To investigate the potential benefit of keratoconus surgery using customized corneal stromal donor lenticules obtained from myopic small incision lenticule extraction (SMILE) surgery by femtosecond laser.

METHODS: In this prospective, consecutive, non-comparative series of cases, 22 lenticules were obtained from 22 myopic patients who had SMILE with a lenticule central thickness of greater than 110 µm. The lenticules were implanted in 22 eyes with advanced keratoconus. The lenticules were customized for the purpose of the implantation with either a simple necklace or necklace-with-ring shape (compound form) depending on the corneal thickness and corneal topography configuration of the implanted keratoconic eyes. The lenticules were implanted into a 9.5-mm corneal lamellar pocket created by the femtosecond laser. Changes in densitometry, thickness, confocal microscopy, corrected distance visual acuity (CDVA), and endothelial cell density were investigated.

RESULTS: Intrastromal lenticule implantation was successfully performed in all cases without any complication. Corneal thickness showed a mean enhancement of 100.4 µm at the thinnest point. On biomicroscopy, all corneas were clear at 1 year postoperatively and there was a significant improvement in corneal densitometry during the entire follow-up period. Confocal biomicroscopy showed collagen reactivation without any inflammatory features caused by the implanted fresh lenticules. CDVA improved from 0.70 to 0.49 logMAR (P = .001) and keratometry decreased from 54.68 ± 2.77 to 51.95 ± 2.21 diopters (P = .006).

CONCLUSIONS: Customized SMILE lenticule implantation by femtosecond laser proved to be feasible, resulting in an improvement in vision, topography, and refraction in the implanted eyes.

[*J Refract Surg*. 2020;36(12):786-794.]

Keratoconus is the most common corneal ectasia, characterized by bulging, thinning, and distortion of the cornea causing visual decay due to the induction of irregular astigmatism.[1] Apart from spectacles, contact lenses, phakic lenses, and intracorneal ring segments (ICRS) implantation, visual restoration of advanced corneal ectasia frequently requires lamellar or penetrating corneal transplantation techniques, which present different disadvantages (eg, graft failure and rejection) and, frequently, reduced vision due to high postoperative surgically induced astigmatism.[1,2] Additionally, in many areas of the world there is limited access to donor corneal tissue, with approximately 53% of the total population worldwide having no access to corneal transplantation.[3] On the other hand, in progressive keratoconus cases with thin cornea (< 400

From Negah Specialty Ophthalmic Research Center (FD) and the Department of Ophthalmology (SN, FK, FN, HH), Shahid Beheshti University of Medical Sciences, Tehran, Iran (FD); the Department of Ophthalmology (FD, MJ) and Farabi Eye Hospital (MJ, HH), Tehran University of Medical Science, Tehran, Iran; the Department of Optometry, Iran University of Medical Sciences, Tehran, Iran (AS); Isfahan Ophthalmology Research Center, Isfahan University of Medical Sciences and Health Services, Isfahan, Iran (MG); the Department of Public Health, Urmia University of Medical Sciences, Urmia, West Azerbaijan, Iran (CA); Noor Ophthalmology Research Center, Noor Eye Hospital, Tehran, Iran (HH); the Division of Ophthalmology, Universidad Miguel Hernández, Alicante, Spain (JLA); and Vissum Miranza Alicante, Alicante, Spain (JLA).

Submitted: July 11, 2020; Accepted: October 5, 2020

Supported in part by the Red Temática de Investigación Cooperativa en Salud (RETICS), (reference number RD16/0008/0012), financed by the Instituto Carlos III–General Subdirection of Networks and Cooperative Investigation Centers (R&D&I National Plan 2008-2011), and the European Regional Development Fund (Fondo Europeo de Desarrollo Regional FEDER) (Grant from Jorge L. Alió, PI).

The authors have no financial or proprietary interest in the materials presented herein.

Correspondence: Azad Sanginabadi, MSc, Department of Optometry, Iran University of Medical Sciences, No. 3 Ketabi Street, Shariati Avenue, Tehran 1544914599, Iran. Email: sanginabadiazad@yahoo.com

doi:10.3928/1081597X-20201005-01

Reprinted with permission from SLACK Incorporated, Doroodgar F, Jabbarvand M, Niazi S, Karimian F, Niazi F, Sanginabadi A, Ghoreishi M, Alinia C, Hashemi H, Alió JL. Customized Stromal Lenticule Implantation for Keratoconus. *J Refract Surg*. 2020;36(12):786-794. doi:10.3928/1081597X-20201005-01

µm), in which even to perform corneal cross-linking (CXL) is a dilemma, a minimally invasive modality of treatment seems to also be required.[2,4]

Small incision lenticule extraction (SMILE) is an effective femtosecond laser surgery to correct myopia and astigmatism.[5,6] In SMILE, an intrastromal lenticule is created using the femtosecond laser, which is dissected and extracted through a 2- to 5-mm corneal incision.[7] The accomplished myopic correction depends on both the diameter and the thickness of the lenticule, the center of which is thicker than its periphery. It has been suggested in some experimental and clinical studies that the extracted refractive lenticule may be preserved and subsequently reimplanted into the same eye,[8] or be used as autologous or allograft donor tissue in other eyes to treat presbyopia,[9-11] hyperopia,[12] or aphakia,[13] various forms of keratectasia,[14,15] and some corneal dystrophies.[16] The size and shape of the lenticule might even be customized to better adapt to atypical corneal topographies.[17,18] One noteworthy potential advantage of using any SMILE lenticules for such purposes is that the lenticule thickness is harboring a refractive value that is defined by the amount of myopia corrected by the procedure.

The purpose of the current study was to evaluate the use of customized SMILE lenticule implantation as a new surgical approach in corneas with advanced keratoconus.

PATIENTS AND METHODS

PATIENTS

Twenty-two eyes of 22 patients (14 women and 8 men) aged 33 to 42 years with advanced keratoconus with an indication for corneal graft were prospectively selected and recruited for the study from June 2018 to January 2020 by a single surgeon (FD) at the Department of Ophthalmology, Negah Eye Hospital, Tehran, Iran. All patients were properly informed about the methods and risks of the operation and signed an informed consent form before the surgery. The surgical procedure was offered in all cases as a potential alternative that was less invasive than corneal graft. The procedure was approved by the medical ethics committee of Shahid Beheshti University of Medical Sciences and adhered to the tenets of the Declaration of Helsinki.

Tissue donors were chosen from patients who had SMILE with a spherical equivalent (SE) of greater than -8.50 diopters (D), guaranteeing a donor lenticule central thickness of greater than 100 µm.

PATIENT SELECTION CRITERIA

Recipients included in this study all had stage IV keratoconus or greater, as per the Red Temática de Investigación Cooperativa en Salud (RETICS) and CDVA classification[19,20] (mean keratometry: 53.00 D or greater, CDVA: worse than 20/50). All patients were 33 years or older without any immunosuppressive therapy or immunodeficiency, serologic evidence of infection with hepatitis B virus (HBV), HIV, hepatitis C virus (HCV), breast feeding, or pregnancy.

Donors were older than 20 years and a SE of -8.50 D or greater with a cylinder of no more than -1.00 D, corrected distance visual acuity (CDVA) of better than 20/25, stable refractive error (maximum SE variation for twice in a year: ±0.25), and stability was evaluated by the Pentacam (Oculus Optikgeräte GmbH).[21,22] All donors completed a blood test analytical evaluation for blood glucose, HbsAg (HBV), HcvAg (HCV), HIV I and II, and *Treponema pallidum* particle agglutination assay.

Excluded were individuals with CDVA worse than 20/160 in the contralateral eye, active inflammatory eye diseases, glaucoma, retinal diseases, cataract, any previous ocular surgery, significant central scarring, and previous CXL. The patients should not have any history of cognitive impairments or dementia, which might affect their capacity to take part in the informed consent process and follow-up controls. Pregnant patients were also excluded from the study.

For donors, any type of corneal disease, glaucoma, angle kappa of greater than 0.4 mm, any immunosuppressive therapy or immunodeficiency, serologic evidence of infection with HBV, HIV, or HCV, breast feeding, and pregnancy were reasons for exclusion.

SURGICAL TECHNIQUE

The selected donor patients with high myopia were scheduled for SMILE using the VisuMax femtosecond laser (Carl Zeiss Meditec). On the same day, the recipient patients with keratoconus were scheduled for surgery.

Patients were paired before surgery so that more patients with high myopia had simultaneous surgery with their counterpart (patients with advanced keratoconus). All customized SMILE lenticule implantation surgeries were performed by the same surgeon (FD) under topical anesthesia following already described protocols[6,23] and using the VisuMax femtosecond laser.

The predicted final refraction was zero with an anticipated residual stromal thickness of greater than 250 µm. It is expected that total intact stromal thickness becomes 310 µm postoperatively (**Table 1**).

The lenticule was removed from the donor eye with advanced lenticule forceps (Geuder GmbH) and handled with advanced Chansue dissectors. Then it was shaped into necklace and ring 120° forms (**Figure 1**) by biopsy punches from 3 to 5 mm (Kai Industries Co., Ltd). A punching Kai biopsy punch with a piston

TABLE 1
Laser Treatment Parameters

Parameter	Value
Recipient corneas	
Pocket depth	160 to 300 µm (100 µm away from the endothelium) depends on thinnest point of pachymetry
Pocket diameter	7.4 to 8.9 mm
Pulse energy	300 nJ
Energy offset (1 offset = 5 nJ)	60
Donor cornea	
Cap data	
Cap depth	115 to 140 µm (depends on pachymetry)
Diameter	7.7 µm (1.2 more than optical zone)
Side cut angle	900 degrees
Incision position	120 degrees
Incision angle	520 degrees
Incision width	3.50 mm
Spot distance	Lenticule and cap cuts: 4 µm; lenticule and cap side cuts: 2 µm
Lenticule data	
Transition zone	0.10 mm degrees
Spherical zone	-8.50 to-11.00 diopters
Optical zone	5.75 to 7 mm
Central thickness	The thinnest point of Pentacam pachymetry
Punch size for reshaping lenticule	3 to 5 mm
Shape of lenticule	Depends on pachymetry, mean keratometry, and cone location. In highly asymmetric cornea: necklace form

allows for biopsy and precision cutting of the tissue with excellent accuracy and minimal tissue damage, available in different sizes from 1 to 8 mm (with a 0.50-mm step).

The cut lenticule was first washed with 1% antibiotic/antimycotic (Sigma) liquid 100 mL (Gibco) and then with balanced salt solution immersed in 0.06% Trypan Blue ophthalmic solution (VisionBlue) for 30 seconds and then washed, coloring the lenticule for a precise implantation in the recipient eye.

The recipient patients were selected for the procedure according to the nomogram shown in **Figure A** (available in the online version of this article). To achieve the intended pocket to insert the stromal lenticule, the outer and inner diameters were 0 and 8.5 mm, respectively. The center of the donor lenticules was marked. In recipients (keratoconic eyes), the center of the pupil and between the corneal and pupillary center in large angle kappa were considered.

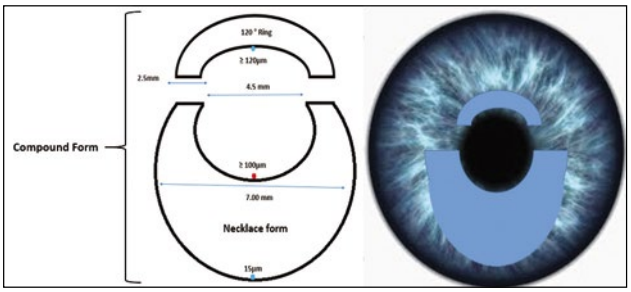

Figure 1. Form of lenticule used for reimplantation

A 9.5-mm stromal pocket was made with a 500-kHz VisuMax femtosecond laser system and two small incisions (2 to 3 mm) were created at locations 150° superotemporal and 330° inferonasal for the right eye of a patient for a right-handed surgeon and vice versa. The upper interface was separated in the normal fashion, then the prepared donor lenticule was inserted into the space provided by the upper interface through the small incision, using a Kelman forceps holding the donor lenticule lengthwise along a diameter. The donor lenticule was distended until flat and centered on the corneal vertex coincident with the axis of fixation. The insertion was such that the central edge of the lenticule was aligned with the pupillary edge of the recipient cornea (**Figure 1**). In cases of compound form application, we inserted the necklace form part first and then the ring 120° part was placed. The orientation of the lenticule was maintained throughout, with the refractive cut anterior and the planar cut posterior. A preserved lenticule was prepared in every case for eventual use in case of complications. All of the lenticules were implanted without any wrinkling or folding. As a midterm corneal storage medium, Optisol is a feasible and useful (for 14 days) method for storage of the SMILE-derived lenticules.[24] If the donor's lenticule was not used within 4 hours, we could seal it in the Optisol medium of the Central Eye Bank of Iran.[25] However, in this study we used fresh lenticules successfully.

Postoperatively, ofloxacin 0.1% was used four times a day together with prednisolone acetate 1% six times a day for 2 weeks. Topical corticosteroid was tapered one drop less per day each subsequent week and stopped after 2 months. Starting at 2 months, fluorometholone drops were used once a day for 2 weeks followed by once on alternate days for 2 months. Patients influenced by vernal or allergic conjunctivitis were kept circumstantially with the past antiallergic drug

TABLE 2
Visual Acuity and Refraction for Preoperative (Baseline) and Postoperative Follow-up (1, 6, and 12 Months)

Parameter	Mean ± SD (Range)				*P*
	Baseline	1 Month	6 Month	1 Year	
Mean K (D)	54.68 ± 2.77 (50.00 to 59.00)	53.04 ± 2.88 (47.00 to 57.00)	52.50 ± 2.58 (47.00 to 56.00)	51.95 ± 2.21 (47.00 to 55.00)	.006
Thickness (mm) (thinnest point)	383.64 ± 42.83 (270 to 455)	489.68 ± 41.54 (395 to 542)	477.18 ± 42.21 (380 to 526)	475.55 ± 41.32 (380 to 521)	.001
Sphere (D)	-6.17 ± 4.56[a] (-13.00 to -5.00)	-6.84 ± 1.60 (-9.00 to -4.00)	-6.34 ± 1.90 (-10.00 to -4.00)	-5.89 ± 1.63 (-10.00 to -4.00)	.702
Cylinder (D)	-5.99 ± 3.99[a] (- 11.00 to -5.00)	-5.75 ± 1.15 (-9.00 to -4.00)	-5.48 ± 1.29 (-9.00 to -3.50)	-5.00 ± 0.96 (-6.00 to -3.50)	.497
CDVA (logMAR)	0.70 ± 0.17 (0.4 to 1)	0.61 ± 0.12 (0.4 to 0.8)	0.57 ± 0.11 (0.4 to 0.8)	0.49 ± 0.12 (0.4 to 0.8)	.001

SD = standard deviation; K = keratometry; D = diopters; CDVA = corrected distance visual acuity
[a]Six eyes with severe keratoconus were not included due to undetectable refraction.

used by the patient as required. The patients were followed up at 1 day, 2 weeks, and 1, 6, and 12 months postoperatively.

Postoperative Follow-up

Postoperative manifest refraction and assessment of CDVA with Snellen chart, slit-lamp biomicroscopy, intraocular pressure, funduscopy, corneal topography, and endothelial cell count by specular microscopy (Nidek) were compared with preoperative measurements. In addition, densitometry (Pentacam), Fourier-domain anterior segment optical coherence tomography (AS-OCT) (CASIA2), and corneal confocal biomicroscopy with Confoscan 4 (Nidek Technologies) were considered in postoperative evaluations.

Statistical Analysis

We used a parametric one-way repeated measure analysis of variance test to assess the statistically significant changes in the outcomes over time with a *P* value of less than .05 significance level (the sample size was enough and the data illustrated a normal distribution). We used the Stata Version 15 statistical program (Stata Corp) for the statistical analysis.

The main outcome measures of the study were improvement in CDVA, corneal thickness, and corneal transparency as evaluated by Pentacam pachymetry, densitometry, and slit-lamp biomicroscopy. Secondary outcome measures were the refractive improvement from preoperative refraction, keratometry change, and uncorrected distance visual acuity.

RESULTS

The 22 patients had a mean age of 36.13 years (range: 33 to 41 years). The study sample was composed of 13 women and 9 men. None of these eyes had previous CXL or any other ophthalmic intervention. All surgeries were accomplished with no intraoperative complications. All patients completed the 1-year follow-up period. The outcomes are summarized in **Table 2**.

Visual Acuity

All visual parameters had general improvement (**Table 2**), including a mean CDVA improvement from 0.70 logMAR (range: 0.4 to 1 logMAR) to 0.49 logMAR (range: 0.3 to 0.7 logMAR) (P = .001). Initially, vision was negatively affected in the first week after surgery due to a mild graft edema, visible at the slit-lamp examination. CDVA was increased by one or more line in 10 eyes (45%) at 6 months. At 1 year, CDVA increased by one or more line in 15 eyes (68.18%) and there was no reduction in CDVA compared to preoperatively and previous follow-up periods (**Table 2**).

Manifest Refraction

Refractive sphere was not significantly improved, with a mean value of -6.17 D (range: -5.00 to -13.00 D) preoperatively and -5.89 D (range: -4.00 to -10.00 D) at 12 months after surgery (P = .702). Importantly, refraction was not measurable in 6 eyes before surgery due to high refractive irregularities, whereas it was measurable after surgery due to reduced corneal irregularity (**Figure BD**, available in the online version of this article). The refractive cylinder remained stable, showing only a mild, non-significant improvement (**Table 2**) from a preoperative mean value of -5.99 D (range: -5.00 to -10.00 D) to a 1-year postoperative mean value of -5.00 D (range: -3.50 to -7.00 D).

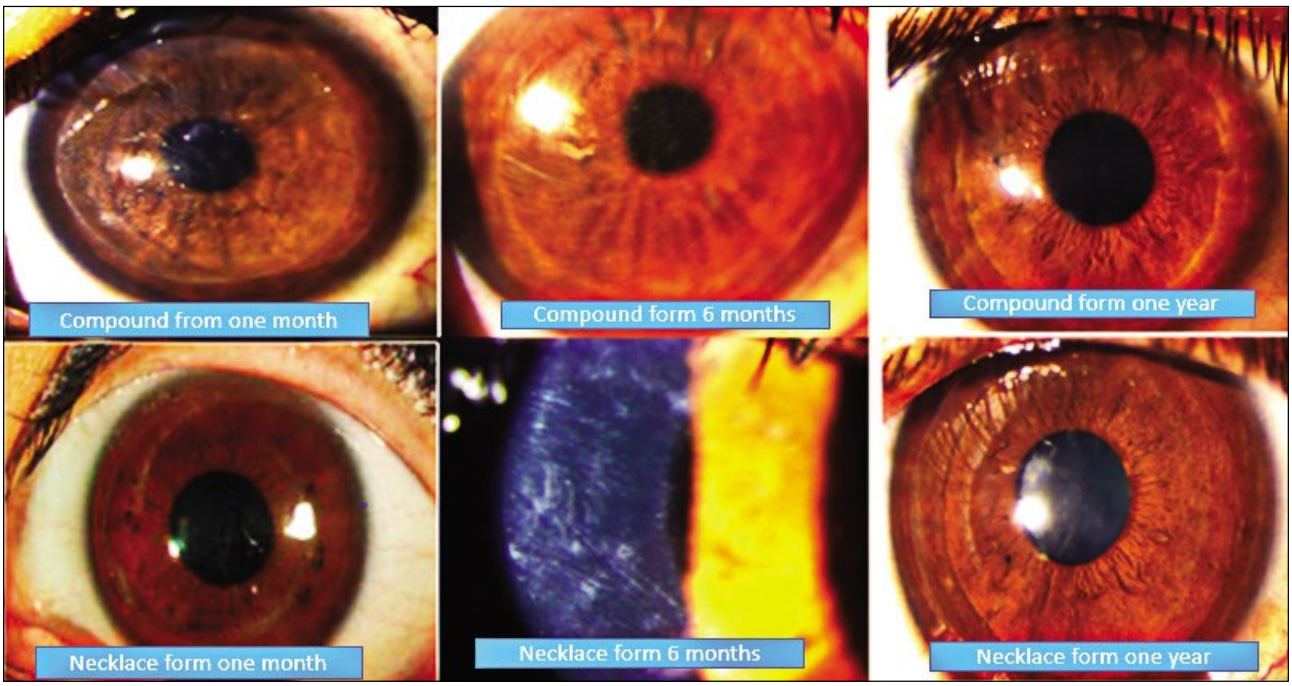

Figure 2. Slit-lamp biomicroscopic images at follow-up periods.

Slit-lamp Biomicroscopy

After surgery, no complications, especially inflammation or evidence of stromal rejection, were observed in any of the patients during the whole follow-up period. The day after surgery, edema was considerably reduced compared to immediately postoperatively, with no Descemet's folds. On the second postoperative day, lenticular edema appeared relatively equivalent to that of the surrounding stroma. Mild haziness was observed due to mild lenticular edema only in the first month and then resolved. This outcome has a good correlation with the initial decrease in visual acuity (**Figure 2**, top and bottom left).

Pentacam Topometric Parameters Densitometry

Table 2 lists the keratometric and refractive values over the 1-year postoperative period. The mean SE refraction reduced from -12.59 to -8.43 D and mean keratometry decreased 2.73 D from 54.68 ± 2.77 to 51.95 ± 2.21 D. In the topographic map, the anterior corneal surface remarkably flattened, especially at 4-mm centrally, where the minimum radius of curvature is located (**Figures BB-BD**); however, the posterior surface elevation also changed remarkably with a central bulge into the anterior chamber that was obvious on day 1 and was steady all during the follow-up period.

The Pentacam anterior elevation map with a 3-mm best-fit sphere revealed the mean radius of curvature of 6.44 ± 0.17 mm before and 6.79 ± 0.19 mm after the procedure, which translated into a 2.67 ± 1.60 D change in mean refractive power. The Pentacam posterior elevation map revealed the mean radius of curvature of 5.49 ± 0.16 mm before and 6.33 ± 0.16 mm after the procedure, which translated into a 1.13 ± 0.13 D change in refractive power. This equaled a 1.54 D total change in refractive power (using a refractive index of 1 for air, 1.336 for aqueous humor, and 1.377 for cornea).

There was a significant improvement in corneal clarity with a decreasing amount in results of corneal densitometry during the follow-up periods. An increase in corneal densitometry was observed only in the first month and then decreased (**Table A**, available in the online version of this article). We did not observe any induced haze after 1 year.

AS-OCT

Corneal thickness estimated at different points by AS-OCT confirmed the outcomes observed with topography (mean preoperative value: 383.64 mm; range: 270 to 455 mm; 1 year after surgery: 475.55 mm; range: 380 to 521 mm) ($P > .01$) (**Figure BA**, **Table 2**). AS-OCT showed a clearly visible transplanted lenticule in the cornea, which was due to the hyperreflection of the implanted layer in the first month after surgery associated with the mild clinical haze (**Figure BA**, left). The lenticule provided a natural reflection equivalent to the surrounding stroma receptor, which confirms the consistency of the densitometry results by 6 months

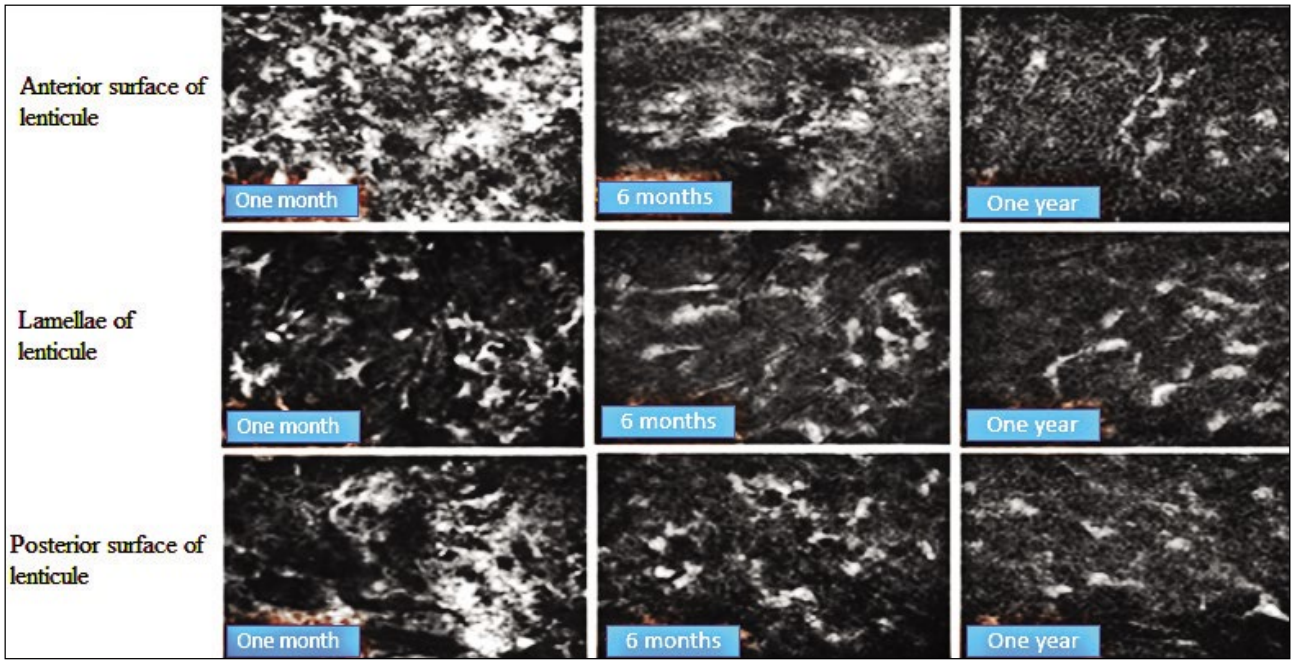

Figure 3. In vivo confocal microscopy assessment at 1 month, 6 months, and 1 year after surgery at the anterior and posterior surface of the lenticule, and at the lenticule plane.

(**Figure BA**). No areas of new collagen production were visible in any case.

Confocal Biomicroscopy

In the 6 months after surgery, a normal cell pattern was seen in the anterior and posterior stroma (**Figure 3**, middle column). Lenticule boundaries were readily visible as an overreflective linear band at the interface between the conventional anterior or posterior cell stroma and the donor stroma (**Figure 3**, first column). Stromal reflexes reduced at 6 months after surgery and corneal stromal nerves were observed in both stroma surrounding the lenticule and lenticule layers after 12 months. Finally, after 1 year, all patients showed early recellularization signs and few confined cells scattered throughout the lenticule (**Figure 3**, third column).

Other Clinical Outcomes

There were no significant changes in the intraocular pressure or endothelial cell density (EM 3000; Tomey) in preoperative data compared to the 6-month and 1-year postoperative results ($P > .05$).

The cornea remained clear throughout the 1-year postoperative period of observation defined in this study.

DISCUSSION

We evaluated the implantation of customized stromal donor lenticules derived from SMILE surgery for myopic patients in host corneas with advanced keratoconus. The outcomes demonstrated the potential of this surgical technique for stromal volume restoration.

This study reports the 1-year outcomes of keratoconus surgery using the customized stromal lenticule implantation technique. Customized necklace SMILE implants were chosen to accomplish three goals: to increase the corneal thickness, to reduce the keratometric values, and to increase regularity of the cornea in case of inferior steepening (the predominant feature of keratoconus) (**Figure A**, the nomogram). For these purposes, we decided to customize the shape of the lenticules. On the other hand, the necklace could have similar effects to ICRS implantation and cause central corneal flattening. Furthermore, implantation of a thicker lenticule (120 µm or greater) in the upper part had a compensatory flattening effect on the center of the cornea. Second, the crescent section is inserted so that the center of the crescent (red point in **Figure 1**) matched the pupil edge near the thinnest point of the cornea, which optimally increases the thickness and will induce the least myopic effects.

The most significant outcome of this study was the absence of complications that have constructively been shown in this 1-year prospective clinical investigation. These results are consistent with previous studies reported by Alió et al[26] and Alió del Barrio et al,[27,28] who used a large femtosecond pocket in advanced keratoconus without any complications. Good corneal transparency had been reported in their follow-up pe-

riod, and they introduced a new approach to improve the corneal stroma using stem cells associated with or without the implantation of acellular or repopulated corneal laminas.

In these studies, the authors demonstrated safety of the femtosecond laser corneal lamellar dissection, which was not influenced by preoperative keratometric, pachymetric, and topographic data.[29] These findings further confirm the safety of the creation of a femtosecond pocket in keratoconic corneas even in advanced stages. According to the ''success index'' of the previous studies[30] and the waveform analysis proposed by Ambrósio et al,[31] we predicted that the CDVA improved more when the biomechanical characteristics before lenticule implant biomechanical characteristics were worse. Thus, this procedure was done in patients with keratoconus having the worst CDVA before lenticule implantation. Such findings are in agreement with a previous study that determined the lack of secondary effects of tunnels or pockets created by the femtosecond laser for the implantation of ICRS in keratoconus.[29,32]

Although the corrective outcome of corneal refraction is directly proportional to the thickness of the tissue or implant and inversely proportional to the diameter, there is not a universal consensus about the power of the donor lenticule and the amount of posterior curvature flattening and anterior curvature steepening applied by each donor lenticule.[33] More recently, the concepts of stromal healing, epithelial thickness alterations, and compensatory processes have evolved to show that the implanted refractive power alone does not make a refractive alteration. The more critical factors are the overall tissue compensatory effects and the stromal depth, the diameter of the femtosecond cutting, better integrity in SMILE instead through flap formation, and corneal biomechanical factors.[33-35] The tissue additive procedures might become more favorable to mild decentration than tissue ablation procedures.[34] However, we paid attention to centration.[33]

In this study, all eyes achieved a stable condition during the 1-year follow-up period and showed an improvement in CDVA (22 eyes) and uncorrected distance visual acuity (7 eyes) without progression of ectasia or any evidence of rejection. The corneal thickness increased at least 110 ± 11 µm at 6 months postoperatively, which was generally equivalent to the lenticular thickness (120 µm). Concerning corneal morphology, the anterior corneal surface showed statistically significant flattening after surgery and the total corneal refractive power decreased from 54.68 ± 2.77 to 51.95 ± 2.21 D.

As a midterm corneal storage medium, Optisol is a feasible and useful (for 14 days) method for storage of the SMILE-derived lenticules.[24] If the donor's lenticule was not used before 4 hours, we could seal it in the Optisol medium of the Central Eye Bank of Iran.[25] However, in this study we used fresh lenticules successfully with customized, compound (necklace form + ring 120°) and necklace shapes.

These results are in agreement with previous reports demonstrating that corneal curvature and corneal thickness could be reestablished to the preoperative state by lenticule reimplantation following the ReLEx system.[36] The main purpose of the current study was to evaluate changes in corneal thickness and transparency using densitometry by Pentacam HR after surgery. Most of the tomographic indexes improved and even index of height asymmetry (3.6) and central keratoconus index (1.04) reached normal and near normal limits, respectively. Nonetheless, none of the aforementioned indices should be used alone to identify ectasia absolutely and cutoff value of previous reports should be considered for interpretation. However, these two parameters (index of height asymmetry and central keratonus index), along with nearly all other metric indexes, identified good efficacy of the current method.[37] Densitometry results improved significantly in all zones of the cornea in the follow-up period of 12 months; the results have been supported by the slit-lamp biomicroscopic findings (**Table A**, **Figure 1**).

We observed that corneal thickness increased significantly and mean keratometry decreased approximately 2.00 D (**Table 2**, **Figure CB**, available in the online version of this article). During the follow-up period, densitometry decreased, which indicates more corneal clarity and better light scattering. In agreement with previous reports about densitometry after CXL or ICRS implantation, the highest values were illustrated in the anterior corneal layer after additive keratoplasty.[38] This method can bring the cornea closer to normal without complications and it is easy to perform. The availability of this method is one of the advantages that will provide a special place in the future for the treatment of corneal ectasia.

Pradhan et al[13] noted the lenticule reimplantation methodology is intended to restore corneal stromal volume, and the postoperative corneal thickness is equivalent to the preoperative estimated thickness of the lenticule in SMILE. Some findings indicate postoperative corneal thickness in the recipient may be estimated from the preoperative refractive condition of the donor.

Ectasia after LASIK and cases of progressive keratoconus with thin cornea (< 400 µm) create a powerful dilemma for topography-guided photorefractive keratotomy, ICRS implantation, and even CXL. Basically,

corneal allogenic intrastromal segments are biocompatible, more flexible than their synthetic counterparts, and less likely to extrude or cause corneal melting; can be cut to different thicknesses and shapes; and may be inserted at 50% corneal depth or even more superficially.[2,39] In addition to these advantages of corneal allogenic intrastromal segments, donor segments cut by the femtosecond laser have the advantages of excellent smoothing similar to the natural cornea and fitting so well that they are not easily identified after the implantation. These biologic homogenous regular implants (lenticules of SMILE) have been taken up in corneal restoration with broad use from minimal cases to the most severe cases.

The treatment of patients with hyperopia was also reported by Ganesh et al[10] with the implantation of a cryopreserved lenticule from myopic patients. The previous investigations illustrated the safety of reimplantation of cryopreserved lenticules[10,18] for LASIK or other corneal surgeries who would benefit more from the customized SMILE lenticule implantation method. Because volume and thickness are related to corneal resistance, we could also speculate that the corneal resistance should be also increased in the recipient keratoconic cornea postoperatively.[40]

Future studies on the shape of the customized SMILE lenticules for implantation to show the best efficiency for refractive error correction are necessary.

AUTHOR CONTRIBUTIONS

Study concept and design (FD, MJ, SN, FK, FN, AS, MG, CA, HH, JLA); data collection (FD, SN, FN, AS); analysis and interpretation of data (FD, MJ, SN, FN, AS, MG, CA, HH, JLA); writing the manuscript (FD, MJ, SN, FK, FN, AS, MG, CA); critical revision of the manuscript (FD, MJ, SN, AS, HH, JLA); statistical expertise (SN, FN, AS); administrative, technical, or material support (MJ); supervision (FD, MJ, FK, FN, MG, CA, HH, JLA)

REFERENCES

1. Arnalich-Montiel F, Alió Del Barrio JL, Alió JL. Corneal surgery in keratoconus: which type, which technique, which outcomes? *Eye Vis (Lond)*. 2016;3(1):2. doi:10.1186/s40662-016-0033-y
2. Pedrotti E, Chierego C, Bonacci E, et al. New treatments for keratoconus. *Int Ophthalmol*. 2020;40(7):1619-1623. doi:10.1007/s10792-020-01455-9
3. Gain P, Jullienne R, He Z, et al. Global survey of corneal transplantation and eye banking. *JAMA Ophthalmol*. 2016;134(2):167-173. doi:10.1001/jamaophthalmol.2015.4776
4. Sachdev GS, Sachdev R, Sachdev MS. Intra corneal ring segment implantation with lenticule assisted stromal augmentation for crosslinking in thin corneas. *Am J Ophthalmol Case Rep*. 2020;19:100726. doi:10.1016/j.ajoc.2020.100726
5. Shah R, Shah S, Sengupta S. Results of small incision lenticule extraction: all-in-one femtosecond laser refractive surgery. *J Cataract Refract Surg*. 2011;37(1):127-137. doi:10.1016/j.jcrs.2010.07.033
6. Sekundo W, Kunert KS, Blum M. Small incision corneal refractive surgery using the small incision lenticule extraction (SMILE) procedure for the correction of myopia and myopic astigmatism: results of a 6 month prospective study. *Br J Ophthalmol*. 2011;95(3):335-339. doi:10.1136/bjo.2009.174284
7. Pedersen IB, Ivarsen A, Hjortdal J. Three-year results of small incision lenticule extraction for high myopia: refractive outcomes and aberrations. *J Refract Surg*. 2015;31(11):719-724. doi:10.3928/1081597X-20150923-11
8. Moshirfar M, Shah TJ, Masud M, Linn SH, Ronquillo Y, Hoopes PC Sr. Surgical options for retreatment after small-incision lenticule extraction: advantages and disadvantages. *J Cataract Refract Surg*. 2018;44(11):1384-1389. doi:10.1016/j.jcrs.2018.07.047
9. Sun L, Yao P, Li M, Shen Y, Zhao J, Zhou X. The safety and predictability of implanting autologous lenticule obtained by SMILE for hyperopia. *J Refract Surg*. 2015;31(6):374-379. doi:10.3928/1081597X-20150521-03
10. Ganesh S, Brar S, Rao PA. Cryopreservation of extracted corneal lenticules after small incision lenticule extraction for potential use in human subjects. *Cornea*. 2014;33(12):1355-1362. doi:10.1097/ICO.0000000000000276
11. Mastropasqua L, Nubile M. Corneal thickening and central flattening induced by femtosecond laser hyperopic-shaped intrastromal lenticule implantation. *Int Ophthalmol*. 2017;37(4):893-904. doi:10.1007/s10792-016-0349-6
12. Jacob S, Kumar DA, Agarwal A, Agarwal A, Aravind R, Saijimol AI. Preliminary evidence of successful near vision enhancement with a new technique: PrEsbyopic Allogenic Refractive Lenticule (PEARL) corneal inlay using a SMILE lenticule. *J Refract Surg*. 2017;33(4):224-229. doi:10.3928/1081597X-20170111-03
13. Pradhan KR, Reinstein DZ, Carp GI, Archer TJ, Gobbe M, Gurung R. Femtosecond laser-assisted keyhole endokeratophakia: correction of hyperopia by implantation of an allogeneic lenticule obtained by SMILE from a myopic donor. *J Refract Surg*. 2013;29(11):777-782. doi:10.3928/1081597X-20131021-07
14. Ganesh S, Brar S. Femtosecond intrastromal lenticular implantation combined with accelerated collagen cross-linking for the treatment of keratoconus—initial clinical result in 6 eyes. *Cornea*. 2015;34(10):1331-1339. doi:10.1097/ICO.0000000000000539
15. Niazi S, Niknejad H, Niazi F, Doroodgar F, Sanginabadi A. Tissue-engineered recombinant human collagen-based corneal substitutes in end stage keratoconus. *Invest Ophthalmol Vis Sci*. 2019;60(9):5105.
16. Zhao J, Sun L, Shen Y, Tian M, Yao P, Zhou X. Using donor lenticules obtained through SMILE for an epikeratophakia technique combined with phototherapeutic keratectomy. *J Refract Surg*. 2016;32(12):840-845. doi:10.3928/1081597X-20160920-01
17. Angunawela RI, Riau AK, Chaurasia SS, Tan DT, Mehta JS. Refractive lenticule re-implantation after myopic ReLEx: a feasibility study of stromal restoration after refractive surgery in a rabbit model. *Invest Ophthalmol Vis Sci*. 2012;53(8):4975-4985. doi:10.1167/iovs.12-10170
18. Lim CH, Riau AK, Lwin NC, Chaurasia SS, Tan DT, Mehta JS. LASIK following small incision lenticule extraction (SMILE) lenticule re-implantation: a feasibility study of a novel method for treatment of presbyopia. *PLoS One*. 2013;8(12):e83046. doi:10.1371/journal.pone.0083046

19. Alió JL, Piñero DP, Alesón A, et al. Keratoconus-integrated characterization considering anterior corneal aberrations, internal astigmatism, and corneal biomechanics. *J Cataract Refract Surg*. 2011;37(3):552-568. doi:10.1016/j.jcrs.2010.10.046
20. Vega-Estrada A, Mimouni M, Espla E, Alió Del Barrio J, Alió JL. Corneal epithelial thickness intrasubject repeatability and its relation with visual limitation in keratoconus. *Am J Ophthalmol*. 2019;200:255-262. doi:10.1016/j.ajo.2019.01.015
21. Duncan JK, Belin MW, Borgstrom M. Assessing progression of keratoconus: novel tomographic determinants. *Eye Vis (Lond)*. 2016;3(1):6. doi:10.1186/s40662-016-0038-6
22. Doroodgar F, Niazi F, Sanginabadi A, et al. Comparative analysis of the visual performance after implantation of the toric implantable collamer lens in stable keratoconus: a 4-year follow-up after sequential procedure (CXL+TICL implantation). *BMJ Open Ophthalmol*. 2017;2(1):e000090. doi:10.1136/bmjophth-2017-000090
23. Riau AK, Angunawela RI, Chaurasia SS, Lee WS, Tan DT, Mehta JS. Early corneal wound healing and inflammatory responses after refractive lenticule extraction (ReLEx). *Invest Ophthalmol Vis Sci*. 2011;52(9):6213-6221. doi:10.1167/iovs.11-7439
24. Liang G, Wang L, Pan Z, Zhang F. Comparison of the different preservative methods for refractive lenticules following SMILE. *Curr Eye Res*. 2019;44(8):832-839. doi:10.1080/02713683.2019.1597890
25. Rezaei Kanavi M, Ghalenoee M, Chamani T, Javadi MA, Fazili N. Comparison of donor cornea storage in Optisol-GS and the Central Eye Bank of Iran (CEBI) medium. *Bina Journal of Ophthalmology*. 2015;20(4):374-379.
26. Alió JL, Alió Del Barrio JL, El Zarif M, et al. Regenerative surgery of the corneal stroma for advanced keratoconus: 1-year outcomes. *Am J Ophthalmol*. 2019;203:53-68. doi:10.1016/j.ajo.2019.02.009
27. Alió Del Barrio JL, El Zarif M, Azaar A, et al. Corneal stroma enhancement with decellularized stromal laminas with or without stem cell recellularization for advanced keratoconus. *Am J Ophthalmol*. 2018;186:47-58. doi:10.1016/j.ajo.2017.10.026
28. Alió Del Barrio JL, El Zarif M, de Miguel MP, et al. Cellular therapy with human autologous adipose-derived adult stem cells for advanced keratoconus. *Cornea*. 2017;36(8):952-960. doi:10.1097/ICO.0000000000001228
29. Alió JL, Piñero DP, Daxer A. Clinical outcomes after complete ring implantation in corneal ectasia using the femtosecond technology: a pilot study. *Ophthalmology*. 2011;118(7):1282-1290. doi:10.1016/j.ophtha.2010.12.012
30. Vega-Estrada A, Alió JL, Brenner LF, et al. Outcome analysis of intracorneal ring segments for the treatment of keratoconus based on visual, refractive, and aberrometric impairment. *Am J Ophthalmol*. 2013;155(3):575-584. doi:10.1016/j.ajo.2012.08.020
31. Ambrósio R Jr, Borges JS, Costa-Ferreira C, et al. Intrastromal corneal ring segments for keratoconus: results and correlation with preoperative corneal biomechanics. *Rev Bras Oftalmol*. 2012;71(2):89-99. doi:10.1590/S0034-72802012000200004
32. Daxer A. Biomechanics of corneal ring implants. *Cornea*. 2015;34(11):1493-1498. doi:10.1097/ICO.0000000000000591
33. Moshirfar M, Hopping GC, Somani AN, et al. Human allograft refractive lenticular implantation for high hyperopic correction. *J Cataract Refract Surg*. 2020;46(2):305-311. doi:10.1097/j.jcrs.0000000000000011
34. Riau AK, Liu YC, Yam GHF, Mehta JS. Stromal keratophakia: corneal inlay implantation. *Prog Retin Eye Res*. 2020;75:100780. doi:10.1016/j.preteyeres.2019.100780
35. Orlich C. Keratophakia with autograft aided by a femtosecond laser: one-year follow-up. *J Cataract Refract Surg*. 2018;44(2):245-247. doi:10.1016/j.jcrs.2017.11.010
36. Riau AK, Angunawela RI, Chaurasia SS, Lee WS, Tan DT, Mehta JS. Reversible femtosecond laser-assisted myopia correction: a non-human primate study of lenticule re-implantation after refractive lenticule extraction. *PLoS One*. 2013;8(6):e67058. doi:10.1371/journal.pone.0067058
37. Motlagh MN, Moshirfar M, Murri MS, et al. Pentacam® corneal tomography for screening of refractive surgery candidates: a review of the literature, Part I. *Med Hypothesis Discov Innov Ophthalmol*. 2019;8(3):177-203.
38. Sedaghat M-R, Momeni-Moghaddam H, Heravian J, et al. Scheimpflug corneal densitometry changes after the intrastromal corneal ring segment implantation. *Cornea*. 2020;39(6):761-768. doi:10.1097/ICO.0000000000002307
39. Jacob S, Patel SR, Agarwal A, Ramalingam A, Saijimol AI, Raj JM. Corneal allogenic intrastromal ring segments (CAIRS) combined with corneal cross-linking for keratoconus. *J Refract Surg*. 2018;34(5):296-303. doi:10.3928/1081597X-20180223-01
40. Hwang HS, Park SK, Kim MS. The biomechanical properties of the cornea and anterior segment parameters. *BMC Ophthalmol*. 2013;13(1):49. doi:10.1186/1471-2415-13-49

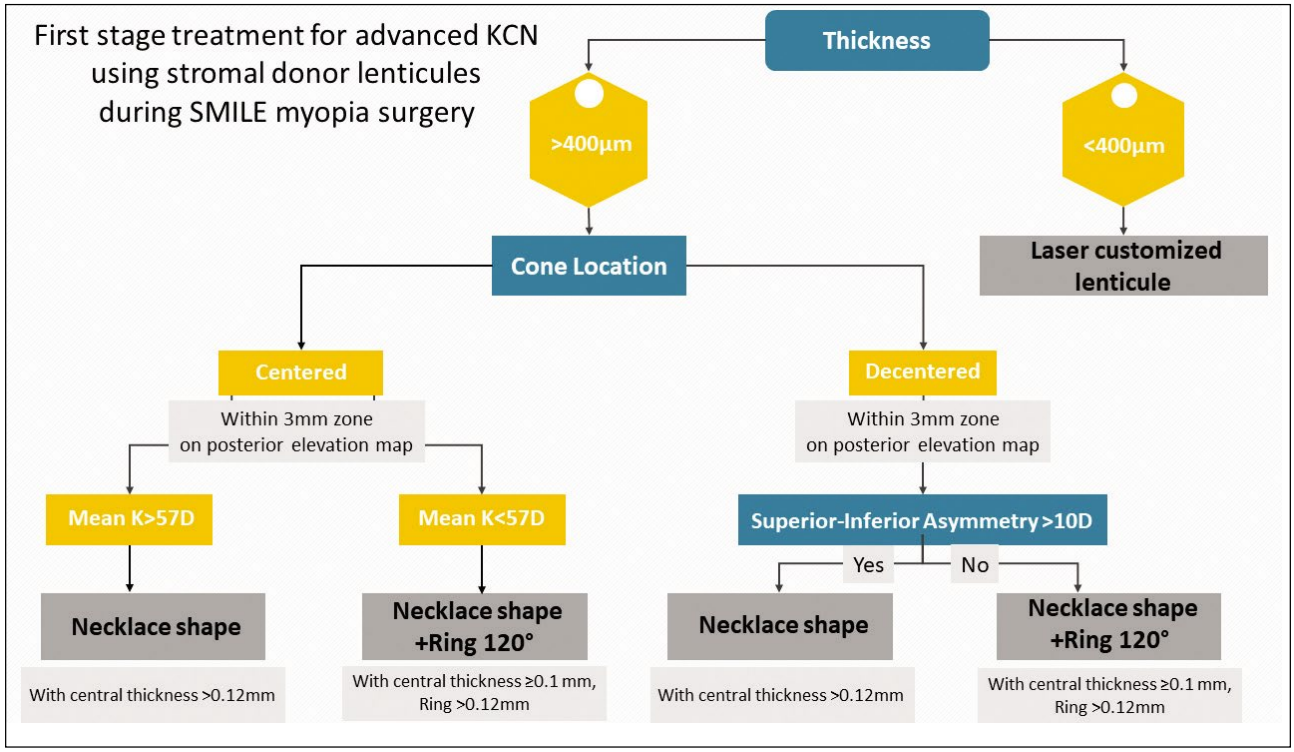

Figure A. Nomogram of first stage treatment for advanced keratoconus (KCN) using stromal donor lenticules during myopic small incision lenticule extraction (SMILE) surgery. D = diopters

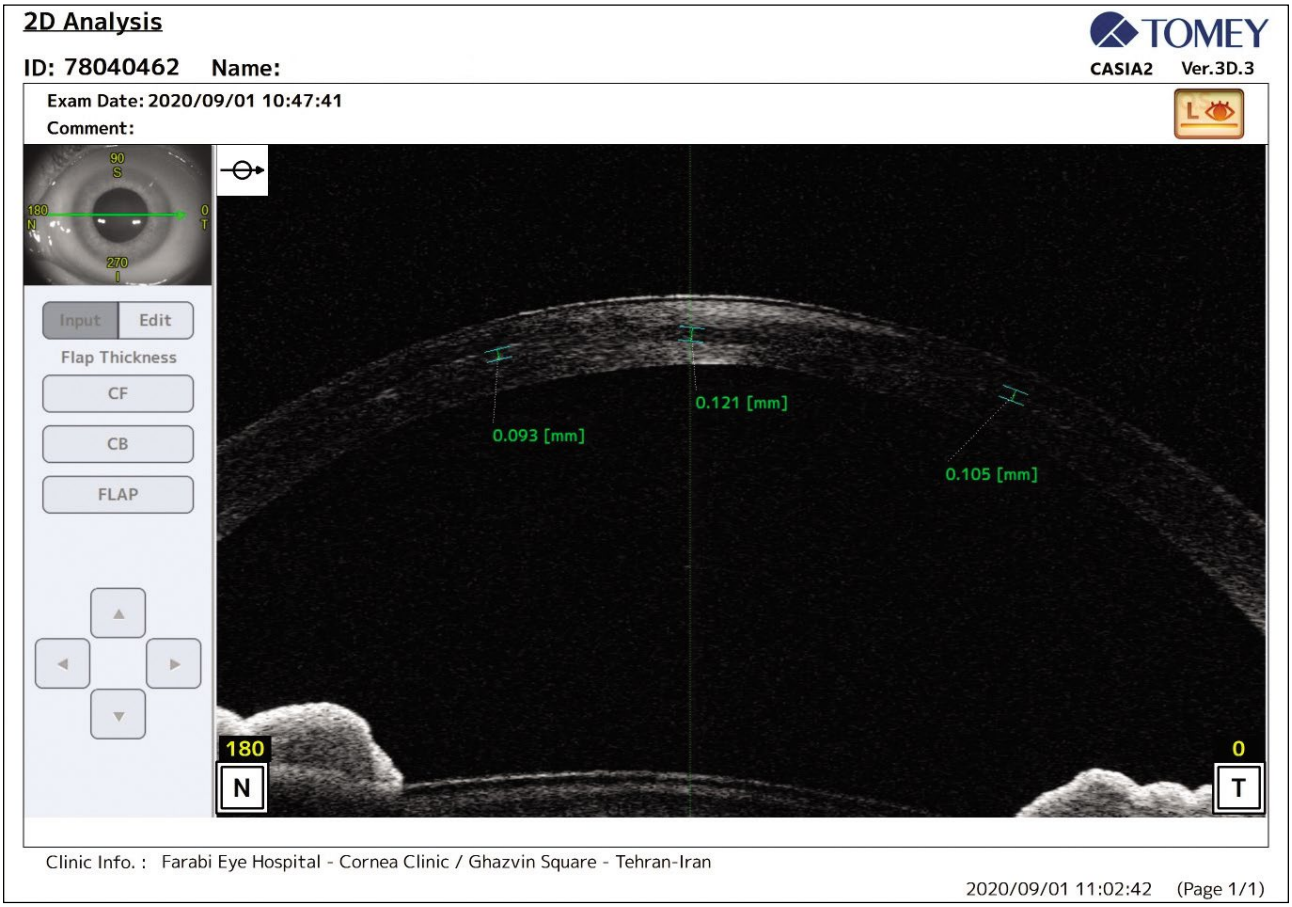

Figure BA. Case 1: anterior segment optical coherence tomography of the postoperative corneas at 1 year after lenticule reimplantation.

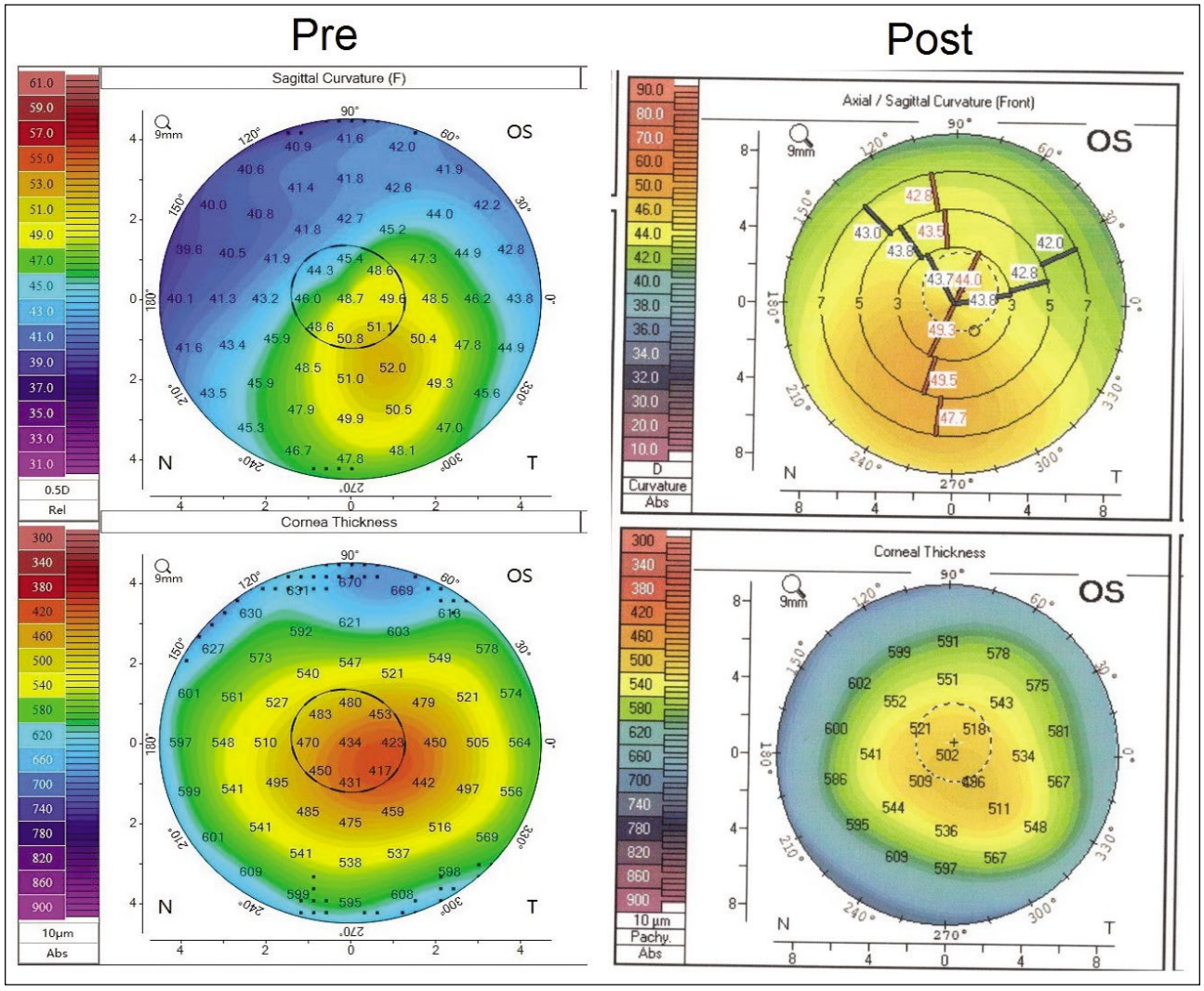

Figure BB. Case 1: total corneal refractive power and corneal thickness before and after reimplantation of a 110-µm lenticule.

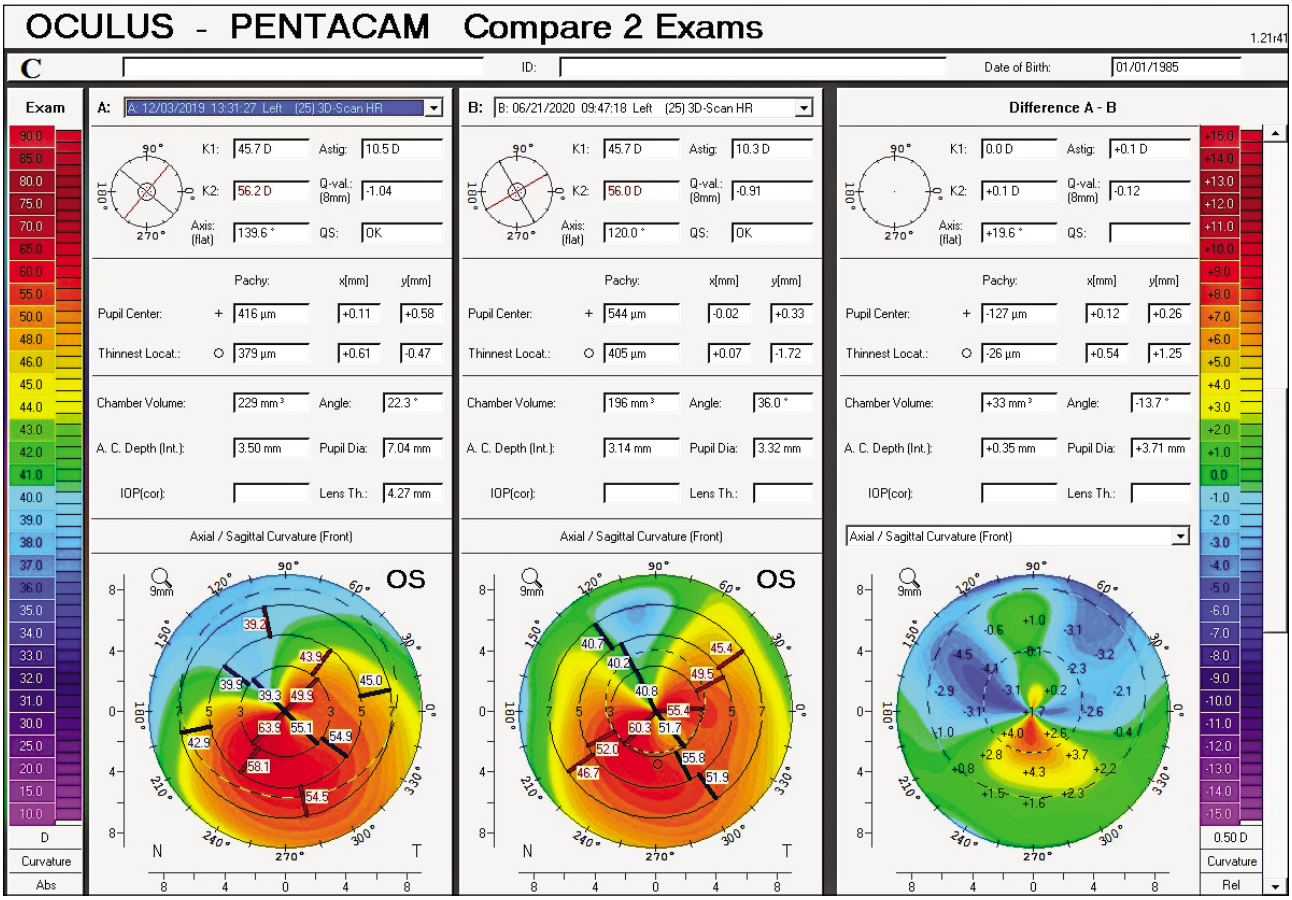

Figure BC. Case 2: difference map of another patient who received a necklace form of lenticule. Keratometry illustrated a 3.00 to 5.00 diopters (D) decrease in the 3-mm zone.

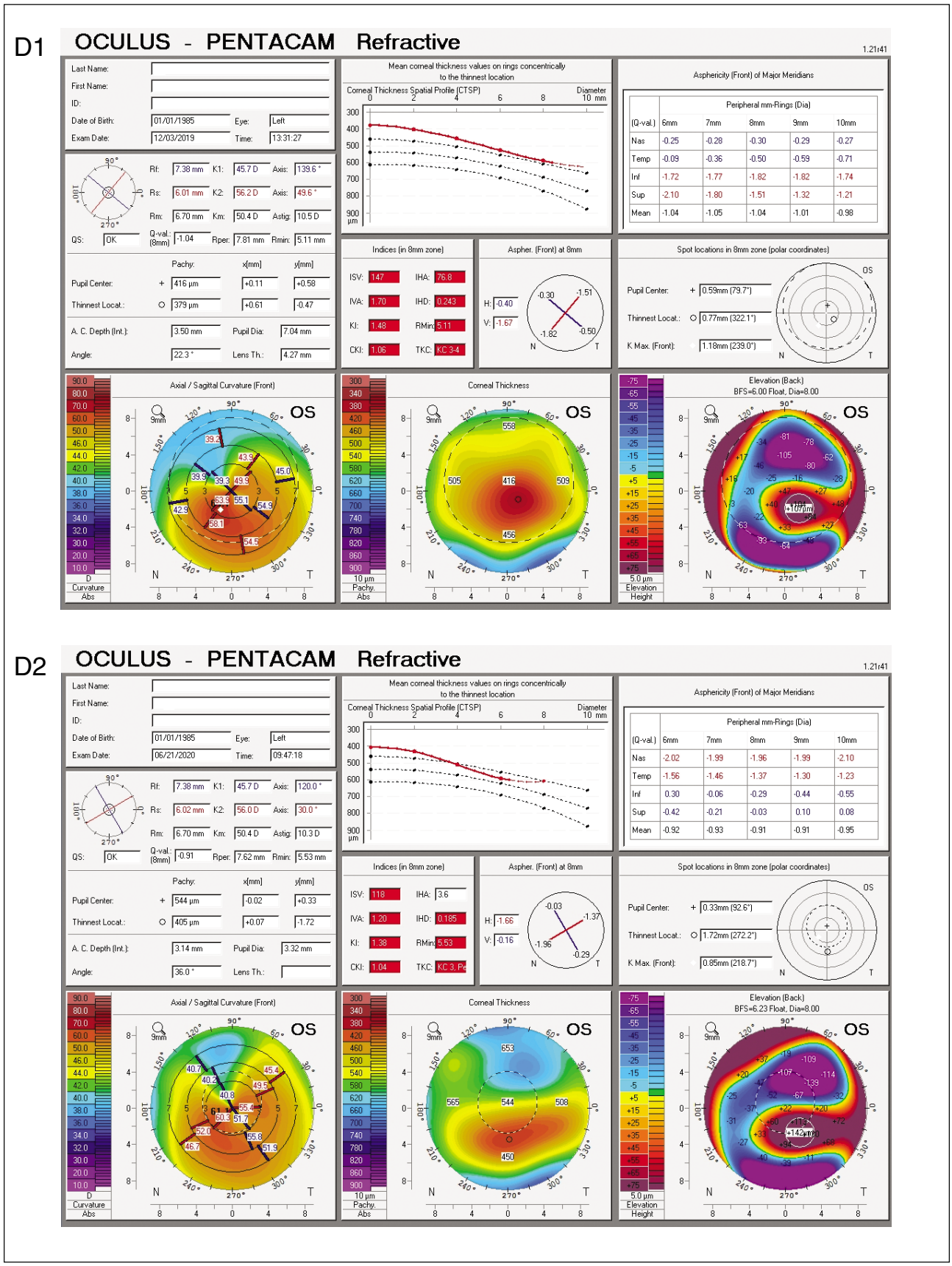

Figure BD. Case 2: comparison between (1) preoperative and (2) postoperative topometric indexes. D = diopters

TABLE A

Corneal Densitometry in All Zones and Layers Postoperatively[a]

		Mean (SD) (GSU)			
Layer	**Zone (mm)**	**1 Month**	**6 Months**	**1 Year**	***P***
Anterior 120 μm	0 to 2	25.82 (2.67)	22.41 (2.22)	21.95 (2.13)	.001
	2 to 6	21.41 (2.40)	19.59 (1.74)	19.59 (1.74)	.003
	6 to 10	16.59 (2.04)	14.82 (1.65)	14.00 (1.54)	.001
Center layer	0 to 2	18.95 (2.44)	16.82 (1.97)	16.09 (1.44)	.001
	2 to 6	18.95 (1.40)	16.78 (1.42)	16.59 (1.44)	.001
	6 to 10	16.91 (1.48)	15.00 (1.41)	15.18 (1.80)	.001
Posterior 60 μm	0 to 2	14.04 (2.06)	12.64 (2.08)	12.45 (2.01)	.024
	2 to 6	15.05 (1.09)	13.27 (1.24)	12.82 (1.14)	.001
	6 to 10	13.36 (1.47)	11.73 (0.98)	11.36 (0.79)	.001

SD = standard deviation; GSU = grayscale units
[a]Estimation range is from 0 (no corneal cloudiness) to 100 (absolutely opaque cornea) light scatter.

Polypseudophakia for High Hyperopia

Sonia H Yoo MD

A novel technique for primary intracapsular polypseudophakia with posterior capsulotomy optic capture was performed in a pediatric patient with unilateral congenital posterior polar cataract in a nanophthalmic eye. Phacoemulsification combined with primary posterior capsulotomy, anterior vitrectomy, and primary intracapsular polypseudophakia was performed to attain full emmetropic refractive correction due to limited commercial availability of high-powered IOLs, resulting in a piggyback 1-piece IOL in the capsular bag with posterior optic capture of an underlying 3-piece IOL. The patient's refractive target was achieved by 2 months postoperatively, with good stability and safety through postoperative Year 1. This case demonstrated a useful technique to consider during cataract surgery in nanophthalmic or hypermetropic eyes, for which alternative methods of correcting residual postoperative refractive error may be suboptimal.

Complications and Challenges With Intracorneal Ring for Corneal Ectasia

Renato Ambrósio Jr MD

NOTES

Refractive Iris Repair

Amar Agarwal MD

Introduction

Pinhole pupilloplasty (PPP) has been documented to accentuate visual potential in cases with higher-order aberrations.[1-5] The importance of performing an iris reconstruction and PPP around the Purkinje-1 (P1) reflex cannot be overstated.[4,5]

P1 reflex is the target center for PPP, and perfect alignment in the desired location is necessary to achieve optimal refractive visual output. The PPP procedure essentially mandates the removal of natural lens due to its propensity to hit the lens with the suture needle.[2,3] As a result, the patients are rendered pseudophakic.

Case

A 42-year-old male patient with keratoconus presented at our center with apical fibrosis and associated cataract. Therefore, penetrating keratoplasty (PK) was performed with cataract extraction and IOL implantation along with PPP. Following surgery, a refractive surprise of +6.00 D sph/–11.50 D cyl @ 107 was encountered, and the visual acuity was recorded to be 20/400. It was also observed that PPP was decentered, and therefore recentration was deemed necessary.

The case was pseudophakic with PK done. The problem was that the IOL power was wrong. Also the Purkinje image was not centered on the pupil. So the IOL had to be explanted and a new IOL implanted. The issue was that the pupil was large at the end, at about 3.5 mm (see Figure 1).

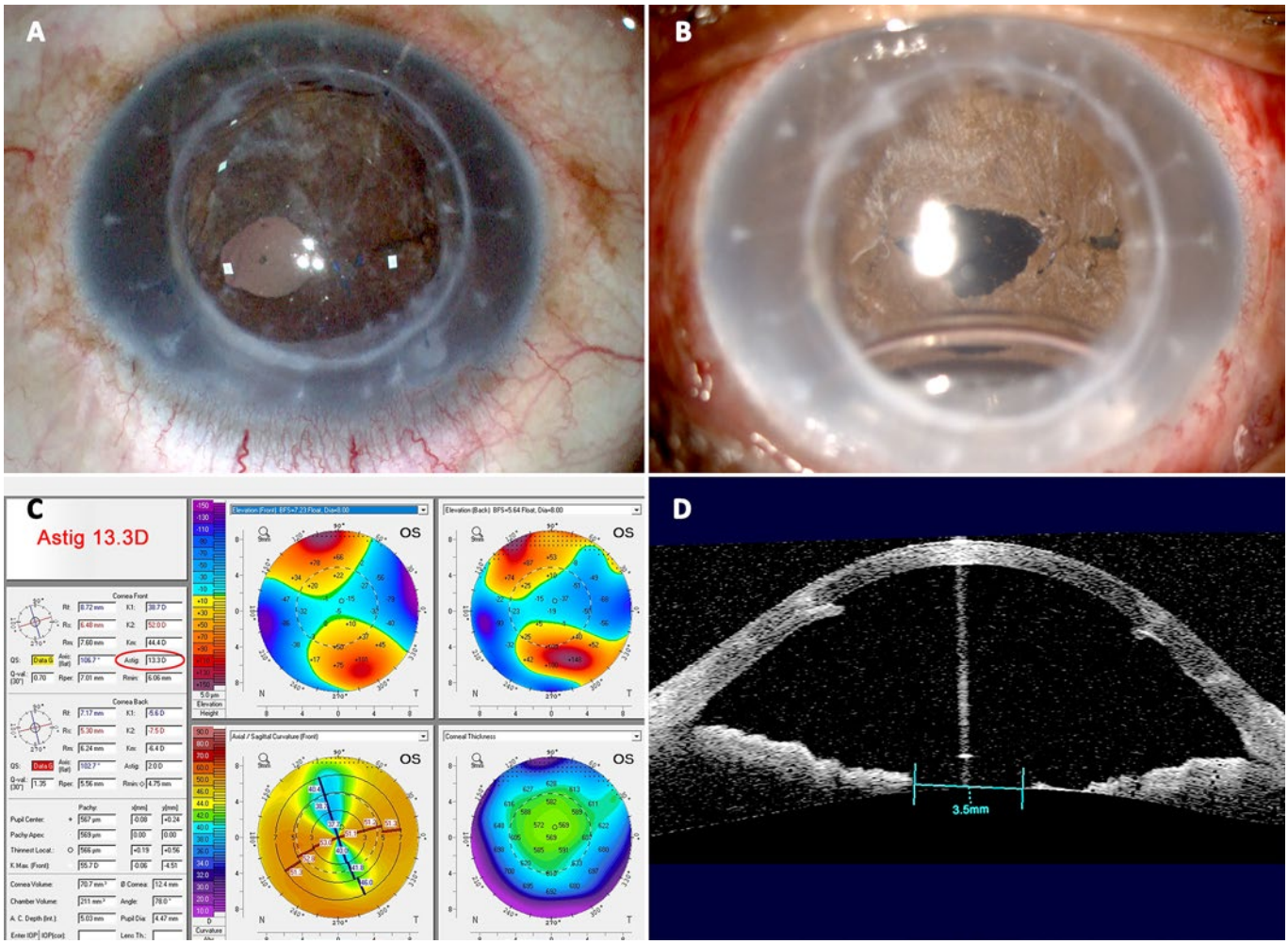

Figure 1. Surgical technique: (A) A pseudophakic eye with penetrating keratoplasty (PK) and pinhole pupilloplasty (PPP). The PPP is eccentrically placed. (B) IOL exchange and PPP done. (C) Pentacam shows 13 D astigmatism. (D) Anterior segment OCT shows 3.5-mm pupil.

Calibrating and Gauging the Pinhole Size

The essential steps to achieve a perfect functional pinhole are (1) appropriate preoperative evaluation of the pinhole size required to optimize visual acuity and (2) intraoperative gauging of the pupil size achieved. Both aspects need to be taken into consideration.

To meet the requirement of step 1, a pinhole device has been designed by Jack Holladay. The 1.60-mm thick device, made up of titanium anodized blue material, comprises of a set of pinholes that range from 0.5 mm and extend up to 4.0 mm in the stepwise gradation of 0.5 mm (see Figure 2). During preoperative assessment, the patient is made to read the visual chart from the device with pinholes of varied diameters, and the response to the best vision subjectively achieved with a specific pinhole diameter is recorded. Intraoperatively, an attempt is made to achieve the same pinhole size that helped achieve best visual acuity for the patient.

Figure 2. Holladay pinhole device.

For step 2, a reticle with a ruler is imposed onto the microscope eyepiece. Hence, when the surgeon looks through the microscope, the reticle image is imposed upon the eye of the patient. While calculating the pupil aperture in PPP, the surgeon should take into account the magnification of surgical microscope, the total number of lines on the reticle, and the value of each reticle division.

Final PPP

Two paracentesis incisions were made, at 5 o'clock and 8 o'clock positions, care being taken to evade the margins of the PK graft. The anterior chamber was formed with ophthalmic viscosurgical device.

The technique of performing PPP was done using the single-pass, four-throw pupilloplasty till the desired pupil size of 1 mm was achieved (see Figure 3). PPP was performed with 10-0 polypropylene suture, and pupil was centered around P1 reflex. Secondly, the image of the reticle was superimposed on the PPP as it was considered for calculating the diameter/size of the PPP. It was noticed that the previous pupil diameter was 3.5 mm, whereas the patient reported best visual acuity with a 1-mm diameter. Therefore, PPP was performed further to achieve the desired 1-mm pupil size.

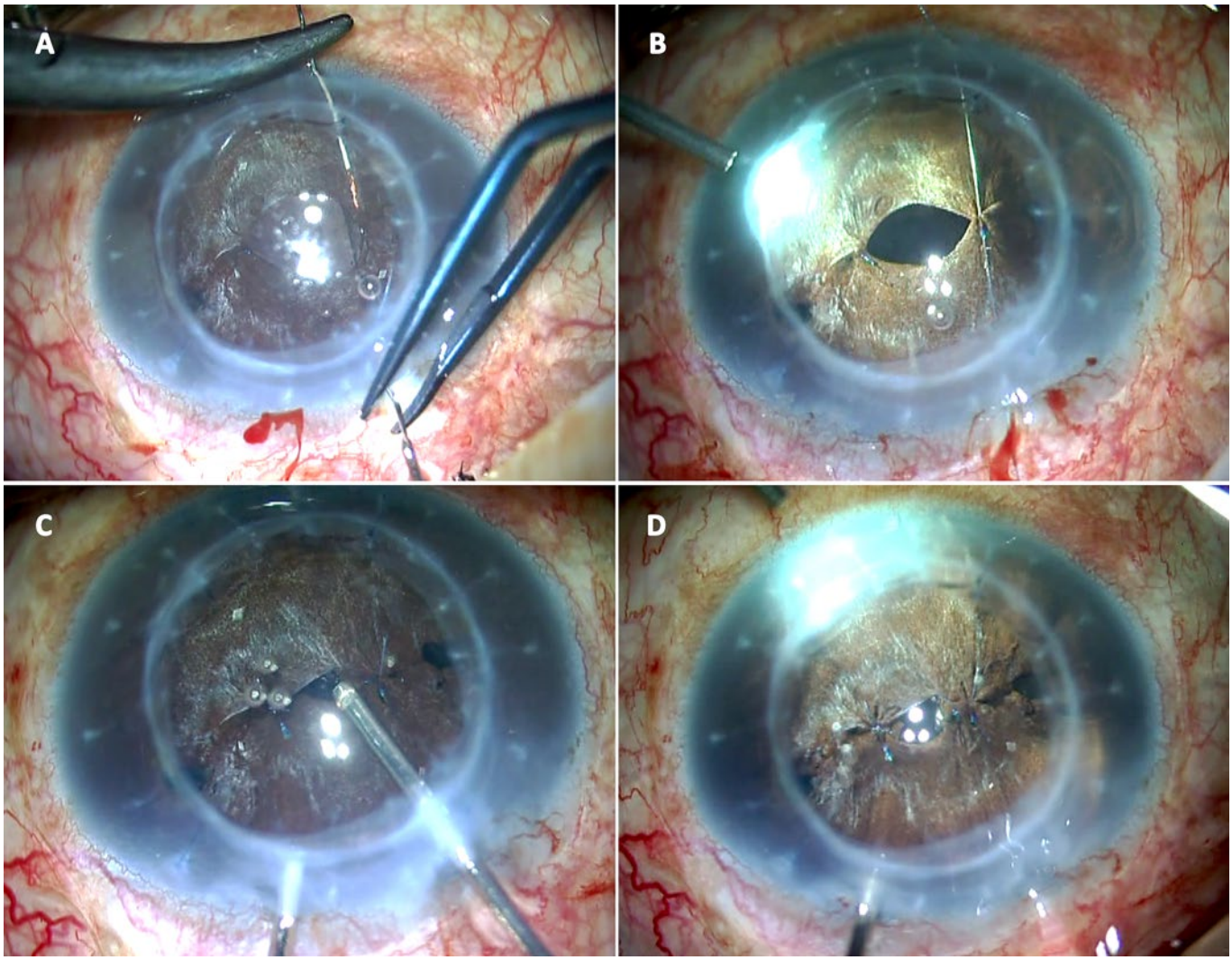

Figure 3. Surgical technique. (A) Single-pass, four-throw pupilloplasty. (C) PPP being performed. (C) Vitrectomy probe is used to cut the overlapping of Purkinje-1 (P1) reflex by iris tissue. (D) PPP is centered around P1 reflex.

References

1. Narang P, Holladay J, Agarwal A, Gracy H, Kumar DA, Sivagnanam S. Pinhole pupilloplasty for higher order aberrations: assessment of visual quality and depth of focus. *J Refract Surg.* 2020; 36(12):812-819.
2. Narang P, Agarwal A, Kumar DA, Sivagnanam S, Agarwal A. Pinhole pupilloplasty after previous radial keratotomy. *J Cataract Refract Surg.* 2021; 47(7):955-959.
3. Narang P, Agarwal A, Ashok Kumar D, Agarwal A. Pinhole pupilloplasty: small-aperture optics for higher-order corneal aberrations. *J Cataract Refract Surg.* 2019; 45(5):539-543.
4. Narang P, Holladay J, Agarwal A, Jaganathasamy N, Kumar DA, Sivagnanam S. Application of Purkinje images for pinhole pupilloplasty and relevance to chord length mu. *J Cataract Refract Surg.* 2019; 45(6):745-751.
5. Narang P, Agarwal A. Iris reconstruction with Purkinje-1 reflex as a marker for pupil centration. *J Refract Surg.* 2021; 37(8):570-571.

Management of Toric IOL Surprises

Elizabeth Yeu MD

I. Etiology
   A. Wrong magnitude of total corneal astigmatism
      1. Incorrect delta of K-values
      2. Posterior corneal astigmatism
   B. Induced or "false" corneal astigmatism
      1. Dry eye disease
      2. Pterygium
      3. Epithelial basement membrane dystrophy
      4. Salzmann nodular degeneration
   C. IOL power miscalculation
      1. Short/long axial length
      2. Post-LASIK
      3. Staphyloma
      4. Epiretinal membrane
      5. Ocular surface disease
   D. Effective lens position
      1. Short/long axial length
      2. Postoperative shift in position of IOL
   E. Malposition of toric IOL
      1. Steep axis misidentified preop or intraoperatively
      2. Postop malrotation of toric IOL
   F. Noncorneal sources of astigmatism
      1. Macula
      2. IOL tilt

II. Evaluation of the Patient With a Postoperative Surprise
   A. Finish all postoperative drops
   B. Diagnostics
      1. OCT macula
      2. Repeat biometry and topography
   C. Compare to preop diagnostics
   D. Careful ocular surface examination
   E. Accurate manifest refraction
   F. Check dilated eye for toric IOL position and identify meridian where toric IOL is at present.
   G. Is toric IOL re-rotation warranted?

III. Treatment of Ametropia
   A. Which corrective option do I choose?
      1. Depends on size of refractive error
      2. Treatment options
         a. Astigmatic keratotomy (peripheral corneal relaxing incisions, limbal relaxing incisions, astigmatic keratotomy)
         b. Corneal laser vision correction (LASIK, PRK)
         c. Toric IOL rotation, if warranted
         d. IOL exchange
         e. Piggyback lens
   B. What comorbidities exist that preclude treatment option?
      1. Irregular cornea
      2. Dry eye disease
      3. Prior LASIK or radial keratotomy surgery

IV. Conclusion: A Methodical Approach to Treat Residual Refractive Error
   A. Find the cause, and treat the cause if possible!
   B. Options: spectacles, corneal relaxing incisions, laser vision correction; infrequently, IOL exchange, piggyback IOL

IOL Scaffold

Ashvin Agarwal MD

In cases of posterior capsular rupture (PCR), a foldable IOL is used as a scaffold for preventing the nucleus fragment from descending into the vitreous. After removing the vitreous in the anterior chamber by anterior vitrectomy, a 3-piece foldable IOL is injected via the existing corneal incision, with one haptic above the iris and the other haptic extending outside the incision. Alternatively, both haptics can be placed above the iris or above the capsules. The nucleus is emulsified with the phacoprobe above the IOL optic. Cortical cleaning is done, and the IOL is then placed over the remnants of the capsule in the ciliary sulcus. This can be performed in eyes with moderate to soft cataracts. It avoids corneal incision extension and thereby limits induced astigmatism. This was conceptualized by Amar Agarwal.

Introduction

PCR is one of the common complications during phacoemulsification.[1-3] PCR with vitreous prolapse and the nucleus still in the capsular bag is an impending situation for a nucleus drop. As a preventive step, it is usual for the cataract surgeon to extend the corneal incision and deliver the nucleus.[4-6] Lens glide or Viscoat-assisted levitation have also been used to remove the nuclear fragments.[8] Another method is to emulsify the nucleus in the anterior chamber with low flow rate and vacuum.

Surgical Technique

When there is a PCR, an anterior chamber (AC) maintainer is introduced through a 1.2-mm stab microvitreoretinal (MVR) blade incision. The position of the AC maintainer should be away from the PCR, and flow should be kept low. Anterior vitrectomy is done with the vitrectomy cutter to remove the vitreous prolapsed in the anterior chamber. An Agarwal globe stabilization rod (Katena, USA) passed through the side port helps to push the fragment away from the PCR. The fragments are brought into the anterior chamber. A foldable IOL is then injected via the existing corneal wound and is maneuvered below the nucleus. The leading haptic of the IOL is positioned above the iris, and the trailing haptic is placed just outside the incision site. Using a dialer in the nondominant hand, the junction of the optic haptic junction on the trailing side is maneuvered so that the IOL blocks the pupil. Thus the IOL now acts as a scaffold and prevents the fragments from falling into the vitreous cavity. The nucleus fragment is then removed with the phaco probe (low flow and vacuum). Cortex is removed with suction and low aspiration using a vitrectomy probe. The nondominant hand adjusts the trailing optic haptic junction so that the IOL is well centered over the pupil, acting as a scaffold while emulsifying the nucleus. Once cortical cleaning is done, the IOL is placed over the capsular remnants in the ciliary sulcus. The AC maintainer is then removed, and wound hydration is done. Postoperatively, topical ofloxacin and corticosteroid eye drops are used 4 times daily for 2 weeks. A short-acting mydriatic drop twice a day is used for the first 3 days. Postoperative anterior chamber flare is graded by slit-lamp examination.

Instead of an AC maintainer, one can use a sutureless trocar cannula. This technique can be easily done in moderately soft nuclei. In very hard cataracts, it might be better to extend the incision and remove the nucleus to avoid corneal damage.

Glued IOL Scaffold

The IOL scaffold technique[11] was described by us in 2011, and we used this as a technique to prevent nuclear fragment drop into the vitreous cavity in the presence of a PCR. But in certain cases with insufficient iris and anterior capsular support for IOL scaffolding, it may not be prudent to implant the IOL and use it as a scaffold because of the risk of the IOL dropping into the vitreous cavity secondary to lack of any support. We have been using a technique that we term as "glued IOL scaffolding" to provide support during nuclear fragment removal in such eyes with insufficient iris support and absent or insufficient capsular support for sulcus placement of IOL. For glued IOL scaffolding, we combine the glued IOL technique with the IOL scaffold technique.

The problem comes in cases in which the iris support is not sufficient and there is no anterior capsular support to support the IOL scaffold technique. In such cases we cannot implant the IOL to support the nuclear pieces, as then the IOL may sink. This can happen in cases like an iris coloboma in which a PCR has occurred and there is no capsular support at all. Alternatively in cases like a floppy iris, where the iris is not taut enough to support the IOL, or cases in which the pupil is very dilated and not constricting due to trauma and once again there is no capsular support.

If there is a PCR in a case, one should stop phacoemulsification. The remaining nuclear pieces are brought to the anterior chamber. One should now fix an infusion cannula and create scleral flaps to prepare for glued IOL surgery. A 20-gauge needle then creates a sclerotomy 1 mm behind the limbus, under the sclera flaps. A 23-gauge vitrectomy is passed through the sclerotomy to perform vitrectomy so that there is no traction in the vitreous. Vitrectomy is an essential step in the surgery, as one can otherwise land up with a retinal detachment postoperatively.

The 3-piece foldable IOL is loaded onto the injector, and the cartridge is passed into the AC. The haptic tip should be slightly out of the cartridge so that when one goes to grasp the haptic with the glued IOL forceps, it is easy. The haptic tip is grasped with the glued IOL forceps, and while the IOL is unfolded the haptic tip is still caught. The chances of the IOL falling down are not there, as the haptic is caught with the forceps and the trailing haptic is still outside the clear corneal incision. The haptic is subsequently externalized. Using the handshake technique, the trailing haptic is externalized. This maneuver is sometimes difficult if the nuclear pieces are occupying a lot of space in the AC. One should use viscoelastic to dislodge the pieces to the side to gain visualization.

A 26-gauge needle is used to create the Scharioth pocket, and the haptics are tucked into the intrascleral pocket. Phacoemulsification of the nuclear pieces is performed. An artificial

posterior capsule has been created using the combination of the glued IOL and the IOL scaffold technique. This prevents the nuclear fragments from falling into the vitreous cavity. Finally, air is injected into the AC, and fibrin glue is used to seal the haptics in the sclera.

Conclusion

Avoiding PCR is the goal of every cataract surgeon. If a tear occurs, management techniques and skills are required for preventing further complications. Early recognition of PCR combined with prevention of collapse of the AC may prevent extension of the tear, forward movement of the vitreous, and displacement of the lens posteriorly. Here in this technique, the AC is maintained by slow infusion, forward movement of the vitreous is prevented by the IOL scaffold, and the nucleus fragment drop is stopped by the IOL, which acts as a physical barrier. Thus we favor this new IOL scaffolding technique in PCRs with nonemulsified, moderate to soft nucleus during phacoemulsification. However, in cases of hard cataract, conversion to extracapsular cataract extraction is ideal. By combining the glued IOL and the IOL scaffold techniques, one can create an artificial posterior capsule in certain select cases of capsular deficiency where the iris is deficient or the pupil too large to support an IOL.

References

1. Vejarano LF, Tello A. Posterior capsular rupture. In: Agarwal A, ed. *Phaco Nightmares: Conquering Cataract Catastrophes*. Slack, Inc.; 2006: 253-264.
2. Vajpayee RB, Sharma N, Dada T, Gupta V, Kumar A, Dada VK. Management of posterior capsule tears. *Surv Ophthalmol*. 2001; 45(6):473-488.
3. Gimbel HV, Sun R, Ferensowicz M, Anderson Penno E, Kamal A. Intraoperative management of posterior capsule tears in phacoemulsification and intraocular lens implantation. *Ophthalmology* 2001; 108(12):2186-2189; discussion: 2190-2192.
4. Dada T, Sharma N, Vajpayee RB, Dada VK. Conversion from phacoemulsification to extracapsular cataract extraction: incidence, risk factors, and visual outcome. *J Cataract Refract Surg*. 1998; 24(11):1521-1524.
5. Prasad S, Kamath GG. Converting from phacoemulsification to ECCE. *J Cataract Refract Surg*. 1999; 25(4):462-463.
6. Thatte S, Raju VK. Phacosandwich technique. *J Cataract Refract Surg*. 1999; 25(8):1039-1040.
7. Chang DF, Packard RB. Posterior assisted levitation for nucleus retrieval using Viscoat after posterior capsule rupture. *J Cataract Refract Surg*. 2003; 29(10):1860-1865.
8. Michelson MA. Use of a Sheets' glide as a pseudo-posterior capsule in phacoemulsification complicated by posterior capsule rupture. *Eur J Implant Refract Surg*. 1993; 5:70-72.
9. Hansson LJ, Larsson J. Vitrectomy for retained lens fragments in the vitreous after phacoemulsification. *J Cataract Refract Surg*. 2002; 28(6):1007-1011.
10. Monshizadeh R, Samiy N, Haimovici R. Management of retained intravitreal lens fragments after cataract surgery. *Surv Ophthalmol*. 1999; 43(5):397-404.
11. Kumar DA, Agarwal A, Prakash G, Jacob S, Agarwal A, Sivagnanam S. IOL scaffold technique for posterior capsular rupture. *J Refract Surg*. 2012; 28(5):314-315.

ISHF: Glued IOL – Yamane – Canabrava Techniques

Eric D Donnenfeld MD

I. Glued IOL Technique

Introduced by Amar Agarwal MD, this is an innovative and effective method for repositioning a dislocated 3-piece IOL in eyes without adequate capsular support or inserting a new 3-piece IOL, and it has advantages over suturing. With the glued IOL technique, the IOL almost always centers perfectly, and I have not seen any IOL tilt, which can occur after suturing a dislocated IOL.

A. Preoperative evaluation

1. Evaluate position, capsule, and type of posterior chamber IOL.
2. Evaluate corneal integrity and consider endothelial cell count.

B. Surgical technique

1. Peribulbar or general anesthesia
2. Create scleral flaps.
   a. Perform a conjunctival peritomy with a Wescott scissors.
   b. Eraser cautery to achieve hemostasis
   c. Using a crescent blade, create 2 limbus-based scleral flaps 180° apart.
3. Place anterior chamber maintainer.
4. Create 2 limbal incisions with a keratome and fill the anterior chamber with viscoelastic.
5. Perform a pars plana vitrectomy.
   a. Create 2 sclerotomies 1.5 mm posterior to the limbus and under the scleral flaps using an MVR blade.
   b. Pars plana vitrectomy performed under direct visualization using a 25-gauge vitrector to separate vitreous from the IOL, taking care to avoid exerting vitreous traction. Consider using intracameral triamcinolone to demarcate vitreous.
6. Position IOL: The handshake technique
   a. Using a microforceps through the pars plana incision, grasp the IOL or haptic and bring the IOL into the anterior chamber in front of the iris.
   b. Handshake technique: Using 2 microforceps introduced into the eye through a limbal incision and one of the sclerotomies, the handshake technique is used to pass one of the haptics from the anterior chamber into the posterior chamber for externalization through the sclerotomy. The end of the externalized haptic is grasped by an assistant to prevent its slippage while the surgeon repeats the handshake technique to grasp and deliver the second haptic through the sclerotomy on the opposite side.
7. Fixating the IOL: Once the haptics are externalized, an incision is placed into the sclera and the haptics are placed into a scleral incision adjacent to the scleral flap. Then, the anterior chamber maintainer is removed and the scleral flaps and conjunctiva are fixed over the pockets with fibrin glue.

II. Yamane Technique

The double-needle intrascleral flanged haptic fixation technique described by Shin Yamane:

A. Radial toric axis marker and an inked Sinskey hook are used to mark 2 points at the limbus, 180° apart. The marks should be centered on the pupil or on the intended position of the IOL optic.

B. Anterior or posterior vitrectomy

C. Anterior chamber maintainer

D. Thin-walled 30-gauge needles (TSK Laboratory inner diameter: 0.20 mm) provide the most secure tunnel for the haptics of 3-piece IOLs (diameter: 0.14 to 0.17 mm). The needles should be inserted 2.5 mm posterior to the limbus, and the sclerotomy tunnels must be equal in length.

E. CT Lucia 602 (Carl Zeiss Meditec) is the preferred 3-piece lens to use for the Yamane technique because its polyvinylidene fluoride haptics are more easily manipulated and resist breakage, which can occur with a Prolene haptic.

F. The most technically difficult step of the Yamane technique is threading the trailing haptic into the needle. I create a paracentesis 180° away from the sclerotomy to optimize the direction of the intraocular 25-gauge microforceps so that the haptic can be grasped parallel to the 30-gauge needle.

G. Slowly remove both needles simultaneously (or fixate one at a time) and observe the optic centration. Adjust the centration of the IOL by positioning the haptics prior to cauterizing the haptics with a low-temp cautery and burying beneath the conjunctiva.

III. Canabrava Technique

The Canabrava or 4-flanged technique was originally described by Sergio Canabrava:

A. Two 26-gauge hypodermic needles are used to perform 2 sclerectomies, each one 90° from the main incision. These needles work as an external guide to remove 2 pieces of 5-0 polypropylene suture from the eye.

B. Outside of the eye, the 2 polypropylene suture ends are passed through the 2 eyelets of a nonfoldable IOL and heated by the thermocautery to create the first and second flanges. The first haptic of the IOL is then drawn into the eye using McPherson forceps while the other hand pulls the externalized suture to aid the correct positioning of the first haptic.

C. McPherson forceps are used to make a pronation movement in the second haptic while the surgeon uses the other hand to pull the other limbus externalized suture to aid the positioning of the second haptic in the sulcus. The IOL is centered using the 2 polypropylene suture ends externalized 2 mm from the limbus at each side. The sutures are cut 2 mm from their base and heated to form the third and fourth flanges, which will be inserted into the sclera

Selected Readings

1. Agarwal A, Kumar DA, Jacob S, Baid C, Agarwal A, Srinivasan S. Fibrin glue-assisted sutureless posterior chamber intraocular lens implantation in eyes with deficient posterior capsules. *J Cataract Refract Surg.* 2008; 34:1433-1438.

2. Yamane S, Sato S, Maruyama-Inoue M, Kadonosono K. Flanged intrascleral intraocular lens fixation with double-needle technique. *Ophthalmology* 2017; 124(8):1136-1142.

3. Canabrava S, Andrade N, Henriques P. Scleral fixation of a 4-eyelet foldable intraocular lens in patients with aphakia using a 4-flanged technique. *J Cataract Refract Surg.* 2021; 47(2):265-269.

Premium IOL Exchange for Unhappy Patient

David F Chang MD

NOTES

Refractive Lens Exchange: SIM vs. SEQ IOL Surgery

Julie M Schallhorn MD

NOTES

Enhancement Strategy in Premium IOLs: My Best Pearls

Majid Moshirfar MD

NOTES

Premium IOL Implantation After Laser Vision Correction: My Greatest Errors and Solutions

Zeba A Syed MD

I. Case Presentation

A. 62-year-old male who underwent myopic LASIK (pre-LASIK refraction –5.50 sph OD and –6.25 sph OS) at age 32 years and had presented for cataract evaluation OU

B. Examination with 2-3+ nuclear sclerosis OU

C. Patient with strong desire for spectacle independence at distance, intermediate, and near

D. After discussion of risks, benefits, and alternatives, he underwent uneventful cataract extraction with IOL of the right (dominant) eye with a diffractive trifocal IOL.

E. Patient presented for follow-up with an uncorrected distance visual acuity of 20/25 and uncorrected near visual acuity of J1 but was unhappy with significant glare and positive dysphotopsias.

F. Over a period of 4 weeks, he continued to find the dysphotopsias disabling and interfering with daily activities; options discussed included observation vs. IOL exchange.

G. Patient underwent IOL exchange in the right eye with extended-depth-of-focus IOL. Postoperative uncorrected distance visual acuity was 20/20 and uncorrected near acuity was J4, and he reported a reduction in glare and dysphotopsia symptoms.

H. Patient was dissatisfied with near acuity, underwent mini-monovision with nondominant eye for near; patient now happy with results.

II. Discussion

A. Considerations for premium IOLs after prior corneal refractive surgery

1. Corneal topography; decentered ablations
2. Corneal higher-order aberrations
3. Pupil
4. Macula status (eg, posterior staphyloma)
5. Challenges in IOL calculations and sources of error
6. Patient expectations
7. Availability of power in desired IOL (eg, Vivity)

B. Testing to perform: anterior segment OCT, topography, tomography, macular OCT

C. IOL options, including pros and cons of each

1. Monofocal (± toric)
2. Extended depth of focus
3. Diffractive trifocal

D. Options for unhappy patients

1. Lens exchange
2. Refractive touch-up
3. Piggyback IOL

E. Results of survey distributed to cataract surgeons about preferred premium IOLs for post–refractive surgery patients

Selected Readings

1. Brenner LF, Gjerdrum B, Aakre BM, Lundmark PO, Nistad K. Presbyopic refractive lens exchange with trifocal intraocular lens implantation after corneal laser vision correction: refractive results and biometry analysis. *J Cataract Refract Surg.* 2019; 45(10):1404-1415.
2. Christopher KL, Miller DC, Patnaik JL, Lynch AM, Davidson RS, Taravella MJ. Comparison of visual outcomes of extended depth of focus lenses in patients with and without previous laser refractive surgery. *J Refract Surg.* 2020; 36(1):28-33.
3. Li QM, Wang F, Wu ZM, et al. Trifocal diffractive intraocular lens implantation in patients after previous corneal refractive laser surgery for myopia. *BMC Ophthalmol.* 2020; 20(1):293.
4. Vrijman V, Abulafia A, van der Linden JW, van der Meulen IJE, Mourits MP, Lapid-Gortzak R. Evaluation of different IOL calculation formulas of the ASCRS Calculator in eyes after corneal refractive laser surgery for myopia with multifocal IOL implantation. *J Refract Surg.* 2019; 35(1):54-59.
5. Vrijman V, van der Linden JW, van der Meulen IJE, Mourits MP, Lapid-Gortzak R. Multifocal intraocular lens implantation after previous corneal refractive laser surgery for myopia. *J Cataract Refract Surg.* 2017; 43(7):909-914.

Zero Endophthalmitis With Zero Topical Antibiotics

Andrzej Grzybowski MD

Introduction

The incidence of postcataract endophthalmitis varies among several countries from 0.03% to 0.7%. The recommendations of the European Registry of Quality Outcomes for Cataract and Refractive Surgery have set the maximum acceptable level of postoperative endophthalmitis (POE) after cataract extractions at 0.05%. Surgical complications (wound leak, posterior capsule rupture, vitreous loss or zonular complications) are related to a higher incidence of POE. Elderly patients (>85 years), those with clear corneal incisions versus scleral tunnel incisions, and those without intracameral injection of cefuroxime also have a higher risk of infection. Several studies from different regions found an increased relative risk of endophthalmitis with clear corneal incisions compared to scleral tunnel or limbal incisions (RR approximately 2.0-3.0). Endophthalmitis occurs infrequently (0.05%-0.08%) using scleral tunnel or limbal incisions. Patients with silicone IOLs have higher probability of endophthalmitis than those with acrylic (or other material) IOLs. Moreover, the highest incidence of endophthalmitis was observed after secondary IOL implantation; and the lowest, after pars plana vitrectomy. The ESCRS Study and many later retrospective studies showed that intracameral injection of antibiotic reduced the risk for contracting endophthalmitis following phacoemulsification cataract surgery, which was adopted in many countries as standard prophylaxis procedure, especially in places where on-label products are available.

Discussion

European Society of Cataract and Refractive Surgeons guidelines argue that topical antibiotics preoperatively and/or postoperatively do not confer a clear benefit over povidone iodine preoperatively and intracameral antibiotics injected at the close of surgery. The use of topical antibiotics differs in many European countries. In Sweden and Denmark, national guidelines do not recommend topical antibiotics before and after cataract surgery in standard cases, and most surgeons avoid using them. Although postoperative topical antibiotics are used in a majority of European countries for 5-7 days, their preoperative use has declined in recent years. For example, French national guidelines do not recommend use of topical antibiotics before surgery, and many surgeons in Poland and in Germany have stopped this practice in recent years. Nowadays, some new approaches have been proposed that reduce the need for topical therapy. They include intracameral injection, sustained or slow-release drug delivery mechanisms, and the recently introduced "dropless cataract surgery," which involves intravitreal injection of single-use, compounded combination of antibiotics and corticosteroids.

Take-home Messages

- Intracameral antibiotics (ICA) can decrease POE; after considering availability, cost, and the POE without ICA, its use should be considered.
- Intraoperative complications increase the POE significantly, thus the use of ICA seems to be reasonable in these situations.
- There is evidence that with ICA, topical antibiotics are not needed.

Selected Readings

1. Grzybowski A, Brona P, Zeman L, Stewart MW. Commonly used intracameral antibiotics for endophthalmitis prophylaxis: a literature review. *Surv Ophthalmol*. 2021; 66(1):98-108.
2. Sengillo JD, Chen Y, Garcia Perez D, Schwartz SG, Grzybowski A, Flynn HW Jr. Postoperative endophthalmitis and toxic anterior segment syndrome prophylaxis: 2020 update. *Ann Transl Med*. 2020; 8(22):1548.
3. Grzybowski A, Koerner JC, George MJ. Postoperative endophthalmitis after cataract surgery: a worldwide review of etiology, incidence and the most studied prophylaxis measures. *Expert Rev Ophthalmol*. 2019; 14:4-5, 247-257.
4. Grzybowski A, Kanclerz P. Less might be more: are disposable gloves and gowns necessary for cataract surgery? *Acta Ophthalmol*. 2018; 86(7):e896-e897.
5. Grzybowski A, Turczynowska M. More antisepsis, less antibiotics whenever possible. *Asia-Pac J Ophthalmol*. 2018; 7(2):72-75.
6. Shimada H, Nakashizuka H, Gzybowski A. Prevention and treatment of postoperative endophthalmitis using povidone-iodine. *Curr Pharm Des*. 2017; 23(4):574-585.
7. Lindstrom RL, Galloway MS, Grzybowski A, Liegner JT. Dropless cataract surgery: an overview. *Curr Pharm Des*. 2017; 23(4):558-564.
8. Grzybowski A, Turczynowska M. Prophylaxis and treatment of endophthalmitis. *Cataract Surg*. Epub ahead of print 2021 Jan. doi: 10.1007/978-3-030-38234-6_11.
9. Grzybowski A, Turczynowska M. Endophthalmitis, toxic anterior segment syndrome, and vitritis. In: Narang P, Trattler W, eds. *Optimizing Suboptimal Results Following Cataract Surgery: Refractive and Non-refractive Management*. New York: Thieme; 2019.

My Decision Tree for Choosing the Type of Presbyopia-Correcting IOL

Luis Izquierdo Jr MD

NOTES

Optimizing Outcomes In Toric IOLs

Robert Edward T Ang MD

NOTES

Has the Time Come for Spectacle Independency Without Optical Side Effects?

Rudy Nuijts MD, J Wanten, VSC Webers, NJC Bauer, LHH Clement, and FJHM Van den Biggelaar

Introduction

The most common types of IOLs used during cataract surgery are monofocal, multifocal, or extended depth of focus (EDOF) IOLs. Multifocal IOLs (mIOLs) are well known for providing unaided vision at more than one distance, causing less spectacle dependency for patients after cataract surgery.[1] However, important side effects of mIOLs are contrast sensitivity loss and the possible manifestations of photic phenomena, due to their optical design with either a diffractive or zonal refractive technology.[2,3] This potential deterioration of vision quality makes implantation of mIOLs less applicable in patients who have high expectations or in patients with pre-existing pathology that may affect the visual pathway.[1,4-6] The new EDOF IOLs provide in an extended range of focus, and compared to monofocal IOLs, these IOLs arrange a wider range of unaided vision, especially from the intermediate to far distances. For enhancement of spectacle independency, a mini-monovision approach is often used for EDOF IOLs, with the dominant eye targeted for emmetropia and the nondominant eye targeted for slightly myopic. Studies have shown that patients are very satisfied about the results using this approach.[7,8]

In a prospective cohort study 22 patients were enrolled: 44 eyes were bilaterally implanted with the Alcon Vivity IOL and targeted for mini-monovision; 4 patients received a toric version.

Visual Outcomes, Spectacle Independence, and Optical Phenomena

The mean binocular postoperative visual outcomes at 3 months are for the uncorrected distance visual acuity (UDVA) −0.07 ± 0.10, uncorrected intermediate visual acuity (UIVA) 0.04 ± 0.09, uncorrected near visual acuity (UNVA) 0.23 ± 0.12, corrected distance visual acuity (CDVA) −0.10 ± 0.08, distance-corrected intermediate visual acuity (DCIVA) 0.03 ± 0.07, and distance-corrected near visual acuity (DCNVA) 0.28 ± 0.08 logMAR. The postoperative monocular visual and refractive outcomes are subdivided in the dominant and nondominant eye, which show respectively a CDVA of −0.04 ± 0.11 logMAR and manifest refractive spherical equivalent (MRSE) of 0.11 ± 0.31 D, and a CDVA of −0.03 ± 0.10 logMAR and MRSE of −0.13 ± 0.30 D, as shown in Table 1. The percentage of eyes with MRSE between 1.0 D and 0.5 D of the predicted phoropter refraction (PPR) for the dominant eye is 100% and 95%; and for the nondominant eye, 100% and 86%, demonstrated in Figure 1.

Table 1. Postoperative Refractive and Visual Acuity Results

Parameter	Dominant Eye	Nondominant Eye
Spherical error (D), mean ± SD (range)	0.31 ± 0.34 (−0.25, 1.00)	0.13 ± 0.37 (-0.75, 0.75)
Residual cylinder (D), mean ± SD (range)	−0.40 ± 0.29 (−1.00, 0.00)	−0.50 ± 0.40 (−1.50, 0)
MRSE (D), mean ± SD (range)	0.11 ± 0.31 (−0.50, 0.63)	−0.13 ± 0.30 (−0.75, 0.38)
Visual acuity		
Monocular CDVA at 4 m (logMAR), mean ± SD (range)	−0.04 ± 0.11 (−0.20, 0.26)	−0.03 ± 0.10 (−0.20, 0.20)
Binocular UDVA at 4 m (logMAR), mean ± SD (range)	−0.07 ± 0.10 (−0.24, 0.18)	
Binocular UIVA at 66 cm (logMAR), mean ± SD (range)	0.04 ± 0.09 (−0.10, 0.24)	
Binocular UNVA at 40 cm (logMAR), mean ± SD (range)	0.23 ± 0.12 (0.00, 0.42)	
Binocular CDVA at 4 m (logMAR), mean ± SD (range)	−0.10 ± 0.08 (−0.24, 0.02)	
Binocular DCIVA at 66 cm (logMAR), mean ± SD (range)	0.03 ± 0.07 (−0.08, 0.18)	
Binocular DCNVA at 40 cm (logMAR), mean ± SD (range)	0.28 ± 0.08 (0.08, 0.40)	

Abbreviations: CDVA, corrected distance visual acuity; DCIVA, corrected intermediate visual acuity; DCNVA, corrected near visual acuity; logMAR, logarithm of the minimum angle of resolution; MRSE, mean refractive spherical equivalent; UDVA, uncorrected distance visual acuity UDVA; UIVA, uncorrected intermediate visual acuity; UNVA, uncorrected near visual acuity.

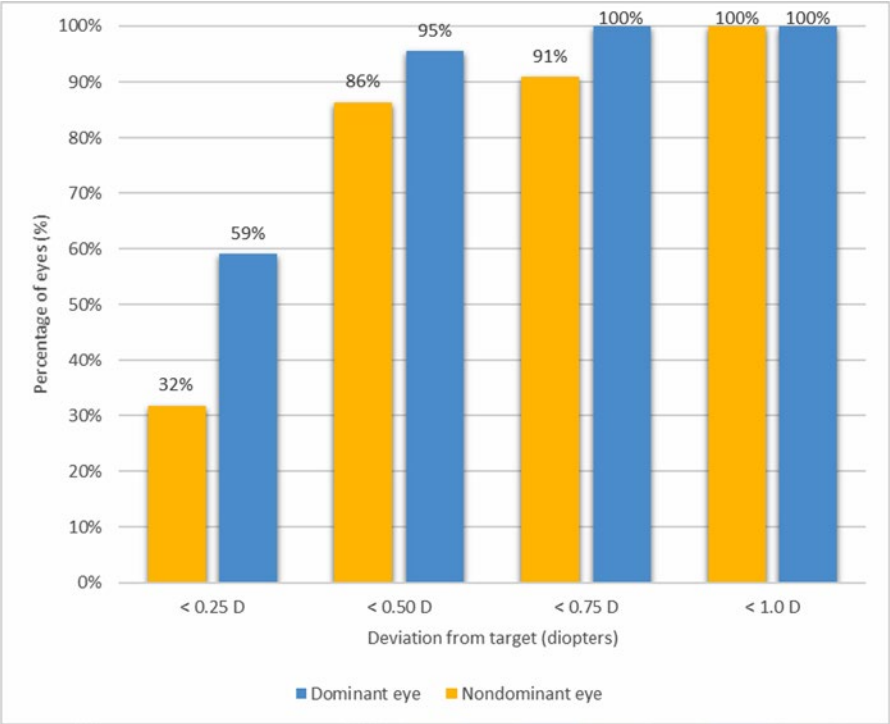

Figure 1. Percentages of MRSE within 0.25 D, 0.50 D, 0.75 ,D and 1.0 D of the PPR in the dominant and nondominant eyes.

The uncorrected and distance-corrected binocular defocus curves have the best visual acuity achieved at 0 D with –0.07 logMAR and –0.11 logMAR, respectively, as can be seen in Figure 2. Both defocus curves show a gradual increase in logMAR between –2.5 D and 0 D while achieving a visual acuity greater than 0.10 logMAR in the range from –2.0 D to +0.5 D. At the –2.5 D point, the achieved logMAR is 0.24 and 0.20 for the corrected and uncorrected binocular defocus curves. The uncorrected monocular defocus curves for the dominant eye and nondominant eye, seen in Figure 3, show a slight myopic shift in the defocus curve for the nondominant eye as a result of the mini-monovision approach.

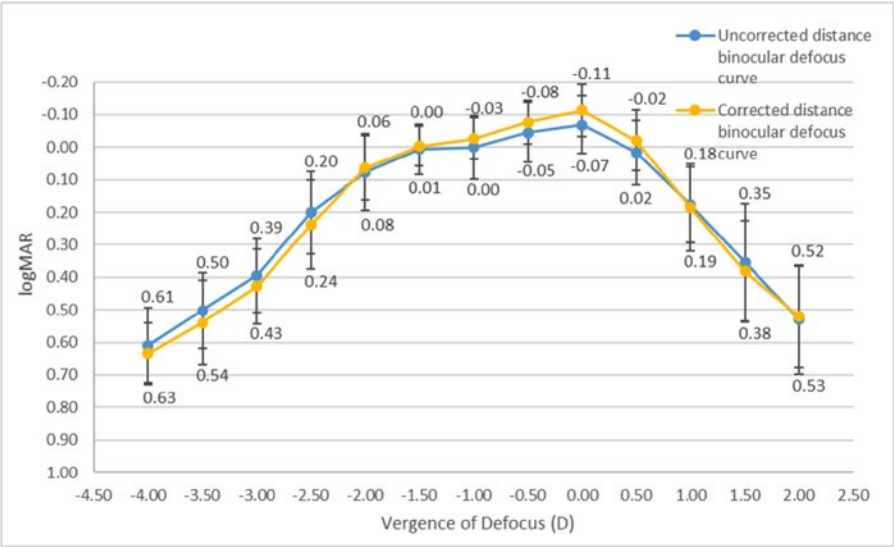

Figure 2. Uncorrected and distance corrected binocular defocus curves.

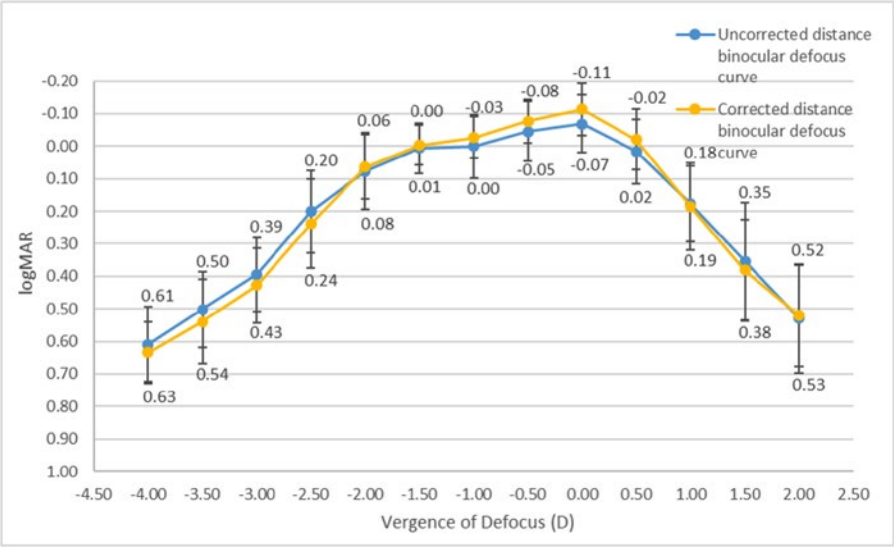

Figure 3. Uncorrected monocular defocus curves for the dominant eye and nondominant eye.

Patients have reported spectacle independence at 3 months. Under mesopic conditions, the percentage of patients who reported using glasses rarely or not at all is lower than under photopic conditions for distance (95% vs. 96%) and near (24% vs. 38%) viewing distance, while the intermediate viewing distance scored better under mesopic than photopic conditions (77% vs. 68%). Overall, 32% and 14% of patients have achieved total spectacle independence, while 38% and 24% of patients reported never/rarely using glasses at all distances, in photopic and mesopic conditions, receptively.

The percentage of patients who have not experienced halos, glare, or starbursts are 91%, 91%, and 100%, respectively. The percentage of patients who reported mild complaints of halos, glare, or starbursts are 9%, 9%, and 0%, respectively. None of the patients has reported severe optical complaints.

Complications: Mini-Monovision Target

In this current study, mini-monovision was approached, targeting the dominant eye to emmetropia and the nondominant eye to between −0.25 and −0.50 D PPR. Even though the refractive outcomes in terms of MRSE were slightly more hyperopic than expected, with 0.11 D in the dominant eye and −0.13 D in the nondominant eye, both binocular UDVA and UIVA showed very good results, with acceptable binocular UNVA. Using the fogging technique, obtaining the least minus or maximum plus sphere, could be the reason for our more hyperopic residual refraction outcomes. This research showed a lower achieved spherical equivalent (SE) within 0.25 D of target for the nondominant eye in comparison to the dominant eye (59% and 32%, respectively). However, when the achieved SE within 0.25 D is combined for both the dominant and nondominant eye, the percentage is around 45%, which is in line with the current mean absolute error of 41.7% for the BU-II, reported by Kane et al.

Conclusions

In conclusion, this research shows that binocular implantation of the AcrySof IQ Vivity IOL with a mini-monovision approach provides excellent uncorrected distance and intermediate visual acuities together with an acceptable useful near vision. This results in a high degree of distant and intermediate spectacle independence. The novel nondiffractive EDOF IOL design offers patients an extended range of vision, including a monofocal optical disturbance profile.

References

1. Breyer DRH, Kaymak H, Ax T, Kretz FTA, Auffarth GU, Hagen PR. Multifocal intraocular lenses and extended depth of focus intraocular lenses. *Asia-Pac J Ophthalmol*. 2017; 6(4):339-349.
2. Alio JL, Plaza-Puche AB, Férnandez-Buenaga R, Pikkel J, Maldonado M. Multifocal intraocular lenses: an overview. *Surv Ophthalmol*. 2017; 62(5):611-634.
3. Erie JC, Simpson MJ, Bandhauer MH. A modified intraocular lens design to reduce negative dysphotopsia. *J Cataract Refract Surg*. 2019; 45(7):1013-1019.
4. Jonker SMR, Bauer NJC, Makhotkina NY, Berendschot TTJM, van den Biggelaar FJHM, Nuijts RMMA. Comparison of a trifocal intraocular lens with a +3.0 D bifocal IOL: results of a prospective randomized clinical trial. *J Cataract Refract Surg*. 2015; 41(8):1631-1640.
5. de Vries NE, Nuijts RMMA. Multifocal intraocular lenses in cataract surgery: literature review of benefits and side effects. *J Cataract Refract Surg*. 2013;39(2):268-278.
6. Vrijman V, van der Linden JW, van der Meulen IJE, Mourits MP, Lapid-Gortzak R. Multifocal intraocular lens implantation after previous corneal refractive laser surgery for myopia. *J Cataract Refract Surg*. 2017; 43(7):909-914.
7. Georgiev S, Palkovits S, Hirnschall N, Döller B, Draschl P, Findl O. Visual performance after bilateral toric extended depth-of-focus IOL exchange targeted for micromonovision. *J Cataract Refract Surg*. 2020; 46(10):1346-1352.
8. Ganesh S, Brar S, Pawar A, Relekar KJ. Visual and refractive outcomes following bilateral implantation of extended range of vision intraocular lens with micromonovision. *J Ophthalmol*. 2018; 2018:7321794-7321794.
9. Darcy K, Gunn D, Tavassoli S, Sparrow J, Kane JX. Assessment of the accuracy of new and updated intraocular lens power calculation formulas in 10 930 eyes from the UK National Health Service. *J Cataract Refract Surg*. 2020; 46(1):2-7.

New Management Strategies for Cataract Surgery in the Post–Refractive Surgery Patient

Thomas Kohnen MD PhD FEBO

Many patients want to be independent from spectacles or contact lenses. The different treatment approaches for achieving this include LASIK, SMILE, PRK, and phakic IOLs and refractive lens exchange.

Surgery has increased significantly in recent years and decades, and surgeons now face the challenge that invariably cataract patients have had previous refractive corneal procedures. In most cases, patients still want to continue to manage in their daily lives without glasses. To achieve the best possible visual and refractive results, complex knowledge and further development of previous treatment methods and calculation formulas are necessary. Therefore, several points must be considered as new management strategies for cataract surgery in the post–refractive surgery patient.

Measurements and Corneal Surface Optimization

The corneal surface after refractive surgery may be irregular, with a small (previously treated) or even a decentered optical zone. For an upcoming cataract surgery, it is especially important to optimize the cornea preoperatively, especially if abnormalities are present. Especially, a dry eye should be treated with tear substitutes to achieve a smoothing of the corneal surface and to ensure good quality and repeatability of the preoperative measurements.

The biometric data are the basis for a good lens estimation. For example, in recurrent epithelial basement membrane dystrophy, preoperative consideration should be given to whether treatment with a phototherapeutic keratectomy might lead to improvement so that a smoothing of the corneal surface can be aimed at. In case of previous surgeries with corneal inlays, one should consider whether these should be removed before the planned cataract procedure, and whether to wait for a time between the surgeries or if it should be included in the calculation.

An unoptimized corneal surface is one of the main sources of erroneous astigmatism measurements, along with the lens and retina. Astigmatism and consideration of posterior surface astigmatism in IOL estimation are critical to achieving the best possible postoperative outcome.

IOL Estimation (Calculation)

During the preliminary examination of the cataract patient, care should be taken to ensure that the measurements of the eye are repeatable and checked for plausibility. If possible, the patient should provide records of all existing examinations performed prior to refractive surgery treatment. This is a good prerequisite, especially for the IOL estimation, as it makes more likely the predictability of the postoperative result.

Also important for the IOL estimation in post-refractive patients is the correct choice of the calculation formula. This is where the medical history, pre–refractive surgery examinations, and accurate measurement of current examination results come into play. The accuracy of predicted IOL estimates in post–refractive surgery patients is lower than that in nonoperated patients. The study group of Melles et al[1] evaluated the variation of 7 calculation formulas for previously unoperated cataract patients with a monofocal IOL. They concluded that for each formula, more than 95% achieved a SE of ±1.00 D. By varying each of the 7 formulas, 72% to 80% of the eyes were within a SE of ±0.50 D. Similar but less predictable results were obtained in the study by Cho et al,[2] looking at lens power calculation methods following myopic laser refractive surgery. Visual outcomes within 1.0 D of target refraction were achieved in 85% of eyes using the calculation formulae Haigis-L, Shammas, Barrett True-K (no history), Wang-Koch-Maloney, Scheimpflug TCRP 4 mm (Haigis), Scheimpflug true net power 4 mm (Haigis), and Scheimpflug TRP 4 mm (Haigis). In presbyopia-correcting IOL (here extended depth of focus [EDOF]) the group of Lwowski et al[3] came up with a target accuracy of only 52% on average within the SE of ±0.50 D when comparing the formulas after myopic LASIK.

Patient Expectation

The desire for spectacle independence is very high, especially among patients who already had refractive surgery. At the same time, they want good visual acuity with as few optical phenomena as possible. In these cases, the patient should be informed in detail about the existing possibilities and possible limitations. Especially in patients with high corneal aberrations, one has to consider implanting only a monofocal (aspheric) IOL, because multifocal lenses are rather incompatible. In addition, the patient must be educated about the accuracy of IOL power estimation and the increased difficulty with previous corneal refractive surgery. In addition, the fact that postoperative surprises may occur must also be discussed, along with how they could be remedied—for example, by IOL exchange, IOL piggyback implantation (add-on IOL), and further keratorefractive procedures. A realistic expectation of the patient's refractive visual outcome contributes to patient satisfaction.

Which IOL to Choose?

The choice of the right IOL to use in cataract surgery is always complex. Especially with ocular conditions like regular and irregular astigmatism, corneal diseases, and in patients with previous corneal refractive surgery, the size of the optical zone as well as the corneal aberrometry have to be taken into consideration. Depending on this and the patient's expectation, monofocal, trifocal, and panfocal IOLs as well as EDOF (here especially nondiffractive technology) IOLs are available to the surgeon.

Conclusion

Cataract surgery after refractive surgery remains a challenge. But the development and introduction of new technologies, like ray tracing, helps us to measure the changes in corneal tomography and to incorporate them into our calculations. New formulas have also been developed to increase precision. Nevertheless, there may be refractive surprises and dissatisfied patients, and these have to be treated accordingly.

References

1. Melles RB, Holladay JT, Chang WJ. Accuracy of intraocular lens calculation formulas. *Ophthalmology* 2018; 125:169-178.
2. Cho K, Lim DH, Yang CM, Chung ES, Chung TY. Comparison of intraocular lens power calculation methods following myopic laser refractive surgery: new options using a rotating Scheimpflug camera. *Korean J Ophthalmol*. 2018; 32(6):497-505.
3. Lwowski C, Pawlowicz K, Hinzelmann L, Adas M, Kohnen T. Prediction accuracy of IOL calculation formulas using the ASCRS online calculator for a diffractive extended depth-of-focus IOL after myopic laser in situ keratomileusis. *J Cataract Refract Surg*. 2020; 46:1240-1246.

Where Is Refractive Surgery Going From Now?

Jorge L Alio MD PhD FEBO

Refractive surgery today offers emerging innovations that will affect the immediate future of the practice of the subspecialty as well as the long-term development of new refractive surgery technology.

The most recent innovations are primarily happening in the area of new diagnostic preoperative studies of the candidate for refractive surgery. Factors such as corneal asphericity and level of aberrations, lens densitometry, anatomy of the anterior chamber, quality of the retinal image, total eye aberrometry, pupillometry, and others influence the outcomes, and the control of these variables is especially important when the idea is to provide the patient with the highest possible quality of vision.

The development of integrated diagnostic imaging with the objective of an improved and optimal retinal image is probably the most ambitious project, as it aims to unify all this information into a single concept that will help guide the refractive surgeon. With these integrated diagnostics, an artificial intelligence algorithm[1] will guide the decision about whether corneal refractive or lens refractive surgery is indicated. It will also guide the design of phakic IOLs. The type of ablation and the technique to use will be decided by this algorithm, managing the risk–benefit ratio of the particular case. All this integrated analysis will eliminate part of the risk of mistaken indications based on misinterpretation of the diagnostic tools and promote a further step in the practice of refractive surgery, targeting a predicted quality of retinal image that obviously will influence the subjective quality of vision and patient satisfaction.

The other area in which refractive surgery is progressing now is in the area of lasers and lenses. Corneal refractive surgery has reached unprecedented levels of precision and safety.[2,3] The emergence of intralamellar surgical procedures—applied to myopia, hyperopia, and astigmatism and in part to presbyopia correction—can offer also a further predictive factor that should be estimated preoperatively in order to choose the most adequate technique. Developments in interlamellar surgery include intracorneal lenticular extraction or tissue vaporization in the form of plasma created by the laser. Lasers are using less energy and more predictable patterns, which create a better, less invasive, and much more customized ablation profile in order to create a more adequate cornea for the purpose of achieving the best vision performance. This progress is taking place both in excimer lasers and femtosecond laser technology. Other technologies will emerge that could be applicable to this improved approach.

Concerning IOLs, a major step forward has been made with the recent development of phakic lenses, which are much safer and better designed for the purpose of refractive and visual optimization. Phakic lenses at this moment are limited to iris-supported and posterior chamber models. When correctly indicated, both provide adequate levels of safety and precision. Soon phakic IOLs will probably offer an innovative alternative for the correction of presbyopia.[4]

Concerning pseudophakic lenses, lenticular surgery has made tremendous progress, including new technologies for premium presbyopia lenses. Both diffractive and refractive lenses are competing to provide adequate levels of vision for all distances, while the recently developed extended-depth-of-field lenses, which is a very broad concept, has emerged as an alternative.[5] Recent designs concerning the extension of wavefront, customized use of spherical aberration at different levels, new refractive technologies to distribute the light forming the retinal image, and all of them inducing the minimal or null optic phenomena are going to lead our practice in the future.

In general, we are facing a decade of innovations in the integration of diagnostic methods, guiding us to use better lasers with better performance and improved phakic lenses and pseudophakic premium lenses that are more sophisticated in terms of optical design, all of which will eliminate most of today's existing optical side effects.

A brilliant technological future is waiting for the refractive surgeon.

References

1. Benet D, Pellicer-Valero OJ. Artificial intelligence: the unstoppable revolution in ophthalmology. *Surv Ophthalmol*. Epub ahead of print 2021 Mar 16:S0039-6257(21)00076-X. doi: 10.1016/j.survophthal.2021.03.003.
2. Kim TI, Alió Del Barrio JL, Wilkins M, Cochener B, Ang M. Refractive surgery. *Lancet* 2019; 393(10185):2085-2098.
3. El Bahrawy M, Alió JL. Excimer laser 6(th) generation: state of the art and refractive surgical outcomes. *Eye Vis (Lond)*. 2015; 2:6.
4. Schmid R, Luedtke H. A novel concept of correcting presbyopia: first clinical results with a phakic diffractive intraocular lens. *Clin Ophthalmol*. 2020; 14:2011-2019.
5. Alio JL; Pikkel J. *Multifocal Intraocular Lenses. The Art and the Practice*. 2nd ed. Springer; 2019. ISBN: 978-3-030-21281-0.

Monofocal+ IOL: The New Standard?

Gerd U Auffarth MD

I. New types of "NextGen" monofocal IOLs based on different optical principles have been developed by different manufacturers. (Not all are approved in the USA yet.)

A. The category is called "enhanced monofocals" or "monofocal+ IOLs."

B. In addition to standard monofocal, the new IOLs offer a small but significant amount of increased depth of focus (DOF).

C. These IOLs are identical to their previous monofocal platform.

D. Several laboratory and clinical studies could prove the optical concepts and clinical performance.

1. The Eyehance DIB00 (Manufacturer: J&J) enhanced monofocal IOL is based on a high aspheric optic with continuous power development from the center to the periphery.

a. Optical bench testing showed an extended DOF of 0.75 to 1.25 D on the 0.1 logMAR level.

b. This DOF effect contributes to a better refractive outcome and broader landing zone for IOL calculation.

c. This enhanced monofocal IOL has the same dysphotopsia profile as a normal monofocal IOL.

2. The LuxSmart IOL (Manufacturer: B+L) has a 2-mm DOF zone consisting of spherical aberration of 4th and 6th order of opposite forsign.

a. This increases the DOF by 118%, as laboratory studies could show.

b. Clinical defocus curves confirm the optical bench data.

3. There are several new IOLs on the market in Europe that will be shown and displayed in the lecture.

4. Overall, the new types of enhanced monofocal/monofocal+ IOLs will replace currently available standard aspheric monofocal IOLs in the future. Their characteristics are as follows:

a. Enhanced DOF of around 1-1.25 D (less than established EDOF IOLs)

b. Better forgiveness in IOL calculation

c. Same dysphotopsia profile then conventional monofocal IOLs

State of the Union: Innovation

William J Link PhD

Innovation in refractive surgery began in the 1970s, accelerated in the 1980s, and continues to this day. Forward-thinking ophthalmic surgeons and creative innovators have engaged to develop surgical concepts that would compete with and potentially eliminate the need for spectacles and contact lenses. The cornea was the initial target in refractive surgery as the primary "refractive" component in our visual system. In the early 1970s, radial keratotomy (RK) was conceived and refined by Svyatorslav Fyoderov MD, director of the Moscow Research Institute of Eye Microsurgery. Fyoderov trained many surgeons who, in turn, brought RK to countries around the world.

The impact and the limitations of RK brought a cascade of innovations to corneal refractive surgery. First, the excimer laser and photorefractive keratectomy (PRK). Then mechanical microkeratomes enabled LASIK. Of course, then came the femtosecond laser, enabling all-laser LASIK, followed by SMILE.

As innovation in corneal refractive surgery progressed, a major focus developed to improve visual outcomes with cataract surgery, IOLs, the ocular surface, and pharmaceutical therapies. In the 1990s a reimbursement breakthrough occurred, allowing cataract patients to use cash pay for improved visual outcomes to reduce or eliminate the postoperative need for spectacle lenses. A key principle underlying innovation is that resources are directed where they are rewarded. Clearly, cash pay has facilitated innovation in refractive cataract surgery as it has in corneal refractive surgery.

The field of ophthalmology is one of the most innovative medical specialties. There are 4 constituents required for innovation: (1) inventors and entrepreneurs, (2) leading surgeons, (3) sources of capital, and (4) industry leaders. In our field, there is excellent collaboration among these 4 constituents.

Innovation in refractive surgery has solid momentum. The pipeline for future innovation is richly populated with promising technologies. In the coming years, millions of patients will benefit from our commitment to innovation in refractive surgery.

Introduction & Global Challenges

How to Further Unlock Innovation in Ophthalmology

Jim Mazzo

Introduction

While the level of innovation and sophistication in ophthalmology is impressive, in particular in the last decade, more can be done to spur both innovation and growth in the field. Mr. Mazzo's talk addresses three key challenges in ophthalmology and how the ophthalmic industry can begin to better adopt and foster innovation as a means to accelerate the pace of innovation and growth.

The Role of Artificial Intelligence in Refractive Surgery Diagnostics

Marcony R Santhiago MD

NOTES

Pharmaceutical Treatment for Presbyopia

Jennifer M Loh MD

NOTES

Femto Lenticular Corneal Shaping

Theo Seiler MD PhD

The procedure for manually removing an intrastromal lenticule cut out with the femtosecond laser (stromal lenticule extraction, or SLE) has been used for more than 10 years successfully to correct myopia and myopic astigmatism. Hitherto, it was known as "small-incision lenticule extraction" (SMILE), but this term is today restricted to the use of a Zeiss laser.

The clinical advantages of SLE are a refractive success rate close to that of LASIK, fewer dry eyes, and enhanced residual stromal thickness. But there are also significant disadvantages compared to LASIK, such as delayed visual rehabilitation, lack of automated centration and cyclotorsion control, longer learning curve, and unclear complication management.

In 2020, two more femtosecond laser systems have arrived—ATOS (Schwind; Germany), providing Smart Sight, and Z8 (Ziemer; Switzerland), providing CLEAR. Both laser systems support automated centration, cyclotorsion control, and by a second incision, a shorter learning curve). Early encouraging results of the prospective pilot studies will be presented and discussed.

Femtosecond Laser–Induced Change of Refractive Index

Liliana Werner MD PhD

Introduction

Despite the many advances in cataract surgery, incorrect IOL power has historically been a significant issue, and it remains one of the most frequent causes of IOL exchange. There are still some factors involved in cataract surgery and IOL power calculation over which we do not have full control, such as unpredictable effects of wound healing or long-term changes of the capsule. Therefore, the ability to change the IOL power in a noninvasive manner in the postoperative period is considered a highly suitable feature.[1] The company Perfect Lens in California developed a technology that makes this possible through the use of a femtosecond laser.

Background Observations

Previous studies described the overall principles of this technology.[2,3] The laser uses green light and operates at much lower energy levels than those required for ablation or cutting. This technology can be used with acrylic IOLs already available on the market. The laser induces a chemical reaction in a specific area within the substance of the IOL. In this area, there is an increase in hydrophilicity, with a decrease in the refractive index. The treated area is shaped like an IOL within the substance of the original lens. At the molecular level, when the IOL polymeric material is exposed to the laser, there is a hydrolysis with the formation of hydrophilic functional groups. As the lens is in an aqueous medium, hydrogen bonds will form between water molecules and new functional groups, while the integrity of the polymeric material is preserved.

The shape of the treatment is called phase wrapping, and through it we can obtain significant refractive changes, treating only a very thin area inside the lens. As the treated area is very thin, several other corrections can be made later using areas above or below the initial area. If a multifocal pattern has been added but the patient does not adapt to it, this pattern can be canceled with one with characteristics opposite to those of the initial pattern. In this specific indication, the treatment can be performed in an area above, below, or even in the area of the initial treatment. Although the laser application is fast and can be done with topical anesthesia, the IOL changes do not occur immediately, as they depend on the complete hydration of the treated area within the lens. Complete hydration will be reached at different time points, depending on the base material of the IOL.

This treatment can be used for astigmatism corrections, after the IOL is well stabilized inside the capsular bag. Even high levels of customized toricity can be achieved. Significant amounts of asphericity can also be provided to the IOL, and the amount will be based on the spherical aberration of the cornea and the amount of residual spherical aberration the ophthalmologist would like to have for each patient. In the future, this technique will be used to correct any aberrations of the eye, in association with wavefront.

We have evaluated the IOL power, modulation transfer function (MTF), light transmission, and light scattering of a blue light-filtering IOL before and after power adjustment by the femtosecond laser.[4] Ten single-piece yellow hydrophobic acrylic IOLs were used in this study. The IOL power and MTF were measured with a power and modulation transfer function device. Light transmission was measured using a Lambda 35 UV-VIS spectrophotometer. Backlight scattering was assessed with a Scheimpflug camera within the IOL substance. All measurements were done with hydrated IOLs. The IOLs were also evaluated under light microscopy before and after laser adjustment. A mean power change of –2.037 D was associated with a MTF change of –0.064 and a light transmittance change of –1.4%. Backlight scattering increased within the IOL optic in the zone corresponding to the laser treatment at levels that are not expected to be clinically significant. Treated areas within the optic could be well appreciated under light microscopy without damage to the IOLs.

We have also evaluated the biocompatibility (uveal and capsular) of IOL power adjustment by the femtosecond laser in vivo, using the rabbit model.[5] Six rabbits had phacoemulsification with bilateral implantation of a commercially available hydrophobic acrylic IOL. The postoperative power adjustment was performed 2 weeks after implantation in 1 eye of each rabbit. The animals were followed clinically for an additional 2 weeks and then euthanized. Their globes were enucleated and bisected coronally just anterior to the equator for gross examination from the Miyake-Apple view to assess capsular bag opacification. After IOL explantation for power measurements, the globes were sectioned and processed for standard histopathology. Slit-lamp examinations performed after the laser treatments showed the formation of small gas bubbles behind the lenses that disappeared within a few hours. No postoperative inflammation or toxicity was observed in the laser-treated eyes, and postoperative outcomes and histopathological examination results were similar to those in untreated eyes. The power measurements showed that the change in power obtained was consistent and within ±0.1 D of the target.

Similar findings were observed in a long-term rabbit study (follow-up of 6 months after laser treatment). Clinical studies on this technique have already started in Panama but unfortunately had to be stopped due to the COVID-19 pandemic. They are expected to resume soon.

Conclusions

Consistent and precise power changes can be induced in the optic of commercially available IOLs in vivo by using a femtosecond laser to create a refractive-index shaping lens. The laser treatment of the IOLs is biocompatible and does not significantly affect the quality of the IOL.

References

1. Ford J, Werner L, Mamalis N. Adjustable intraocular lens power technology. *J Cataract Refract Surg*. 2014; 40(7):1205-1223.
2. Bille JF, Engelhardt J, Volpp HR, et al. Chemical basis for alteration of an intraocular lens using a femtosecond laser. *Biomed Opt Express*. 2017; 8(3):1390-1404.
3. Sahler R, Bille JF, Enright S, Chhoeung S, Chan K. Creation of a refractive lens within an existing intraocular lens using a femtosecond laser. *J Cataract Refract Surg*. 2016; 42(8):1207-1215.
4. Nguyen J, Werner L, Ludlow J, et al. Intraocular lens power adjustment by a femtosecond laser: in vitro evaluation of power change, modulation transfer function, light transmission, and light scattering in a blue light-filtering lens. *J Cataract Refract Surg*. 2018; 44(2):226-230.
5. Werner L, Ludlow J, Nguyen J, et al. Biocompatibility of intraocular lens power adjustment using a femtosecond laser in a rabbit model. *J Cataract Refract Surg*. 2017; 43(8):1100-1106.

Laser-Generated Aperture to Extend Depth of Focus

Omid Kermani MD, H Burkhard Dick MD, and Holger Lubatschowski PhD

Small-Aperture IOLs and Depth of Focus

Optical principle

The optical principle of a small-aperture or pinhole effect is already well known from photography, where the depth of field (DOF) of the image can be adjusted by changing the aperture (f-number). Following the laws of optics, the smaller the aperture, the wider the depth of field increases (see Figure 1).

Figure 1. Two photos of the same flower taken with a large aperture (shallow depth of field, left) and a small aperture (wide depth of field, right). Source: Lys Olson and Braden Van Dragt. Understanding exposure in photography. REI website. www.rei.com/learn/expert-advice/understanding-exposure-in-photography.html

The optical principle of DOF extension by small-aperture IOLs is illustrated in Figure 2. In eyes with monofocal IOLs fixed for good far distance, near vision is blurred due to the lack of ability to accommodate the lens. By applying a small aperture into the IOL, the DOF will be increased. As a consequence, the range of vision will significantly increase, resulting in sharp images for near and distant objects.

Another positive effect on the image quality with a small aperture is its major impact on spherical aberration. Since aberrations are becoming stronger and stronger toward the periphery of the cornea, the small aperture will also reduce the perception of these disturbing peripheral light rays

Current small-aperture implants on the market

Currently 2 companies have small-aperture implants on the market, the U.S. company AcuFocus, Inc. and the German company Morcher GmbH.

AcuFocus, Inc. was the first company to introduce the principle of small aperture in implants for the eye. The first implant on the market was the Kamra Inlay, a corneal implant, with the intention to improve near vision in patients with presbyopia. More than 60,000 Kamra inlays have already been implanted. (The Kamra Inlay has now been acquired by CorneaGen.)

As a next step, AcuFocus launched an IOL for cataract patients (IC-8TM), which obtained CE approval in Europe in 2014. The IC-8 has a free inner diameter (= aperture) of 1.36 mm and an outer diameter of 3.23 mm (see Figure 3). First clinical data for this lens are already available[1-3] or under investigation.[4] So far, the IC-8 has shown excellent visual performance, safety, patient satisfaction, and tolerance to residual astigmatism.

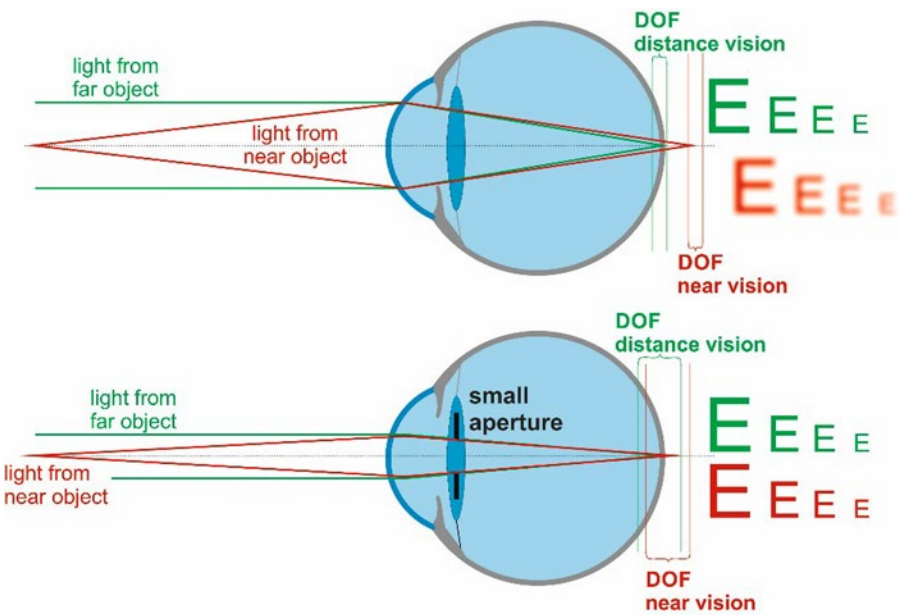

Figure 2. On monofocal IOLs, near vision is blurred, making it difficult to see near objects without glasses. A small aperture placed into the IOL extends the depth of focus (DOF) significantly, resulting in sharp images for near and distant objects.

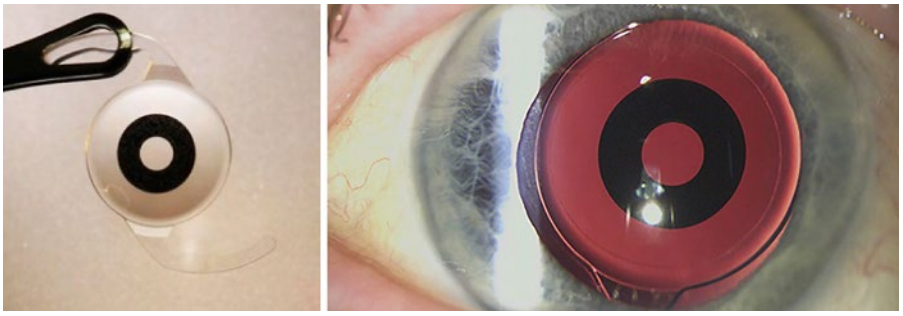

Figure 3. The IC-8 IOL, manufactured by Acufocus, Inc. Source left: http://www.newtechspa.it. Source right: Dick HB, Piovella M, Vukich J, et al. Prospective multicenter trial of a small-aperture intraocular lens in cataract surgery. *J Cataract Refract Surg.* 2017; 43(7):956-968.

The second small-aperture IOL available on the market is the Xtrafocus from Morcher. The main indications for this IOL, in addition to DOF enhancement, are the treatment of irregular corneal astigmatism and the reduction of halos, glare, or shadows in the field of view after cataract surgery.

Raised and resolved clinical concerns of small-aperture implants

A few concerns have been raised in regard to the clinical use of small apertures. One concern has been poor night vision due to the small aperture. The eye can regulate the amount of light that reaches the retina by adjusting the size of the pupil. In general, in dark environments, the pupil gets wider to allow more light to enter the eye. With a small aperture in the IOL, the opening allowing the light to enter is restricted to the size of the aperture. The concern was that this would cause problems for patients in dark environments (scotopic vision).

However, this is not the case. The range, the incident amount of light that can be regulated by narrowing or widening the pupil, is about 1:10. Retinal adaptation, on the other hand, makes it possible to process light stimuli of many orders of magnitude: the difference between seeing weakly shining stars in the night sky and detecting traces in the snow in bright sunlight covers a range of about 1:109 (1:1 billion). This is also confirmed by patients who have already received a small aperture.5,6 After a certain adaptation period of a few weeks, during which the retina learns to compensate for the pupil adaptation, the IOL wearers no longer notice any difference.

Another concern was whether the small aperture impacts the access to retinal images when patients require fundus examination or vitreoretinal surgeries. Here it could be demonstrated that fundus examinations can be well carried out through the aperture or at the side of the aperture.[7] In a rabbit eyes study, view and ease of performing retinal procedures on implanted IC-8 were compared to those implanted with a monofocal or multifocal IOL. The mean scores of the surgeons for image quality were the same for all three types of IOL.[8]

Finally, it could be demonstrated that the inlay aperture does not seem to interfere with the field of view.[9]

Existing problems with small-aperture implants

The success of improving near vision with small-aperture implants has been well demonstrated with clinical data from the Kamra inlay, the IC-8, and the Xtrafocus. However, all existing small-aperture implants have their limitations.

The corneal implant, the Kamra inlay, is dealing with considerable wound healing problems in the cornea. Consequently, a large number of implants had to be removed again, which of course led to a considerable decrease in acceptance by physicians.

The IOL implants, the IC-8 and the Xtrafocus, have the advantage of not facing the problem related to wound healing. Another advantage of the IOL implants compared to the corneal implants is the better optical performance because the aperture is located closer to the nodal point of the eye.

However, there is another big challenge for the small-aperture IOLs, which is the centration of the implant in the eye. As a rule, IOLs (so the IC-8) are implanted into the remaining capsular bag of the crystalline lens. During implantation the pupil is dilated, and it is not easy to center the aperture. Due to centration difficulties, the position of the IOL is not always optimal (Figure 4). In addition, even if the IOL is well positioned, during the first 3 months postoperatively, the capsular bag and the zonular fibers holding the IOL may change shape and thus bring the IOL into a new position. The optical elements of the eye (cornea, pupil, IOL aperture, fovea) are then no longer on axis, and the image quality is reduced accordingly. This effect will be particularly annoying with a small-aperture device.

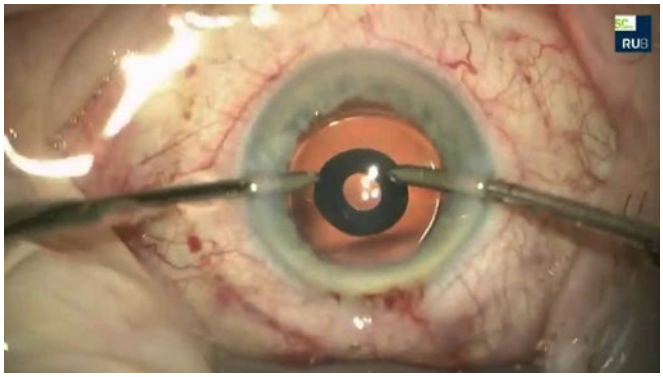

Fig. 4 During implantation the pupil is dilated. Accordingly, it is not easy to center the aperture in the capsular bag. Neither the pupil nor the visual axis of the patient can be used in this situation. Image is a screen shot from a video produced by B. Dick, "Implantation einer IC-8 small-aperture extended depth-of-focus Intraokularlinse mit LCS," June 18, 2015, https://www.youtube.com/watch?v=rA25IyPzlC0.

Finally, the size of the aperture is only supplied in a standard geometry for the existing small-aperture implants on the market. An optimal adaptation to the requirements of different patient eyes, which would once again clearly emphasize the advantages of small aperture, is therefore not possible.

Femto-Masking

Femto-masking offers an elegant solution, noninvasively generating small apertures in IOLs, using a femtosecond laser system. By applying a certain configuration of laser pulses (energy, spot size, spot distance, repetition rate) depending on the lens material, a photochemical reaction can be induced that makes the material optically impermeable (blackening).

Mechanism of action

With the use of ultrashort laser pulses, it is possible to induce nonlinear absorption of the laser light in originally transparent materials or tissue via multiphoton processes. This process is known as photodisruption, where a plasma is generated that locally disrupts the material. The disruption effect is used in corneal surgery (preparation of flaps, tunnels and lenticules) and laser-assisted cataract surgery.

At laser intensities slightly below threshold for photodisruption, only a few free electrons are generated by the laser light, and these induce photochemical reactions without any disruptive effect. This means that only the chemical properties of the irradiated material can be permanently changed, with local control.

This subthreshold processing is currently being used by several startup companies—Perfect Lens and Clerio Vision (both U.S.), Medicem (Czech Republic), and LicriEye/Merck (Germany)—who are trying to change the refractive index on special IOL materials in order to make minor refractive power changes to readjust the refraction of an implanted IOL. This procedure can be regarded as very ambitious. In contrast to the generation of a small aperture, the laser pulses must be applied with extremely high accuracy and over the entire optical zone of the IOL.

Status of the technical development

By scanning the laser pulses inside the IOL, a mask with the shape of a pinhole similar to the IC-8 can be created (see Figure 5.1).

As a first lab experiment, different IOLs were irradiated with the Rowiak femtosecond laser to demonstrate the proof of concept. In Figure 5.2, the laser effect inside the lens material on a selection of commercially available IOLs is shown. Figure 5.3 shows a Rayner IOL with maximum illumination from the back side. The illumination intensity was set until just before saturation of the camera sensor. As it can be easily seen, the processed area is optically sealed. The fact that the masks have different color impressions is due to the different material compositions of the IOLs. No other changes were detected on the irradiated samples. A toxicological examination of the irradiated area of the IOLs is currently under way.

The process works on the majority of all common IOL materials (perhaps even more; investigations are not yet completed). Thus it is possible to write arbitrary masks (apertures) in almost all implanted and still to be implanted IOLs.

With the currently used Femto Lentotomy laser system for presbyopia therapy, it takes approximately 1-2 minutes to generate a mask similar to IC-8. Theoretical considerations suggest that a technical upgrade of the laser system (laser source, scanner technology) can even reduce the processing time.



Figure 5. Comparison of an original AcuFocus, IC-8 IOL with a small aperture by design and an AcrySof Single-Piece Acrylic lens SA60AT from Alcon with a subsequently lasered small aperture. More than 70 million AcrySof lenses of this type alone have been used worldwide to date.

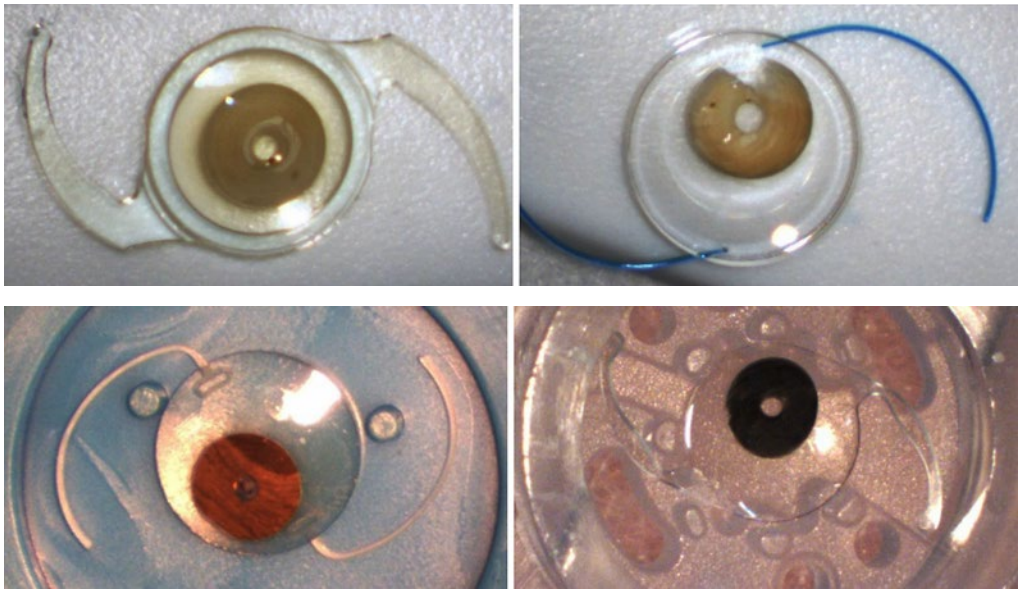

Figure 6. Four examples of commercially available monofocal IOLs with a laser generated small aperture inside the lens material to demonstrate proof of concept. Top left, B1ADY0-Basis Z/1stQ GmbH; top right, Sensar-AR40M (J&J). Bottom left, Tecnis Model: Z9000/J&J; bottom right, Alcon SA60AT.



Figure 7. Left: Laser-processed Rayner hydrophobic IOL with maximum back illumination to demonstrate opaqueness. Right: Magnification of the inner part of the laser-marked IOL. A slight fraying of the inner edge can be seen, which does not play a role optically or clinically.

Advantages of Femto-Masking

Femto-Masking can turn a monofocal IOL into a premium lens in less than 2 minutes. Due to the noninvasive nature of the procedure, no sterile operation room is necessary, and it can be offered as in-office procedure.

Compared to small-aperture IOLs, which can only be roughly centered within a dilated pupil, the laser-generated mask can be easily and precisely centered along the visual axis of the patient's eye. A well-centered aperture means maximized efficiency of the applied pinhole principle and consequently a higher patient satisfaction.

Moreover, because the mask generation will be performed at least 3 months after IOL implantation, when the conditions of the eye are stable, no postoperative decentration due to capsule shrinkage will be expected. Femto-Masking offers a solution both for cataract patients about to undergo surgery and patients with already implanted IOLs wishing to improve their near vision.

In contrast to available small-aperture implants on the market, Femto-Masking offers complete flexibility in terms of customization of the aperture. It means that each laser-generated mask can follow the patient's needs regarding size and shape of the aperture, which would emphasize even more the advantages of small aperture as a premium IOL solution.

Risks with Femto-Masking

Potential risks for a new medical application include (1) technical feasibility, (2) demonstration of performance, and (3) safety of the device and procedure.

1. Regarding the technical feasibility of the laser system, the risk is extremely low. The mask could already be created with the existing femtosecond laser for presbyopia therapy, where this process took only less than 2 minutes. The extremely high accuracy required, for example, by systems for changing the refractive index of the IOL is far from being required for Femto-Masking.
2. The clinical performance of small apertures has already been demonstrated as an inlay in the cornea and as a small aperture integrated in a monofocal IOL. Certainly, a clinical investigation will still be required. However, the excellent clinical performance and efficacy of Femto-Masking can be predicted from the clinical data already available on the Kamra inlay, IC-8, and Xtrafocus.
3. In terms of safety, there are at least 3 concerns. First, the used laser radiation has to be safe for the retina. For this, an optical radiation safety analysis has been carried out, which showed no safety issues for the used laser parameter.

The second safety issue is the biocompatibility of the processed IOL material. The laser-generated layer that leads to darkening is only a few micrometers thick within an IOL that is several hundred micrometers thick, and the entire manipulation process for mask generation takes place inside the IOL. Nonetheless, it has to be demonstrated that the irradiated areas do not emerge from the lens material (eg, by outgassing) and the products are expected to be biocompatible and nontoxic. Proof is currently under investigation.

Finally, the long-term behavior of the darkened areas must be controlled to ensure that they do not bleach. This will be tested before human application of Femto-Masking. In the worst case, a follow-up or refresh treatment with a laser would be necessary and is possible.

References

1. Agarwal A, Thornell EM. Cataract surgery with a small-aperture intraocular lens after previous corneal refractive surgery. *J Cataract Refract Surg*. 2018; 44(9):1150-1154.
2. Dick HB, Piovella M, Vukich J, et al. Prospective multicenter trial of a small-aperture intraocular lens in cataract surgery. *J Cataract Refract Surg*. 2017; 43(7):956-968.
3. Grabner G, Ang RE, Vilupuru S. The small-aperture IC-8 intraocular lens: a new concept for added depth of focus in cataract patients. *Am J Ophthalmol*. 2015; 160(6):1176-1184.e.1.
4. Evaluation of long-term clinical acceptability and satisfaction with the IC-8 intraocular lens. ClinicalTrials.gov identifier: NCT03314766; and Clinical evaluation of a small aperture extended depth of focus intraocular lens. ClinicalTrials.gov identifier NCT03633695.
5. Artal P, Manzanera S. Perceived brightness with small apertures. *J Cataract Refract Surg*. 2018; 44(6):734-737.
6. Manzanera S, Webb K, Artal P. Adaptation to brightness perception in patients implanted with a small aperture. 2019; 197:36-44.
7. Inoue M, Bissen-Miyajima H, Arai H, Hirakata A. Retinal images viewed through a small aperture corneal inlay. 2014; 92(2):e168-169.
8. Empey G, Kuppermann B, Bababeygy SR, Gwon A. Evaluation of vitreoretinal surgery through a hydrophobic small aperture intraocular lens in New Zealand black rabbits. *Invest Ophthalmol Vis Sci*. 2015; 56:2988.
9. Atchison DA, Blazaki S, Suheimat M, Plainis S, Charman WN. Do small-aperture presbyopic corrections influence the visual field? *Ophthalmic Physiol Opt*. 2016; 36(1):51-59.

Financial Disclosure

The Academy has a profound duty to its members, the larger medical community and the public to ensure the integrity of all of its scientific, educational, advocacy and consumer information activities and materials. **Thus each Academy Trustee, Secretary, committee Chair, committee member, taskforce chair, taskforce member, councilor, and representative to other organizations ("Academy Leader"), as well as the Academy staff and those responsible for organizing and presenting CME activities must disclose interactions with Companies and manage conflicts of interest or the appearance of conflicts of interest that affect this integrity. Where such conflicts or perceived conflicts exist, they must be appropriately and fully disclosed and resolved.**

All contributors to Academy educational and leadership activities must disclose all financial relationships (defined below) to the Academy annually. The ACCME requires the Academy to disclose the following to participants prior to the activity:

- All financial relationships with Commercial Companies that contributors and their immediate family have had within the previous 12 months. A commercial company is any entity producing, marketing, re-selling or distributing health care goods or services consumed by, or used on, patients.
- Meeting presenters, authors, contributors or reviewers who report they have no known financial relationships to disclose.

The Academy will request disclosure information from meeting presenters, authors, contributors or reviewers, committee members, Board of Trustees, and others involved in Academy leadership activities ("Contributors") annually. Disclosure information will be kept on file and used during the calendar year in which it was collected for all Academy activities. Updates to the disclosure information file should be made whenever there is a change. At the time of submission of a Journal article or materials for an educational activity or nomination to a leadership position, each Contributor should specifically review his/her statement on file and notify the Academy of any changes to his/her financial disclosures. These requirements apply to relationships that are in place at the time of or were in place 12 months preceding the presentation, publication submission, or nomination to a leadership position. Any financial relationship that may constitute a conflict of interest will be resolved prior to the delivery of the activity.

Visit www.aao.org/about/policies for the Academy's policy on identifying and resolving conflicts of interest.

Financial Relationship Disclosure

For purposes of this disclosure, a known financial relationship is defined as any financial gain or expectancy of financial gain brought to the Contributor or the Contributor's immediate family (defined as spouse, domestic partner, parent, child or spouse of child, or sibling or spouse of sibling of the Contributor) by:

- Direct or indirect compensation;
- Ownership of stock in the producing company;
- Stock options and/or warrants in the producing company, even if they have not been exercised or they are not currently exercisable;
- Financial support or funding to the investigator, including research support from government agencies (e.g., NIH), device manufacturers, and\or pharmaceutical companies; or
- Involvement with any for-profit corporation that is likely to become involved in activities directly impacting the Academy where the Contributor or the Contributor's family is a director or recipient

Description of Financial Interests

Category	Code	Description
Consultant / Advisor	C	Consultant fee, paid advisory boards or fees for attending a meeting
Employee	E	Employed by a commercial company
Lecture Fees	L	Lecture and speakers bureau fees (honoraria), travel fees or reimbursements when speaking at the invitation of a commercial company
Equity Owner	O	Equity ownership/stock options (publicly or privately traded firms, excluding mutual funds)
Patents / Royalty	P	Patents and/or royalties that might be viewed as creating a potential conflict of interest
Grant Support	S	Grant support from all sources

Financial Disclosures

Amar Agarwal MD
Jaypee-Highlights Medical Publishers: P
SLACK Incorporated: P
Staar Surgical: C
Thieme Medical Publishers: P

Ashvin Agarwal MD
Elisar: O

Jorge L Alio MD PhD
None

Renato Ambrósio Jr MD
Alcon Laboratories, Inc.: C
Allergan: L
Carl Zeiss, Inc.: L
Essilor Instruments: L
Genom: C
Mediphacos: L
Oculus, Inc.: C

Robert Edward T Ang MD
Acevision: S
AcuFocus, Inc.: C,L,S
Alcon Laboratories, Inc.: L
Bausch + Lomb Surgical: C,L,S
Glaukos Corp.: S
Ivantis: S
Johnson & Johnson Vision: L,S
Physiol: L,S
Staar Surgical: S

Gerd U Auffarth MD
Abbott: C,L,S
AcuFocus, Inc.: S
Alcon Laboratories, Inc.: C,L,S
Alimera Sciences, Inc.: S
Anew: S
Biotech Europe Meditech, Inc. Ltd.: S
Carl Zeiss, Inc.: L,S
Contacmac, England: S
HEIKA, Heidelberg-Karlsruhe University Research Program: S
Hoya, Japan: L,S
Klaus Tschira Foundation, Germany: S
Novartis Pharmaceuticals Corp.: S
Oculentis GmbH, Germany: L,S
Oculus, Inc.: L,S
PhysIOL, Belgium: S
Rayner Intraocular Lenses Ltd.: S
Santen, Inc.: S
SIF Ltd. Italy: S
Ursapharm: L,S

Shady T Awwad MD
Bausch + Lomb: L

Francesco Carones MD
Alcon Laboratories, Inc.: C
Beaver-Visitec International, Inc.: C
Carl Zeiss Inc: C
CSO Strumenti Oftalmici: C
HOYA: C
Johnson & Johnson Vision: C
Percept Corp.: C
SLACK Incorporated: C
Staar Surgical: L
Vivior: C
WaveLight AG: C

Lorenzo J Cervantes MD
Eversight: C
Eyevance: C

David F Chang MD
Beyeonics: C,O
Carl Zeiss, Inc.: C
Centricity: C,O
Eyenovia: O
Forsight Robotics: C,O
ForSight Vision 6: C,O
Iantrek: C,O
iDrops: C,O
Ivantis: C,O
JelliSee: C,O
Johnson & Johnson Vision: C
Long Bridge: C,O
Orasis: O
Perfect Lens: C,O
Presbyopia Therapies: O
RX Sight: C,O
SLACK, Incorporated: P
Surface, Inc.: O
Versant Ventures: O
Viewpoint: C,O
Visionary Ventures II: O

Steven J Dell MD
Johnson & Johnson Vision: C

Deepinder K Dhaliwal MD LAc
Allergan, Inc.: C
Avedro, Inc.: S
Haag-Streit Group: C
Horizon: C
Johnson & Johnson: C
Novartis: C,S
Noveome: S
Ocular Therapeutix: L,C
Staar Surgical: L
Trefoil: C

Burkhard Dick MD
Avedro, Inc.: C
Bausch + Lomb: L
Johnson & Johnson Vision: C
Johnson & Johnson: L
Oculus Surgical, Inc.: P
RxSight, Inc.: C

John F Doane MD
Carl Zeiss Meditec: C
Iveena: O
Presbyopia Therapies: O
RxSight: C

Eric D Donnenfeld MD
Alcon Laboratories, Inc.: C
Allergan: C,L
Avellino Labs: C
Bausch + Lomb: C
Beaver-Visitec International, Inc.: C
BlephEX, LLC: C,O
CorneaGen: C,O
Eyepoint Pharma: C
Glaukos Corp.: C
Ivantis: C
Johnson & Johnson: C
Katena Products, Inc.: C,O
LacriScience, LLC: C,O
Mynosis: C,O
Novartis Pharma AG: C
Ocular Therapeutix: C
Omeros Corp.: C
PRN Physician Recommended Nutriceuticals: C,O
TLC Laser Center: C
Zeiss: C

Farideh Doroodgar MD
None

Daniel S Durrie MD
AcuFocus, Inc.: C,O
Alcon Laboratories, Inc.: C
Alphaeon: O
Concierge Key Health: C,O
Eyegate Pharma: C
Gebauer Medical: C
Glaukos Corp.: C,O
Hoopes Durrie Rivera Research Center: C
iOR Holdings: O
iOR Partners: E,O
Johnson & Johnson Vision: C
Schwind Eye-tech-Solutions GmbH: C
Staar Surgical: C
Strathspey Crown LLC: O

Nicole R Fram MD
Alcon Laboratories, Inc.: C,L
Allergan: C
Beaver-Visitec International, Inc.: L
CorneaGen: C,O,L
Dompé: C,L
Johnson & Johnson Vision: C
MicroSurgical Technology: L
Novartis Pharma AG: L
Ocular Science: O
Ocular Therapeutix: C,L

Ronald D Gerste MD
None

Andrzej Grzybowski MD
Pfizer, Inc.: L
Polpharma: L
Thea: L

Bonnie An Henderson MD
Alcon Laboratories, Inc.: C,L

Luis Izquierdo Jr MD
None

Pooja Khamar MBBS MS
None

Michael C Knorz MD
EuroEyes International Eye Clinic Ltd.: O

Thomas Kohnen MD PhD FEBO
Allergan Medical Affairs: C
Bausch + Lomb: C
Carl Zeiss Meditec: C,S
Dompé: C
Geuder: C
Hoya: S
Johnson & Johnson Vision (Abbott): C,S
MedUpdate: C
Merck & Co., Inc.: C
Novartis (Alcon): C,S
Oculentis: C,S
Oculus Optikgeräte: C,S
Presbia: C,S
Rayner Intraocular Lenses Ltd.: C
Santen, Inc.: C
Schwind eye-tech-solutions: C,S
Staar Surgical: C
TearLab Corp.: C
Thea Pharma: C
Thieme Compliance: C
Zeiss: C,S
Ziemer: C

Min Li MD
None

Richard L Lindstrom MD
AcuFocus, Inc.: C,O,P
Alcon Laboratories, Inc.: C
Allegro: C,O
Alphaeon: C,O
Aprea Therapeutics: O
Arixa: O,C
Augustine Temperature Management: O
Avellino Labs: C,O
Aviana: O
Bausch + Lomb: C,O,P
Belkin Laser: C,O
Broadspot: C,O
Bruder: O
Centricity Vision: C,O
Checked-Up: C,O
Combangio: C,O
Confluence Acquisition Partners, Inc.: O
CorneaGen: C,O
CXL, ESI: C,O
Digital Systems: O
Dose: C,O
E-Vision Medical Devices: O
E-Vision: O
EBV Partners: O
Egg Basket Ventures: O
Egg Factory: O
Equinox: C,O
Eton: O
Evolus: O
Excel-Lens, Inc.: O
Expert Opinion: C,O
Eye Safe: C,O
Eyemaginations, Inc.: C,O
Flying L Ventures: C,O
ForeSight #4: O
ForSight Vision 3, drug delivery posterior segment: O
ForSight Vision 6, accommodating IOL: C,O
Freedom Software: O
FZioMed, Inc.: O
Glaukos Corp: C,O
Gondola: O,C
Harrow Health: C,O,P
Health-E: C,O
Healthcare Transaction Services: C,O
High Performance Optics: O
Iantrek: O
IDoc, Inc.: O
Imprimis: C,O
InjectSense: C,O
Innovega: O
iOR: O,C
Johnson & Johnson Vision: C
KalaRx Pharmaceuticals: C,O
Kedallion: C,O
KeraFlow: C,O
Lensar: C,O
LenTechs: C,O
Lenticular Research Group: O
Lifeguard Health: C,O
Lumineyes: O
MD Backline: C,O
Melt: C,O
Minnesota Eye Consultants: C,O
NASA-Vision for Mars Program: C
Neurovision: C,O
New Sight Reality: O
Novabay: C,O
Nutraceutical Holdings: C,O
Ocular Optics: C,O
Ocular Surgery News/Slack: C
Ocular Therapeutix: C,O
Oculatec: O
Ocutryx: C,O
Omega Eye Health: C,O
Omega Ophthalmics: C,O
Omeros Corp.: C
Orasis: C,O
Oysterpoint: C,O
PogoTec: C,O
Q Sensei: O
Quest: C,O,P
Revana: O
RxSight: C,O
Schroeder Ventures Fund II, III, IV, VI: C,O
SightPath: C,O
Silk Technologies: C
Solbeam, Inc.: O
Strathsprey Crown: O
Stroma: O
SunPharma: C
Surface Pharmaceuticals: C,O
Tarsus: C,O
TearClear: C
TearLabs, Inc.: C,O
TearOptix: O,C
Theroptix: O,C
Tissue Tech: O
Tracey Technologies: C,O
True Iris: C,O
True Vision: C,O
Versant Fund Side Fund: C,O
Vinci: C,O
Viradax: O
Vision Solutions Technology: C,O
Visionary Ventures: C,O
Ziess: C

Jennifer M Loh MD
Aerie Pharmaceuticals, Inc.: L
Allergan: C
Bausch + Lomb: C
Eyepoint: C
EyeVance: C
Imprimis: C
Johnson & Johnson Vision: C
Kala Pharmaceuticals: L
Novabay: O
Novartis, Alcon Pharmaceuticals: C
Omeros Corp.: C
Orasis Pharmaceuticals: C
Sight Sciences: C,L,S
Sun Ophthalmics: C,L

Stephanie Jones Marioneaux MD
None

Erik L Mertens MD FRACOphth
C.S.O. Srl: C
Carl Zeiss Meditec: C
Hoya: C
Medicontur International SA: C Physiol: C
Staar Surgical: C

Majid Moshirfar MD
None

Priya Narang MS
None

Rudy Nuijts MD
Alcon Laboratories, Inc.: C,L,S
Carl Zeiss Meditec: S
Johnson & Johnson: S
Ophtec: L

J Bradley Randleman MD
None

Dan Z Reinstein MD
Arcscan, Inc.; Morrison, Colorado: O,P
Carl Zeiss Meditec: C
Optimo Medical AG: C

Karolinne M Rocha MD
Alcon Laboratories, Inc.: C
Allergan: C
Bausch + Lomb: C
Dompé: C
Johnson: C
LaserAce: C

Julie M Schallhorn MD
Carl Zeiss Meditec: C
Long Bridge: O
Vanda: C

Rohit Shetty MBBS
None

Priyanka Sood MD
Johnson & Johnson Vision: C
Novartis, Alcon Pharmaceuticals: C

Zeba A Syed MD
Bio-Tissue, Inc.: L
Dompé: S

Vance Michael Thompson MD
AcuFocus, Inc.: C,L,O
AI Optics: O
Alcon Laboratories, Inc.: C,L
Allergan: C
Allotex: C,O
Avellino Labs: C,O
Avisi Technologies, Inc.: C,O Bausch + Lomb: C
BRIM Biotechnology, Inc.: C
C.S.O. Srl: C
Carl Zeiss Inc.: C
Centricity Vision, Inc.: C,L,O
Conjtac: C,O
D & D Biopharmaceuticals: C,O
Equinox: C,O
Euclid Systems: C,L,O
Expert Opinion: C,O
eyeBrain Medical, Inc.: C,O
Eyedetec: C,O
Eyegate Pharma: C,O FemtoVision: C,O
Forsight Robotics: C,O
Glaukos Corp.: C,L
Healthe: C,L,O
Imprimis: C
iVeena: C,O
Johnson & Johnson Vision: C,L
Leica Microsystems: C
Melt Phamaceuticals: C,O
Ocular Innovations: C,O OneFocus: C,O
ORA: C
Oyster Point Pharma: C,O
Percept: C,O
Refocus Group: C
RxSight: C,O
Sight Sciences, Inc.: C,O
Stuart Therapeutics: C,O
Tarsus Rx: C,O
TearClear: C,O
TherOptix: C,O
Treehouse Health: C,O
Veracity: C,O
Visant: C,O
Visus: C
Vivior AG: C,O

William B Trattler MD
Abbott Medical Optics: C,L
Alcon Laboratories, Inc.: C
Allergan, Inc.: C,L,S
Alphaeon: O
ArcSCan: O
Avedro: C,L,O
Bausch + Lomb: C,L
CXLO: C,O
CXLUSA: C
EyeVance: C
Guardian Health: C,O
Healthe: O
Iantech: C,O
Kala: C,L
LensAR: C
Oculus, Inc.: L
Shire: C,L
Sun: C,L
Tarsus: C,O
True Vision: C,O

George O Waring IV MD
ACE Vision: C
Allergan: C,L
Avedro: C,L
Bausch + Lomb: C,L
Glaukos Corp.: C,L
Johnson & Johnson Vision: C,L
Novartis: C
Oculus, Inc.: C,L
Omega Ophthalmics: C
Omeros: C
Perfect Lens, LLC: C
SRD Vision: C
Strathspey Crown: O
Visiometrics: C,O
Zepto: C

Elizabeth Yeu MD
Alcon Laboratories, Inc.: C,L
Allergan: C,L
ArcScan: C
Bausch + Lomb: C
Bio-Tissue, Inc.: C,L
Carl Zeiss Meditec: C,L
Glaukos Corp.: C,L
Innovation Labs: O
iOptics: C,S
Johnson & Johnson Vision: C,L
Kala: C,S
Katena Products, Inc.: C
Melt: C,O
Modernizing Medicine: O
Novartis, Alcon Pharmaceuticals: C
Ocular Science: C,O
OcuSoft: C
Omeros: L
ScienceBased Health: C
Sight Sciences: C
Sun Ophthalmics: L
Surface: C
Tarsus: C,O
TearLab: C
TearScience: C
TissueTech, Inc.: C,L
Topcon Medical Systems, Inc.: S

Sonia H Yoo MD
Avedro, Inc.: C,S
Avellino Labs: S
Carl Zeiss Meditec: C
Dompé: C

Presenter Index

* Indicates that the presenter has financial disclosures. No asterisk indicates that the presenter has no financial interest.

Refractive Surgery ePosters

Refractive Surgery ePosters

View at www.aao.org/mobile.

ePosters are not eligible for CME credit.

Refractive Surgery ePosters

Friday–Monday, November 12–15

View at the ePoster terminals or www.aao.org/mobile.
ePosters are not eligible for CME credit.

Cataract & Refractive Lens Surgery

Innovation

JRS—Hot, Hotter, Hottest Late Breaking News

Laser Vision Correction

ePoster Abstracts

Cataract & Refractive Lens Surgery

Effective SMILE Treatment of Residual Refractive Errors in Pseudophakic Patients
RP30068447

Senior Author: Anita Syla Lokaj MD
Coauthors: Faruk Semiz MD, Anita D Lokaj II, Gulser Caliskan PhD, Giuseppe Verlato, Njomza Hima Musa, Zekeriya Alp Demirsoy, Ceren Ece Semiz, and Olcay Semiz

Purpose: This study aims to show that pseudophakic patients with residual myopic refraction increase both their vision and their satisfaction with SMILE surgery. **Methods:** 208 eyes of 150 consecutive patients who underwent pseudophakic (IOL) implantation such as trifocal, multifocal, and monofocal were included in this retrospective study. All residual myopic eyes underwent SMILE surgery. **Results:** The age of patients was between 53 and 82 years, and the preoperative residual myopic refraction was between −0.75 D and −5.50 D. 208 eyes were followed after SMILE for 2 years. There was a significant increase in uncorrected distance visual acuity, from 0.51 ± 0.18 to 0.01 ± 0.02 logMAR ($P < .001$). Moreover, patients' satisfaction improved. **Conclusion:** SMILE surgery is the most reliable method in the treatment of pseudophakic residual refractions. It also increases patient satisfaction and vision in a short time.

Comparative Outcomes in Refractive Lens Exchange: Bilateral Extended Depth of Focus IOL vs. Mix-and-Match Approach in Emmetropic Presbyopic Patients
RP30068473

Senior Author: Sofia Padilla II MD
Coauthors: Jose A Nava-Garcia MD, Julio Hernandez Camarena MD, Jorge E Valdez-Garcia MD, and Sara González Godinez MD

Purpose: To describe visual outcomes in emmetropic presbyopic patients who had refractive lens exchange (RELEX) with extended depth of focus (EDOF) IOL only vs. a mix-and-match approach. **Methods:** We evaluated presbyopic patients with axial length (AL) between 22 and 24 mm who had bilateral RELEX and divided them in 2 groups: EDOF only (n = 16 eyes) and mix and match (MaM): EDOF in the dominant eye and trifocal IOL in the fellow eye (n = 12 eyes). Visual and refractive outcomes were assessed 3 months postoperatively with corrected (CDVA) and undercorrected (UDVA) far visual acuity and undercorrected near visual acuity (UNVA), as well as residual spherical equivalent (SE). **Results:** For both groups, postoperative UNVA was 20/20 at 33 cm, and CDVA was 20/20. Residual mean SE was −0.25 D for the MaM group and −0.50 D for the EDOF-only group. **Conclusion:** Visual outcomes were similar in both groups. We observed similar results in visual acuity at both far and near in both groups.

SRK-T, Holliday, and Hoffer-Q IOL Formulas Compared in Keratoconus When Keratometry Was Adjusted by Tomography-Guided Data
RP30068475

Senior Author: A John Kanellopoulos MD

Purpose: Refractive accuracy of novel keratometry data used to adjust the SRK-T, Holliday, and Hoffer-Q formulas for toric IOL calculation (tIOLc) in keratoconus (KCN) was evaluated. **Methods:** Forty-two consecutive cases measured: with 3 different model interferometries for axial length, chamber depth, and keratometry. Additionally, with topography, tomography with both Scheimpflug and anterior segment-OCT. tIOLc was calculated with the SRK-T, Holliday, and Hoffer-Q formulas, adjusting the keratometric power and axis from data calculated by a tomography-guided excimer treatment plan at a 5-mm optical zone and compared. Postoperative clear-cornea cataract surgery uncorrected (UDVA) and corrected distance visual acuity (CDVA) and refraction were evaluated up to 12 months. **Results:** Holliday calculated the highest IOL spherical power and was preferred in order to avoid hyperopic surprises. Mean values change: UDVA from 20/400 to 20/32, CDVA: 20/50 to 20/24. Refraction in diopters: sphere, −4.5 to −0.5; cylinder, 3.5 to 0.75. **Conclusions:** tIOLc with tomography-guided excimer treatment plan used in the Hoffer-Q formula for emmetropia approximation in KCN offered the highest accuracy.

Our Experience With the Use of a New Extended Depth of Focus IOL: Our First 10 Results

RP30068493

Senior Author: Panos S Gartaganis MD
Coauthor: Ioannis P Giannakis MD

Purpose: To evaluate the visual performance of a new fully preloaded acrylic hydrophobic IOL with extended depth of focus (EDOF) technology. **Methods:** The study enrolled 10 patients who underwent age-related cataract surgery with unilateral implantation of the EDOF LuxSmart (Bausch + Lomb) IOL. All participants underwent LenStar Optical Biometry (Haag-Streit USA), and the formula used to calculate the IOL power was SRK/T. Patients were evaluated 1 month postoperatively for distance visual acuity, near visual acuity at 50 cm and 30 cm, contrast sensitivity, and halos quantitative assessment. **Results:** The mean age of participants was 70.3 ± 12.4 years. The mean uncorrected distance visual acuity and distance-corrected near visual acuity were, respectively, 0.03 ± 0.08 logMAR and N1 with addition +2.00 at 30 cm and N2 without correction at 50 cm, $P < .001$. The contrast sensitivity was similar in all patients. The defocus curve confirmed great satisfaction, and none of them reported glare, halos, or night visual disturbances. **Conclusions:** This preloaded EDOF ringless IOL does not compromise quality of distance vision and provides excellent intermediate near vision without correction.

Choosing the Most Appropriate 3-Piece IOL for Patients With Posterior-Capsular Rupture: Do We Have a Problem?

RP30068499

Senior Author: Sunil Mamtora MBBS
Coauthors: Rebecca Jones MBBS, Selina Khan MBChB, Jordan Chervenkoff BMBS, Antoine Safi, and John Ferris FRCOphthHK MBBCh MBChB

Purpose: Cataract surgery complicated by posterior capsular rupture (PCR) usually necessitates the insertion of a 3-piece lens in the ciliary sulcus. This anterior change in effective lens position requires modification of the IOL power. We compared the number of cases with correct sulcus lens power between 2 regional hospitals in the southwest of England. **Methods:** A retrospective audit was performed of 22,975 patients undergoing cataract surgery in the previous 5 years. In patients identified as having PCR with the implantation of a 3-piece IOL, documentation was reviewed to identify the preoperatively determined IOL and intended refractive aim, the intraoperatively selected 3-piece IOL, and whether or not there was optic capture. **Results:** The data from 137 patients was included in our study. Cumulatively, a correct IOL was found to have been implanted in 26% of patients (35/137). The median error was +0.5 D (interquartile range: 0-1 D) in both centers. **Conclusion:** We have identified widespread incorrect selection of the appropriate 3-piece IOL in patients with PCR.

Innovation

AcuSimX: A Virtual Artificial Intelligence Platform for Predicting Post–Refractive Surgery Corneal Stiffness
RP30068496

Senior Author: Reshma Raghunath Ranade DOMS MBBS
Coauthors: Rohit Shetty MBBS, Abhijit Sinha Roy, Mathew Francis, Pooja Khamar MBBS MS, and Sneha Gupta MBBS

Purpose: To depict accuracy of AcuSimX to estimate postoperative corneal stiffness (CS) following SMILE, LASIK, and PRK. **Methods:** AcuSimX helped build a patient-specific iFEM model with preoperative Corvis-ST deformation, Pentacam HR tomography 3-D volume, and intended aspheric ablation profile. Using inverse methods, it estimated biomechanics from preop measurements. Using preop biomechanics and surgical 3-D mesh models specific to surgery, it gave postop CS that was refined by in-built database of 300 post-surgery eyes CS outcomes and lasso regression AI. **Results:** Interclass correlation (ICC) between measured and predicted postop CS was 0.91 (LASIK = 0.92, SMILE = 0.91, and PRK = 0.85). Difference between predicted and measured postop CS was 4.02 (2.85, 5.2), 3.69 (2.36, 5.03), and 2.8 (1.16, 4.43) N/m for LASIK, SMILE, and PRK. ICC improved to 0.95 after lasso regression AI adjustment (LASIK = 0.95, SMILE = 0.93, and PRK = 0.92). Difference improved to −0.27 (−1.25, 0.71), 0.27 (−0.87, 1.4), and 0.3 (−0.95, 1.55) N/m for LASIK, SMILE, and PRK. **Conclusion:** Excellent ICC (>0.9) showed accuracy of postop CS predictions.

Long-term Outcomes of Bowman Membrane Relaxation for Enhancement of Femtosecond Intrastromal Lenticule Implantation Performed for the Management of High Hyperopia
RP30068449

Senior Author: Sri Ganesh MBBS MS DNB
Coauthors: Sheetal Brar MBBS and Skanda Samak Sriganesh

Purpose: To evaluate, retrospectively, the feasibility of and report the long-term outcomes with Bowman membrane relaxation (BMR) for enhancing the residual refractive error following femtosecond intrastromal lenticule implantation (FILI). **Methods:** BMR was performed using a Hessburg-Barron trephine to create a circular incision into the Bowman membrane and anterior corneal fibers up to the depth of around 120-130 µm. Post-enhancement clinical outcomes were analyzed at a mean period of 36 (14-57) months. **Results:** Four eyes of 3 patients were included with residual refractive error of +2.25 D SE following FILI for high hyperopia. Following BMR, the SE reduced to +0.31 D, resulting in improvement in uncorrected distance visual acuity from 0.55 to 0.33 logMAR. The mean front keratometry increased from 46.2 D to 49.3 D, and the mean back keratometry increased from −5.9 to −6.3 D following BMR, the latter returning to the baseline (pre-FILI) value of −6.3 D. Corneal biomechanics indicated reduction of stiffness post-enhancement. **Conclusion:** BMR may be a safe, simple, and effective technique for enhancement of residual hyperopia following tissue addition techniques such as FILI.

Fresh Corneal Lenticule Implantation by SMILE in Treating Residual Hyperopic Refraction Following LASIK
RP30068452

Senior Author: Njomza Hima Musa MD DOMS
Coauthors: Faruk Semiz MD, Anita D Lokaj II, Gulser Caliskan PhD, Giuseppe Verlato MD PhD, Ceren Ece Ece Semiz, Zekeriya Alp Demirsoy, and Olcay Semiz

Purpose: To evaluate correcting hyperopic residual refraction 1 year after LASIK in young patients with fresh corneal lenticule implantation by SMILE surgery. **Methods:** Thirty patients, 40 eyes, underwent fresh corneal lenticule implantation taken from myopic patients (min. −1.50 D) and inserted in post-LASIK with residual hyperopic refractive error (min.+1.0 D). Group 1 (n = 20): The flap of LASIK is lifted and cleaned and the lenticule is gently inserted according to the K2 values. Group 2 (n = 20): The flap is not lifted, but using SMILE we created a stromal pocket (8 mm), inserting the lenticule. **Results:** Uncorrected distance visual acuity (UDVA) at the first year significantly improved for both groups. Group 1: Preop, 0.39 ± 0.12 logMAR; postop 1 year, 0.16 ± 0.06 logMAR, $P < .001$. Group 2: Preop, 0.41 ± 0.12 logMAR; postop 1 year, 0.09 ± 0.04 logMAR, $P < .001$. There were statistically significant differences in terms of UDVA between the study groups, and the second group showed better results. **Conclusion:** Fresh corneal lenticule implantation reduced residual hyperopic refractive errors after LASIK, increasing visual acuity (especially accommodation process) and patient satisfaction.

Fresh Corneal Lenticule Implantation as a Safe Treatment in Hyperopic Patients With High Astigmatism (3-Year Follow-up)
RP30068453

Senior Author: Njomza Hima Musa MD DOMS
Coauthors: Faruk Semiz MD, Anita D Lokaj II, Gulser Caliskan PhD, Giuseppe Verlato MD PhD, Ceren Ece Ece Semiz, Zekeriya Alp Demirsoy, and Olcay Semiz

Purpose: To evaluate SMILE treatment using fresh corneal lenticule in treating visual and refractive outcomes (especially accommodation problems) in hyperopic patients with high astigmatism. **Methods:** Thirty-two patients (40 eyes). Inclusion criteria was dioptry over +4.0 D +3.0 cyl. Fresh corneal lenticule as allogenic implant was taken from myopic patients (−5.0 D) to be implanted in hyperopic patients (+4.0 D +3.0 cyl) according to high K2 values following corneal topography. The stromal pocket diameter was 8 mm; super incision, 4 mm; and cap thickness, 130 µm. Preoperative measurements were vision with glasses, OCT, and corneal topography. **Results:** Compared to preoperative values (preop, 0.76 ± 0.19 logMAR), uncorrected distance visual acuity 1 year postop was 0.19 ± 0.07 logMAR ($P < .001$); 2 years, 0.18 ± 0.06 logMAR ($P < .001$), and 3 years, 0.17 ± 0.06 logMAR ($P < .001$)—significantly improved. There were no complications in any eye during the 3-year follow-up. **Conclusion:** This safe surgical procedure has primary objective increase of visual acuity, accommodation process, and patient satisfaction, enjoying a happier life. This study contributes to future of refractive surgery for treating high hyperopia.

Fresh Human Myopic Lenticule Intrastromal Implantation in Keratoconus Disease With SMILE: Three-Year Long-term Ultrastructural Analysis by Transmission Electron Microscopy

RP30068458

Senior Author: Faruk Semiz MD
Coauthors: Anita Syla Lokaj, Njomza Hima Musa MD DOMS, Gamze Tanriverdi, Gulser Caliskan PhD, Giuseppe Verlato MD PhD, Ceren Ece Ece Semiz, Zekeriya Alp Demirsoy, Olcay Semiz, and Aynur Abdulova

Purpose: To investigate the histological structure of the fresh human lenticule after intrastromal implantation in keratoconus with SMILE using transmission electron microscopy (TEM). **Methods:** Sixty eyes with advanced keratoconus indicated for corneal transplantation were included in this study. Fresh lenticules were implanted in all of the eyes with SMILE. For electron microscopic study, 5 samples were taken from normal, keratoconus corneas and implanted lenticules (at the end of first, second, and third years) and compared histologically. **Results:** In the keratoconus cornea, disorganized and thinned collagen fibers and apoptotic bodies were seen in the stroma with degenerative stromal cells. However, during the controls and treatments, corneal stroma, which came from 1, 2, and 3 years after the lenticule implantation, became well-organized, parallel-running lamellar structures, and healthy keratocytes and telocyte-like cells were seen. Telocytes may be activated by appropriate stimuli like stem cells and involved in stromal regeneration. **Conclusion:** This surgical technique in keratoconus is a new and curative method that is reliable, safe, satisfactory, and economical.

Human Fresh Corneal Lenticule Implantation With SMILE Surgery and Autolog Serum: A New Approach in Treatment of Advanced Keratoconus Disease, Case Report

RP30068459

Senior Author: Anita Syla Lokaj MD
Coauthors: Faruk Semiz MD, Gulser Caliskan PhD, Giuseppe Verlato MD PhD, Njomza Hima Musa MD DOMS, Ceren Ece Ece Semiz, Zekeriya Alp Demirsoy, Olcay Semiz, and Anita D Lokaj II

Purpose: To investigate the effect of small-incision femtosecond laser–assisted intrastromal fresh myopic lenticule implantation in keratoconus. **Methods:** Nineteen-year-old female patient; minimum corneal thickness in the right eye was 378 µm as measured by anterior segment OCT. Corneal topography showed steep K-values, 82.60 ax 37 and flat K 75.15 D ax 127, with –7.45 corneal astigmatism. 118-µm fresh lenticule intrastromal implantation using SMILE. **Results:** Central corneal thickness was improved on the day of surgery, and vision started to improve in the first week. Moreover, corneal topography showed a significant decrease in the anterior K1 and K2 during the study period. The graft in the recipient cornea was clear, and electron microscopy has shown that regular collagen fibers and healthy keratocytes and telocyte-like cells were seen even 3 years after implantation. **Conclusion:** This surgical procedure in keratoconus is a new and therapeutic technique. Furthermore, it is reliable, safe, and economical; maintaining the healthy ocular surface in the advanced keratoconus eye using autologous serum is the best choice.

Successful Treatment of Residual Hyperopia After Trifocal IOL Implantation With SMILE: Two-Year Long-term

RP30068462

Senior Author: Faruk Semiz MD
Coauthors: Anita D Lokaj II , Anita Syla Lokaj, Njomza Hima Musa MD DOMS, Ceren Ece Semiz, Zekeriya Alp Demirsoy, Gulser Caliskan PhD, Giuseppe Verlato MD PhD, Olcay Semiz, Gamze Tanriverdi, and Aynur Abdulova

Purpose: To evaluate outcomes for patients with residual hyperopia after trifocal IOL who were implanted fresh myopic lenticule with a SMILE, improving patient satisfaction and increasing their vision. **Methods:** Refractive trifocal IOL implantation was performed in 462 eyes of 236 patients. Residual hyperopia was detected in 38 eyes of 34 of these patients. Fresh myopic lenticule was implanted intrastromal to these patients with a SMILE. Lenticule diopter was 0.5 higher than a residual diopter. Patients were followed for 2 years. **Results:** Thirty-eight eyes were followed for 2 years. No complications were observed. There was a significant increase in uncorrected distance visual acuity, from 0.38 ± 0.10 to 0.03 ± 0.04 logMAR ($P < .0001$). **Conclusion:** Fresh myopic lenticule implantation with SMILE can be used for treating residual hyperopia after trifocal IOL implantation; we observed that both patient vision and satisfaction improved. This surgical method is safe, with no complications, and provides a quick return to daily life.

Swept Source OCT in Corneal Epithelial Thickness Mapping: Repeatability and Agreement With a Validated Device

RP30068472

Senior Author: Yue Feng MD
Coauthor: Aleksandar Stojanovic MD

Purpose: To assess repeatability of corneal epithelial thickness mapping (ETM) using a swept-source OCT (SS-OCT) and the agreement with a validated device. **Methods:** Retrospective analysis of ETMs measured by SS-OCT (Anterion) and spectral domain OCT (Avanti) in 81 virgin, 19 post-laser refractive surgery (LRS), and 69 keratoconus (KC) eyes. Within-subject standard deviation, coefficient of variation (COV), and intraclass correlation coefficient (ICC) were analyzed for repeatability. Agreement was analyzed by mean difference. Pearson correlation (R) and paired, 2-tailed *t*-tests were used to compare the measurements. **Results:** Repeatability of Anterion ETMs was high (ICC > 0.96, COV < 3.0%). Pearson correlation test indicated that the 2 ETMs were highly correlated (R > .80, $P < .001$). Anterion showed significantly thinner ETMs ($P < .001$), with a mean difference of 3.88, 3.56, and 3.29 µm in virgin, LRS, and KC groups, respectively. **Conclusion:** The repeatability of the Anterion's ETM was high. There is excellent correspondence in ETM between Anterion and Avanti, although Anterion measurements were about 7% thinner than Avanti's.

Novel Collagen Imaging Using Polarization-Sensitive OCT in Healthy, Suspect and Keratoconus Corneas

RP30068495

Senior Author: Ritika Mullick MBBS
Coauthors: Abhijit Sinharoy, Pooja Khamar MBBS MS, Rahul Patil Mr Senior Research Fellow, and Raghav Narasimhan Mr Research Fellow

Purpose: To assess the collagen distribution in healthy and keratoconus corneas and correlate with early disease-related changes in the distribution of collagen in suspicious corneas with custom-built polarization-sensitive OCT (PS-OCT). **Methods:** Fifty healthy, 50 KC, and 35 suspicious corneas were imaged prospectively by PS-OCT. Suspicious corneas were diagnosed clinically. PS-OCT studies collagen fiber birefringence by phase retardation (PR) and axis orientation (AO), evaluated at each pixel of an OCT B-scan. **Results:** PR and AO histograms of healthy corneas matched those of human donor corneas from earlier studies. KC corneas had reduced number of pixels with PR (<25 degrees) and increased with AO (<0 degrees) ($P < .001$). The histograms of some suspect corneas matched those of the healthy corneas ($P > .05$), while the remaining ($P < .01$) had a unique distribution that was much different from those of KC corneas. **Conclusion:** PS-OCT imaging clearly identified differences in collagen distribution between healthy and KC corneas. Asymmetric fellow corneas revealed a unique distribution of collagen, indicating early changes, before their topographic manifestations in these eyes.

JRS—Hot, Hotter, Hottest Late Breaking News

Using Artificial Intelligence for High-Risk Factors and Demographic Profiling of Keratoconus Patients Who Progressed During the COVID-19 Pandemic
RP30068498

Senior Author: Divya Trivedi MBBS MS
Coauthors: Rohit Shetty MBBS, Abhijit Sinha Roy, Gairik Kundu MBBS MS, and Raghav Narasimhan M Tech

Purpose: To identify and analyze demographic and high-risk factors influencing progression of keratoconus (KC) during COVID-19 using artificial intelligence (AI). **Methods:** This study included 200 KC patients with ≥1 stable visit before COVID-19 who progressed and 50 KC patients with ≥1 stable visit before COVID-19 who remained stable. Progression was defined as change in Kmax 1 D between 2 visits in 6 months. Demographic and clinical data from day of listing and on day of documented progression/stability. Questionnaire: eye-rubbing, IgE, VitD and VitB12 levels, hours of indoor activity, use of lubricants, immunomodulators, topical medication, screen time, hormonal disturbance, use of hand sanitizer. Two AI models were run, and top 5 parameters were studied. **Results:** Model A: Progression vs. Stable. Model B: Aggressive Progression vs. Progression. Classification accuracy in Model A: 87% for progression, 83% sensitivity, 81% specificity. In Model B: 90% for progression, 92% sensitivity, 83% specificity. Progressors: IgE > 100 IU/mL, VitD < 25 ng/mL, mask use > 4 hrs/day, more eye rubbing, no/less topical lubricant use. **Conclusion:** AI is important for risk stratification of KC, helping us detect and manage them better.

Videographic Assessment and Laboratory Analysis of Injector Nozzle Damage of Preloaded Injectors Used in a Clinical Study
RP30068446

Senior Author: Ramin Khoramnia MD
Coauthors: Timur Yildirim MD, Grzegorz Labuz, Tadas Naujokaitis, Jan Weindler, and Gerd U Auffarth MD

Purpose: To evaluate quality and duration of implantation of 2 preloaded IOL injectors and assess post-implantation damage. **Methods:** Implantation videos and postuse injectors from 60 paired eyes of 30 bilateral cataract patients were included. Patients' eyes were randomly assigned for IOL implantation with the AutonoMe (Alcon) and the iSert (Hoya). Injectors' nozzles were examined (light and scanning electron microscopy). **Results:** IOL delivery was without critical events. Implantation took 56 sec with the AutonoMe and 44 sec with the iSert ($P < .05$). Most AutonoMe injectors (97%) showed no damage or slight deformation. In most of the iSert injectors (80%), short or extended cracks were present. The incision enlargement was 0.20 ± 0.10 mm for the AutonoMe and 0.29 ± 0.10 mm for the iSert, with a statistically significant difference ($P < .05$). **Conclusion:** Both preloaded IOL injectors allowed a safe and convenient IOL delivery. The AutonoMe showed less nozzle tip damage than that of the iSert.

Refractive Lens Exchange: Clinical Outcomes After Binocular Implantation of a Continuous-Range-of-Vision IOL
RP30068454

Senior Author: Ramin Khoramnia MD
Coauthors: Isabella Diana Baur, Annette Stengele, Maximilian Koeppe, and Gerd U Auffarth MD

Purpose: Clinical evaluation of a diffractive continuous-range-of-vision IOL that combines bifocal and extended-depth-of-focus technologies. **Methods:** In an ongoing study, bilateral implantation of the Tecnis Synergy IOL (Johnson & Johnson Surgical Vision; Santa Ana, CA) is performed in 56 eyes of 28 refractive lens exchange patients. Postoperative follow-up at 3 months includes uncorrected (UDVA) and corrected (CDVA) distance visual acuity, uncorrected (UIVA) and distance-corrected (DCIVA) intermediate visual acuity (80 cm), uncorrected (UNVA) and distance corrected (DCNVA) near visual acuity (40 cm), as well as defocus curve testing. **Results:** UDVA and CDVA were −0.05 ± 0.06 and −0.12 ± 0.05 logMAR. UIVA and DCIVA were −0.08 ± 0.05 and −0.10 ± 0.04 logMAR; UNVA and DCNVA were 0.00 ± 0.07 and −0.03 ± 0.08 logMAR. The defocus curve revealed a visual acuity of ≥0.1 logMAR from +0.5 to −3.0 D. **Conclusion:** The Tecnis Synergy IOL provided very good distance, intermediate, and near visual outcomes.

Phase 2 Clinical Trial to Evaluate the Efficacy of Phentolamine Ophthalmic Solution and Low-Dose Pilocarpine for the Treatment of Presbyopia
RP30068457

Senior Author: Jay Stuart Pepose MD PhD
Coauthors: Mina Sooch B Eng MBA, Konstantinos Charizanis PhD, Mitchell Brigell PhD, Charles B Slonim MD, and Eliot Lazar MD

Purpose: To evaluate a kit combination of Nyxol, which is 0.75% phentolamine ophthalmic solution (POS), plus low-dose 0.4% pilocarpine (LDP) for the temporary treatment of presbyopia. **Methods:** The VEGA-1 study is a Phase 2, multicenter, randomized, placebo-controlled, double-masked 5-day clinical trial of subjects ages 40-64 with distance-corrected near visual acuity (DCNVA) of 20/50 or worse randomized to either 0.75% POS or placebo vehicle with and without LDP. **Results:** Enrollment was completed with 150 subjects enrolled across 17 sites. The primary endpoint will be the percent of patients with at least 15 letters ETDRS (3 lines) or more of binocular photopic DCNVA improvement relative to baseline on a standard near vision eye chart at 1 hour. Additional secondary endpoints include near/distance/intermediate visual acuity at multiple timepoints, effect of iris color, percentage of subjects with <5 letters of loss in distance visual acuity, and measurements in pupil diameter over time. Topline efficacy and safety data will be analyzed and presented at the meeting. **Conclusion:** The Phase 2 efficacy and safety profile will inform Phase 3 presbyopia trials.

Drug Repository Contact Lens Study: Prolongation of Corneal Antimicrobial Contact in Bacterial Keratitis
RP30068460

Senior Author: Lional Raj Daniel Raj Ponniah MD

Purpose: To evaluate the efficacy of novel therapeutic drug-repository contact lens (CL) in subjects with bacterial keratitis (BK). **Methods:** BK was randomized in 1:1 ratio into Group 1 (antimicrobials only) and Group 2 (antimicrobials + drug-reservoir CL, with dual base curves for a central reservoir along with fenestrations to enable capture of drops). Both groups received a standard regimen of moxifloxacin. Improvement in BK severity scores and pain analog scores (PAS) were compared at 12 hours, Days 1, 3, 5, and 14, in addition to drug retention studies (DRS) with repository CL. **Results:** Twenty cases. PAS in Group 2 improved by 5.29 points, 2 points in Group 1 at Day 1 ($P < .001$), by 6.86 points in Group 2 at Day 3 ($P < .001$). BK resolved by 0.66 mm at 12 hrs in Group 2, 0.09 mm in Group 1 ($P < .0001$), 1.27 in Group 2, 0.41 in Group 1 ($P < .0001$) by Day 1, 2.06 in Group 2 vs. 1.09 in Group 1 ($P = .013$) by Day 3. Vision improved by 1.5 lines by Day 1, another line by Day 3 in Group 2, whereas commenced by Day 3 in Group 1. AC-reaction resolved in Group 2 fast. Drug in precorneal space was evidenced up to 4 hrs by DRS. **Conclusion:** Drug-repository CL prolongs antimicrobial contact time over the lesion, hastens to heal BK, and improves patient tolerance.

Prospective Results of a Novel Transepithelial Laser Method for Epithelial Removal in PRK: A Comparative Study
RP30068480

Senior Author: Laila Christina Silveira MD
Coauthors: Marcony R Santhiago MD, Gustavo F Resende MD, and Breno De Mello Vitor

Purpose: To compare the safety and efficacy of a new transepithelial method of a single-step transepithelial PRK vs. that of conventional alcohol-assisted PRK. **Methods:** This prospective, randomized, double-blind, fellow-eye-controlled clinical trial included 40 eyes of 20 patients with myopia or myopic astigmatism. Each patient was randomly and alternately assigned to undergo TransPRK (StreamLight WaveLight Ex500 Excimer Laser, Alcon Surgical) on 1 eye and alcohol-assisted PRK (WaveLight Ex500 Excimer Laser, Alcon Surgical) on the fellow eye. A 6-month follow-up was done. **Results:** The preliminary results showed that both alcohol-assisted and trans-PRK provided effective and safe outcomes for the correction of myopia and myopic astigmatism, without differences between procedures after a 6-month follow-up. **Conclusion:** The new transepithelial method and alcohol-assisted PRK were comparable techniques concerning safety and efficacy 6 months after surgery.

The Effect of Wearing Protective Masks on the Ocular Surface During COVID-19 Pandemic in Health-care Workers
RP30068483

Senior Author: Bhavya Gorimanipalli MBBS MD
Coauthors: Rohit Shetty MBBS, Pooja Khamar MBBS MS, Arkasubhra Ghosh MS PhD, and Swaminathan Sethu PhD

Purpose: Extended use of masks has been seen to cause ocular discomfort. This study examines the impact of mask on ocular surface health of health-care workers (HCWs). **Methods:** Healthy volunteers underwent Schirmer Test 1, tear-film breakup time, ocular surface wash with sterile saline, and Ocular Surface Disease Index (OSDI) questionnaire, before and during COVID-19. Soluble tear factors acquired from tear strip were measured using multiplex ELISA. Ocular surface cells taken from ocular surface wash were immunophenotyped using specific antibodies for leukocytes, neutrophils, monocytes, macrophages, natural killer cells, T cells, and B cells. **Results:** OSDI was significantly elevated in the COVID-19 era. IL-1, IL-2, NGF, perforins, and RANTES increased, and IL-8, IL-13, HGF, and VEGF decreased. Higher levels of leukocytes, T cells, and natural killer T cells, and lower levels of B cells were noted. **Conclusion:** Distinct changes were found on the ocular surface of HCWs during COVID-19, unlike those observed in other ocular surface conditions.

A Next-Generation Crosslinking Calculator for Titration of Ultraviolet Energy in Thin Keratoconic Cornea
RP30068494

Senior Author: Sailie Shirodkar MBBS MS
Coauthors: Rohit Shetty MBBS, Pooja Khamar MBBS MS, Abhijit Sinha Roy PhD, and Sharon D'Souza MBBS

Purpose: To evaluate the safety and efficacy of New Generation CXL for Thin Cornea (NXT) UV-A calculator in customizing fluence to corneal thickness for crosslinking (CXL) in thinner corneas. **Methods:** 70 eyes (70 patients) with progressive keratoconus and mean thinnest corneal thickness (TCT) <420 µm were included. Mean TCT after de-epithelialization was entered into a web-based calculator (https://jscalc.io/calc/VmanUJD6y-Q13VQQ6), which gave fluence times based on UV power. Postoperative assessments were done at 1 week and 1, 3, 6, and 12 months. **Results:** There was no loss of lines/visual acuity (VA), no significant haze on densitometry ($P = .14$), no progression at 6 months, and no change in cell density on specular microscopy ($P = .83$). Sixty-four percent had a demarcation line at 3 months at a depth of 295 ± 71 µm. All patients were fitted with contact lenses at 3 months, with VA 20/30 or more. **Conclusion:** NXT calculator is a promising modality to titrate energy fluence and perform CXL safely in thin corneas.

Tear Soluble Factors and In Vivo Confocal Microscopy Features in Subjects With Ocular Surface Discomfort/Pain

RP30068497

Senior Author: Ritika Mullick MBBS
Coauthors: Rohit Shetty MBBS, Swaminathan Sethu PhD, Arkasubhra Ghosh MS PhD, Pooja Khamar MBBS MS, Gairik Kundu MBBS MS, and Sharon D'Souza MBBS

Purpose: To correlate in vivo confocal microscopy (IVCM) features and tear factors in patients with ocular surface discomfort. **Methods:** IVCM images, Ocular Surface Disease Index (OSDI) score, and tear film breakup time (TBUT) from 134 subjects (267 eyes) were recruited to determine corneal dendritic cell density (DCD), sub-basal nerve plexus (SBNP) features, and microneuroma-like features. Thirteen soluble factors with nociceptive potential were measured using multiplex ELISA in tears from 76 subjects (88 eyes). Subjects were grouped into 1: normal TBUT (≥10 secs) + normal OSDI (<12); 2: low TBUT + normal OSDI; 3: normal TBUT + increased OSDI; and 4: low TBUT + increased OSDI. **Results:** Groups 2-4 had higher DCD than Group 1 ($P < .05$). No relationship was observed between OSDI and SBNP/microneuroma-like features. Groups 3-4 had increased tear IL-17A (pro-nociceptive) and reduced VEGF-A (anti-nociceptive) levels ($P < .05$). **Conclusion:** Altered DCD and tear nociceptive cytokines are associated with ocular surface discomfort independent of tear film instability.

Enhancing Innate Immunity in Ocular Surface Possibly Halts SARS-CoV-2 Entry and Transmission Through Ocular Portals: A Human Globe Study

RP30068502

Senior Author: Sneha Gupta MBBS
Coauthors: Rohit Shetty MBBS, Arkasubhra Ghosh MS PhD, Swaminathan Sethu PhD, Pooja Khamar MBBS MS, Sharon D'Souza MBBS, and Vishnu Suresh Babu PhD Scholar

Purpose: SARS-CoV2 uses host proteins on mucosal epithelium of ocular surface for cellular entry, amplification, and modulation of host immune response. ACE2, TMPRSS2, CTSL, and antiviral interferon expression across ocular tissues and identification of potential therapeutics to prevent transmission were studied. **Methods:** Donor human globes of control, COVID-19-infected, and recovered were microdissected to study distribution of above genes by gene expression and immunofluorescence, along with effect of trehalose on receptors in uninfected. **Results:** Corneal and conjunctival epithelium having highest levels of ACE2R, CTSL indicated autophagy as an important aspect of viral transduction. Trehalose reduced ACE2R and enhanced MxA expression, indicating antiviral immunity. **Conclusion:** Presence of pro-viral host factors increases risk of infection. Pharmacological induction of interferon-mediated antiviral response with prophylactic use of trehalose protects ocular surface and nasolacrimal duct from respiratory viral infections.

The Nexus Between Microbiome and Immune Factors at the Ocular Surface: Novel Drivers of Keratoconus Pathology

RP30068503

Senior Author: Sneha Gupta MBBS
Coauthors: Rohit Shetty MBBS, Arkasubhra Ghosh MS PhD, Swaminathan Sethu PhD, Pooja Khamar MBBS MS, Archana Padmanabhan Nair PhD Scholar, and Nimisha Rajiv Kumar PhD Scholar

Purpose: Keratoconus (KC) is known to be inflammatory in nature. Inflammatory status and microbiome influence each other in the body. Thus, we analyzed ocular surface microbiome and tear profile in KC patients. **Methods:** Fifteen healthy controls and 34 KC subjects underwent detailed examination and topography, and swabs from the lower corneal fornix were collected. Microbiome profile was determined by V3-V4 amplicon sequencing and bioinformatics analysis. Tear analysis was done by multiplex ELISA. **Results:** Microbiome profile varied with different grades of KC. Genus *Lactobacilli*, *Streptococcus*, and *Rothia* were reduced, and *Dienococcus*, *Brevundimonas*, and *Bacillus* increased across KC grades. Actinobacteria significantly correlated with IL-8, CD121, and MPO levels, proteobacteria with IL-17A and IL-12, and Bacteroidetes with perforin levels. **Conclusion:** Unique ocular microbiome profile that correlated with KC grades and severity suggests a causal relationship and may aid in future therapeutics.

Laser Vision Correction

Optimizing Topography-Guided LASIK Outcomes and Treatment Planning Strategies
RP30068482

Senior Author: Lara Asroui BS MD
Coauthors: William J Dupps MD PhD and J Bradley Randleman MD

Purpose: To evaluate refractive outcomes after topography-guided LASIK and determine the best strategy for treatment planning. **Methods:** 133 eyes treated with topography-guided LASIK were retrospectively evaluated. Optimal treatment correction was determined from postoperative outcomes and actual surgical treatment. Outcomes resulting from planning based on manifest refraction, VARIO, Phorcides, LYRA, and an intuitive model were determined for each eye. **Results:** A significant difference in spherical equivalent (SE) and cylinder deviation from target was found between the treatment plans ($P < .001$). The intuitive model performed best, with 92.86% and 95.24% of eyes within 0.5 D of target SE and cylinder, respectively. There was a significant difference between planning based on manifest refraction and both Phorcides and the intuitive model in SE and cylinder deviation from target ($P < .001$). **Conclusion:** LASIK planning based on an intuitive model that was influenced by Phorcides treatment plans results in the best outcomes. Treatment plans combining manifest and topography-derived refraction have better outcomes than either method alone.

Retinal Nerve Fiber Layer Thinning in Glaucoma Patients With Prior Refractive Corneal Surgery
RP30068448

Senior Author: Justin Riffel
Coauthor: Anjulie K Quick MD

Purpose: To compare rates of change in global peripapillary retinal nerve fiber layer (gpRNFL) thickness in primary open-angle glaucoma patients with and without prior refractive corneal surgery (RCS). **Methods:** Retrospective from 2010-2020. Linear regressions were performed on spectral domain OCT scans retrieved from clinical data. **Results:** The RCS group contained 23 eyes, 14 patients (mean baseline age, mean follow-up: 60.9, 5.3 years); the Non-RCS group contained 25 eyes, 14 patients (61.9, 5.4 years). The gpRNFL thickness change per year (median, interquartile range [IQR]) was not significantly different: RCS group (–1.31, –2.03 to –0.77 µm/y), Non-RCS group (–1.14, –1.37 to –0.55 µm/y), $P = .131$. Mean central corneal thickness (CCT) was lower in the RCS group (525.3 vs. 551.2 µm), $P = .041$. Mean follow-up IOP was lower in the RCS group (13.5 vs. 15.8 mmHg), $P < .001$. Subgroup analysis of linear regression slopes with $P < .05$ also showed no difference in gpRNFL rates of change. **Conclusion:** There was no significant difference in rates of gpRNFL change between groups, despite lower mean CCT and IOP in the RCS group.

Comparison of Long-term Outcomes and Refractive Stability Following SMILE vs. SMILE Combined With Accelerated Crosslinking (SMILE Xtra)
RP30068450

Senior Author: Sri Ganesh MBBS MS DNB
Coauthor: Sheetal Brar MBBS

Purpose: To compare the long-term results and refractive stability following SMILE with those of SMILE combined with accelerated crosslinking (SMILE Xtra). **Methods:** This retrospective study included 54 eyes of SMILE and 52 eyes of SMILE Xtra treated for normal and borderline cases of myopia/myopic astigmatism, respectively, based upon predefined risk factors. Both groups were matched for age and refractive error. Mean follow-up was 22.18 ± 10.41 months. **Results:** At the end of follow-up, the mean sphere, cylinder, and SE reduced to –0.03, –0.09, and –0.08 D in SMILE and –0.06, –0.15, and –0.13 D in the SMILE Xtra group, $P = .17$. Ninety-three percent and 92% of eyes remained within ±0.50 D, with 94% and 88% of eyes maintaining an uncorrected distance visual acuity of 20/20 or better in SMILE and SMILE Xtra groups, respectively. Safety and Efficacy indices for SMILE group were 1.16 and 1.03 and for the SMILE Xtra group were 1.06 and 0.93. No eye in either group developed keratectasia or underwent enhancement for significant residual refraction. **Conclusion:** Both SMILE and SMILE Xtra resulted in similar amount of regression. SMILE combined with accelerated crosslinking did not result in a hyperopic outcome over a long-term follow-up when used to treat borderline cases.

Visual and Refractive Outcomes and Complications of Customized PRK Plus Accelerated CXL in Early Keratoconus vs. Customized LASEK in Myopic Subjects
RP30068455

Senior Author: Seyed Javad Hashemian MD

Purpose: To compare the safety, efficacy, stability, and predictability of wavefront-guided PRK plus accelerated CXL in early keratoconus (KCN) with customized LASEK in patients with myopia. **Methods:** Thirty-nine eyes of 39 patients with stable early KCN and 44 eyes of 44 patients with myopia were included. After 6.0 months, uncorrected and corrected distance visual acuity (UDVA and CDVA), refractive outcomes, and complications were evaluated. **Results:** At 6 months, UDVA, CDVA, and refractive error improved significantly in both groups. Mean SE refraction improved from –2.39 D to –0.13 in the KCN group and from -2.28 D to +0.06 in the LASEK group. Mean cylinder improved from –1.35 to –0.54 D and –0.84 to –0.04 D, respectively. Nine eyes (23.1%) in the KCN group developed corneal haze at 2 months that improved at 6.0 months postop. Sixteen eyes (41%) in KCN group gained 1-4 lines of UCVA. The safety and efficacy indexes were 1.10, 1.00, and 98.1%, 100% in KCN and LASEK groups, respectively. **Conclusion:** The visual and refractive outcomes of wavefront-guided PRK plus accelerated CXL in stable early KCN are promising and comparable with customized LASEK in normal myopic subjects. Both techniques appear safe and effectively improved the UDVA, CDVA, and refractive error.

Removing Soft Contact Lenses 1 Day vs. 1 Month or More Before LASIK Procedure: Functional Outcomes and Results

RP30068464

Senior Author: Georges Khattar MD
Coauthor: Ali Fadlallah Yahya MD

Purpose: To compare the outcomes, safety, efficacy, and predictability of LASIK 24 hours (Group 1) and 1 month or more (Group 2) after soft contact lens (SCL) removal. **Methods:** The patients were divided based on the time of SCL discontinuation before LASIK into 2 well-matched groups. Schirmer testing, corrected distance visual acuity, uncorrected distance visual acuity (UDVA), manifest refraction spherical equivalent, and infection rate were evaluated preoperatively and at 1 week, 1 month, and 6 months after treatment. **Results:** Group 1 comprised 1026 patients (2051 eyes); and Group 2, 1051 patients (2102 eyes). The overall-mentioned outcomes were comparable between both groups, with UDVA of −0.081 ± 0.11 logMAR in Group 1 and −0.079 ± 0.14 logMAR in Group 2 at 6 months (P = .302). Schirmer testing results were also comparable between groups on follow-up visits at 1 week (P = .508) and 6 months (P = .702) postoperatively. Finally, no infectious or inflammatory complications were recorded in either of the groups. **Conclusion:** Removal of SCL 1 day before LASIK does not affect its outcomes and safety.

Keratoconus Detection and Utility of Epithelial Mapping With the MS39 Anterior Segment Optical Coherence Tomographer

RP30068465

Senior Author: Brian K Armstrong MD

Purpose: The purpose of this study is to compare the clinical diagnosis of keratoconus to the diagnostic accuracy of the MS39 anterior segment OCT instrument–derived diagnosis and to determine if epithelial mapping can be used as an early indicator for keratoconus. **Methods:** All scans performed on the MS39 will be evaluated for their instrument-derived diagnosis and compared to the clinical diagnosis. Epithelial thickness profiles of normal and keratoconus eyes will be compared using ordinary least squares regression models. **Results:** 108 keratoconus eyes of 62 patients were identified by the MS39 to be keratoconus (80 eyes), keratoconus suspect (17 eyes), abnormal (10 eyes), and normal (1 eye). Epithelial mapping revealed significantly thinner epithelium at steepest anterior tangential location and significantly bigger difference between the maximum and minimum epithelial thickness in the central 6-mm zone in keratoconus eyes. **Conclusion:** The MS39 was sensitive in detecting eyes with clinically diagnosed keratoconus. OCT epithelial mapping is useful in differentiating normal from keratoconus eyes.

Functional Outcomes of LASIK in Breastfeeding Women: A Retrospective Comparative Study

RP30068467

Senior Author: Georges Khattar MD
Coauthor: Ali Fadlallah Yahya MD

Purpose: To compare the outcomes, safety, efficacy, and predictability of LASIK between a group (Group 1) of breastfeeding women, 3 months postpartum, and a group (Group 2) of nonbreastfeeding women. **Methods:** The patients were separated into 2 well-matched groups. Uncorrected distance visual acuity (UDVA), corrected distance visual acuity, manifest refraction spherical equivalent, Schirmer II testing, and infection rate were evaluated preoperatively and at 1 week, 1 month, and 6 months after treatment. Moreover, adverse events in infants were assessed, as well as the need for any additional interventions. **Results:** Group 1 comprised 2251 patients (4501 eyes); and Group 2, 103 patients (205 eyes). The outcomes were comparable between both groups, with a stable UDVA of −0.080 ± 0.14 logMAR in Group 1 and of −0.078 ± 0.12 logMAR in Group 2 at 6 months (P = .344). Schirmer testing results were also comparable (P = .212, after 1 month). No complications were recorded in either of the groups or in the breastfed infants. No further interventions within 1 year after the procedure were required. **Conclusion:** LASIK in breastfeeding women is safe and efficient.

Minimally Invasive, Rapid-Recovery Ray Tracing Customized Myopic PRK: One-Year Clinical Data of a Novel Technique

RP30068474

Senior Author: A John Kanellopoulos MD

Purpose: Safety and efficacy of customized-minimal PRK. **Methods:** Twenty patients (40 eyes) underwent customized PRK for myopia with custom-shape and diameter epithelial removal, bromfenac 0.9 mg/mL the first postoperative day. Visual acuity, corrected and uncorrected distance visual acuity (CDVA and UDVA), refraction, and postoperative pain were measured on a subjective scale, and epithelial healing and epithelial mapping profile were evaluated for 12 months. **Results:** Pain scores were 0.27 ± 0.15 (0-4). Day 2 epidefect was 1.52 ± 1.23 mm^2. Eight eyes were not epithelialized by Day 3, and none by Day 4. Four patients reported use of additional analgesia. All eyes were 20/25 immediately after the procedure, and all were 20/25 by Day 4. At 3 months UDVA was 20/15.5, residual refractive error: −0.15 D. Residual manifest cylinder: −0.18 D; high-order aberrations: 0.21 µm. **Conclusion:** PRK may minimize pain and visual debilitation by accelerating re-epithelialization and early visual recovery. These data appear superior to LASIK and SMILE for the immediate postop rehabilitation and restrictions, similar in discomfort experienced with both of these lamellar procedures, with a potentially superior intraoperative safety profile.

Epithelial Remodeling and CXL-Line Depth in Keratoconus Following CXL Combined With Excimer Corneal Reshaping
RP30068476

Senior Author: Ioanna Kontari MD
Coauthor: A John Kanellopoulos MD

Purpose: To evaluate epithelial remodeling and CXL-line depth in keratoconus (KCN) eyes following surface ablation normalization combined with corneal crosslinking (CXL) (Athens protocol). **Methods:** Anterior segment OCT (AS-OCT) was used to obtain in vivo 3-dimensional corneal and epithelial thickness maps and specific location variability data, as well as cross-section assessment of the average depth and width of the CXL-derived intrastromal line. **Results:** Forty-three treated KCN eyes were evaluated over 2 years. The mean overall epithelial thickness (ET) changed from 54.6 to 52.6 µm; superior vs. inferior change: 56.9 and 52.3 µm to 53.3 and 52 µm. ET change over cone center, 45.1 to 53.2. [LV1] All differences were statistically significant >0.01. CXL line mean depth: 265 µm. **Conclusion:** Normal thickness over the cone center along with documentation of deep CXL line may serve as result efficacy along with corneal thickness and curvature stability over time in CXL with the Athens Protocol in KCN.

LASIK vs. SMILE for Myopia and Myopic Astigmatism: Four-Year Data of a Randomized, Prospective, Contralateral Eye Study
RP30068477

Senior Author: Ioanna Kontari MD
Coauthor: A John Kanellopoulos MD

Purpose: To compare the long-term safety and efficacy of topography-guided LASIK (TGL) vs. contralateral eye SMILE for myopia and myopic astigmatism correction. **Methods:** This contralateral eye study included 44 eyes of 22 patients; 22 eyes were treated with TGL, and the fellow eye of each patient was treated with SMILE. The following parameters were evaluated preoperatively and up to 48 months postoperatively: uncorrected distance vision acuity (UDVA), corrected distance vision acuity (CDVA), refractive error, corneal keratometry, contrast sensitivity, and retreatments. **Results:** At 48 months, 92.4% of the TGL group and 79.2% of the SMILE group had UDVA of 20/20 ($P < .002$), and 62.3% and 34.5%, respectively, had UDVA of 20/16 ($P < .002$). Spherical equivalent refraction (±0.50 D) was 95.5% for the LASIK group and 76.3% for the SMILE group ($P < .002$). Residual refraction cylinder (≤0.25 D) was 81.8% for the LASIK group and 50% for the SMILE group ($P < .001$). Two eyes of the SMILE group underwent PRK retreatment. **Conclusions:** Topography-guided LASIK was superior in all visual performance parameters studied, over long-term follow-up.

Initial Outcomes With Customized Myopic LASIK Guided by Automated Ray Tracing Optimization—A Novel Technique
RP30068479

Senior Author: Vasilis Skouteris MD
Coauthor: A John Kanellopoulos MD

Purpose: Safety and efficacy of a novel excimer ablation in myopic LASIK. **Methods:** In a consecutive case series, 20 patients (40 eyes) treated with myopic femtosecond laser–assisted LASIK with this technique: The novel artificial-intelligence platform initially calculates the ablation profile based on a model eye for each case, based on interferometry axial length data. Low- and high-order aberration calculation is performed by ray tracing based on wavefront and Scheimpflug tomography measurements, all from a single diagnostic device. Visual acuity, refractive error, keratometry, topography, high-order aberrations, and contrast sensitivity were evaluated over 3 months of follow-up. **Results:** Change from pre- to postoperative: mean refractive error from −5.49 ± 2.54 D (range: −8.0 to −0.50 D) to −0.07 ± 0.09 D at 6 months; refractive astigmatism from −1.07 ± 0.91 D (range: −3.75 to 0 D) to −0.11 ± 0.04 D; topographic astigmatism from −1.65 ± 0.85 to −0.26 ± 0.11. Sixty-five percent of eyes gained 1 line of vision, and 38% gained 2 lines. **Conclusion:** Ray-tracing optimization appears to offer improved and predictable visual outcomes.

Determining the Utility of Epithelial Thickness Mapping in Refractive Surgery Evaluations
RP30068481

Senior Author: Lara Asroui BS MD
Coauthors: William J Dupps MD PhD and J Bradley Randleman MD

Purpose: To determine how corneal epithelial thickness maps impact screening for refractive surgery candidacy. **Methods:** A retrospective evaluation of 137 patients was conducted. Each patient was screened based on Scheimpflug tomography, clinical data, and patient history. Patients were rescreened after addition of their epithelial thickness maps derived from OCT. **Results:** Candidacy for corneal refractive surgery changed in 16.00% of patients after evaluation of the epithelial thickness maps, with 36.36% of changes resulting in screening-out patients, and 63.64% resulting in screening-in patients. In the subset of patients that remained candidates for surgery, surgery of choice changed in 16.00% of cases. **Conclusion:** Epithelial thickness mapping derived from OCT imaging of the cornea impacted candidacy for corneal refractive surgery, as well as choice of surgery, in a substantial percentage of patients, when added to the refractive screening process. Overall, the use of epithelial thickness maps results in screening-in a slightly higher percentage of patients for corneal refractive surgery.

Two-Year Outcomes of Topography-Guided PRK With CXL for Keratoconus

RP30068484

Senior Author: Simon P Holland MD
Coauthors: Geoffrey Ching, David T C Lin MD, Gregory Moloney MD, and Ahmed Hamroush FRCS MBChB MRCOphth

Purpose: To evaluate 2-year results of topography-guided photorefractive keratectomy (TG-PRK) with simultaneous collagen crosslinking (CXL) for keratoconus (KC). **Methods:** We assessed the outcomes of KC management using TG-PRK with the Schwind Amaris 1050 excimer laser and simultaneous CXL. Preoperative and postoperative uncorrected distance visual acuity (UDVA), corrected distance visual acuity (CDVA), manifest refraction (MR), and topographic data were analyzed. **Results:** Eighty-eight eyes had sufficient data at 2 years for analysis. Fifty eyes showed UDVA ≥20/40 postoperatively. Thirty-six eyes had improved CDVA, and 20 gained 2 or more lines, while 22 eyes lost CDVA, with 8 eyes losing 2 lines or more. Mean astigmatism changed from 2.83 ± 1.81 D to 1.82 ± 1.64 D. Mean spherical equivalent improved from –3.46 ± 3.65 D to –0.52 ± 2.14 D. Four eyes showed KC progression, and 5 had haze sufficient to reduce CDVA. **Conclusion:** Two-year results of TG-PRK with CXL for KC show that it may provide an alternative for contact lens–intolerant keratoconus patients.

Outcome of Transepithelial PRK for Extreme Myopia With High-Speed Excimer Laser and Advanced Laser Beam Profile

RP30068485

Senior Author: Simon P Holland MD
Coauthors: Geoffrey Ching, David T C Lin MD, Gregory Moloney MD, and Ahmed Hamroush FRCS MBChB MRCOphth

Purpose: Evaluation of postoperative outcomes of transepithelial photorefractive keratectomy (TE-PRK) in extremely myopic eyes using Schwind Amaris 1050 (SA) with SmartSurfACE beam profile. **Methods:** Twelve-month postoperative outcomes of TE-PRK treatments using SA with SmartSurfACE beam profile were collected. Manifest refraction, uncorrected distance visual acuity (UDVA), corrected distance visual acuity (CDVA), and change of CDVA from baseline were evaluated. **Results:** 150 eyes with a mean preoperative spherical equivalent of –11.69 ± 1.54 D were included. The achieved treatment effect ranged from -10.1 D to –16.9 D (mean: –12.1 D). 132 eyes (88%) showed UDVA ≥20/40 postoperatively. 143 eyes (95%) had unchanged or improved CDVA, 53 eyes (35%) had gained 1 line or more, and 9 eyes (6%) gained 2 lines or more. Two eyes (1%) lost 2 lines or more. Four eyes had visually significant haze. **Conclusion:** TE-PRK with SA achieved good safety and efficacy in eyes with extreme myopia (≥ –10 D) and may be considered for correction of extreme myopia.

Outcome of PRK With Advanced Beam Profile for Myopia

RP30068486

Senior Author: David T C Lin MD
Coauthors: Geoffrey Ching, Simon P Holland MD, Gregory Moloney MD, and Ahmed Hamroush FRCS MBChB MRCOphth

Purpose: Outcomes of transepithelial photorefractive keratectomy (TE-PRK) using the Schwind Amaris 1050 (SA) laser with SmartSurfACE beam profile for myopia were evaluated. **Methods:** Patients with moderate myopia (0.00 D to –6.00 D), high myopia (–6.12 D to –10.00 D), and extreme myopia (> –10.00 D) were included. Pre- and 12-month postoperative uncorrected distance visual acuity (UDVA), corrected distance visual acuity (CDVA), and manifest refraction were noted. **Results:** 1522 eyes with moderate myopia, 530 eyes with high myopia, and 150 eyes with extreme myopia were evaluated. Mean spherical equivalent improved from –3.55 ± 1.41 D to 0.13 ± 0.38 D, –7.63 ± 1.12 D to 0.05 ± 0.49 D, and –11.69 ± 1.52 D to 0.04 ± 0.69 D, respectively. UDVA ≥20/25 was achieved by 1461 (96%), 482 (91%), and 116 (77%) eyes, respectively. CDVA ≥20/20 was achieved by 1476 (97%), 504 (95%), and 123 (82%) eyes, respectively. 1492 (98%), 514 (97%), and 143 (95%) eyes had improved or unchanged CDVA, respectively. **Conclusion:** TE-PRK with SA showed efficacy and safety in a range of myopic eyes.

Topography-Guided PRK for Correction of Irregular Astigmatism Following Penetrating Keratoplasty

RP30068487

Senior Author: David T C Lin MD
Coauthors: Geoffrey Ching, Simon P Holland MD, Gregory Moloney MD, and Ahmed Hamroush FRCS MBChB MRCOphth

Purpose: Post-penetrating keratoplasty (PK) eyes may have high and irregular astigmatism refractory to rigid contact lens correction. We evaluated the effectiveness of topography-guided photorefractive keratectomy (TG-PRK) for the correction of irregular astigmatism following PK. **Methods:** Patients with 12 months of follow-up data were included. Preoperative and postoperative uncorrected distance visual acuity (UDVA), corrected distance visual acuity (CDVA), manifest refraction (MR), and topographic cylinder were analyzed. **Results:** Forty-seven eyes were analyzed. Postoperatively, 17 eyes (36%) had UDVA ≥20/40 compared to none preoperatively. Twenty-two eyes (47%) had improved CDVA. Fourteen eyes (30%) gained ≥2 lines. Five eyes (11%) lost ≥2 lines. Mean astigmatism reduction was 2.38 ± 2.44 D. Mean spherical equivalent improved from –3.11 ± 3.92 D to –1.49 ± 2.21 D. Five eyes had delayed epithelial healing without long-term sequelae. **Conclusion:** TG-PRK showed efficacy and safety for treatment of irregular astigmatism in contact lens–intolerant post-PK patients.

Topography-Guided PRK for Irregular Astigmatism After Radial Keratotomy Using a High-Speed Laser
RP30068488

Senior Author: Ahmed Hamroush FRCS MBChB MRCOphth
Coauthors: Geoffrey Ching, David T C Lin MD, Simon P Holland MD, and Gregory Moloney MD

Purpose: To evaluate topography-guided photorefractive keratectomy (TG-PRK) for irregular astigmatism after radial keratotomy (RK) with Schwind Amaris 1050 (SA). **Methods:** Forty-six RK eyes treated with SA 1050 excimer laser with CXL with Athens protocol. Preoperative and postoperative uncorrected distance visual acuity (UDVA), corrected distance visual acuity (CDVA), manifest refraction (MR), and topographic cylinder were analyzed after 12 months of follow-up. **Results:** Twenty-three eyes (51%) showed UCVA ≥20/40 postoperatively. Eighteen eyes (39%) had improved CDVA, and 5 (11%) gained ≥2 lines while 1 (2%) lost 2 or more lines. Mean astigmatism was reduced from 2.51 ± 1.94 D to 1.11 ± 0.96 D. Mean spherical equivalent improved from 1.97 ± 1.95 D to −0.77 ± 2.08 D. **Conclusion:** Early results of TG-PRK CXL with SA show efficacy and safety in treating post-RK irregular astigmatism. More than a half (51%) had UDVA ≥20/40 at 1 year, and 39% had CDVA improved. The technique may be an alternative treatment for post-RK with contact lens intolerance.

Evaluation on 1-Year Outcome of Topography-Guided PRK and CXL for Post-LASIK Ectasia
RP30068489

Senior Author: Ahmed Hamroush FRCS MBChB MRCOphth
Coauthors: Geoffrey Ching, David T C Lin MD, Simon P Holland MD, and Gregory Moloney MD

Purpose: Topography-guided photorefractive keratectomy (TG-PRK) for post-LASIK ectasia (EC) with crosslinking (CXL) using a Schwind Amaris 1050 excimer laser (SA) was newly evaluated. **Methods:** Post-LASIK ectatic eyes that underwent treatment with the SA and Athens protocol CXL were evaluated. Preoperative and 12-month postoperative uncorrected distance visual acuity (UDVA), corrected distance visual acuity (CDVA), manifest refraction (MR), and topographic cylinder were analyzed. **Results:** Forty-three eyes with complete data at 12 months were included. Twenty-nine eyes (67%) showed UDVA ≥20/40 postoperatively. Fifteen eyes (35%) had improved CDVA. Seven eyes (16%) gained 2 or more lines, while 2 eyes (5%) lost 2 lines or more. No cases showed ectatic progression. Mean astigmatism changed from 3.05 ± 1.43 D to 0.98 ± 0.99 D. Mean spherical equivalent improved from −1.48 ± 3.42 D to −0.32 ± 1.75 D. **Conclusion:** Early results of TG-PRK CXL as a treatment for post-LASIK ectasia show safety and efficacy as a potential alternative treatment for post-LASIK ectasia.

Meeting High Expectations: Transepithelial PRK for Very Low Myopic and Astigmatic Corrections
RP30068490

Senior Author: Gregory Moloney MD
Coauthors: Geoffrey Ching, David T C Lin MD, Simon P Holland MD, and Ahmed Hamroush FRCS MBChB MRCOphth

Purpose: We evaluated transepithelial photorefractive keratectomy (TE-PRK) for very low myopia and/or myopic astigmatism using Schwind Amaris (SA) 1050 with SmartSurfACE. **Methods:** Patients with preoperative spherical equivalent (SE) of ≥ −0.50 D to ≤ −1.50 D with ≤1.50 D cylinder and who were treated with TE-PRK using SA 1050 SmartSurfACE were included. Data analysis included pre- and 12-month postoperative uncorrected distance visual acuity (UDVA), corrected distance visual acuity (CDVA), and spherical equivalent. **Results:** Eighty-four eyes were included. Twenty-three eyes had undergone cataract and/or laser refractive surgery previously. Preoperative SE of −1.23 ± 0.28 D improved postoperatively to 0.08 ± 0.28 D. All cases achieved UDVA ≥20/40 at 12 months, and 81 eyes achieved ≥20/25. Twenty eyes gained 1 line or more of CDVA, and 4 eyes lost 1 line or more of CDVA. **Conclusion:** Patients with very low myopic and myopic astigmatic refractive error after cataract or laser refractive surgery may be treated with TE-PRK using the SA 1050 excimer laser.

Topography-Guided PRK for Retreatment on Post-LASIK Refractive Error
RP30068491

Senior Author: Geoffrey Ching
Coauthors: David T C Lin MD, Simon P Holland MD, Gregory Moloney MD, and Ahmed Hamroush FRCS MBChB MRCOphth

Purpose: Evaluation of early results of topography-guided photorefractive keratectomy (TG-PRK) for retreatment on post-LASIK residual refractive error with SmartSurfACE (SS) and Schwind Amaris 1050 (SA) excimer laser. **Methods:** Eyes with post-LASIK residual refractive error that underwent treatment with SA and SS technology were evaluated. Preoperative and 6-month postoperative uncorrected distance visual acuity (UDVA), corrected distance visual acuity (CDVA), manifest refraction (MR), spherical equivalent (SE), and topographies were analyzed. **Results:** Seventy-five eyes were included. Thirty-three eyes (44%) showed UDVA ≥20/40 preoperatively. This improved to 61 eyes (81%) postoperatively. Sixty-two eyes (83%) had unchanged or improved CDVA, while 3 eyes (4%) lost 2 or more lines. Mean SE improved from −0.93 ± 1.84 D to −0.22 ± 1.04 D. Mean astigmatism changed from 0.97 ± 1.11 D to 0.50 ± 0.73 D. **Conclusion:** Early results of TG-PRK with SS and SA show efficacy and safety as treatment for post-LASIK residual refractive error.

Comparison of 2 Different Preservative-Free Lubricant Eyedrops on the Ocular Surface in the Early Postop of PRK: A Prospective, Randomized, Controlled Pilot Study

RP30068492

Senior Author: Miguel A Teus MD
Coauthors: Rafael Cañones-Zafra MD PhD, Juan Pedro Abad-Montes MD, Miriam Alonso-Castellanos, and Francisco Aviles-Rogel

Purpose: To compare the effect of a conventional preservative-free (PF) artificial tear containing carmellose (control group) with another with hyaluronic acid (HA) and hydroxypropyl guar (HP Guar) (study group) in the early postop of PRK. **Methods:** In this ongoing, randomized, dual-arm, prospective, interventional, single masked study, a total of 75 eyes scheduled to have PRK to correct myopia were randomized in 2 groups: 42 eyes in the HA+HP Guar group (study eyes) and 33 in the carmellose group (control eyes). In both groups, ocular surface and ocular pain were evaluated at postop days 1, 4, and 7 and at 1 month. **Results:** Both groups were comparable in terms of age, gender, and preop refractive error magnitude ($P < .05$). A statistically significant smaller de-epithelized area was observed at postop Day 4 in the study group vs. controls (0.07 ± 0.3 mm vs. 0.62 ± 0.2 mm; $P = .04$). A statistically significant decrease in ocular pain was observed at Day 3 postop in the study group (3.77 ± 2.2 vs. 5.31 ± 2.2; $P = .003$). **Conclusion:** The use of topical lubricants containing HA and HP Guar seems to provide a clinical benefit in the early postop of PRK.

Evaluating Visual Outcomes of Wavefront-Guided PRK With Mitomycin C in Patients With Moderate to High Myopia

RP30068500

Senior Author: Samuel A Schadt DO
Coauthors: Jacklyn Mahgerefteh DO, Jennifer M Loh MD, William B Trattler MD, and Roya Garakani DO

Purpose: To evaluate visual outcomes of wavefront-guided PRK using a single-use polymer epithelial removal device along with mitomycin C (MMC) 0.02% for 12 seconds in patients with moderate to high myopia (–4.5 D to –10 D). **Methods:** Retrospective analysis of wavefront-guided PRK performed by multiple surgeons. All eyes underwent preoperative evaluation with a high-resolution aberrometer. The epithelium was removed with a single-use polymer spatula. Following laser ablation, MMC 0.02% was used for 12 seconds. **Results:** Seventy-six eyes were evaluated. The mean age was 32 (18-51). The average preop sphere was –6.34 D (range: –4.5 to –10). The average ablation depth was 97 microns (range: 56 to 135 microns). Patients achieving a final UCVA of 20/25 or better was 74%. Eleven eyes had UCVA of 20/40 or worse, although these 11 patients all had short follow-up (36 days or less). Patients achieving a final BCVA of 20/25 or better was 86%. No patients experienced visually significant haze or infection. **Conclusion:** This study demonstrates that wavefront-guided PRK with a high-resolution aberrometer for moderate to high myopia with a polymer epithelial removal device along with MMC provides great outcomes.