

Refractive Surgery 2018

Better Together— Lens- and Cornea-Based Surgery

Program Directors

William B Trattler MD and Marcony R Santhiago MD

The Annual Meeting of the International Society of Refractive Surgery (ISRS)



Sponsored by ISRS

McCormick Place
Chicago, Illinois
Friday, Oct. 26, 2018

Presented by:
The American Academy of Ophthalmology



AMERICAN ACADEMY
OF OPHTHALMOLOGY®
Protecting Sight. Empowering Lives.

Refractive Surgery 2018 Planning Group

William B Trattler MD

Program Director

Marcony R Santhiago MD

Program Director

Renato Ambrósio Jr MD

John So-Ming Chang MD

Daniel S Durrie MD

J Bradley Randleman MD

George O Waring IV MD

Former Program Directors

2017 Renato Ambrósio Jr MD

William B Trattler MD

2016 Bonnie A Henderson MD

Renato Ambrósio Jr MD

2015 A John Kanellopoulos MD

Bonnie A Henderson MD

2014 Sonia H Yoo MD

A John Kanellopoulos MD

2013 Michael C Knorz MD

Sonia H Yoo MD

2012 David R Hardten MD

Michael C Knorz MD

2011 Amar Agarwal MD

David R Hardten MD

2010 Ronald R Krueger MD

Amar Agarwal MD

2009 Gustavo E Tamayo MD

Ronald R Krueger MD

2008 Steven C Schallhorn MD

Gustavo E Tamayo MD

2007 Francesco Carones MD

Steven C Schallhorn MD

2006 Steven E Wilson MD

Francesco Carones MD

2005 Jorge L Alió MD PhD

Steven E Wilson MD

2004 John A Vukich MD

Jorge L Alió MD PhD

2003 Terrence P O'Brien MD

John A Vukich MD

2002 Daniel S Durrie MD

Terrence P O'Brien MD

2001 Douglas D Koch MD

Daniel S Durrie MD

2000 Richard L Lindstrom MD

Douglas D Koch MD

1999 Marguerite B McDonald MD

Richard L Lindstrom MD

1998 Peter J McDonnell MD

Marguerite B McDonald MD

1995–1997 Peter J McDonnell MD

2018 ISRS Executive Committee

John So-Min Chang MD, President

Renato Ambrósio Jr MD

Deepinder K Dhaliwal MD

Damien Gatinel MD

A John Kanellopoulos MD

Aylin Kılıç MD

Ronald R Krueger MD

Jodhbir S Mehta MBBS PhD

Zoltan Nagy MD

Sonia H Yoo MD

Subspecialty Day Advisory Committee

Daniel S Durrie MD

Associate Secretary

Julia A Haller MD

Michael S Lee MD

Francis S Mah MD

R Michael Siatkowski MD

Kuldev Singh MD MPH

Maria M Aaron MD

Secretary for Annual Meeting

Staff

Melanie R Rafaty CMP DES, *Director,
Scientific Meetings*

Ann L'Estrange, *Subspecialty Day Manager*

Carolyn Little, *Presenter Coordinator*

Debra Rosencrance CMP CAE, *Vice*

President, Meetings & Exhibits

Patricia Heinicke Jr, *Copy Editor*

Mark Ong, *Designer*

Gina Comaduran, *Cover Designer*

2018 Refractive Surgery Subspecialty Day Planning Group

On behalf of the American Academy of Ophthalmology and the International Society of Refractive Surgery, it is our pleasure to welcome you to Chicago and **Refractive Surgery 2018: Better Together—Lens- and Cornea-Based Surgery**, the Annual Meeting of the International Society of Refractive Surgery.



William B Trattler MD
Program Director

Abbott Medical Optics: C,L
Alcon Laboratories Inc.: C
Allergan Inc.: C,L,S
Alphaeon: O
ArcScan: O
Avedro: L,O,C
Bausch + Lomb: C,L
CXLO: C,O | CXLUSA: C
Guardian Health: C,O
Healthe: O | LensAR: C
Oculus Inc.: L
Shire: C,L | Sun: C,L
Vmax Vision: C



Marcony R Santhiago MD
Program Director

Alcon Laboratories Inc.: C,L
Ziemer: C

**Renato Ambrósio Jr MD**

Alcon Laboratories Inc.: C
 Allergan: L
 Carl Zeiss Inc.: L
 Mediphacos: L
 Oculus Inc.: C

**John So-Ming Chang MD**

Abbott Medical Optics: L
 Alcon Laboratories Inc.: L
 Avedro Inc.: L
 Johnson & Johnson: L

**Daniel S Durrie MD**

AcuFocus Inc.: C,L,O
 Alcon Laboratories Inc.: S
 Alphaeon: C,O
 Avedro: C,L,O
 Concierge Key Health: C,O
 Eyedotec Medical Inc.: C
 Eyegate Pharma: C
 Hoopes Durrie Rivera Research
 Center: C
 Johnson & Johnson Vision: C,L
 Strathspey Crown LLC: C,O

**J Bradley Randleman MD**

None

**George O Waring IV MD**

Abbott Medical Optics Inc.: C,L
 ACE Vision Group: C
 AcuFocus Inc.: C,L
 Alcon Laboratories Inc.: C,L
 Allergan: C,L
 Avedro: C,L
 Bausch + Lomb: C,L
 Gerson Lehrman Group: C
 GlassesOff: C
 Glaukos Corp.: C,L
 Johnson & Johnson Vision: C,L
 Minosys: C
 Oasis Medical Inc.: C,L
 Oculus Inc.: L,C
 Omega Ophthalmics: C
 Perfect Lens LLC: C
 Refocus Group Inc.: C
 Strathspey Crown: O
 Visiometrics: C,O

2018 Subspecialty Day Advisory Committee

Daniel S Durrie MD, Chair (Refractive Surgery)

AcuFocus Inc.: C,L,O
Alcon Laboratories Inc.: S
Alphaeon: C,O
Avedro: C,L,O
Concierge Key Health: C,O
Eyedotec Medical Inc.: C
Eyegate Pharma: C
Hoopes Durrie Rivera Research
Center: C
Johnson & Johnson Vision: C,L
Strathspey Crown LLC: C,O

Julia A Haller MD (Retina)

Aura Biosciences: C
Celgene: O | KalVista: C
Lowy Medical Research
Institute: C
Novartis Pharmaceuticals
Corp.: C
Spark Therapeutics: C

Michael S Lee MD (Neuro-Ophthalmology)

National Eye Institute: S
Quark Pharmaceuticals: S
Springer: P
Uptodate: P

Francis S Mah MD (Cornea)

Abbott Medical Optics
Inc.: C,L,S
Aerie: C | Alcon: C
Allergan: C
Avedro, Inc.: C
Avellino Labs: C
Bausch Lomb: C,L
CoDa: C | EyePoint: C
inVista: C | iView: C
KALA: C
Mallinckrodt Pharmaceuticals: C
NovaBay: C
Novartis, Alcon Pharmaceuticals:
C,L
Ocular Science: C,O
Ocular Therapeutix: C,S
Okogen: C,O
Omeros Corporation: C
PolyActiva: C
RxSight: C
Senju: S | Shire: C,L
Slack Publishing: C,P
Sun Pharma: C,L
Sydnexis: C,O
TearLab: C

R Michael Siatkowski MD (Pediatric Ophthalmology)

National Eye Institute: S

Kuldev Singh MD MPH (Glaucoma)

Aerie: C
Alcon Laboratories Inc.: C
Allergan: C
Belkin Laser Ltd.: C
Glaukos Corp.: C
InjectSense: C | Ivantis: C
Johnson & Johnson: C
Mynosys: C
National Eye Institute: S
Novartis Institute for Biomedical
Research: C
Ocular Therapeutix Inc.: C
Santen Inc.: C | Shire: C
Thieme Medical Publishers: C
U.S. Food and Drug
Administration: C,S

AAO Staff

Ann L'Estrange

None

Carolyn Little

None

Melanie Rafaty

None

Debra Rosencrance

None

Beth Wilson

None

Refractive Surgery 2018 Contents

	Program Planning Group	ii
	CME	vi
	2018 Award Winners	viii
	Faculty Listing	xiii
	How to Use the Audience Interaction Application	xviii
	Program Schedule	xix
	Keynote Lecture: Thirty Years of Laser Vision Correction	1
Section I:	Advances in Refractive Surgery	2
Section II:	Management and Prevention of Complications in Refractive Surgery	24
Section III:	Video-Based Master Complications	31
	Advocating for the Profession and Patients	49
Section IV:	ESCRS Symposium—Will Small-Incision Lenticule Extraction Replace LASIK?	52
	Troutman Prize: Histological and microRNA Signatures of Corneal Epithelium in Keratoconus	56
Section V:	The <i>Journal of Refractive Surgery</i> 's Hot, Hotter, Hottest—Late Breaking News	56
	Faculty Financial Disclosure	67
	Presenter Index	71
Non-CME	ePosters	73
	Break With the Experts	91

CME Credit

Academy's CME Mission Statement

The purpose of the American Academy of Ophthalmology's Continuing Medical Education (CME) program is to present ophthalmologists with the highest quality lifelong learning opportunities that promote improvement in physician practice, resulting in the best possible eye care for their patients

2018 Refractive Surgery Subspecialty Day Learning Objectives

Upon completion of this activity, participants should be able to:

- Evaluate the latest techniques and technologies in refractive surgery, specifically the latest and emerging techniques and technologies in cornea biomechanics, cornea imaging, IOL calculations, and ectasia detection
- Identify the current status and future of femtosecond laser, excimer laser, inlay, intracorneal ring segment, crosslinking, and IOL refractive surgery
- Compare the pros and cons of various lens- and corneal-based modalities, including presbyopic and toric IOLs
- Describe the increasing importance of refractive surgery in any ophthalmology practice and the reasons to consider this subspecialty to improve patient care

2018 Refractive Surgery Subspecialty Day Target Audience

The intended audience for this program is comprehensive ophthalmologists; refractive, cataract, and corneal surgeons; and allied health personnel who are performing or assisting in refractive surgery.

2018 Refractive Surgery Subspecialty Day CME Credit

The American Academy of Ophthalmology is accredited by the Accreditation Council for Continuing Medical Education (ACCME) to provide CME for physicians.

The Academy designates this live activity for a maximum of 7 *AMA PRA Category 1 Credits*[™]. Physicians should claim only the credit commensurate with the extent of their participation in the activity.

Teaching at a Live Activity

Teaching instruction courses or delivering a scientific paper or poster is not an *AMA PRA Category 1 Credit*[™] activity and should not be included when calculating your total *AMA PRA Category 1 Credits*[™]. Presenters may claim *AMA PRA Category 1 Credits*[™] through the American Medical Association. To obtain an application form please contact the AMA at www.ama-assn.org.

Scientific Integrity and Disclosure of Conflicts of Interest

The American Academy of Ophthalmology is committed to ensuring that all CME information is based on the application of research findings and the implementation of evidence-based medicine. It seeks to promote balance, objectivity, and absence of commercial bias in its content. All persons in a position to control the content of this activity must disclose any and all financial interests. The Academy has mechanisms in place to resolve all conflicts of interest prior to an educational activity being delivered to the learners.

The Academy requires all presenters to disclose on their first slide whether they have any financial interests from the past 12 months. Presenters are required to verbally disclose any financial interests that specifically pertain to their presentation.

Control of Content

The American Academy of Ophthalmology considers presenting authors, not coauthors, to be in control of the educational content. It is Academy policy and traditional scientific publishing and professional courtesy to acknowledge all people contributing to the research, regardless of CME control of the live presentation of that content. This acknowledgment is made in a similar way in other Academy CME activities. Though coauthors are acknowledged, they do not have control of the CME content, and their disclosures are not published or resolved.

Attendance Verification for CME Reporting

Before processing your requests for CME credit, the American Academy of Ophthalmology must verify your attendance at Subspecialty Day and/or AAO 2018. In order to be verified for CME or auditing purposes, you must either:

- Register in advance, receive materials in the mail, and turn in the *Subspecialty Day Syllabi* exchange voucher(s) onsite;
- Register in advance and pick up your badge onsite if materials did not arrive before you traveled to the meeting;
- Register onsite; or
- Scan the barcode on your badge as you enter an AAO 2018 course or session room.

CME Credit Reporting

South Building Level 2.5 and Academy Resource Center

Attendees whose attendance has been verified (see above) at AAO 2018 can claim their CME credit online during the meeting. Registrants will receive an email during the meeting with the link and instructions on how to claim credit.

Onsite, you may report credits earned during Subspecialty Day and/or AAO 2018 at the CME Credit Reporting booth.

Academy Members

The CME credit reporting receipt is not a CME transcript. CME transcripts that include AAO 2018 credits entered at the Academy's annual meeting will be available to Academy members through the Academy's CME web page (www.aao.org/cme-central) beginning Thursday, Dec. 13.

The Academy transcript cannot list individual course attendance. It will list only the overall credits claimed for educational activities at Subspecialty Day and/or AAO 2018.

Nonmembers

The Academy provides nonmembers with verification of credits earned and reported for a single Academy-sponsored CME activity. To obtain a printed record of your credits, claim CME credits onsite at the CME Credit Reporting kiosks. Nonmembers choosing to claim online through the Academy's CME web page (www.aao.org/cme-central) after December 13 will have one opportunity to print a certificate.

Proof of Attendance

The following types of attendance verification are available during AAO 2018 and Subspecialty Day for those who need it for reimbursement or hospital privileges, or for nonmembers who need it to report CME credit:

- CME credit reporting / proof-of-attendance letters
- Onsite registration receipt
- Instruction course and session verification

You must have obtained your proof of attendance at the CME Credit Reporting kiosks onsite, located in South, Level 2.5, and in the Academy Resource Center.

2018 Award Winners

José I Barraquer Lecture and Award

The José I Barraquer Lecture and Award honors a physician who has made significant contributions in the field of refractive surgery during his or her career. This individual exemplifies the character and scientific dedication of José I Barraquer MD—one of the founding fathers of refractive surgery.

Presidential Recognition Award

The Presidential Recognition Award is a special award that honors the recipient's dedication and contributions to the field of refractive surgery and to the ISRS.

José I Barraquer and Presidential Recognition Awards— Dr. Ronald R. Krueger



Ronald R Krueger
MD MSE

Dr. Ronald R Krueger, Medical Director of Refractive Surgery at the Cleveland Clinic Cole Eye Institute in Ohio, is a renowned ophthalmologic surgeon with more than 30 years of experience in the field of refractive surgery, specifically in excimer and femtosecond laser research and wavefront optics.

In 1982, Dr. Krueger graduated summa cum laude from Rutgers University with a BSEE in electrical engineering, followed by an MSE in bioengineering from the University of Washington in the following year. After receiving his medical training at the UMDNJ–New Jersey Medical School in 1987, he completed a residency in ophthalmology at Columbia Presbyterian Medical Center in New York City in 1991, followed by both a cornea fellowship at the Dean McGee Eye Institute at the University of Oklahoma and a refractive surgery fellowship at the Doheny Eye Institute of the University of Southern California in 1993.

Dr. Krueger has performed over 20,000 refractive surgery procedures and has published more than 150 peer-reviewed manuscripts, as well as numerous abstracts, book chapters, and trade journal articles. He is credited with documenting the first physical description of the effects of the excimer lasers on corneal tissue, in 1985, and coauthoring the first book on wavefront customized corneal ablation, in 2001. He also pioneered the development of femtosecond laser treatment of the crystalline lens and cataracts, leading to the cofounding of LensAR, Inc. in 2004, and the publication of the first textbook on the subject in 2013, *Refractive Laser Assisted Cataract Surgery (ReLACS)*.

Dr. Krueger teaches as a professor of ophthalmology at the Cleveland Clinic Lerner College of Medicine of Case Western Reserve University. He recently served as the president of the International Society of Refractive Surgery (ISRS) in partnership with the American Academy of Ophthalmology (the Academy) for the years 2014 and 2015. In addition, Dr. Krueger has served as the associate editor of the *Journal of Refractive Surgery* over the past 20 years, and he has lectured on refractive surgery in more than 40 countries.

Dr. Krueger has received numerous awards, including the National Leadership Award, the Castle Connolly America's Top Doctors award in 2005 and 2010, the 2007 Kritzing Memorial Award jointly presented by the ISRS and the Academy (ISRS/AAO), the 2008 Lans Distinguished Award of the ISRS/AAO, the Academy's 2014 Secretariat Award, the 2015 Founders Award of the ISRS/AAO, and in 2016, the Academy's Lifetime Achievement Award. In 2013, his thesis "Ultrashort-Pulse Lasers Treating the Crystalline Lens: Will They Cause Vision Threatening Cataract?" was accepted for membership in the American Ophthalmological Society (AOS), the oldest and most prestigious in U.S. ophthalmology. In 2018, he will receive the José I Barraquer Award and Lecture at AAO 2018, which is the most prestigious honor in refractive surgery worldwide.

2019 Barraquer Award—Dr. Noel Alpíns



Noel A Alpíns MD
FACS

Casebeer Award

The Casebeer Award recognizes an individual for his or her outstanding contributions to refractive surgery through nontraditional research and development activities.

Casebeer Award—Prof. Michael Mrochen



Professor Michael Mrochen PhD

Professor Michael Mrochen PhD (Dr. rer. medic.) is fully dedicated to improving diagnostics and treatments with ophthalmic medical devices from scientific, technological, and business perspectives. He developed multiple technologies in the field of ophthalmologic medical devices that led to bringing new applications and products to the market. In particular, he is recognized as a leading figure in customized corneal refractive surgery, corneal crosslinking, tissue

addition technology, biometry, wavefront sensing, and vision behavior monitoring. During the past 20 years he has cofounded multiple ophthalmic companies, driving innovation from work bench to clinical praxis in ophthalmology.

Prof. Mrochen's scientific achievements are represented by more than 120 peer-reviewed articles, book chapters, and proceedings in the field of ophthalmic devices. He has generated more than 30 national and international patents and patent applications. Prof. Mrochen is cofounder of the International Congress of Wavefront Sensing and the International Congress of Corneal Cross Linking.

He has received numerous awards, including the following: in 2003, the Troutman Award of the International Society of Refractive Surgery (ISRS) and the American Academy of Ophthalmology; in 2005, the Swiss Technology Award for the development of customized contact lenses; in 2007, finalist for the Swiss Economic Award for corneal crosslinking (last 3 in high tech); in 2010, the Congress of German Ophthalmic Surgeons (DOC) Bronze Medal; in 2013, the DOC Silver Medal; in 2014, listed as one of the 100 most influential people in ophthalmology (*The Ophthalmologist*); in 2015, the DOC Silver Medal; in 2015, the ISRS Recognition Award; in 2016, EyeAdvanced, Indian Academy of Ophthalmology, Meritorious Service Star; in 2016, the American Academy of Ophthalmology Achievement Award.

Founders' Award

The Founder's Award recognizes the vision and spirit of the Society's founders by honoring an ISRS member who has made extraordinary contributions to the growth and advancement of the Society and its mission.

Founders' Award—Dr. Renato Ambrósio



Renato Ambrósio Jr MD PhD

Prof. Ambrósio is the first son of the late Renato Ambrósio MD, who pioneered refractive surgery in Brazil in the early 1980s, and Vera Martins Ambrósio MD, a resilient and dedicated ophthalmologist who upheld the family practice after the premature decease of her husband in January 1994.

He belongs to a family with many ophthalmologists, including his younger brother, Rodrigo Martins Ambrósio MD, a talented retina surgeon; and his

beautiful wife, Renata Siqueira da Silva MD, a well-trained and skilled glaucoma and contact lens specialist.

Prof. Ambrósio concluded a residency in ophthalmology at the Instituto de Oftalmologia Tadeu Cvintal (São Paulo) in 1999, a fellowship program in Refractive Surgery and Cornea at the University of Washington (Seattle, WA) in October 2002, and the PhD, Doctorate in Sciences, at the Faculdade de Medicina da Universidade de São Paulo in May 2004.

In 2006, he was elected the president of the Brazilian Society of Administration in Ophthalmology, being in this position until July 2010. From 2012 until 2014, he was the last president of the Brazilian Society of Refractive Surgery before the Society's incorporation with the Brazilian Society of Cataract and Implants, for the creation of the Brazilian Association of Cataract and Refractive Surgery (BRASCRS). He was also vice-president of the Brazilian Council of Ophthalmology from 2013 until 2015 and has served on the ISRS Executive Committee since 2014.

In 2007, Prof. Ambrósio founded the Rio de Janeiro Corneal Tomography and Biomechanics Study Group, from which over 100 publications have originated. He is an affiliate professor of the Post-Graduation Program in Ophthalmology at the Pontifical Catholic University of Rio de Janeiro (*lato sensu*) and the Federal University of São Paulo (*stricto sensu*). In 2017, he was approved by public examination as an adjunct professor in ophthalmology at the Federal University of the State of Rio de Janeiro.

With more than 500 publications and more than 60 awards in Brazil and abroad, Prof. Ambrósio was voted the 11th most influential ophthalmologist by the British journal *The Ophthalmologist* in 2014, and again was included among the top 100 in 2016 and 2018.

Professor Ambrósio is a world-class refractive surgeon who is considered a true clinician-scientist. His major areas of interest are corneal tomography, biomechanical imaging and wavefront, custom laser vision correction, refractive cataract surgery, and therapeutic procedures for keratoconus. Besides his busy and proactive academic appointments, he is at private practice in Rio de Janeiro at Instituto de Olhos Renato Ambrósio and VisareRIO - Refracta Personal Laser.

Google Acadêmico entry: <https://scholar.google.com.br/citations?user=ACWjXwsAAAAJ&hl=pt-BR>; Research Gate profile: https://www.researchgate.net/profile/Renato_Jr/reputation; VisareRIO website: <https://www.visarerio.com.br>.

Kritzinger Memorial Award

The Kritzinger Memorial Award recognizes an individual who embodies the clinical, educational, and investigative qualities of Dr. Michiel Kritzinger, who advanced the international practice of refractive surgery.

Kritzinger Award—Dr. Soosan Jacob



Soosan Jacob MS
DNB FRCS

Dr. Soosan Jacob MS DNB FRCS, director and chief of Dr. Agarwal's Refractive and Cornea Foundation (DARCF), has won more than 50 international awards for her innovations, publications, and video films. Two-time winner of the American Society of Cataract and Refractive Surgery (ASCRS) Golden Apple award, recipient of the ASCRS Top-Gun Instructor award, the John Henahan Writing Prize for Young Ophthalmologists, the Innovator's

Award from the Connecticut Society of Eye Physicians, the *Journal of Refractive Surgery* (JRS) Waring Medal for editorial excellence, the AM Gokhale oration, the Harold Stein Innovator Lecture, and the Bruce Jackson oration, Dr. Jacob has authored 94 peer-reviewed publications and more than 200 chapters in 34 textbooks and is editor for 17 ophthalmology textbooks. She is chair of the International Society of Refractive Surgery (ISRS) Multimedia Library Editorial Board, a member of the ISRS Executive Committee, and associate editor of *JRS*, and she is on the editorial boards of the *International Journal of Ophthalmology*, *EyeNet* (AAO), *EuroTimes*, the *International Journal of Keratoconus and Ectatic Corneal Disease*, *Ocular Surgery News*—Asia-Pacific edition, *Glaucoma Today*, *Cataract and Refractive Surgery Today Europe*, *TNOA Journal of Ophthalmic Science and Research*, and *Ophthalmology & Therapy*.

Her latest award-winning innovations include corneal allogenic intrastromal ring segments (CAIRS) for keratoconus (winner of Best Paper of Session, ASCRS 2017); presbyopic allogenic refractive lenticule (PEARL) inlay for presbyopia (awards at ASCRS 2016 and Belgian Society of Cataract and Refractive Surgeons 2016, Best of Show at AAO 2016, and the JRS Waring Medal, 2017), and glued capsular hook for subluxated cataracts (first prize at ESCRS and AAO Global Video Contest).

Other award-winning innovations are contact lens–assisted crosslinking (CA-CXL) for thin corneas; stab-incision glaucoma surgery (SIGS); air-pump–assisted pre-Descemet endothelial keratoplasty and endoilluminator-assisted Descemet membrane endothelial keratoplasty (E-DMEK); classification of Descemet detachments into rhegmatogenous, tractional, bullous, and complex with treatment algorithm; relaxing Descemetotomy; turnaround technique for Intacs; glued endocapsular ring, anterior segment transplantation, supra-brow single-stab incision ptosis surgery, sequential segmental terminal lenticular side-cut dissection, and white ring sign for small-incision lenticule extraction (SMILE). Her educational YouTube channel (<http://goo.gl/9STje0>) is among the top-most heavily subscribed ophthalmic YouTube channels.

Lans Distinguished Lecturer Award

The Lans Distinguished Lecturer Award honors Dr. Leedert J Lans. Given annually, the award recognizes individuals who have made innovative contributions in the field of refractive surgery, especially in the correction of astigmatism.

Lans Award—Dr. Bonnie An Henderson



Bonnie An Henderson
MD

Bonnie An Henderson MD served as the President of the American Society of Cataract and Refractive Surgery from 2017 to 2018 and is a clinical professor at Tufts University School of Medicine. Dr. Henderson is the associate editor for the *Journal of Refractive Surgery*, and she has served as the associate editor of *Eyeworld* of the American Society of Cataract and Refractive Surgery and on the editorial board of *EyeNet Magazine* of the American

Academy of Ophthalmology.

Dr. Henderson has authored over 125 articles, papers, book chapters, and abstracts and has delivered over 275 invited lectures worldwide. She has published 5 textbooks in cataract and refractive surgery. Her textbook, *Essentials of Cataract Surgery*, is the one of most commonly used textbooks to teach cataract surgery in the United States. Dr. Henderson's principal research involves cataract surgery outcomes and innovative methods of teaching, including the development of a digital-based method for teaching cataract surgery, supported by a Department of Defense TATRIC grant. She has invented and commercialized a number of medical instruments, including the modified capsule tension ring, astigmatism-correcting markers, and a capsule polisher. She donates all of her royalties from the textbooks and instruments to charity.

Dr. Henderson has received an Achievement Award, Secretariat Award, and the Senior Achievement Award from the American Academy of Ophthalmology, as well as "Best of" awards from the American Society of Cataract and Refractive Surgery for her research and films and the Teacher of the Year award from Harvard Medical School. She has received the Visionary Award from the American-European Congress of Ophthalmic Surgery and the Suzanne Veronneau-Troutman Award from Women in Ophthalmology.

Dr. Henderson completed her ophthalmology residency at Harvard Medical School, Massachusetts Eye and Ear Infirmary. She graduated from Dartmouth College and from Dartmouth Medical School with high honors. She serves on the Board of Overseers at the Geisel School of Medicine at Dartmouth and the Executive Committee of American Society of Cataract and Refractive Surgery. Married with three children, her interests include culinary arts and competing in triathlons.

Lifetime Achievement Award

The Lifetime Achievement Award honors an ISRS member who has made significant and internationally recognized contributions to the advancement of refractive surgery over his or her career.

Lifetime Achievement Award—Dr. William W Culbertson



William W
Culbertson MD

Dr. Culbertson has spent his career at the Bascom Palmer Eye Institute, where he holds the Higgins Chair of Ophthalmology. He is the director of both the Cornea Service and the Refractive Surgery Service at Bascom Palmer.

Dr. Culbertson attended college and medical school at Emory University. Following residency at Vanderbilt University Eye Institute, he performed fellowships in cornea and external diseases at Bascom Palmer in 1978-79 and at the Proctor Foundation in 1979-80. There he studied the histopathology of radial keratotomy incisions in primates and noted the epithelial ingrowth and poor wound healing inherent in RK. After joining the faculty of the Bascom Palmer Eye Institute, he became a coinvestigator in the PERK Study that revealed the consequent hyperopia that occurred due to stretching of poorly healed corneal incisions.

From 1980 to 1994, refractive surgery at Bascom Palmer was limited to corneal incisional procedures. With the advent of the excimer laser, Dr. Culbertson directed the establishment of the Bascom Palmer Refractive Surgery Center in 1994, with the acquisition of a VISX Star laser. This center has grown to 6 lasers, 5 surgeons and 4 corneal fellows.

Over the next 15 years, he was an investigator in the major laser trials for wavefront-guided myopic and hyperopic treatment, conductive keratoplasty, femtosecond laser corneal and refractive surgery, and most recently the small-incision lenticule extraction (SMILE) procedure for myopia.

Dr. Culbertson has also been involved in discoveries and treatment of infectious retinitis, the initial corneal endothelial transplantation techniques, and the development of the Catalys femtosecond cataract laser. His current research interest is in magnetized cultured corneal endothelial transplantation, atomized microdrop drug application devices, and novel topical scar and inflammation inhibitors for the cornea.

He is most proud of his participation in the training of over 110 corneal fellows, many of whom have gone on to splendid clinical and academic careers.

His hobbies are sailing his boat *Aqueous Humor* and playing "grumpy old men" tennis on Saturday mornings.

Presidential Recognition Award

The Presidential Recognition Award is a special award that honors the recipient's dedication and contributions to the field of refractive surgery and to the ISRS.

Presidential Recognition Award—Dr. Marguerite B McDonald



Marguerite B
McDonald MD FACS

Dr. McDonald received her medical degree from Columbia University College of Physicians and Surgeons in 1976, followed by an internship at Lenox Hill Hospital and an ophthalmology residency at Manhattan Eye, Ear, and Throat Hospital/Cornell, both in New York City. She finished her training in 1981 after a fellowship in corneal and external diseases with Dr. Herbert E Kaufman at the Louisiana State University (LSU) Medical School

in New Orleans. From 1981 Dr. McDonald held tenure at LSU Medical School and became full professor of ophthalmology, director of the Corneal Service, and chair of Promotions and Tenure before she established the Southern Vision Institute in New Orleans in 1994. She joined the Ophthalmic Consultants of Long Island in Lynbrook, New York, in 2006.

Currently, Dr. McDonald is a clinical professor of ophthalmology at New York University in Manhattan and an adjunct clinical professor of ophthalmology at Tulane University Medical School in New Orleans. She is a staff physician at Manhattan Eye, Ear, and Throat Hospital; TLC Laser Eye Center in Garden City, New York; Island Eye Surgicenter in Carle Place, New York; and Mercy Medical Center in Rockville Centre, New York. For her pioneering work in refractive surgery, which included development and performance of the first excimer laser procedure in patients, she has received numerous recognition awards from her peers. These include the 1988 Lans Distinguished Refractive Surgeon Lecture, Contact Lens Association of Ophthalmologists, International Society of Refractive Keratoplasty; the 1993 Barraquer Lecture, International Society of Refractive Keratoplasty of the American Academy of Ophthalmology; the 2000 Whitney Sampson Lecture, American Academy of Ophthalmology; and the 2001 Binkhorst Lecture, American Academy of Ophthalmology. She serves on numerous editorial boards of clinical and scientific journals and is an active member of multiple national and international professional societies that have accorded recognition, including vice-president of finance, International Society of Contact Lens Research (1993-2011); honorary president, founding member, International Association of Women Eye Surgeons (1997-1998); 2001 president, Association of Women Eye Surgeons; president, American Society of Cataract and Refractive Surgery (2002-2003); president, International Society of Refractive Surgery of the American Academy of Ophthalmology; and president, International Society for Contact Lens Research (2011-2013). Dr. McDonald was selected as a Top Ophthalmologist in Lynbrook, New York, by the International Association of HealthCare professionals (IAHCP) for 2014. She has over 1,000 publications in the field of cornea and refractive surgery and has been the principal investigator of 3 National Eye Institute grants. Dr. McDonald lives in Port Washington, New York.

27th Annual Richard C Troutman MD DSc (Hon) Prize

The Troutman Prize recognizes the scientific merit of a young author publishing in the *Journal of Refractive Surgery*. This prize honors Richard C Troutman MD DSc (Hon).

Richard C Troutman MD DSc (Hon) Prize— Dr. Yumeng Wang



Yumeng Wang MD
PhD

Dr. Yumeng Wang received her Bachelor of Clinical Medicine degree from Shandong University, China, in 2013, on an Outstanding Students Scholarship from the same university in 2009-2013. In 2015, she obtained her Master of Medicine degree, majoring in ophthalmology, from Shandong University, and completed her residency in ophthalmology at Shandong Provincial Hospital. In 2018, Dr. Wang received her doctoral degree in ophthalmology and visual sciences on a full postgraduate studentship, 2015-2018, at the Chinese University of Hong Kong. Currently Dr. Wang conducts postdoctoral research at the Department of Ophthalmology and Visual Sciences, the Chinese University of Hong Kong.

Dr. Wang's research areas include investigations of keratoconus focusing on imaging, corneal properties, genetics, epigenetics, and pathophysiology. She also utilizes investigative technologies, such as Spectralis OCT, swept source OCT, OCT angiography, Pentacam, and Corvis for corneal studies in children, emphasizing corneal structural parameters and biomechanical properties in children with low vision and refractive errors. Her other research interest is the development of myopia in schoolchildren in terms of genetic factors, parental influences, and corneal properties.

Dr. Wang received an Association for Research in Vision and Ophthalmology (ARVO) Travel Grant Award in 2017, and she was awarded a top presentation prize at the Sixth Li Ka Shing Foundation International Ophthalmic Research Student Forum, held in Shantou, China, in 2017. She has been invited to give talks at the World Ophthalmology Congress (WOC 2018), ARVO 2017, and scientific meetings in Tianjin, Osaka, and Hong Kong.

Dr. Wang has contributed more than 20 publications in SCI international peer-reviewed journals and 2 book chapters.

Waring Memorial Award for a Young Ophthalmologist

The Waring Memorial Award for a Young Ophthalmologist recognizes an ISRS member early in his/her career who has demonstrated a commitment to ISRS, as well as a commitment to the promulgation of knowledge and the practice of refractive surgery. This award honors George O Waring III MD for his commitment to the profession and to ISRS.

Waring Memorial Award—Dr. David Smadja



David Smadja MD

David Smadja is director of the Refractive Surgery and Research and Innovation unit at Shaare Zedek Medical Center in Jerusalem, Israel. In 2015, he also joined the Nanotechnology Institute of Bar-Ilan University in Ramat Gan as an adjunct researcher associate in Prof. Zeev Zalevsky's laboratory.

Dr. Smadja graduated from medical school at Paris VI University, France, followed by residency training in ophthalmology at Bordeaux Hospital University and a clinical fellowship in cornea and refractive surgery in the same department. Dr. Smadja completed a postdoctoral fellowship in refractive surgery at the Cole Eye Institute, Cleveland Clinic, in 2011. He then served as a senior consultant at the National Reference Center for Keratoconus in Bordeaux and moved to Israel in 2014, where he now practices.

Dr. Smadja has published over 60 scientific works, including peer-reviewed publications, book chapters, and review articles. He holds 2 patents in the field of nanotechnology and refractive correction, and he is cofounder of 2 start-up companies in the same field. He currently serves as the chair of the ISRS Externship Committee and as a board member of the ISRS Multimedia Library subcommittee. Dr. Smadja has also served regularly as a course instructor at international conferences on corneal topography, keratoconus detection, and astigmatism correction. He is an associate editor of the *International Journal of Keratoconus and Ectatic Disease*.

Dr. Smadja's previous awards and distinctions include the Best Paper Award from the American Society of Cataract and Refractive Surgery (ASCRS) in 2013 and 2015, the ISRS 22nd Troutman Award in 2013, the Joseph Colin Prize in 2018 from the French Society of Intraocular Implant and Refractive Surgery, and the Gold Medal from the Intraocular Implant and Refractive Society of India (IIRSI) in 2018.

Faculty



Amar Agarwal MD
Chennai, India



Robert Edward T Ang MD
Makati City, Philippines



David F Chang MD
Los Altos, CA



Jorge A Alio MD PhD
Alicante, Spain



Vineet N Batra MD
San Leandro, CA



John So-Min Chang MD
Hong Kong, Hong Kong



Renato Ambrósio Jr MD
Rio de Janeiro, Brazil



George Beiko MD
St Catharines, ON, Canada



Y Ralph Chu MD
Bloomington, MN



Beatrice Cochener MD
Brest, France



Eric D. Donnenfeld MD
Garden City, NY



Luca Gualdi MD
Rome, Italy



Deepinder K. Dhaliwal MD
Pittsburgh, PA



Daniel S. Durrie MD
Overland Park, KS



Bonnie An Henderson MD
Waltham, MA



Burkhard Dick MD
Bochum, Germany



Alaa M. Eldanasoury MD
Jeddah, Saudi Arabia



Jack T. Holladay MD MSEE FACS
Bellaire, TX



Kendall E. Donaldson MD
Plantation, FL



William J. Fishkind MD FACS
Tucson, AZ



Osama I. Ibrahim MD PhD
Alexandria, Egypt



Soosan Jacob FRCS
Chennai, India



Nick Mamalis MD
Salt Lake City, UT




Erik L Mertens MD FRACOPhth
Antwerp, Belgium



A John Kanellopoulos MD
Athens, Greece



Leonardo Mastropasqua MD
Chieti, Italy




Saman Nassiri MD
Redlands, CA



Jennifer M Loh MD
Miami, FL



Marguerite B McDonald MD
Lynbrook, NY



Mario Nubile MD
Chieti, Italy



Ahad Mahootchi MD
Zephyrhills, FL



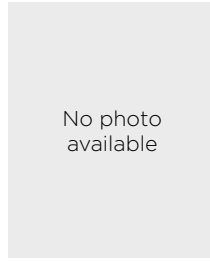Jodhbir S Mehta MBBS PhD
Singapore, Singapore



Thomas A Oetting MD
Iowa City, IA



Arturo J Ramirez-Miranda MD
Mexico City, Mexico



Rohit Shetty MBBS
Bangalore, India



Vance Michael Thompson MD
Sioux Falls, SD



J Bradley Randleman MD
Beverly Hills, CA



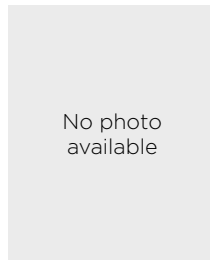Sathish Srinivasan MBBS
Scotland, United Kingdom



William B Trattler MD
Miami, FL



Dan Z Reinstein MD
London, England



Pavel Stodulka MD PhD
Zlin, Czech Republic



John Allan Vukich MD
Madison, WI



Marcony R Santhiago MD
Rio de Janeiro, RJ, Brazil



R Doyle Stulting MD PhD
Atlanta, GA



Yumeng Wang MD PhD
Hong Kong, Hong Kong



George O Waring IV MD
Mount Pleasant, SC



William F Wiley MD
Brecksville, OH



Elizabeth Yeu MD
Norfolk, VA

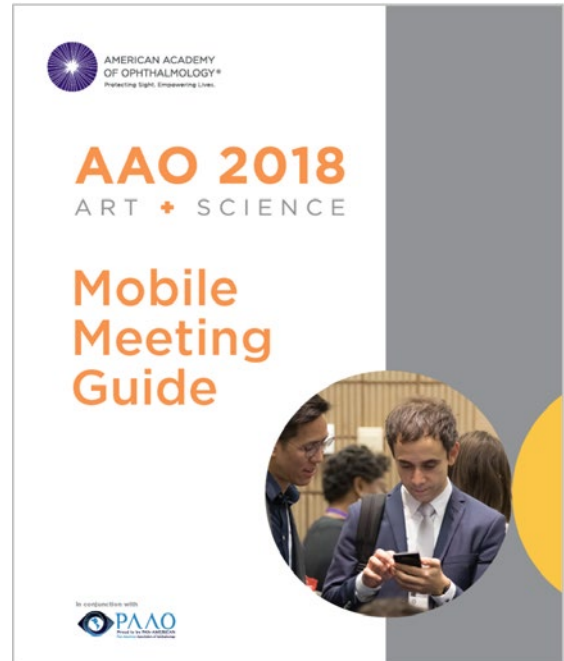

Helen K Wu MD
Chestnut Hill, MA

Ask a Question Live During the Meeting Using the Mobile Meeting Guide

To ask a question during the meeting, follow the directions below.

- Access at www.aao.org/mobile
- Select Program, Handouts & Evals
- Filter by Meeting – Refractive Surgery Meeting
- Select Current Session
- Select “Ask the presenter a question (live)” Link
- Click Submit Question



Refractive Surgery Subspecialty Day 2018: Better Together—Lens- and Cornea-Based Surgery

The Annual Meeting of the International Society of Refractive Surgery

FRIDAY, OCT. 26, 2018

CONTINENTAL BREAKFAST AND BREAKFAST WITH THE EXPERTS, Hall D

7:15 AM

Cataract and IOL Complications	Burkhard Dick MD Priya Narang MS
Elevation Corneal Tomography and Topography	Renato Ambrósio Jr MD Damien Gatinel MD
Femtosecond LASIK: Tips for Optimizing Visual Outcomes and Avoiding Complications	Sheraz M Daya MD Kendall E Donaldson MD
Intracorneal Rings	Aylin Kılıç MD Mitchell A Jackson MD
Laser Vision Correction Enhancements	Eric D Donnenfeld MD Paolo Vinciguerra MD
Management of the Ocular Surface in Refractive Surgery Patients	Beatrice Cochener MD Jennifer M Loh MD
Managing SMILE Complications	Dan Z Reinsteint MD William F Wiley MD
Pediatric Refractive Surgery	Helen K Wu MD Erin D Stahl MD
Phakic IOLs	Erik L Mertens MD FRACOPhth Gregory D Parkhurst MD
Refractive Surgery Enhancements	Daniel S Durrie MD Parag A Majmudar MD
Small-Aperture Procedures	Robert Edward T Ang MD John Allan Vukich MD
Surface Ablation and CXL Combined and Sequential Procedures	David Smadja MD A John Kanellopoulos MD
Toric IOL Pearls	Sumitra S Khandelwal MD Neda Shamie MD
Visual Quality Assessment	Glauco H Reggiani Mello MD Roger Zaldivar MD
8:00 AM Opening Remarks	William B Trattler MD Marcony R Santhiago MD

Keynote Lecture

8:05 AM	Thirty Years of Laser Vision Correction	Marguerite B McDonald MD*	1
---------	---	---------------------------	---

* Indicates that the presenter has financial interest. No asterisk indicates that the presenter has no financial interest.

Section I: Advances in Refractive Surgery

Moderators: William B Trattler MD* and Kendall E Donaldson MD*

Panelists: Burkhard Dick MD, Daniel S Durrie MD*, and John Allen Vukich MD*

8:20 AM	Advances in Preoperative Assessment for Corneal Refractive Surgery	Renato Ambrósio Jr MD*	2
8:28 AM	Discussion		
8:30 AM	Advances in Corneal Inlays for Presbyopia	William F Wiley MD*	13
8:38 AM	Discussion		
8:40 AM	Advances in Corneal Surgery for Myopia: LASIK vs. SMILE vs. PRK	Jodhbir S Mehta MBBS PhD*	10
8:48 AM	Discussion		
8:50 AM	Advances in Presbyopia Therapies	Y Ralph Chu MD*	11
8:58 AM	Discussion		
9:00 AM	Decision Making in Presbyopic IOLs	John So-Min Chang MD*	12
9:08 AM	Discussion		
9:10 AM	Refractive Surgery for Hyperopia: Lens- vs. Cornea-Based	John Allan Vukich MD*	5
9:18 AM	Discussion		
9:20 AM	Refractive Index Reshaping of the Lens	George O Waring IV MD*	14
9:28 AM	Discussion		
9:30 AM	Crosslinking	R Doyle Stulting MD PhD*	20
9:38 AM	Discussion		
9:40 AM	Crosslinking Combination Therapies	A John Kanellopoulos MD*	21
9:48 AM	Discussion		
9:50 AM	Phakic IOLs	Erik L Mertens MD FRACOPhth*	22
9:58 AM	Discussion		
10:00 AM	Case Panel Discussion	William B Trattler MD* Kendall E Donaldson MD*	
10:15 AM	REFRESHMENT BREAK		

ISRS Awards

10:45 AM	Presentation of the 2018 ISRS Awards	John So-Min Chang MD*	
----------	--------------------------------------	-----------------------	--

Section II: Management and Prevention of Complications in Refractive Surgery

Moderator: Marcony R Santhiago MD* and Marguerite B McDonald MD*

Panelists: Jorge A Alio MD PhD*, Deepinder K Dhaliwal MD*, and A John Kanellopoulos MD*

10:55 AM	Prevention of Cystoid Macular Edema and Infection in Lens-Based Surgery	Bonnie An Henderson MD*	24
11:03 AM	Discussion		
11:05 AM	Pearls and Pitfalls in Biometry Following Corneal Refractive Surgery or Keratoconus	Jack T Holladay MD MSEE FACS*	25
11:13 AM	Discussion		

* Indicates that the presenter has financial interest. No asterisk indicates that the presenter has no financial interest.

11:15 AM	Management of Corneal Refractive Surgery Complications	Helen K Wu MD*	26
11:23 AM	Discussion		
11:25 AM	Management of Complications Following Crosslinking	Marcony R Santhiago MD*	27
11:33 AM	Discussion		
11:35 AM	Prevention and Identification of Post-LASIK Ectasia	William B Trattler MD*	28
11:43 AM	Discussion		
11:45 AM	Managing the Dissatisfied Refractive Surgery Patient	Vance Michael Thompson MD*	30
11:53 AM	Discussion		
11:55 AM	Case Panel Discussion	Marcony R Santhiago MD* Marguerite B McDonald MD*	
12:10 PM	LUNCH, Hall D ISRS Member Lunch: Presbyopic IOLs, Room E450		

Section III: Video-Based Master Complications

Moderators: Amar Agarwal MD* and Jennifer M Loh MD*

Virtual Moderator: Sathish Srinivasan MBBS*

Panelists: George Beiko MD*, Burkhard Dick MD, Eric D Donnenfeld MD*, Jack T Holladay MD MSEE FACS*, and Elizabeth Yeu MD*

1:30 PM	Refining IOL Power After Cataract Surgery: Perfect Lens and Light Adjustable IOL	Nick Mamalis MD*	31
1:35 PM	Centration of a Multifocal IOL	William J Fishkind MD FACS*	32
1:40 PM	Mastering the Glued IOL Technique	Ashvin Agarwal MD	34
1:45 PM	Single-Pass Four-Throw Pupilloplasty	Amar Agarwal MD*	38
1:50 PM	Explantation of an EDOF IOL	David F Chang MD*	44
1:55 PM	Pre-Descemet Endothelial Keratoplasty	Ahad Mahootchi MD*	45
2:00 PM	LASIK Nightmares	A John Kanellopoulos MD*	46
2:05 PM	Phakic IOL Complications	Alaa M Eldanasoury MD*	48
2:10 PM	Panel Discussion		
2:20 PM	Advocating for the Profession and Patients	Vineet N Batra MD*	49

Section IV: ESCRS Symposium—Will Small-Incision Lenticule Extraction Replace LASIK?

Moderator: Beatrice Cochener MD

2:25 PM	SMILE vs. Optimized LASIK for Myopia and Astigmatism Correction	Leonardo Mastropasqua MD	52
2:33 PM	SMILE Advantages: From Theory to Clinical Reality	Beatrice Cochener MD	53
2:41 PM	Review and Management of Complications	Mario Nubile MD	54
2:49 PM	The Hope for a Hyperopic SMILE	Pavel Stodulka MD PhD*	55
2:57 PM	Case Panel Discussion		

* Indicates that the presenter has financial interest. No asterisk indicates that the presenter has no financial interest.

REFRESHMENT BREAK with the EXPERTS, Hall D

3:10 PM

Allogenic Corneal Inlays	Soosan Jacob FRCS Ronald R Krueger MD
Collagen Crosslinking	Roy Scott Rubinfeld MD Paolo Vinciguerra MD
Corneal Inlays	Ronald Luke Rebenitsch MD George O Waring IV MD
Epithelial Mapping Prior to Corneal Refractive Surgery	Sumitra S Khandelwal MD Dan Z Reinstein MD
How to Communicate With the Unhappy Patient	John P Berdahl MD William F Wiley MD
Intracameral Antibiotics for Endophthalmitis Prophylaxis	Tat-Keong Chan MD FRCS FRCOphth David F Chang MD
Laser Refractive Lens Surgery	Burkhard Dick MD Sumit Garg MD
Modulation of Corneal Wound Healing After Refractive Surgery	Parag A Majmudar MD Helen K Wu MD
Ocular Surface Management	Maria A Henriquez MD Marguerite B McDonald MD
Patient Selection for Refractive Lens Exchange	Mitchell A Jackson MD Jason E Stahl MD
Planning IOL Powers	Daniel H Chang MD Jack T Holladay MD MSEE FACS
SMILE	Ashvin Agarwal MD Steven C Schallhorn MD
Surface Ablation Pearls	Aylin Kılıç MD Riccardo Vinciguerra MD
Therapeutic Corneal Refractive Surgery, Including Phototherapeutic Keratectomy	Terry Kim MD William B Trattler MD

Section V: The *Journal of Refractive Surgery's* Hot, Hotter, Hottest: Late Breaking News

Moderator: J Bradley Randleman MD and Soosan Jacob FRCS

3:55 PM	Introduction of the Troutman Prize	J Bradley Randleman MD	
4:00 PM	Troutman Lecture: Histological and microRNA Signatures of Corneal Epithelium in Keratoconus	Yumeng Wang MD PhD	56

JRS Papers

4:15 PM	Corneal Allogenic Intrastromal Ring Segments Combined With Corneal Crosslinking for Keratoconus	Soosan Jacob MS FRCS DNB	57
4:20 PM	Customized Corneal Crosslinking Using Different UVA Beam Profiles	Rohit Shetty MBBS	58
4:25 PM	Ciliary Muscle Electrostimulation to Restore Accommodation in Patients With Early Presbyopia: Preliminary Results	Luca Gualdi MD*	59
4:30 PM	Outcomes of Retreatment by LASIK after SMILE	Dan Z Reinstein MD	60

* Indicates that the presenter has financial interest. No asterisk indicates that the presenter has no financial interest.

Free Papers

4:35 PM	Four-Year Visual Performance After Small-Aperture IOL Implantation in Cataract Patients	Robert Edward T Ang MD*	61
4:40 PM	Effectiveness of a New Matrix Therapy Agent, Cacicol, on the Re-epithelialization and Tolerability After PRK	Arturo J Ramirez-Miranda MD*	62
4:45 PM	Distinguishing Highly Asymmetric Keratoconus Eyes Using Combined Scheimpflug and Spectral Domain OCT Analysis	J Bradley Randleman MD	63
4:50 PM	Incidence of Symptomatic Decentration and Small Optical Zone Over a 10,000-Eye Single-Practice Series and Outcomes of Topography-Guided Therapeutic Repair	Dan Z Reinstein MD*	64
4:55 PM	Refractive Outcomes of Intraoperative Wavefront Aberrometry Compared With Preoperative Biometry for Cataract Surgery in Patients With Prior Refractive Surgery	Saman Nassiri MD	65
5:00 PM	To Evaluate Safety and Efficacy of SMILE Procedure: Seven-Year Follow-up	Osama I Ibrahim MD PhD*	66
5:05 PM	Panel Discussion		
5:10 PM	JRS QwikFacts	Marcony R Santhiago MD*	
5:15 PM	Closing Remarks	William B Trattler MD* Marcony R Santhiago MD*	

* Indicates that the presenter has financial interest. No asterisk indicates that the presenter has no financial interest.

Thirty Years of Laser Vision Correction

Marguerite McDonald MD

In 1983, radial keratotomy was the predominant form of refractive surgery, and epikeratophakia was gaining attention. That year, Stephen Trokel MD published a landmark paper in the *American Journal of Ophthalmology*. Trokel documented that the excimer laser could precisely remove exact volumes of corneal tissue, creating smooth, uniform surfaces with no thermal effect on surrounding tissue, thus describing the essentials of excimer laser–cornea interaction.

Shortly thereafter, Trokel, based in New York City, began working with Charles Munnerlyn PhD, a physicist in California with expertise in lasers. Soon they were joined by Marguerite McDonald MD, a cornea surgeon and researcher at Louisiana State University (LSU) in New Orleans.

The team started by ablating countless plastic test plates, cadaver pig and cow eyes, and cadaver human eyes. The first laser had a closing diaphragm (hand cranked) with only 5 positions, or steps; as the center of the ablation was the deepest, it was intended to correct myopia. The first photorefractive keratectomy (PRK) results in living subjects—the rabbits—were dismal, as the corneas healed with thick hyperplastic scars; the need for smoothness and a blend zone was not yet known. Eventually, the laser diaphragm was upgraded to close automatically, with 40 and then eventually hundreds of positions; these refinements resulted in clear corneas with predictable outcomes. The rabbit results were finally encouraging enough for the team to move to monkey studies at the Delta Primate Center in Covington, Louisiana. Years later, the flying spot laser was developed, which provided—and still provides—the smoothest ablations and best clinical results of all.

During this period, the laser delivery system was refined. Before the development of eye trackers, several methods were used to immobilize the eye, from retrobulbar injections to suction handpieces with carpenter's levels to a steel tube that screwed into the limbus. Stephen Klyce PhD, a professor of ophthalmology at LSU Eye Center, had joined the team and assisted in refining the delivery system. Dr. Klyce also analyzed the clinical outcomes with topography.

In parallel with these modifications, the perioperative regimen was developed using trial and error. The proper antibiotic and steroid regimen, the most appropriate bandage contact lenses, and the ideal oral analgesic schedule were worked out through a series of minitrials.

During the monkey trials, a unique opportunity presented itself to the team: a 61-year-old woman with a normal, healthy eye was facing an imminent exenteration because of an orbital cancer that surrounded the eye. The patient, Alberta Cassady, volunteered to allow experimentation on her 20/20 uncorrected eye. The FDA allowed the procedure, and on March 25, 1988, the team rushed Mrs. Cassady past the monkey cages at the Delta Primate Center, where she received the world's first laser vision correction procedure in a living human subject. Dr. McDonald, the team surgeon, had the honor of performing this procedure.

Mrs. Cassady was followed daily for the 11 days leading up to her exenteration. The slit lamp appearance and refractive outcome were both excellent, and the histology on her corneal specimen revealed normal corneal healing without scarring or inflammation.

The FDA was very impressed by these results and allowed the team to stop the monkey trials and leapfrog ahead to the blind eye study. The laser was brought across Lake Pontchartrain to the LSU Eye Center, where the blind eye, partially sighted, and fully sighted clinical trials took place.

The laser was thought to be dangerous; there was the fear that the argon fluorine gas might leak and cause injury or death, so the administration insisted that the laser be placed in a trailer that was next to the LSU trash compactor. This proximity turned out to be fortuitous, as the laser trailer shook gently when the trash compactor was in action, which inadvertently provided a blend zone.

After elucidating the ablation patterns for spherical myopia, the team developed the patterns for myopic astigmatism, hyperopia, and hyperopic astigmatism.

Approximately 10 years after the introduction of PRK, LASIK (laser in situ keratomileusis) was developed by Ioannis Pallikaris MD and became popular worldwide. Now, a femtosecond laser is commonly used to create the LASIK flap, such that two lasers, the excimer and the femtosecond, are utilized. Both PRK and LASIK continue to be performed around the globe.

Eye trackers, wavefront-guided ablations, and topography-guided ablations have since been developed, and small-incision lens extraction (SMILE), an all-femtosecond laser procedure, has been launched internationally.

Advances in Preoperative Assessment for Corneal Refractive Surgery

Renato Ambrósio Jr MD PhD

I. Preoperative Assessment of Corneal Laser Vision Correction (LVC): Key Points

A. What are the goals? (Focus on the patient)¹

1. Understand the overall need and expectations from the patient
2. Examine general ophthalmological health
3. Assess refractive error and optical quality
4. Assess corneal shape / structure
5. Assess crystalline lens function (clarity and accommodation)
6. Choose the most appropriate procedure to optimize efficiency and safety
7. Customize treatment plan

B. How to do it?

1. Comprehensive / general ophthalmic exam
2. Patient interview and education
3. Complementary exams: imaging for refractive surgery

C. Review and classification of imaging methods for refractive surgery

1. Corneal geometry and shape
 - a. Corneal topography: characterization of the front surface of the cornea
 - b. Corneal pachymetry: assessing corneal thickness, typically with ultrasound from a single point at the center and/or paracentral points
 - c. Corneal tomography: 3-D corneal characterization, depicting front and back elevation and thickness mapping
 - d. Segmental or layered corneal tomography: assessing corneal layers
 - i. Epithelial thickness mapping
 - ii. Bowman layer thickness and regularity
 - iii. Descemet membrane thickness
2. Corneal cells
 - a. Specular microscopy for assessing corneal endothelium
 - b. Confocal microscopy for assessing epithelial surface and basal cells, corneal nerves, stromal cells and endothelium of the cornea

3. Ocular surface evaluation

- a. Tear film volume
- b. Tear film stability
 - i. Break-up time of the tear film
 - ii. Optical degradation time
- c. Dynamics of eyelid blinking and tear film regeneration
- d. Bulbar redness and Meibomian gland evaluation
- e. Other tests: osmolarity, biomarkers for inflammation (MMP9 and others)

4. Corneal biomechanical assessment

5. Optical quality assessment of the eye

- a. Ocular wavefront: assessing optical properties and quality of the whole eye, possibly integrating with corneal wavefront for calculating intraocular aberrations. Wavefront accommodation testing.
- b. Optical scatter index
- c. Subjective contrast sensitivity and glare testing

II. Focus on Preventing Complications

“There are known knowns. These are things we know that we know. There are known unknowns. That is to say, there are things that we know we don’t know. But there are also unknown unknowns. There are things we don’t know we don’t know.” — Donald Rumsfeld

A. The goal is to identify conditions that predispose the patient for specific complications in order to define the most appropriate strategy to optimize such state if possible, and/or to plan the safest and most efficient procedure.

B. Which complications should we consider?

1. Progressive keratectasia
2. Tear dysfunction and dry eye
3. Ocular pain
4. Epithelialization of the interface (small-incision lenticule extraction and LASIK)
5. Severe quality of vision symptoms
6. Others: infective keratitis, inflammation

III. How to Identify Patients at Risk for Each Complication?

Table 1.

Complication	What We Are Screening for Preoperatively	How to Screen for It
Progressive keratectasia ²	<ul style="list-style-type: none"> • Detect mild forms of keratoconus, ectasia susceptibility • Consider refractive treatment and the impact on the cornea 	<ul style="list-style-type: none"> • Placido-disk corneal topography, Scheimpflug tomography, OCT (or VHF US) segmental tomography, and biomechanical assessments • Integration with the impact on the cornea by laser vision correction²⁻⁴
Tear dysfunction and dry eye ⁵	Characterize contact lens intolerance, dry eye preoperatively; poor ocular surface health	Questionnaires, tear film osmolarity and inflammation biomarker, tear film stability and optical regularity, meibomian gland visualization with infrared
Ocular pain / dysesthesia ⁶	Assess tear dysfunction syndrome; systemic neuropathy; low vitamin B ₁₂ or D	<ul style="list-style-type: none"> • Confocal microscopy • Esthesiometry
Epithelialization of the interface (small-incision lenticule extraction and LASIK) ⁷	Detect occult corneal basement membrane dystrophy	High-resolution OCT
Severe quality of vision symptoms ⁸⁻¹⁰	Assess preoperative visual performance	Mesopic / scotopic pupil size, corneal / ocular wavefront

IV. Advances in Understanding Progressive Keratectasia

- A. Although uncommon, this is a very severe complication of LVC procedures.
- B. Ectasia occurs due to a combination of 3 basic factors:
 1. Preoperative ectatic corneal disease (the most important risk factor)
 2. The surgical impact on corneal structure
 3. Postoperative trauma (ie, eye rubbing) or other conditions (ie, pregnancy)
- C. Three factors for stability or ectatic progression in every case
 1. Preoperative corneal structure
 2. Surgical impact on the cornea
 3. Postoperative trauma / weakening
- D. Screening for mild ectasia evolved to characterization of ectasia susceptibility
 1. Proper interpretation of advanced diagnostic technologies, including front surface corneal topography, 3-D tomography, and biomechanical assessments
 2. Studies involving eyes with normal and stable corneas, compared to eyes with frank ectatic diseases and to eyes with normal topography from patients with very asymmetric ectasia (VAE), allow for the development of advanced methods and for testing of their sensitivity. However, the ideal studies for testing the sensitivity and specificity of ectasia risk assessments are, respectively, the preoperative study of cases that developed ectasia and the study of cases with stable outcomes after LVC.

- E. Young age and low thickness are surrogates of corneal biomechanics, which may be replaced as risk factors by direct measurements, when these are available.

- F. The impact from the LVC procedure on the cornea is related to the residual stromal bed (RSB) and to the percentage tissue altered (PTA).

1. PTA higher than 40% is a more sensitive parameter than a fixed value for minimal RSB of 250 μ m.
2. The biomechanical impact from surgery is related to the region and number of lamellae that are severed, so that flap thickness and geometry should play a more relevant role, which is in agreement with finite element simulations.

- G. Artificial intelligence methods allow for combining parameters, which significantly enhances the accuracy for detecting ectasia risk.

1. Data integration: key to improve decision-making in screening of refractive surgery: work in progress by the BrAIN (Brazilian Study Group of Artificial Intelligence and Corneal Analysis); see www.youtube.com/watch?v=z1tUJkrUMDY&t=6s

2. Enhanced screening for ectasia; see www.youtube.com/watch?v=d4jOG7jAPwU

V. Major Points in Preventing Ectasia After LVC

- A. Considering there is high variability in subjective classifications of color-coded maps,¹¹ objective and validated criteria are essential for diagnostic interpretation and for the clinician to take full advantage of the diagnostic technologies.¹²⁻¹⁵

- B. Analysis using advanced corneal characterization of the preoperative state of cases that developed ectasia and of those that are stable after LVC represents the closest to ideal route for the development and testing of sensitivity and specificity of ectasia risk assessment approaches.
- C. Young age and low preoperative thickness are surrogates for corneal biomechanical properties, presenting as important risk factors for keratectasia. However, the advent of corneal biomechanical parameters may exclude these factors in artificial intelligence techniques, such as regression analysis, support vector machine, and random forest. Nevertheless, application of cross-validation techniques and external validations in separate populations are fundamental steps for the development of such methods, in order to ensure the clinical applicability and reliability of the test.
- D. Considering that keratectasia occurs due to a combination of preoperative predisposition or susceptibility of the patient's cornea and the impact from surgery on corneal structure, the approaches for assessing ectasia risk should consider a combination of patient-related data and procedure-related parameters. We anticipate fast developments and the integration of simulation analysis and artificial intelligence strategies, which will play a significant role in this field.

References

1. Ambrosio R Jr, Wilson SE. Complications of laser in situ keratomileusis: etiology, prevention, and treatment. *J Refract Surg.* 2001; 17:350-379.
2. Ambrosio R Jr, MW Belin. Enhanced screening for ectasia risk prior to laser vision correction. *Int J Kerat Ect Cor Dis.* 2017; 6:23-33.
3. Ambrosio R Jr, Nogueira LP, Caldas DL, et al. Evaluation of corneal shape and biomechanics before LASIK. *Int Ophthalmol Clin.* 2011; 51:11-38.
4. Ambrosio R Jr, Dawson DG, Salomao M, Guerra FP, Caiado AL, Belin MW. Corneal ectasia after LASIK despite low preoperative risk: tomographic and biomechanical findings in the unoperated, stable, fellow eye. *J Refract Surg.* 2010; 26:906-911.
5. Ambrosio R Jr, Tervo T, Wilson SE. LASIK-associated dry eye and neurotrophic epitheliopathy: pathophysiology and strategies for prevention and treatment. *J Refract Surg.* 2008; 24:396-407.
6. Theophanous C, Jacobs DS, Hamrah P. Corneal neuralgia after LASIK. *Optom Vis Sci.* 2015; 92:e233-40.
7. Ivarsen A, Asp S, Hjortdal J. Safety and complications of more than 1500 small-incision lenticule extraction procedures. *Ophthalmology* 2014; 121:822-828.
8. Moshirfar M, Shah TJ, Skanchy DF, Linn SH, Durrie DS. Meta-analysis of the FDA reports on patient-reported outcomes using the three latest platforms for LASIK. *J Refract Surg.* 2017; 33:362-368.
9. Rosen ES. Night vision disturbance. *J Cataract Refract Surg.* 2005; 31:247-249.
10. Schallhorn SC, Kaupp SE, Tanzer DJ, Tidwell J, Laurent J, Bourque LB. Pupil size and quality of vision after LASIK. *Ophthalmology* 2003; 110:1606-1614.
11. Ramos IC, Correa R, Guerra FP, et al. Variability of subjective classifications of corneal topography maps from LASIK candidates. *J Refract Surg.* 2013; 29:770-775.
12. Ambrosio R Jr, Randleman JB. Screening for ectasia risk: what are we screening for and how should we screen for it? *J Refract Surg.* 2013; 29:230-232.
13. Ambrosio R Jr, Valbon BF, Faria-Correia F, Ramos I, Luz A. Scheimpflug imaging for laser refractive surgery. *Curr Opin Ophthalmol.* 2013; 24:310-320.
14. Rabinowitz YS, Li X, Canedo AL, Ambrosio R Jr, Bykhovskaya Y. Optical coherence tomography combined with videokeratography to differentiate mild keratoconus subtypes. *J Refract Surg.* 2014; 30:80-87.
15. Saad A, Gatinel D. Topographic and tomographic properties of forme fruste keratoconus corneas. *Invest Ophthalmol Vis Sci.* 2010; 51:5546-5555.

Refractive Surgery for Hyperopia: Lens- vs. Cornea-Based

John A Vukich MD

I. Literature Review

Table 1. Literature Review

Study	Patients (N)	Comparison	Metric	Outcome
Barisic, <i>Coll Antropol.</i> , 2010	100	M-IOL vs. Monovision LASIK	Visual acuity and satisfaction	<ul style="list-style-type: none"> Satisfaction similar between groups RLE better UCNVA, increased halo and glare LASIK better UCDVA
Patel, <i>JRS</i> , 2008	45	M-IOL vs. Accom IOL vs. PresbyLASIK	Visual acuity	<ul style="list-style-type: none"> No difference in distance and near vision between M-IOL and PresbyLASIK Accom IOL worse near vision
Chandhrasri, <i>JRS</i> , 2006	27	M-IOL vs. P-IOL vs. LASIK	CS and HOA	<ul style="list-style-type: none"> No loss of CS with P-IOL or LASIK M-IOL had loss of CS HOA increased in all groups

Abbreviations: RLE, refractive lens exchange; UCNVA, uncorrected near visual acuity; UCDVA, uncorrected distance VA; M-IOL, multifocal IOL; Accom IOL, accommodative IOL; P-IOL, phakic IOL; CS, contrast sensitivity; HOA, higher-order aberrations.

II. Methods

A. Inclusion criteria

- Age: 45 to 60 years
- Preop BCVA: 20/25 or better in each eye
- Preop sphere: between -10.0 D and +3.0 D
- Primary monovision LASIK or refractive lens exchange (RLE), with Symfony in at least 1 eye
- Three-month exam and patient experience questionnaire (PEQ)

B. Study group

- Monovision LASIK: 608 patients (1216 eyes)
- RLE: 590 patients (1180 eyes)
 - Bilateral Symfony: 81.0%
 - Symfony plus Tecnis +3.25: 19%
- Clinical and PEQ outcomes compared between the 2 groups

C. Preoperative data (see Figures 1-7)

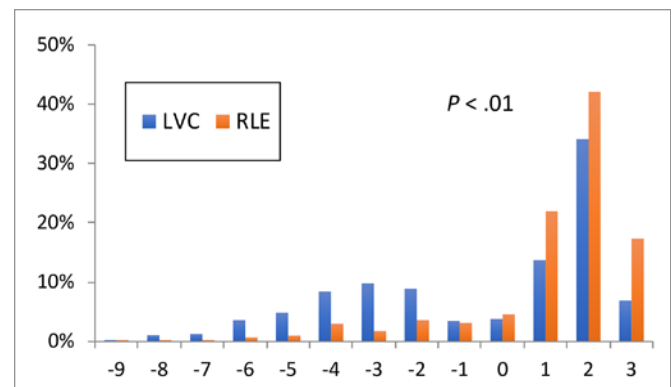


Figure 1. Distribution of preoperative sphere.

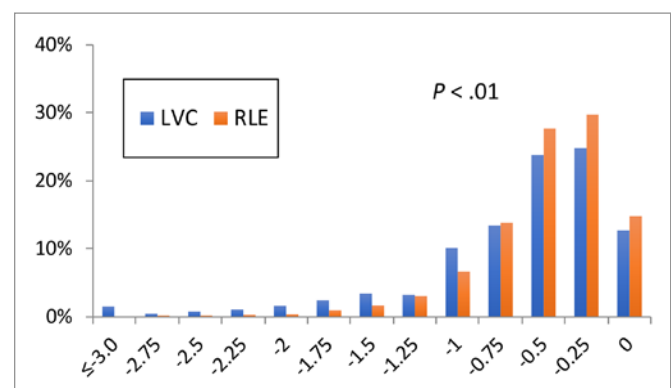


Figure 2. Distribution of preoperative cylinder.

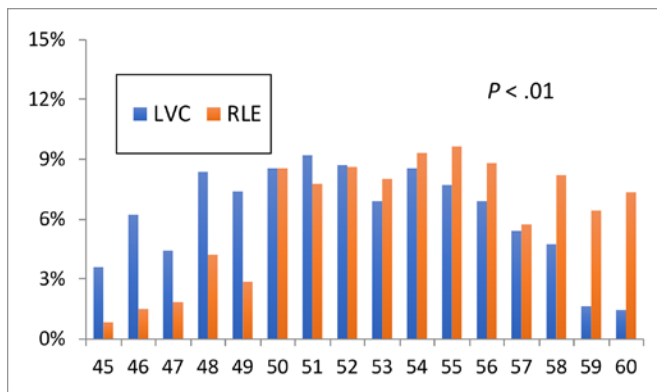


Figure 3. Distribution of preoperative age.

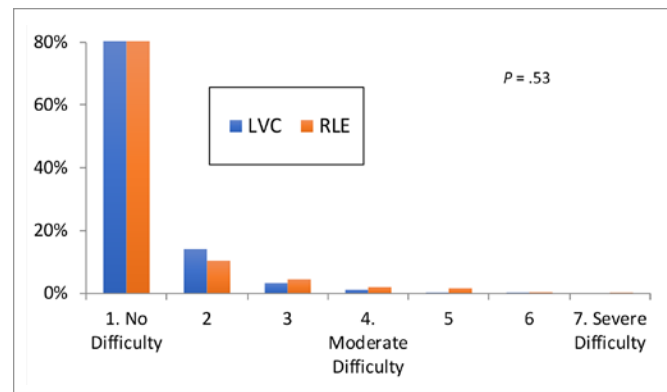


Figure 6. Distribution of preoperative halo.

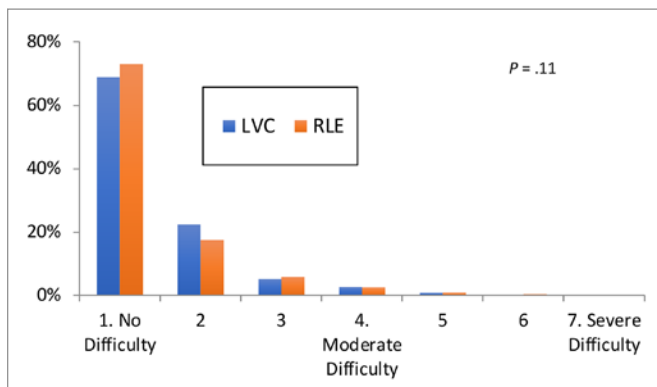


Figure 4. Distribution of preoperative dry eye severity.

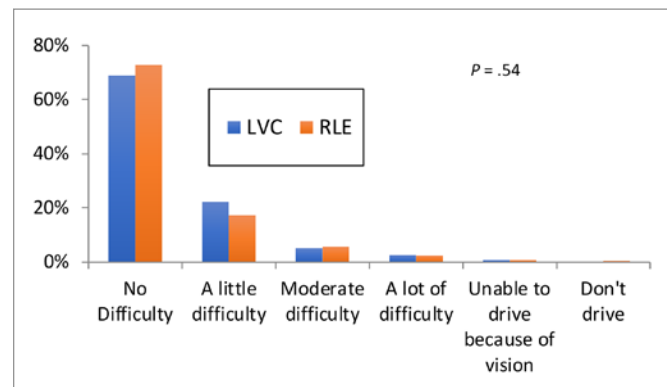


Figure 7. Distribution of preoperative night driving.

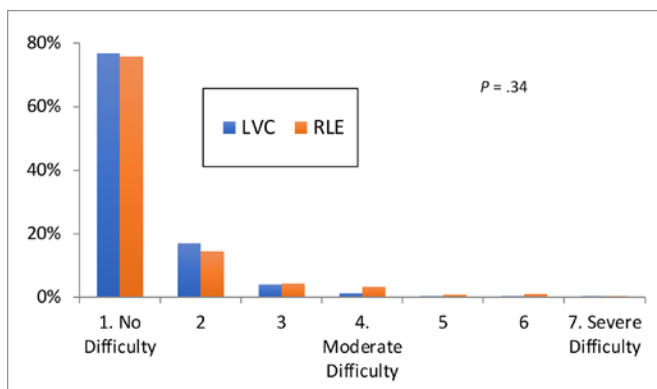


Figure 5. Distribution of preoperative glare.

III. Postop Sphere

- A. RLE both eyes and LASIK distant eye
- B. LASIK near eye

IV. Preoperative Sphere (see Table 2)

V. Month 3 Data

- A. Binocular uncorrected distance visual acuity (UCDVA), percentage of 20/20 or better
- B. Binocular uncorrected near VA (UCNVA), percentage of J5 or better
- C. Patient satisfaction with vision
 1. Percentage "Very Satisfied / Satisfied"
 2. Percentage that would recommend vision correction surgery
 3. Percentage that finds surgery has improved quality of life (QoL)
- D. Dry eye
 1. Significant difficulty with dry eyes, score of 5 or 6 on a scale of 1 to 7
 2. Preop to postop change in dry eyes, increase by more than 2 scores

Table 2. Preoperative Sphere

Parameter	LASIK Monovision (n)	Refractive Lens Exchange (n)	P-value
<ul style="list-style-type: none"> Moderate to high myopia Preop sphere in worse eye: -3.25 D or less 	-5.06 ± 1.43 (176)	-5.02 ± 1.45 (43)	.88
<ul style="list-style-type: none"> Low myopia Preop sphere in worse eye: -0.25 to -3.00 	-2.11 ± 0.84 (94)	1.76 ± 0.89 (54)	.02
<ul style="list-style-type: none"> Plano presbyopes UDVA in each eye: 20/25 or better 	1.05 ± 0.73 (63)	0.91 ± 0.5 (119)	.14
<ul style="list-style-type: none"> Hyperopia Preop sphere in worse eye: $+0.25$ D to $+3.00$ D 	1.76 ± 0.5 (275)	1.92 ± 0.61 (374)	< .01

Abbreviation: UDVA, uncorrected distance visual acuity.

E. Glare

1. Significant difficulty with glare, score of 5 or 6 on a scale of 1 to 7
2. Preop to postop change in glare, increase by more than 2 scores

F. Halo

1. Significant difficulty with halo, score of 5 or 6 on a scale of 1 to 7
2. Preop to postop change in halo, increase by more than 2 scores

G. Night driving

1. Difficulty with night driving, percentage reporting “A lot of difficulty” or “Unable to do the task because of their vision”
2. Change in night driving, increase by more than 2 scores

H. Near vision

1. Difficulty with close-up vision, percentage reporting “A lot of difficulty” or “Unable to do the task because of their vision”
2. Change in near activities, increase by more than 2 scores

I. Distance vision

1. Difficulty with distant activities, percentage reporting “A lot of difficulty” or “Unable to do the task because of their vision”
2. Change in distant activities, increase by more than 2 scores

VI. Symphony: Myopia in the Nondominant Eye and Postoperative Satisfaction

A. Symphony nondominant eye satisfaction: Three categories according to the postop sphere in nondominant eye

1. Distance correction (Sph 0.0 D or more): 211 patients

2. Mini-monovision (Sph between -0.25 and -0.75): 187 patients
3. Monovision (Sph -1.0 D or less): 62 patients

B. Satisfied / Very Satisfied

1. Stratified according to the sphere in nondominant eye (see Figure 8)
2. Stratified according to the sphere in nondominant eye and age (see Figure 9)

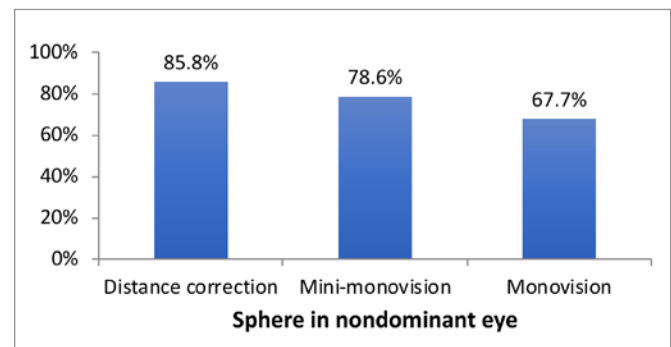


Figure 8. Symphony nondominant eye satisfaction (Satisfied / Very Satisfied), stratified according to the sphere in nondominant eye.

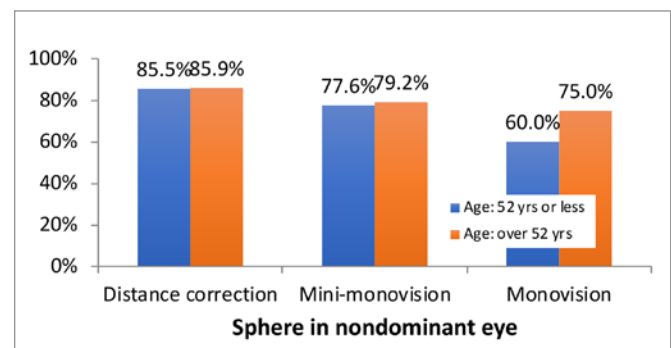


Figure 9. Symphony nondominant eye satisfaction (Satisfied / Very Satisfied), stratified according to the sphere in nondominant eye and age.

C. Dissatisfied / Very Dissatisfied

1. Stratified according to the sphere in nondominant eye (see Figure 10)
2. Stratified according to the sphere in nondominant eye and age (see Figure 11)

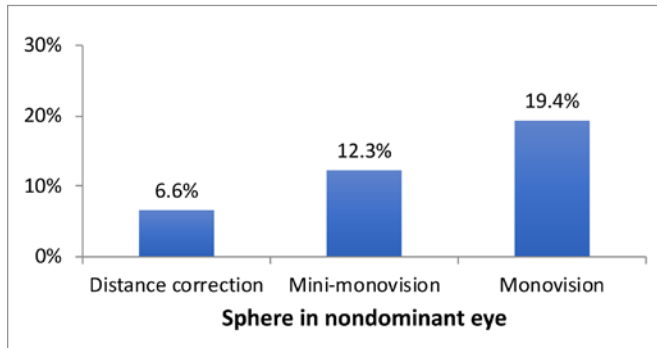


Figure 10. Symphony nondominant eye dissatisfaction (Dissatisfied / Very Dissatisfied), stratified according to the sphere in nondominant eye.

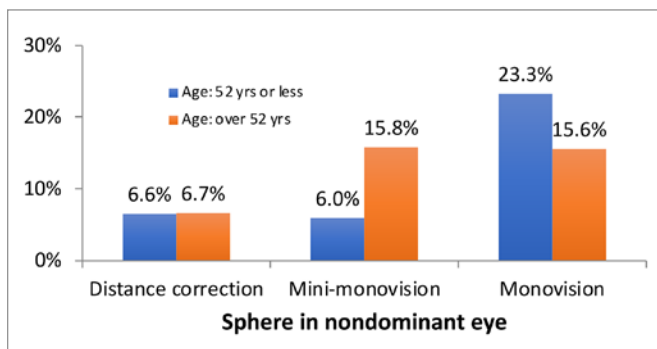


Figure 11. Symphony nondominant eye dissatisfaction (Dissatisfied / Very Dissatisfied), stratified according to the sphere in nondominant eye and age.

VII. LVC Monovision: Myopia in Near Eye and Postoperative Satisfaction

A. Satisfied / Very Satisfied

1. Stratified according to the amount of myopia in near eye (see Figure 12)
2. Stratified according to the amount of myopia in near eye and age (see Figure 13)

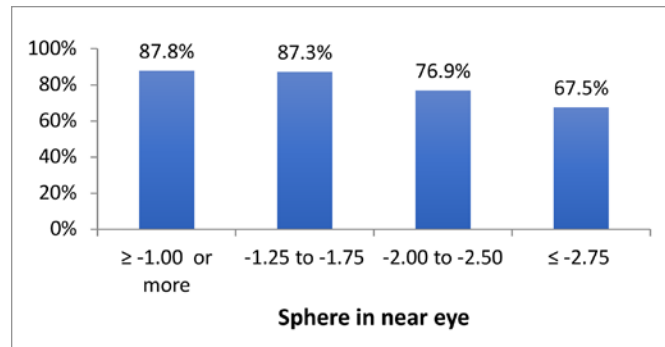


Figure 12. LCV monovision satisfaction (Satisfied / Very Satisfied), stratified according to the amount of myopia in near eye.

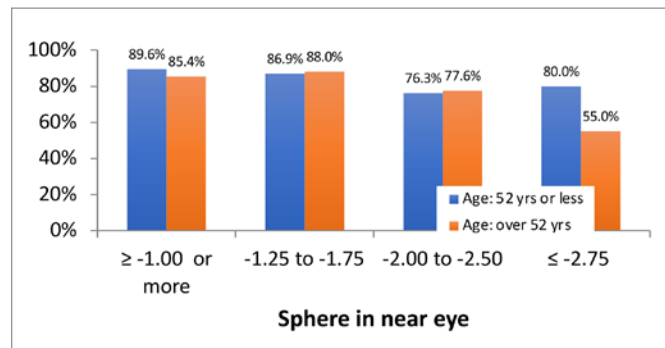


Figure 13. LCV monovision satisfaction (Satisfied / Very Satisfied), stratified according to the amount of myopia in near eye and age.

B. Dissatisfied/Very Dissatisfied

1. Stratified according to the amount of myopia in near eye (see Figure 14)
2. Stratified according to the amount of myopia in near eye and age (see Figure 15)

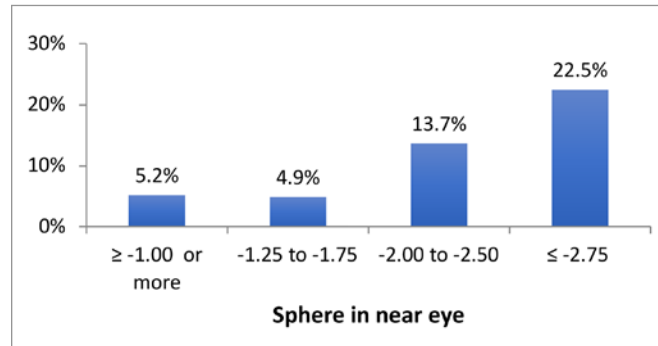


Figure 14. LCV monovision satisfaction (Dissatisfied / Very Dissatisfied), stratified according to the amount of myopia in near eye.

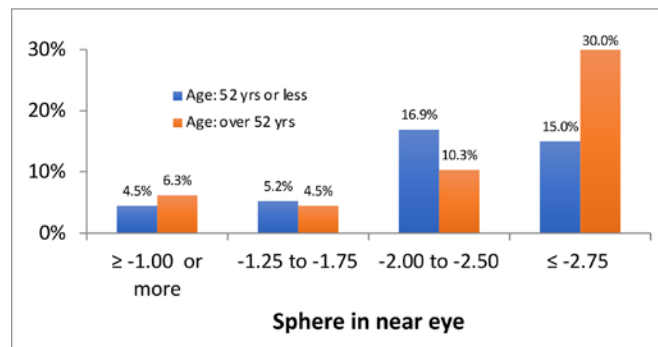


Figure 15. LCV monovision satisfaction (Dissatisfied / Very Dissatisfied), stratified according to the amount of myopia in near eye and age.

VIII. Conclusions

- A. Subgroups well matched
 1. Preop refraction
 2. Preop visual and ocular symptoms
- B. LASIK monovision compared to RLE with M-IOL
 1. Similar QoL and dry eye symptoms
 2. Moderate to high myopia advantages for LASIK monovision
 - a. Satisfaction / Recommend Procedure to Friend or Family
 - b. Near vision
 - c. Less quality of vision (QoV) symptoms
- C. Hyperopes advantages of RLE
 1. UCVA
 2. Satisfaction
 3. However, patients notice increase in QoV symptoms.

IX. Recommendations

- A. Irrespective of age, the near eye target should be between -1.25 and -1.75 D for LASIK monovision.
- B. Symphony refractive target: emmetropia both eyes
- C. LASIK monovision in plano presbyopes requires additional counselling; their satisfaction, QoV, and QoL are lower than those of ametropic patients. Hyperopic presbyopes seeking correction of distance and near vision: RLE with M-IOL as the first option.
- D. Myopic presbyopes seeking correction of distance and near vision: LASIK monovision as the first option.

Advances in Corneal Surgery for Myopia: LASIK vs. SMILE vs. PRK

Jodhbir S Mehta MBBS PhD

PRK, LASIK, and SMILE are the 3 most commonly performed corneal refractive procedures. Each procedure has its own risks and benefits. The talk will highlight the benefits and the limitations of each procedure by showing its use in certain situations and its benefits in others.

Several advances in each of the procedures have increased their use in areas where previously they would be contraindicated. These can be divided into patient-related factors and procedure-related factors.

People Involved in Contact Sports / Certain Occupations

PRK and SMILE have the benefit of being flapless procedures. Despite the reduced incidence of flap-related complications with femtosecond laser flaps compared to microkeratome flaps, there is still a chance of flap-related problems with LASIK. For people performing contact sports, a flapless procedure may be a better option.

Biomechanics

Due to the nature of the procedures, both PRK and SMILE have been shown to be biomechanically stronger than LASIK for the equivalent myopic correction. This is especially important in correcting people with moderate to high degrees of myopia.

Visual Recovery

The visual outcomes from comparative studies show that the safety and efficacy of all 3 procedures are good. However, the speed of visual recovery is different among them, with LASIK being the fastest and PRK being the slowest.

Moderate Myopia

In patients with moderate myopia, LASIK and SMILE are the procedures of choice since there is an increased risk of postoperative haze formation with PRK. This often requires the use of mitomycin C, the concentration of which varies in the literature depending on the ethnicity of the patient.

High Myopia

In patients with moderate to high myopia, SMILE is the procedure of choice. Because of femtosecond laser technology, the refractive correction undergoes less wound healing response than in the excimer-based treatment of both LASIK and SMILE.

Nervous/Uncooperative Patients

Patients who are nervous or uncooperative are better off proceeding with PRK or LASIK. SMILE does require a longer time under laser and significant movement may lead to suction loss and a compromised visual outcome.

Dry Eye

This is a common side effect of all corneal laser-based procedures. Generally the recovery in most patients is complete, but patients with pre-existing dry eye and poor nerve regeneration are at risk of prolonged recovery. Studies have shown faster nerve and tear film recovery in PRK than in LASIK. This is mainly due to the transection of the corneal stromal nerves caused by the LASIK flap formation. Comparative studies with SMILE and LASIK have shown faster recovery of tear film with SMILE than LASIK. By 6 months, however, the recovery is almost the same. Hence patients at risk of dry eye preoperatively may be more suited to PRK and SMILE than LASIK.

Presbyopic Correction

The majority of the presbyopic excimer-based options are performed as a LASIK procedure (eg, PresbyMax, Supracor, Presbyond). If a patient is to choose a presbyopic procedure as such they must undergo LASIK, with the exception of monovision correction, which can be performed with any of the 3 procedures. However, monovision correction for patients who are either unhappy with the outcome or require adjustment of near vision focal plane is far easier with LASIK than with SMILE and PRK. Hence the former may be the procedure of choice.

High Preop HOAs

Topography-guided treatment allows us to treat high-order aberrations with an excimer laser. Currently this is only available as LASIK and PRK. SMILE is not topography guided as yet.

Hyperopic Treatment

Currently SMILE is approved for use with myopic astigmatism. So if a patient requires hyperopic astigmatism correction they would require LASIK or PRK currently; this may change in the future.

In conclusion, there have been significant advances in all forms of corneal refractive laser surgery. Future developments are expected to make this procedure even more efficacious.

Advances in Presbyopia Therapies

Y Ralph Chu MD

- I. Corneal Inlays
 - A. Kamra
 - B. Presbia
- II. Scleral Micro Inlays
 - A. VisAbility
- III. Pharmacologic
 - A. Orasis
 - B. Encore Vision
- IV. IOL Technologies
 - A. Bifocal
 - 1. Lenstec
 - 2. Small Aperture IC-8 (Acufocus)
 - B. Extended depth of focus
 - 1. CORD
 - 2. Trifocal
 - 3. Accommodative
 - a. PowerVision
 - b. LensGen
 - C. Perfect Lens

Decision Making in Presbyopic IOLs

John So-Min Chang MD

NOTES

Advances in Corneal Inlays for Presbyopia

William F Wiley MD

NOTES

Refractive Index Reshaping of the Lens

Adjusting IOLs in Vivo With Refractive Index Shape Changing

George Waring IV MD

- I. Hydrophilicity Refractive Index Shape (RIS) Change
 - A. Femtosecond laser applied to an acrylic IOL selectively changes:
 - 1. Polarity
 - 2. Refractive index
 - B. Allows for the creation of 3-D structures within an IOL

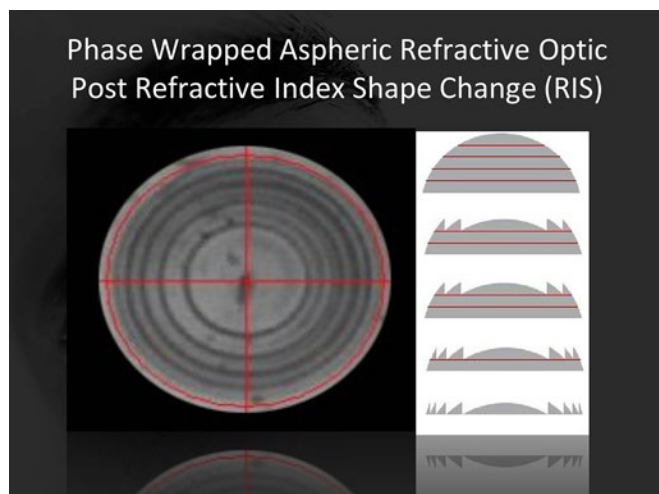


Figure 1.



Figure 2.

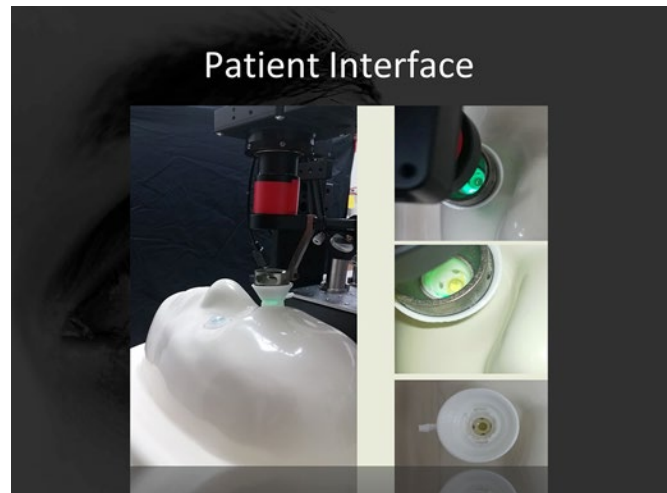


Figure 3.

- II. Examples
 - A. Intended defocus reduction (see Figure 4)
 - B. Myopic or hyperopic defocus change (see Figure 5)
 - C. Combined spherical and aspherical treatment (see Figure 6)
 - D. Astigmatism correction (see Figure 7)
 - E. Monofocal to multifocal (see Figure 8)
 - F. Reversing multifocality (see Figure 9)
 - G. Monofocal to multifocal to monofocal (see Figure 10)

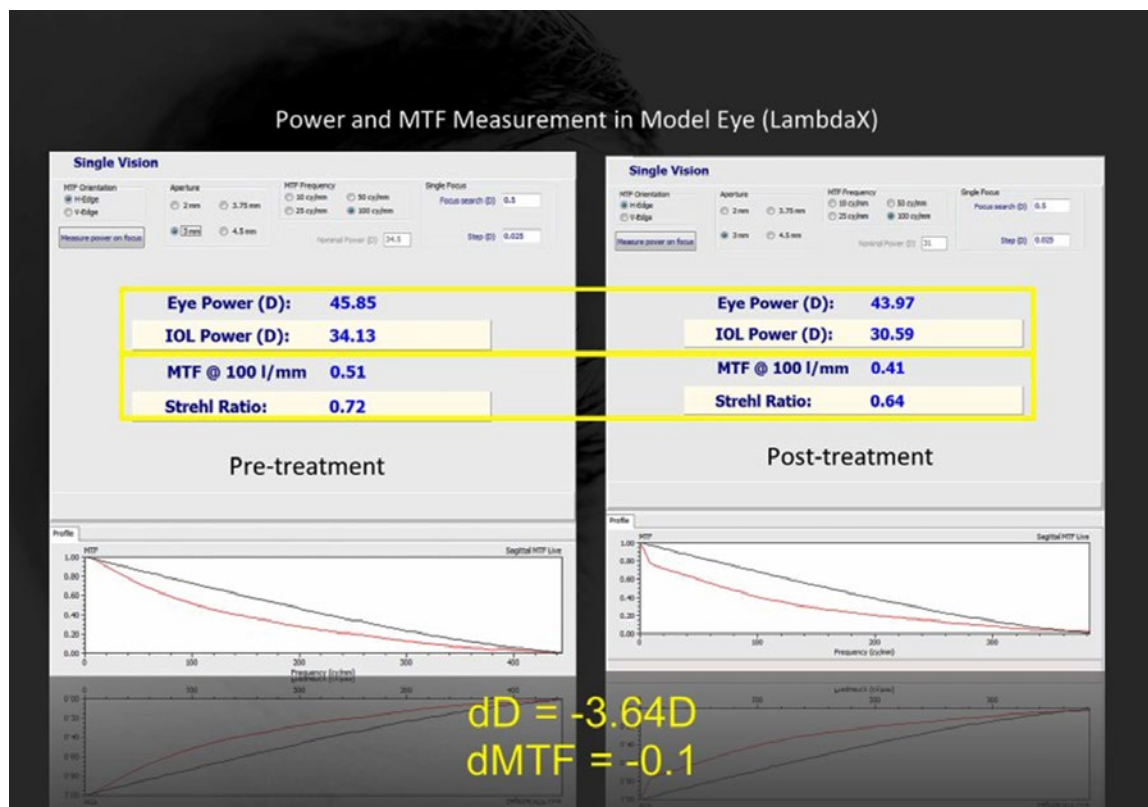


Figure 4. Intended defocus reduction of 3.6 D.

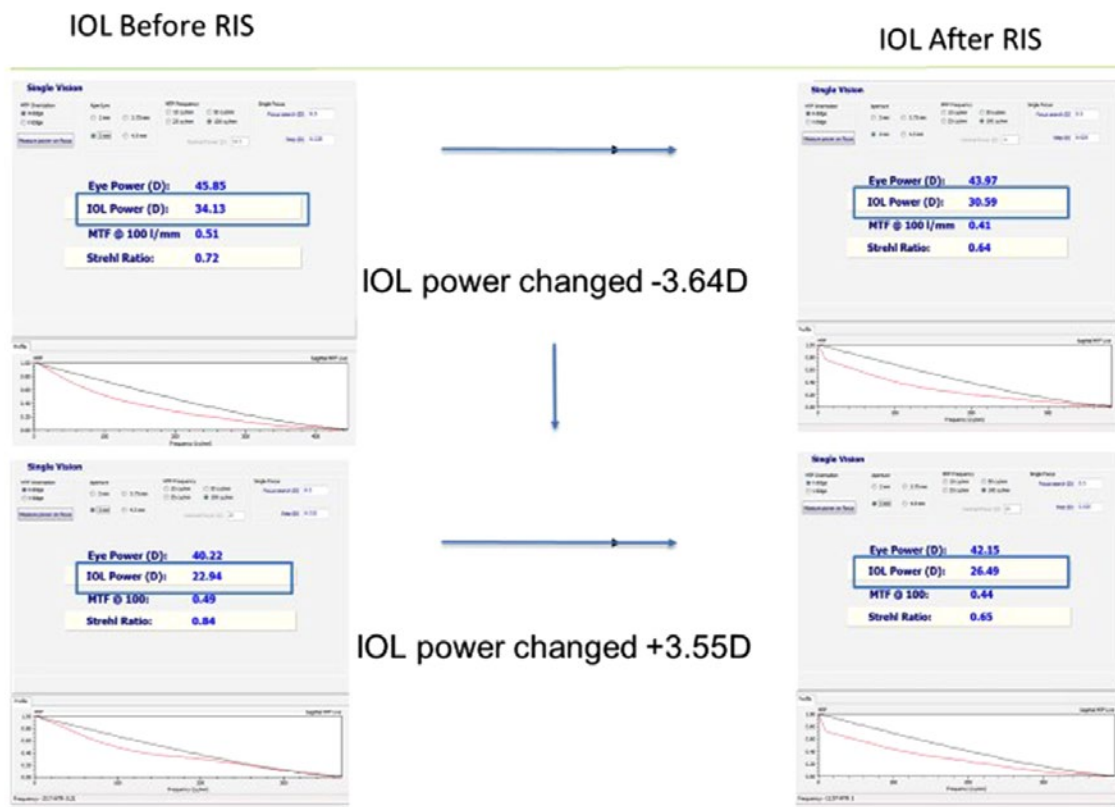


Figure 5. Myopic or hyperopic defocus change.

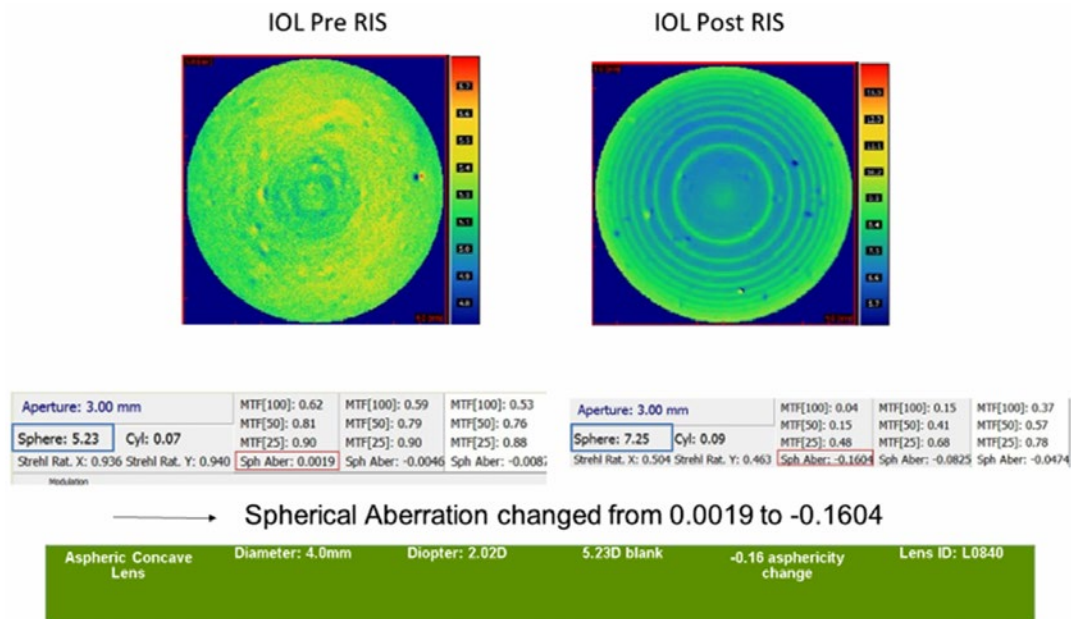


Figure 6. Combined spherical and aspherical treatment, wavefront sensor (Nemo).

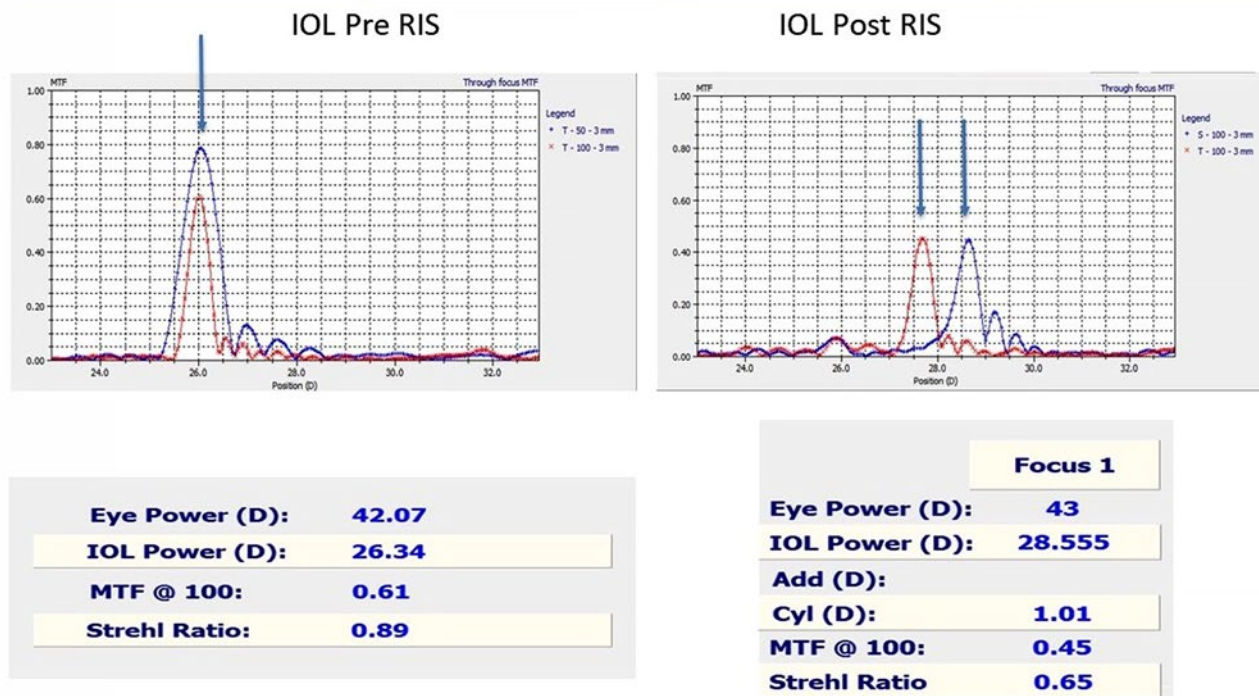


Figure 7. Astigmatism correction.

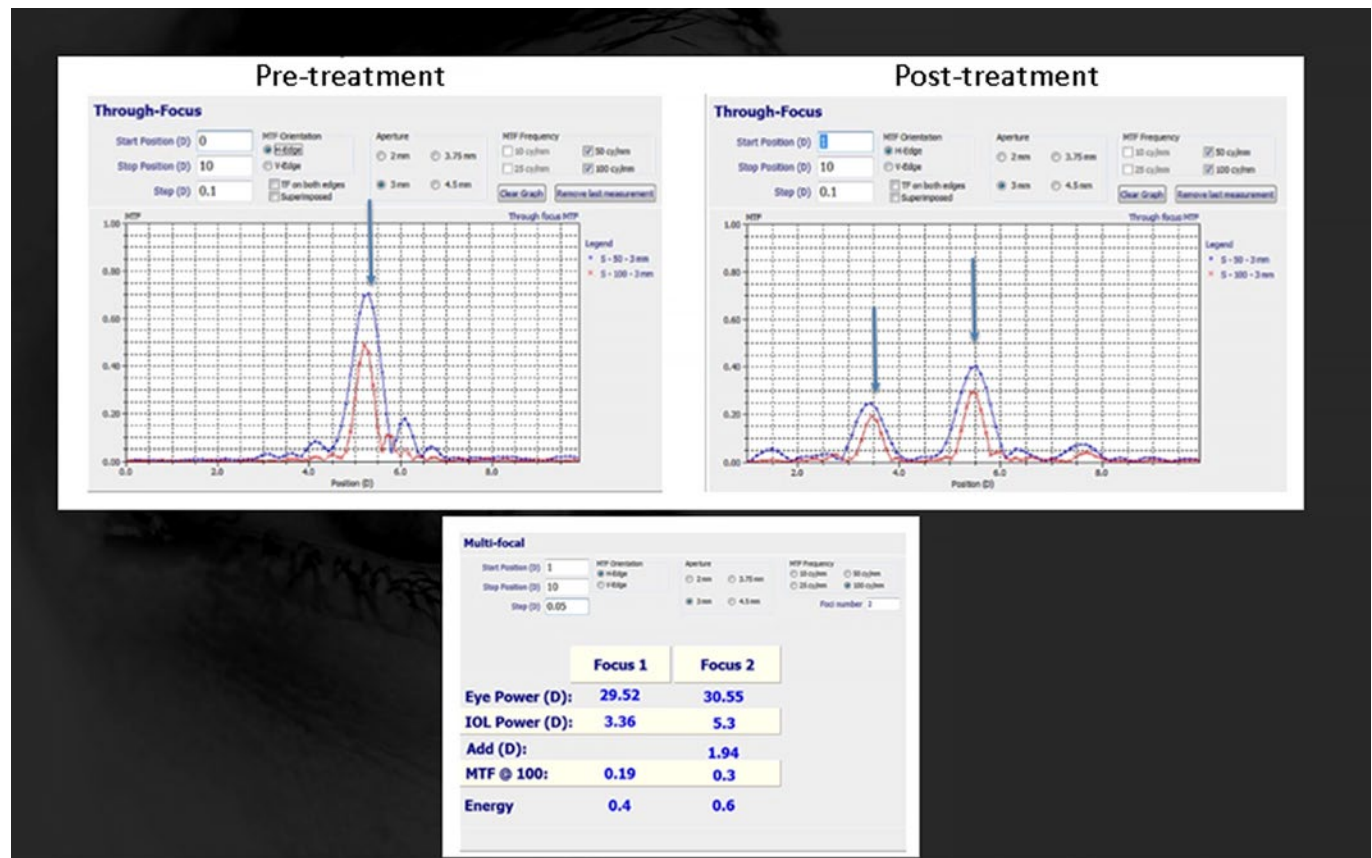


Figure 8. Monofocal to multifocal.

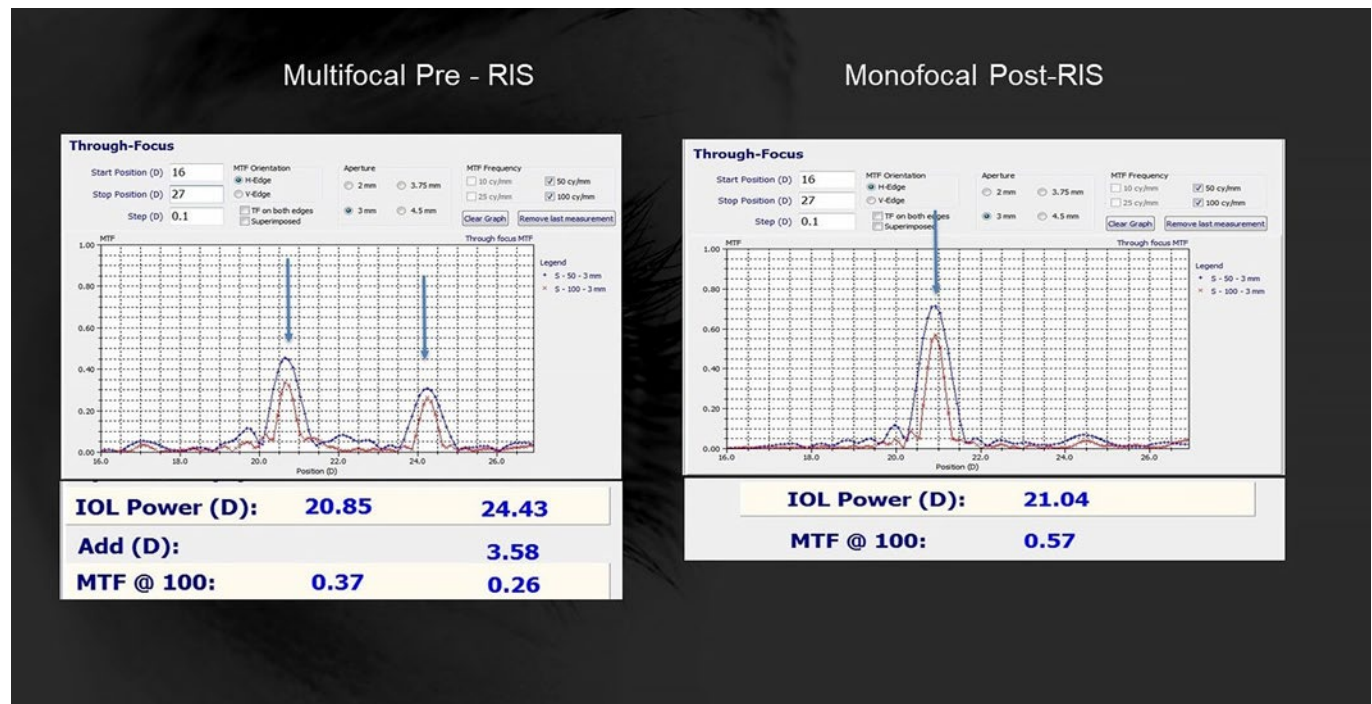




Figure 9. Reversing multifocality.

Monofocal




Before

Multifocal



1st treatment

Monofocal



2nd treatment

Figure 10. Monofocal to multifocal to monofocal.

III. Customization of Near / Far Light Distribution (see Figure 11)

- A. Potential strategy to aid in patients not adapting well to MFIOL
 1. Shift relative % of near light to distance (eg, 60/40 to 75/25)
 2. Preserve multifocality
- B. Potential strategy for neuroadaptation (see Figure 12)
 1. Initiate with primary distance split (80/20)
 2. Gradually increase as desired for effect over time (80/20 to 70/30 to 60/40)
- C. Customization of multifocal distance / near light split for various pupil sizes

IV. Capabilities of RIS

- A. Add or remove defocus power of IOL
- B. Modify toricity
- C. Create custom asphericity
- D. Create EDOF
- E. Create multifocality in monofocal IOL
 1. Refractive multifocality
 2. Diffractive multifocality

F. Customize multifocality

1. Add power
2. Light split
3. Progressively add light to near
4. Customize for pupil size

G. Reverse multifocality

H. Adjust power for pediatric IOLs through lifetime

V. Summary

- A. Refractive index shape change technology enables creation of a lens within an IOL.
- B. Potential applications include customization of most optical circumstances, including reversal and customization of multifocality.
- C. Applications for manufacturing and in vivo IOL treatments
- D. New paradigm in customized IOLs and in vivo postsurgical enhancements
- E. Replace IOL exchange and laser vision correction enhancements?

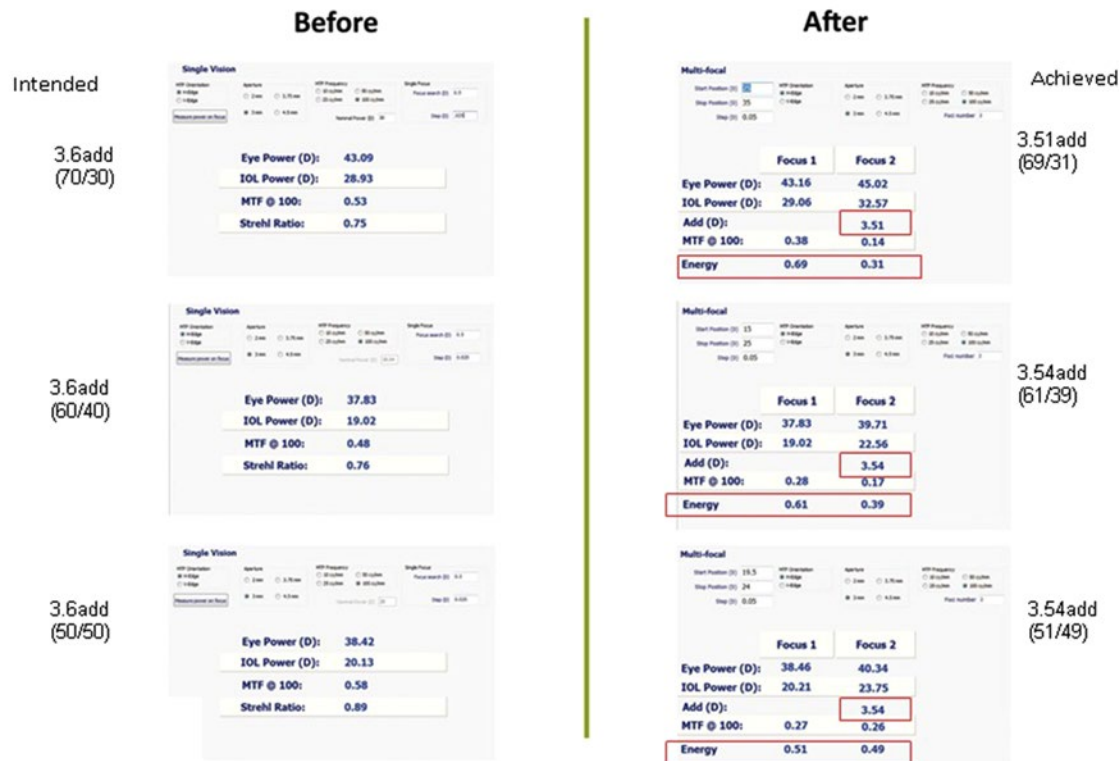

Figure 11. Far / near light energy customization in MF-IOL.

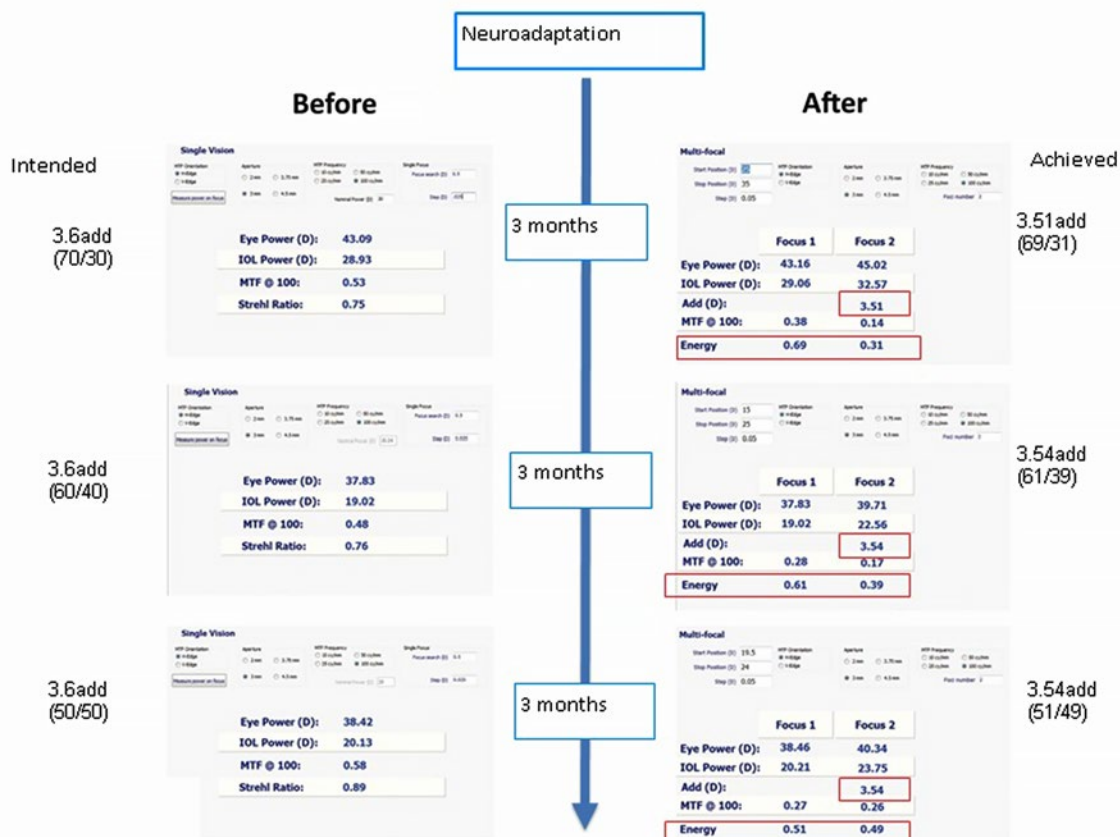


Figure 12. Far / near light energy customization in MF-IOL for neuroadaptation.

R Doyle Stulting MD PhD

NOTES

Crosslinking Combination Therapies

A John Kanellopoulos MD

- I. Combining Topography-Guided Partial PRK With Corneal Crosslinking (CXL): The Athens Protocol
 - A. Surgical technique (see Figure 1)
 - B. Visual rehabilitation of progressing keratoconus in same-day simultaneous topography-guided PRK and CXL vs. sequential CXL and PRK
 - C. Clinical stabilization of ectasia following LASIK

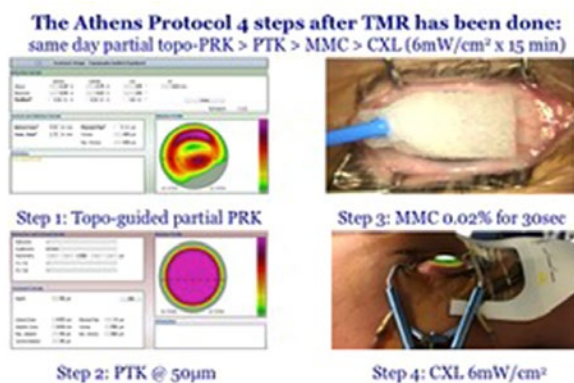


Figure 1. The 4 steps of the current Athens protocol.

- II. LASIK Xtra: Combining LASIK and CXL
 - A. Who should have LASIK Xtra?
 - B. LASIK Xtra for high refractive corrections
 - C. CXL and long-term hyperopic LASIK stability
- III. Prophylactic CXL In Situ Femtosecond Laser-Assisted Treatment of Corneal Ectasia
- IV. Prophylactic CXL in Attempting Corneal Deturgescence in Bullous Keratopathy
- V. Prophylactic CXL as a Prophylactic Intervention Adjuvant to Boston Keratoprosthesis Surgery
- VI. Photorefractive Intrastromal Crosslinking (PiXL)
 - A. Customizable patterns for predictable refractive changes
 - B. The epithelium-on CXL results in a significantly weaker biomechanical effect in comparison to the epithelium-off CXL.
 - C. Addressing keratoconus with PiXL
- VII. CXL and Intrastromal Corneal Ring Segments

Can a combination of CXL and ICRS implantation offer an enhanced treatment option in eyes with keratoconus?

VIII. Phakic IOLs After CXL

Phakic IOLs appear to be safe and effective in high residual myopia and/or anisometropia after CXL stabilization or PRK/CXL combined simultaneous technique (Athens protocol).

IX. CXL in Infectious Keratitis

- A. As a sole treatment
- B. In combination with antibiotics
- C. As prophylaxis for cornea melts (keratoprosthesis)

X. Management of Complications

- A. Delayed epithelial healing / scarring
- B. Protection of limbus
- C. Medications
- D. Autologous serum / platelet rich plasma (PRP)

XI. Evaluation Diagnostics and Surgery Videos

- A. Correlation on modern diagnostics for ectasia and cornea biomechanics (Placido disc-based, Scheimpflug-based, and color LED spot topography, anterior segment OCT, high-frequency ultrasound, ocular scatter measurements, cornea hysteresis)
- B. Step-by-step video case review and discussion

Selected Readings

1. Kanellopoulos AJ, et al. Management of corneal ectasia after LASIK with combined, same-day, topography-guided partial transepithelial PRK and collagen cross-linking: the Athens protocol. *J Refract Surg.* 2011; 27:323-331.
2. Kanellopoulos AJ, et al. Revisiting keratoconus diagnosis and progression classification based on evaluation of corneal asymmetry indices, derived from Scheimpflug imaging in keratoconic and suspect cases. *Clin Ophthalmol.* 2013; 7:1539-1548.
3. Kanellopoulos AJ, et al. Keratoconus management: long-term stability of topography-guided normalization combined with high-fluence CXL stabilization (the Athens Protocol). *J Refract Surg.* 2014; 30:88-93.
4. Kanellopoulos AJ, et al. Collagen cross-linking (CCL) with sequential topography-guided PRK: a temporizing alternative for keratoconus to penetrating keratoplasty. *Cornea* 2007; 26:891-895.

Phakic IOLs

Erik L Mertens MD FRACOPhth

Phakic IOLs have proven to be of enormous benefit for many patients. These lenses are the best choice for vision correction. In general, phakic IOLs have several potential advantages over laser treatment. The cornea is not altered, the IOLs can correct higher amounts of myopia, and they provide excellent quality of vision with no induced higher-order aberrations. These qualities come from being an additive procedure, whereas laser vision correction is subtractive. It is not dose dependent; it is the same for a -1.00 D myope as a -16.00 D myope.

Types

Anterior chamber

- Iris claw Artisan / Verisyse (Ophtec / Johnson & Johnson Vision)
- Iris claw Artiflex / Veriflex (Ophtec / Johnson & Johnson Vision)

Posterior chamber

- EVO and EVO+ Visian ICL (Staar Surgical)
- IPCL (Care Group)

Reasons for Adopting Phakic IOLs as Part of Your Refractive Surgical Armamentarium

Reason No. 1: Phakic IOLs do not require tissue alteration for refractive correction, the quality of postoperative UCVA does not vary with preoperative refractive error.

In a commentary in *JAMA Ophthalmology* on long-term outcomes after posterior phakic IOL implantation for myopia, Stephen D McLeod MD noted, “Phakic intraocular lenses can provide optically superb correction of relatively high degrees of ametropia that lie well beyond the recommended range for keratorefractive procedures, such as laser in situ keratomileusis and photorefractive keratectomy.”¹

Reason No. 2: Phakic IOLs outperform excimer laser procedures in moderate to high myopia.

Schallhorn et al recently reported that “in a prospective, randomized, study comparing ICL implantation and photorefractive keratectomy, the ICL performed better than photorefractive keratectomy in all measures of safety, efficacy, predictability, and stability, supporting the ICL as a viable alternative to this popular refractive surgical procedure.”² Further, a review by Barsam et al found that phakic IOLs were more accurate and safer than excimer laser surgical correction for moderate to high myopia in the range of -6.00 to -20.00 D.³ The reviewers noted that although phakic IOL implantation is often reserved for treatment of higher levels of myopia (> -7.00 D), it may be considered over laser refractive surgery for eyes with lower levels of myopia (≤ 7.00 D) with or without astigmatism as well.³

Reason No. 3: Patients report significant gains in quality of life following ICL implantation.

In a study of quality of life before and after implantation of the Visian ICL, Jeong et al found that “implantation provided significant gains across a broad range of life activities and is clearly a life-changing intervention for many patients with high myopia.”⁴

Data Review

Effectiveness

In 2016, Mark Packer MD FACS examined the peer-reviewed literature from the decade since FDA approval of the Visian ICL.⁵ The resulting meta-analysis indicated that refractive correction with the ICL is predictable and stable over a wide range of refractive errors.

In a multicenter clinical trial that supported FDA approval of the Toric Visian ICL, 210 eyes with a mean spherical equivalent of -9.00 D and mean cylinder of approximately 2.00 D were enrolled. Postoperatively, 77% of treated eyes had a UCVA equal to or better than the preoperative BCVA. At 1 year postoperative, UCVA was 20/20 in 83% of treated eyes and 20/40 in 96%.⁶ These results rival those of LASIK for lower refractive errors,^{7,8} for which the efficacy index remains below 1.0. They also rival the results of small-incision lenticule extraction in eyes with less than -8.00 D of myopia without astigmatism, where about 88% achieve 20/20 UCVA.⁹

In the study of the Visian ICL by Schallhorn et al, 86% of eyes achieved 20/20 UCVA at 1 week postoperative.² Alfonso and colleagues, who reported 5-year follow-up in 188 eyes of 111 patients, noted that mean manifest refraction spherical equivalent (MRSE) decreased from -11.17 ± 3.40 D preoperatively to -0.23 ± 0.50 D at 1 month postoperative.¹⁰ Furthermore, they found that a high level of predictability was achieved early after surgery: 86.7% of eyes were within ± 0.50 D and 96.8% within ± 1.00 D of attempted correction at 1 month. This improvement was maintained over the 5-year period of follow-up.

These results are representative of those identified in my meta-analysis of the literature,⁵ and they underscore the outstanding efficacy of ICL implantation.

Quality of life

Kobashi and coauthors compared quality of life following Visian ICL implantation in patients with mean preoperative MRSE of -9.97 ± 2.51 D (range: -3.00 to -14.50 D) to that following LASIK in patients with mean preoperative MRSE of -6.31 ± 2.20 D (range: -3.00 to -12.88 D). They reported that scores for activity limitations, symptoms, appearance, and satisfaction with correction were significantly higher in the phakic IOL group than in the LASIK group.¹¹ These authors concluded that ICL implantation “may offer significant vision-related quality-of-life advantages (eg, fewer activity limitations

and symptoms and better appearance and satisfaction with correction) over wavefront-guided LASIK for myopia in the long term.”

The possibility of providing substantial gains in quality of life for our patients creates a strong incentive for surgeons to consider phakic IOL implantation.

Safety

Specific safety concerns related to phakic IOL implantation include cataract, increased IOP, and effects on corneal endothelial health. Because of the position of the Visian ICL in the posterior chamber, close to the crystalline lens, the long-term incidence of anterior subcapsular cataract raises concern.

Fortunately, a postmarketing study of the ICL provides reassuring data.¹² In that trial, the incidence of anterior subcapsular cataract was studied in 526 eyes of 294 patients, followed for up to 7.5 years, including 334 eyes available for analysis at 5 or more years. Over that period, a total of 31 eyes developed anterior subcapsular opacities; however, only 5 of these eyes developed visually significant anterior subcapsular cataracts. Per eye, the risk of developing any anterior subcapsular cataract opacity was 6.1% at 5 years, and the risk of developing a visually significant anterior subcapsular cataract was 1.2%. With regard to the incidence of cataract, evidence shows that older age and higher levels of myopia represent risk factors; thus, patient selection can reduce this risk.⁵

The incidence of elevated IOP requiring treatment, especially in the immediate postoperative period when pupillary block may occur, is another important safety concern. In the same Visian ICL postmarketing clinical trial,¹² there were 17 cases of pupillary block out of 526 eyes implanted (3.2%). All were treated successfully with Nd:YAG laser iridotomy. There were also 3 eyes with elevated IOP due to retained ophthalmic viscosurgical device (OVD), all of which resolved after irrigation and aspiration. The risk of elevated IOP in the early postoperative period can be mitigated by use of proper surgical technique; it depends on construction of iridotomies of adequate size and thorough removal of OVD.

Corneal endothelial health was also addressed in the same postmarketing study. Based on clinical data collected through 5 to 7 years postoperatively, the calculated chronic rate of loss of endothelial cell density (ECD) was approximately 1.8% per year.¹² Moya and coauthors published a cumulative 12-year retrospective study including data from 144 eyes implanted with Visian ICLs between 1998 and 2001.¹³ These authors reported a 6.46% surgically induced decrease in ECD in the first year, followed by an average yearly rate of decrease of 1.20%.¹³ These rates should be viewed in the context of the expected age-related loss of ECD, which is about 0.6% per year.¹⁴ Of note, no cases of corneal decompensation in the absence of trauma have been reported following implantation.¹⁵

The reported rates of these specific complications have generally remained low.⁵ Given the significant improvements in vision and quality of life made possible by the ICL, and the high degree of patient satisfaction associated with its use, the benefits of ICL implantation appear to outweigh the risks.

References

- McLeod SD. Long-term clinical outcomes and cataract formation rates after posterior phakic lens implantation for myopia. *JAMA Ophthalmol.* 2016; 134(5):494-495.
- Schallhorn S, Tanzer D, Sanders DR, Sanders ML. Randomized prospective study of Visian toric implantable collamer lens and conventional photorefractive keratectomy for moderate to high myopic astigmatism. *J Refract Surg.* 2007; 23(9):853-857.
- Barsam A, Allan BD. Excimer laser refractive surgery versus phakic intraocular lenses for the correction of moderate to high myopia. Cochrane Database of Systematic Reviews 2014, Issue 6. Art. No.:CD007679.
- Jeong A, Hau SC, Rubin GS, Allan BD. Quality of life in high myopia before and after implantable collamer lens implantation. *Ophthalmology* 2010; 117(12):2295-2300.
- Packer M. Meta-analysis and review: effectiveness, safety, and central port design of the intraocular collamer lens. *Clin Ophthalmol.* 2016; 10:1059-1077.
- Sanders DR, Schneider D, Martin R, et al. Toric implantable collamer lens for moderate to high myopic astigmatism. *Ophthalmology* 2007; 114(1):54-61.
- Wong RC, Yu M, Chan TC, Chong KK, Jhanji V. Longitudinal comparison of outcomes after sub-Bowman keratomileusis and laser in situ keratomileusis: randomized, double-masked study. *Am J Ophthalmol.* 2015; 159(5):835-845.e3.
- Frings A, Richard G, Steinberg J, et al. LASIK for spherical refractive myopia: effect of topographic astigmatism (ocular residual astigmatism, ORA) on refractive outcome. *PLoS One.* 2015; 10(4):e0124313.
- Summary of Safety and Effectiveness Data. VisuMax Femto-second Laser. US Food and Drug Administration. https://www.accessdata.fda.gov/cdrh_docs/pdf15/P150040B.pdf. Accessed April 3, 2018.
- Alfonso JF, Baamonde B, Fernández-Vega L, Fernandes P, González-Méjome JM, Montés-Micó R. Posterior chamber collagen copolymer phakic intraocular lenses to correct myopia: five-year follow-up. *J Cataract Refract Surg.* 2011; 37(5):873-880.
- Kobashi H, Kamiya K, Igarashi A, Matsumura K, Komatsu M, Shimizu K. Long-term quality of life after posterior chamber phakic intraocular lens implantation and after wavefront-guided laser in situ keratomileusis for myopia. *J Cataract Refract Surg.* 2014; 40(12):2019-2024.
- Visian ICL (Implantable Collamer Lens) for Myopia: Directions for Use. Staar Surgical. http://staar.com/file/PKG-02012_Rev_2_DFU-for-MICL-Visian-ICL.pdf. Accessed April 3, 2018.
- Moya T, Javaloy J, Montés-Micó R, Beltrán J, Muñoz G, Montalbán R. Implantable collamer lens for myopia: assessment 12 years after implantation. *J Refract Surg.* 2015; 31(8):548-556.
- Bourne WM, Nelson LR, Hodge DO. Central corneal endothelial cell changes over a ten-year period. *Invest Ophthalmol Vis Sci.* 1997; 38(3):779-782.
- Transcript. Center for Devices and Radiological Health Medical Devices Advisory Committee, Ophthalmic Devices Panel. Gaithersburg, Maryland. March 14, 2014.
- Rose K, Harper R, Tromans C, et al. Quality of life in myopia. *Br J Ophthalmol.* 2000; 84(9):1031-1034.

Prevention of Cystoid Macular Edema and Infection in Lens-Based Surgery

Bonnie An Henderson MD

I. Background

- A. Complications from cataract surgery are not common.
- B. Types of complications
- C. Incidence rates
- D. Serious vision-threatening complications: endophthalmitis, retinal detachment, and cystoid macular edema

II. Endophthalmitis

- A. Causes
- B. Current treatments
- C. Methods of prevention
 1. Topical betadine on ocular surface
 2. Role of preoperative antibiotics (duration, mode of delivery)
 3. Role of intraoperative antibiotics or treatments (published studies on intracameral antibiotics)
 4. Role of postoperative antibiotics
 5. Other factors: wound construction, IOP, complicated surgery, comorbidities, age

III. Cystoid Macular Edema

- A. Causes
- B. Role of preoperative testing
- C. Prevention
 1. Role of preoperative medications
 2. Role of intraoperative treatment
 3. Role of postoperative NSAIDs, steroids: when to use, duration, evidence-based treatments for prevention
 4. Published studies about prevention

phthalmitis after cataract surgery: preliminary report of principal results from a European multicenter study. *J Cataract Refract Surg.* 2006; 32:407-410.

4. ESCRS Endophthalmitis Study Group, European Society of Cataract & Refractive Surgeons. Prophylaxis of postoperative endophthalmitis following cataract surgery: results of the ESCRS multicenter study and identification of risk factors. *J Cataract Refract Surg.* 2007; 33:978-988.
5. Chang DF, Braga-Mele R, Mamalis N, et al.; the ASCRS Cataract Clinical Committee. Prophylaxis of post-operative endophthalmitis after cataract surgery: results of the 2007 ASCRS member survey. *J Cataract Refract Surg.* 2007; 33:1801-1805.
6. Lundström M, Wejde G, Stenevi U, et al. Endophthalmitis after cataract surgery: a nationwide prospective study evaluating incidence in relation to incision type and location. *Ophthalmology* 2007; 114(5):866-870.
7. García-Sáenz MC, Arias-Puente A, Rodríguez-Caravaca G, Bañuelos JB. Effectiveness of intracameral cefuroxime in preventing endophthalmitis after cataract surgery: ten-year comparative study. *J Cataract Refract Surg.* 2010; 36(2):203-207.
8. Barreau G, Mounier M, Marin B, et al. Intracameral cefuroxime injection at the end of cataract surgery to reduce the incidence of endophthalmitis: French study. *J Cataract Refract Surg.* 2012; 38(8):1370-1375.
9. Tan CS, Wong HK, Yang FP. Epidemiology of postoperative endophthalmitis in an Asian population: 11-year incidence and effect of intracameral antibiotic agents. *J Cataract Refract Surg.* 2012; 38(3):425-430.
10. Shorstein NH, Winthrop KL, Herrington LJ. Decreased postoperative endophthalmitis rate after institution of intracameral antibiotics in a Northern California eye department. *J Cataract Refract Surg.* 2013; 39:8-14.
11. American Academy of Ophthalmology Cataract and Anterior Segment Panel. *Preferred Practice Pattern Guidelines: Cataract in the Adult Eye.* San Francisco, CA: American Academy of Ophthalmology; 2011. Available at: www.aao.org/ppp.
12. Packer M, Chang, DF, Dewey SH, et al. Prevention, diagnosis and management of acute postoperative bacterial endophthalmitis. *J Cataract Refract Surg.* 2011; 37:1699-1714.
13. Friling E, Lundström M, Stenevi U, Montan P. Six-year incidence of endophthalmitis after cataract surgery: Swedish national study. *J Cataract Refract Surg.* 2013; 39:15-21.
14. Barry P, Cordoves L, Gardner S. *ESCRS Guidelines for Prevention and Treatment of Endophthalmitis Following Cataract Surgery.* European Society for Cataract & Refractive Surgeons; 2013.
15. Barry P. Adoption of intracameral antibiotic prophylaxis of endophthalmitis following cataract surgery: update on the ESCRS Endophthalmitis Study. *J Cataract Refract Surg.* 2014; 40:138-142.
16. Henderson BA, Kim JY, Ament CS, Ferrufino-Ponce ZK, Grabowska A, Cremers SL. Clinical pseudophakic cystoid macular edema: risk factors for development and duration after treatment. *J Cataract Refract Surg.* 2007; 33(9):1550-1558.

Selected Readings

1. Chang DF, Braga-Mele R, Henderson BA, Mamalis N, Vasavada A; ASCRS Cataract Clinical Committee. Antibiotic prophylaxis of postoperative endophthalmitis after cataract surgery: results of the 2014 ASCRS member survey. *J Cataract Refract Surg.* 2015; 41(6):1300-1305.
2. Braga-Mele R, Chang DF, Henderson BA, Mamalis N, Talley-Rostov A, Vasavada A. A review of intracameral antibiotic: safety, efficacy, and preparation. *J Cataract Refract Surg.* 2014; 40(12):2134-2142.
3. Barry P, Seal DV, Gettinby G, et al; ESCRS Endophthalmitis Study Group. ESCRS study of prophylaxis of postoperative endophthalmitis after cataract surgery: preliminary report of principal results from a European multicenter study. *J Cataract Refract Surg.* 2006; 32:407-410.

Pearls and Pitfalls in Biometry Following Corneal Refractive Surgery or Keratoconus

Jack T Holladay MD MSEE FACS

I. Introduction

A. Pitfalls

1. Keratometry is inaccurate after corneal refractive surgery and in keratoconus.
 - a. With myopic corneal refractive surgery and in keratoconus, keratometry overestimates corneal power, resulting in hyperopic surprise.
 - b. With hyperopic corneal refractive surgery, keratometry underestimates corneal power, resulting in myopic surprise.
2. Dry eye is very common after refractive surgery and must be treated before reliable corneal power can be determined.
3. Optical biometry is inaccurate in long eyes (> 26.0 mm), which is very common in eyes having myopic corneal refractive surgery. The biometer overestimates the axial length, resulting in hyperopic surprise. An adjustment should be used in these eyes, such as the Wang/Koch linear adjustment or the Holladay nonlinear adjustment.¹

B. Pearls

1. Topography or tomography should always be performed in these cases.²
 - a. The zonal corneal power from the 4.5-mm zone should be used to determine the spherical equivalent power and magnitude and axis of astigmatism. The ring value (SimK) is too small a sample of values and not an accurate value.

- b. The higher-order RMS corneal wavefront error over a 6-mm zone should be determined with the topographer / tomographer.³ If value is > 1.0 μm , the retinal image is already compromised from corneal irregularity and multifocal or extended depth of focus IOLs should be avoided.

- i. Normal = $0.38 \pm 0.14 \mu\text{m}$

- ii. Postoperative LASIK happy = $0.58 \pm 0.21 \mu\text{m}$

- iii. Postoperative LASIK unhappy = $1.31 \pm 0.58 \mu\text{m}$

2. Current generation IOL calculation formulas, such as the Barrett 2, Olsen 2, and Holladay 2, have been shown to perform better than older formulas in these eyes.

References

1. Wang L, Shirayama M, Ma XJ, Kohnen T, Koch DD. Optimizing intraocular lens power calculations in eyes with axial lengths above 25.0 mm. *J Cataract Refract Surg*. 2011; 37:2018-2027.
2. Holladay JT, Hill WE, Steinmueller A. Corneal power measurements using Scheimpflug imaging in eyes with prior corneal refractive surgery. *J Refract Surg*. 2009; 25:862-868.
3. McCormick GJ, Porter J, Cox IG, MacRae S. Higher-order aberrations in eyes with irregular corneas after laser refractive surgery. *Ophthalmology* 2005; 112(10):1699-1709.

Management of Corneal Refractive Surgery Complications

Helen K Wu MD

NOTES

Management of Complications Following Crosslinking

Marcony R Santhiago MD

Corneal crosslinking (CXL) with riboflavin has gained world-wide acceptance and has been used as the main therapeutic option to potentially halt the progression of keratoconus, pellucid marginal corneal degeneration, and postoperative corneal ectasia. Despite its widespread use, a few complications have been described, including corneal infiltrates, temporary and permanent corneal haze, and an ongoing flattening and thinning.

Corneal Infiltrates

We hypothesize that the phototoxic effect on the corneal stroma may be the main mechanism that triggers these infiltrates. Alternatively, alterations in antigenicity that occur in native proteins after CXL could result in the body recognizing the proteins as nonself and mounting an immune response. By its very mechanism, crosslinking randomly alters the antigenic sites on native proteins in the cornea. It has been demonstrated that the actual crosslinks are not formed between and within the collagen fibers but rather between the amino terminals of the collagen side chains and the proteoglycans of the extracellular matrix.

Corneal Haze

Corneal haze after CXL is likely attributed to a more extensive stromal wound healing response that is proportional to the level of stromal cell death and associated with the generation of corneal fibroblasts with decreased intracellular corneal crystalline production and alterations in the regular structure of the stromal matrix that is responsible for optical transparency of the cornea. Our results show that the increase in stromal opacity is not attributed to myofibroblast generation, as it is after PRK. This provides an explanation for (1) the more transient nature of stromal opacity noted in CXL, measured in months rather than the years it often persists after PRK, and (2) the tendency for the opacity to extend deeper in the stroma rather than be confined to the subepithelial stroma, as it is in PRK. Blasts could be generated in complicated CXL cases with atypical wound healing and result in more severe and persistent haze generation.

Ongoing Flattening and Thinning

A significant and ongoing flattening and thinning after CXL is a rare postoperative remodeling effect. Although recognized as an early positive side effect, when the flattening is too intense, resulting in more than 10 D and associated with thinning, it may have direct implications for the predictability of the procedure and its safety. It may also suggest the necessity of a patient-specific approach and a better understanding of the actual mechanism. It is a combination of preoperative, perioperative, and postoperative characteristics that will enable an excessive flattening in specific cases. Features inherent in advanced stage disease combined with the UVA irradiation intensity and the riboflavin carrier allow greater CXL photochemical action, which, in some instances, will lead to a more critical wound healing process, a higher effect in increasing corneal strength, and subsequently a more comprehensive remodeling, topographically represented as severe flattening. When investigating through differential maps, it seems more like an intense remodeling effect that associates areas of intense flattening with some localized mild steepening.

References

1. Santhiago MR, Giacomini NT, Medeiros CS, Smadja D, Bechara SJ. Intense early flattening after corneal collagen cross-linking. *J Refract Surg*. 2015; 31:419-422.
2. Santhiago MR. Accelerated corneal cross-linking: we must acquire knowledge as fast. *J Refract Surg*. 2016; 32:362-363.
3. Wilson SE, Medeiros CS, Santhiago MR. Pathophysiology of corneal scarring in persistent epithelial defects after PRK and other corneal injuries. *J Refract Surg*. 2018; 34:59-64.
4. Ghanem RC, Netto MV, Ghanem VC, Santhiago MR, Wilson SE. Peripheral sterile corneal ring infiltrate after riboflavin-UVA collagen cross-linking in keratoconus. *Cornea* 2012; 31:702-705.
5. Randleman JB, Santhiago MR, Kymionis GD, Hafezi F. Corneal cross-linking (CXL): standardizing terminology and protocol nomenclature. *J Refract Surg*. 2017; 33:727-729.
6. Armstrong BK, Lin MP, Ford MR, Santhiago MR, et al. Biological and biomechanical responses to traditional epithelium-off and transepithelial riboflavin-UVA CXL techniques in rabbits. *J Refract Surg*. 2013; 29:332-341.

Prevention and Identification of Post-LASIK Ectasia

William Trattler MD

One of the key parts to the preoperative evaluation for LASIK is determining whether a patient has an increased risk for post-LASIK ectasia. Over the past two decades, significant work has been performed in this area. However, even today, there can be considerable subjectivity in determining whether a patient is at an increased risk for ectasia after laser vision correction. Even “experts” often disagree, despite the extensive work that has been performed in this area. On the positive note, if keratoconus develops, crosslinking can be performed and can prevent the condition from progressing.

Two points are important points here:

1. Patients who do not have LASIK (or any corneal procedure) can develop keratoconus in the future. While a solid percentage of patients develop keratoconus in their teens, many patients present with keratoconus in their twenties and thirties.
2. Patients without any risk factors can develop keratoconus after LASIK.

With these two points in mind, it is important to point out that the development of keratoconus in a patient who has previously undergone laser vision correction does not mean that the corneal refractive procedure was the cause of the development of keratoconus.

Of course, experts agree that there are a few potential risk factors:

- Mild to moderate keratoconus is a risk factor for ectasia (or worsening keratoconus) after LASIK. Rather than PRK or LASIK, patients with keratoconus can benefit from crosslinking. In the future (following crosslinking), these patients may become candidates for laser vision correction (PRK).
- Age appears to be a mild risk factor. Younger patients have a slightly higher risk of developing keratoconus after LASIK than older patients. However, 60+-year-old patients can develop keratoconus following LASIK, so older patients still need to be screened for visible risk factors on topography / tomography.

- The development of keratoconus after laser vision correction appears to be significantly lower with PRK than with LASIK. In borderline cases, surgeons often will perform PRK rather than LASIK.
- The residual stromal bed limit is 250 microns. Many surgeons are more conservative and target a residual stromal bed well above 250 microns.
- The percentage tissue altered (TPA) has been proposed as a potential limit for LASIK (LASIK flap thickness plus ablation depth less than 40% of the total corneal thickness). Other experts do not agree with this criteria.
- Early keratoconus (forme fruste keratoconus, FFKC) is a risk factor for ectasia after LASIK. Note: The risk of a patient with FFKC developing ectasia (keratoconus) after PRK is low, especially in patients who are older, have thick corneas, mild refractive errors, and good BCVA.

Screening for Keratoconus After LASIK or PRK

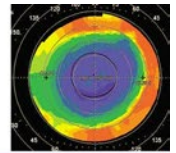
Patients often follow up on an annual basis after LASIK. Performing topography or tomography annually will help establish a baseline as well as allowing surgeons to identify changes in the future that may signify early post-LASIK ectasia.

For example, in Figure 1, a patient with ectasia in her right eye has slowly developed changes in her corneal shape over 5 years, which is consistent with early post-LASIK ectasia, despite maintaining 20/20 UCVA.

Annual topography or tomography screening can help identify patients who develop ectasia at an early timepoint. If identified, patients can be scheduled for crosslinking, which will prevent further progression of their condition.

History of previous LASIK

Seen in 2013 for exam



Example of Myopic LASIK
Round central Optical Zone

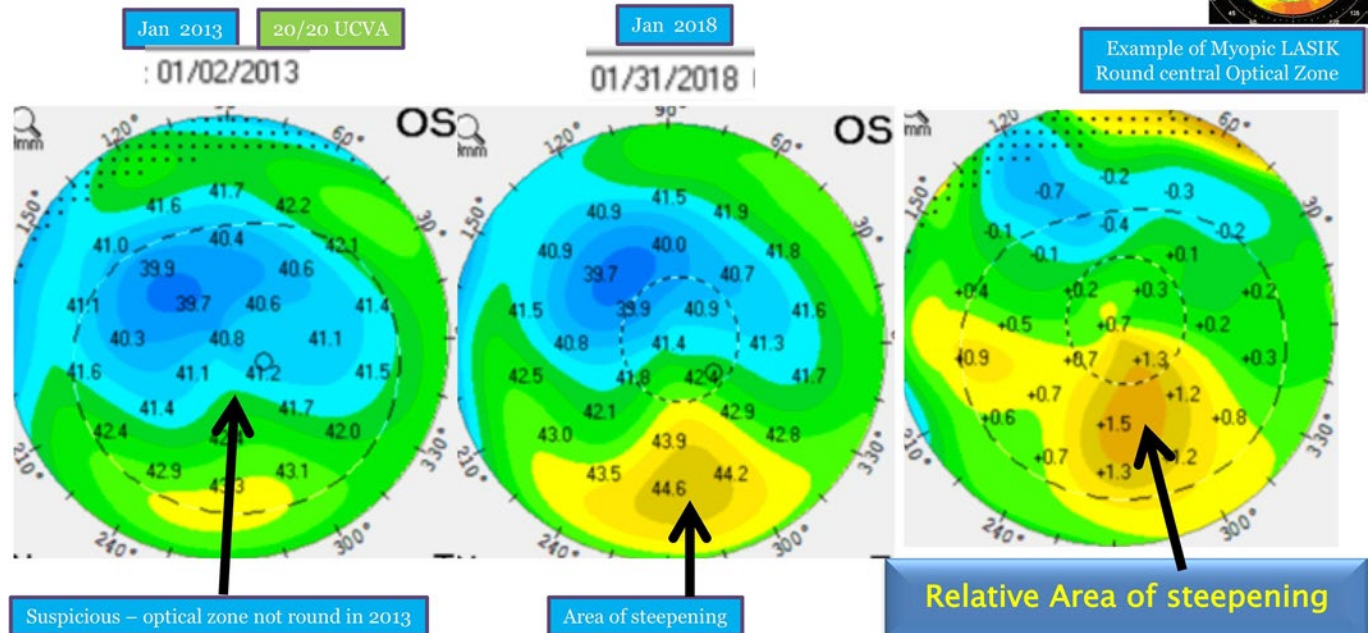


Figure 1.

Summary

Screening prior to LASIK or PRK is a critical part of the preoperative exam. However, even patients without risk factors can develop keratoconus after LASIK or PRK. Therefore, annual screening with topography or tomography after LASIK can help identify patients early on, so that crosslinking can be performed prior to significant loss of vision.

Managing the Dissatisfied Refractive Surgery Patient

Vance Thompson MD

This all matters for cataract and refractive patients.

- Key to the success of a practice
- Need to manage expectations
- When patients pay cash, expectations go up.
- Their expectations are your reality.
- Do the right things right.
 - Tear film
 - Topography
 - High-order aberrations
 - Retina
 - General eye health
- Special considerations for presbyopes
 - Understand the distance they spend the majority of their time.
 - Contact lens testing is very helpful.
 - If lens-based surgery, remember, a 60-year-old may have some accommodation (including pseudo-), and a monofocal implant may be a surprise as far as loss of near.
- The patient experience becomes even more important with unhappy patients.
- Be a good listener.
- Your team will help you if you let them. (What did they learn during the workup?)
- Track your patient satisfaction data.
 - Share with your team.
 - You may discover from your practice's patient questionnaires that patients think you are not spending enough time with them or answering all of their questions.
 - When you learn this, you can do something about it ... but you may only learn this if you are purposeful about tracking your data (and actually reading it :o) and sharing it with your team.
- A caring, confident doctor (and staff):
 - Doesn't panic
 - Stays calm
 - Can say "I am sorry" without feeling they are admitting anything wrong was done.
 - Takes the time necessary.
 - Works together.
- Not reaching the refractive goal of the patient is one of the most common causes of patient dissatisfaction in both refractive and cataract surgery. Be willing to enhance or refer for enhancement.
- Remember: "50%-80% of the information provided by the clinician is instantly forgotten. Of the balance of information that is remembered, only 50% is remembered correctly."
- Remind your staff of this, too.
 - Be patient when you need to repeat things that you know they were told multiple times.
- I have never improved a situation by allowing my temperament into an unreasonable patient conversation.
- I have improved many situations by being parental to a patient who is being childish.
- We are dealing with an aging population, and that brings unique sensitivities to these situations.
- Working on your team culture and having a well-educated and happy team does wonders for patient joy.
- Repeat: When patients are spending their hard-earned dollars above and beyond what their insurance paid they get more sensitive and expectations go up.
- When you have done your job in every way—understanding neural adaptation
- Managing the dissatisfied refractive or cataract surgery patient is a key to practice success.

Thank you.

Refining IOL Power After Cataract Surgery: Perfect Lens and Light Adjustable IOL

Nick Mamalis MD

NOTES

[illegible]

Centration of a Multifocal IOL

Cataract Surgery to Achieve Exceptional Refractive Outcomes

William J Fishkind MD FACS

- I. Normal Eye
 - A. Angle kappa
 - B. Capsular bag along optical axis
 - C. Pupil 3° to 5° nasal
 - D. Multifocal rings should align with pupil. If not, possible glare complaint.
 - E. Average decentration
 - F. Continuous curvilinear capsulorrhexis
 - G. In-the-bag IOL placement
 - H. 0.1 to 0.3 mm
- II. Effect of Negative Spherical Aberration (SA) IOL Decentration
- III. Decentration and Tilt
 - A. Holladay, Piers, et al. *J Refract Surg.*, 2002.
 1. Tilt: $\leq 7^\circ$
 2. Decentration: ≤ 0.4 mm
 - B. IOL with negative SA will lose advantage of improved performance measured by modulation-transfer function (MTF).
 - C. Piers, *J Refract Surg.*, 2007.
 1. Tilt: $\leq 10^\circ$
 2. Decentration: ≤ 0.8 mm
- IV. IOL With Negative SA

Will lose advantage of improved performance measured by MTF
- V. Toric Rotation
 - A. Toric power decrease
 - B. 10% for every 3 degrees
 - C. At 30 degrees, no toric power
 - D. At 90 degrees, the cylinder is doubled.
- VI. IOL Centration With Intraoperative Aberrometry
- VIII. Argon Laser Iridoplasty
 - A. ReSTOR multifocal IOL (MIOL) not properly aligned with pupil
 - B. Reduced quality of vision
 - C. Asymmetric halos
 - D. Glare
 - E. Topical anesthetic
 - F. No contact lens
 - G. Four laser spots
 1. 500-mw power
 2. 500-ms duration
 3. 500- μ m spot diameter
 4. Placed midperiphery of iris where pupil encroaches on IOL
 - H. Pupil now symmetric
 - I. Patient relieved of symptoms
- VIII. IOL Centration With Purkinje Images
- IX. Remove and Replace
- X. Early/Late Decentration
 - A. Capsular bag status
 1. Intact
 2. Intact with zonular dehiscence
 - B. Torn
 1. Torn anterior capsule
 2. Torn posterior capsule
 - C. IOL Type
 1. One piece
 2. Three piece
 3. Crystalens
- XI. Decentered MIOL Capsular Bag Intact Early or Late
 - A. Able to open capsular bag; remove and replace
 - B. Poor zonules: insert appropriate ring
 1. Capsular tension ring (CTR)
 2. Cionni
 3. Ahmed ring segment
- XII. Unable to Open Capsular Bag
 - A. If possible: amputate haptics, remove and replace. New IOL in sulcus.
 - B. Three-piece: suture IOL to iris or sulcus
 - C. One-piece: suture IOL to sulcus

XIII. Decentered MIOL Capsular Bag Torn Early or Late

- A. Anterior capsule torn / posterior capsule torn
- B. Able to open bag, remove and replace
 - 1. In bag with proper orientation
 - 2. In sulcus with appropriate power selection
- C. CRT dependent upon zonular status
- D. Anterior capsule torn / posterior capsule torn
- E. Unable to open bag
- F. One-piece
 - 1. Amputate haptics
 - 2. Remove optic

G. Three-piece

- 1. Spin IOL into AC
- 2. Suture to iris or sulcus
- 3. Yamani

H. Crystalens: Remove and replace with iris or sulcus fixation

XIV. Multifocal Centration

XV. Centering the MIOL

Mastering the Glued IOL Technique

Thomas A Oetting MD

History

- Haptic tucked in scleral tunnel (without use of glue) developed by Gabor Scharioth.¹
- Similar glued technique developed by Amar Agarwal that has evolved over the last 5 years.²⁻⁴

Procedure

Prepare scleral flap

Mark 180 degrees apart (with toric or other marker) usually vertical (12 and 6) but could also go oblique or horizontal. Use vertical in larger eyes, as this dimension is typically shorter and the IOL might not be big enough for a longer horizontal position. Make peritomy about 2 clock hours wide, centered on each of the 2 marks. Prepare the scleral flaps by making 1/3 to 1/2 scleral thickness, limbal-based scleral flaps, about 2-3 mm wide, extending about 3.0 mm posterior and centered on the marks 180 degrees apart. I like to use a 300-micron disposable steel guarded blade (Sharpoint 72-0303) to start the flap, then crescent blade to finish.

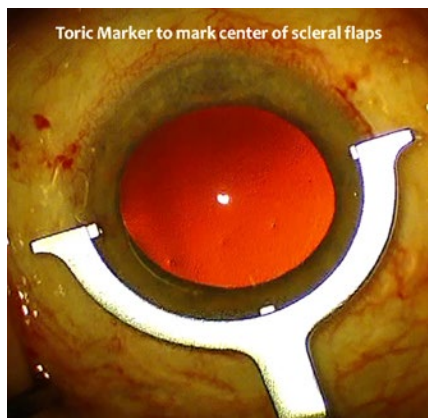


Figure 1. Toric marker to mark center of scleral flaps.

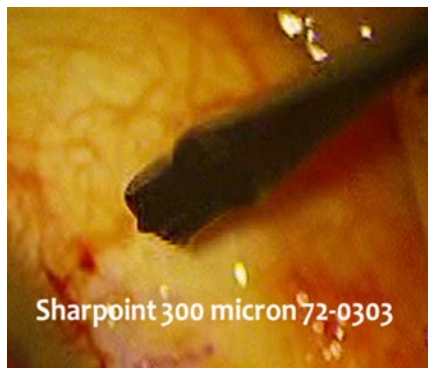

Figure 2. Sharpoint 300-micron 72-0303.

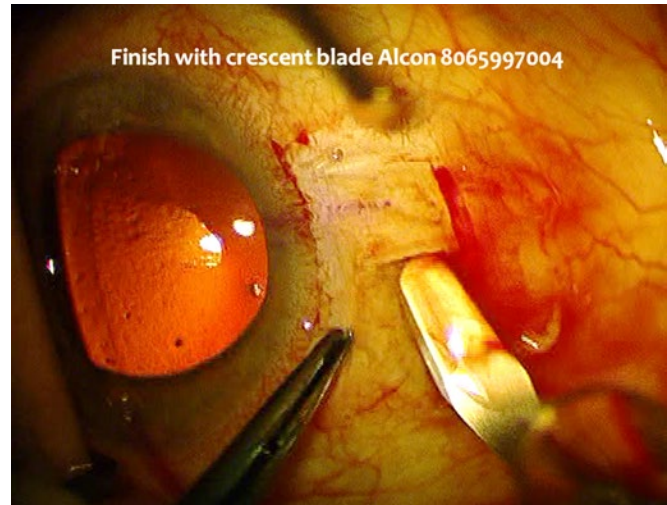

Figure 3. Finish with crescent blade (Alcon 8065997004).

Place AC Maintainer

I like to use a Lewicky anterior chamber (AC) maintainer through paracentesis away from the action. You could also use a pars plana infusion cannula. Believe me (based on a tough case I had), it is critical to use the maintainer as the eye will be too soft to manage the tricky intraocular manipulations required without infused fluid keeping the eye formed.

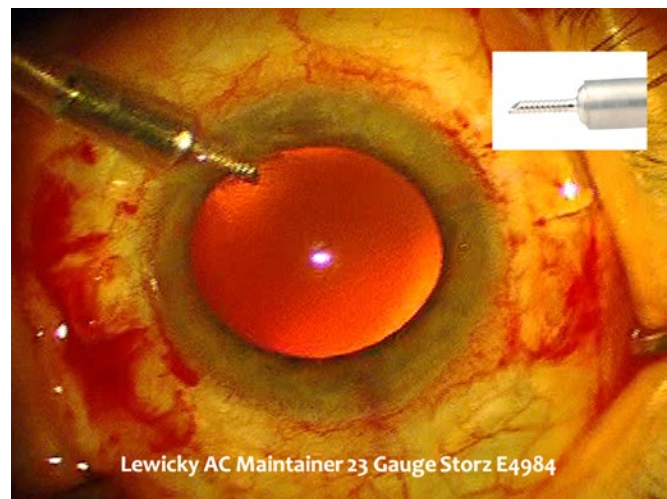


Figure 4. Lewicky anterior chamber maintainer, 23-gauge (Storz E4984).

Make Sclerostomies and Tuck Tunnels

Place the sclerostomies under the 2 scleral flaps. These have to be large enough for the forceps that will retract the haptics. I typically use yellow Alcon Sideport blade (8065921540), but one could use a 23-gauge MVR blade or 20-gauge needle. I use a Duet microforceps, which will easily pass through the 1-mm sclerostomy. Start the sclerostomy incision 1.0-1.5 mm posterior to the limbus, under the flap, so that the knife or needle passes just under the iris in the area of the sulcus. As the limbus is often hard to define and as these eyes have often already had surgery or trauma, which can further make identifying the limbus difficult, I often use the iris as an important guide to the starting point of the sclerostomy. Perform anterior vitrectomy using sclerostomy.

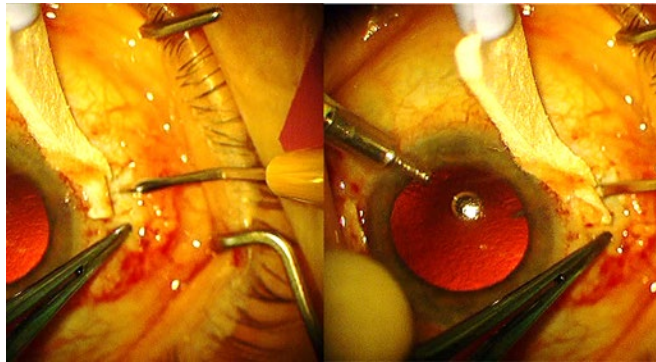


Figure 5.

Make the scleral tunnels where you will tuck the haptics, adjacent to the sclerotomy sites and off the bed of the scleral flap, using the sideport blade or a 26-gauge needle. I will often mark this with ink to make it easier to find in the heat of the battle.

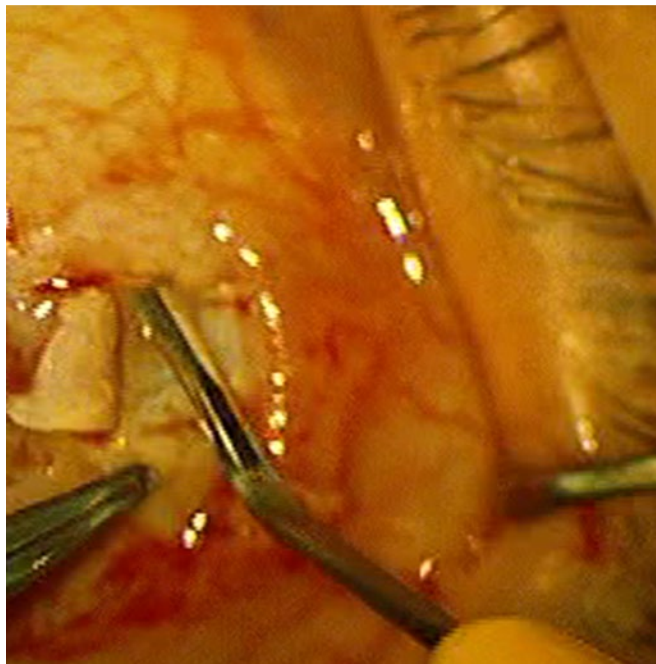


Figure 6.

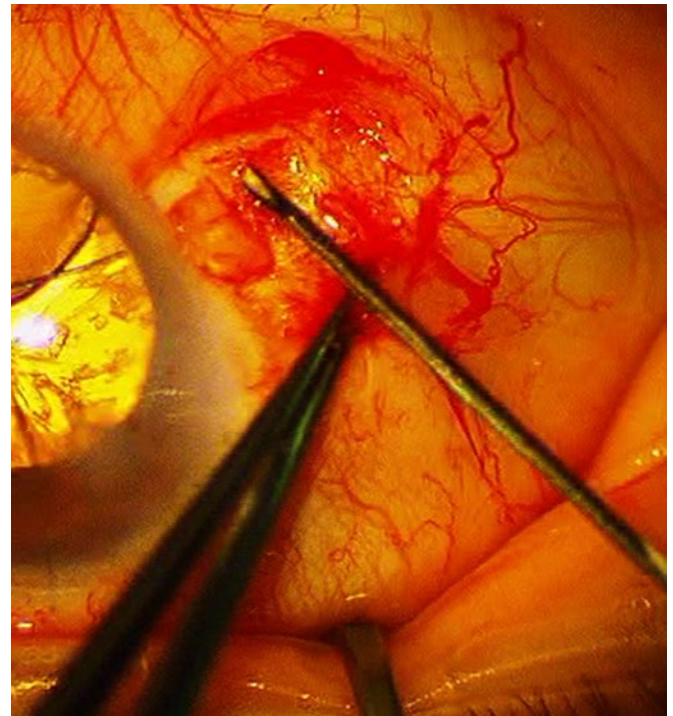


Figure 7.

Inject IOL

Place a 3- or 3.5-mm corneal incision to allow for the injection of a 3-piece foldable IOL. I typically use an Alcon MA50 with the Monarch B cartridge. I would avoid a silicon IOL in these patients that might need pars plana vitrectomy in the future. Dr. Agarwal has described the use of all polymethylmethacrylate (PMMA) for this procedure, but they are brittle and I wonder if they are more likely to erode through the sclera in the long term. The leading IOL haptic is introduced into the AC with the cartridge. A microforceps (eg, Duet) is then introduced through 1 sclerostomy site to grasp the haptic as it enters the eye. Completely inject the IOL into the eye while holding the haptic in the AC with the microforceps. Then, when the IOL optic is right-side up in the AC and the trailing haptic is left safely outside the eye, externalize the leading haptic by pulling it out through the sclerostomy. Place one of your microforceps through the other sclerostomy site and grasp and externalize the trailing haptic using the handshake technique.

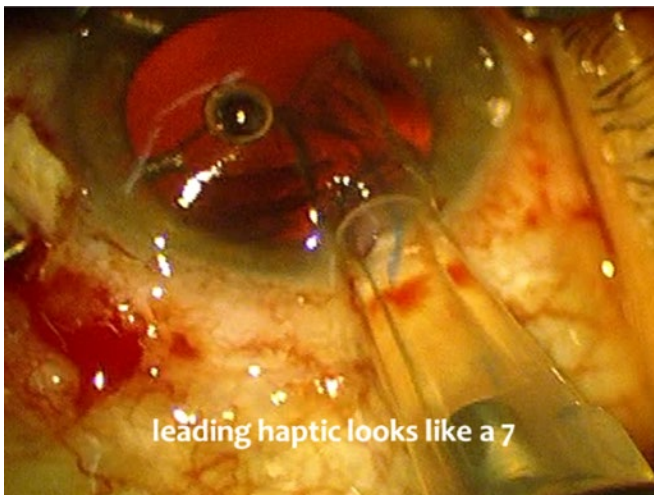


Figure 8. Leading haptic looks like a 7.

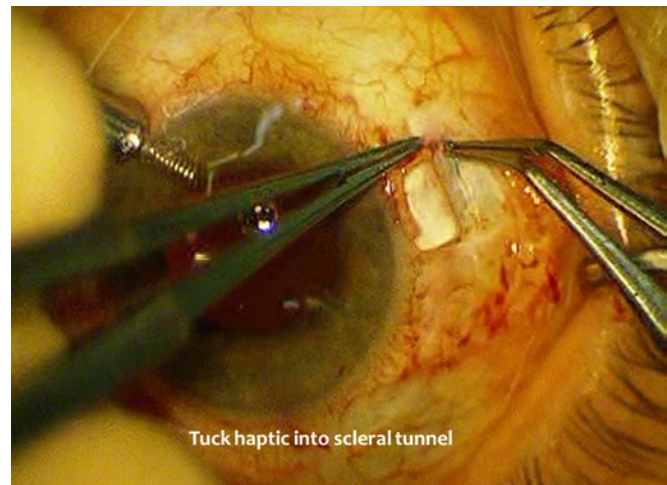


Figure 10. Tuck haptic into scleral tunnel.

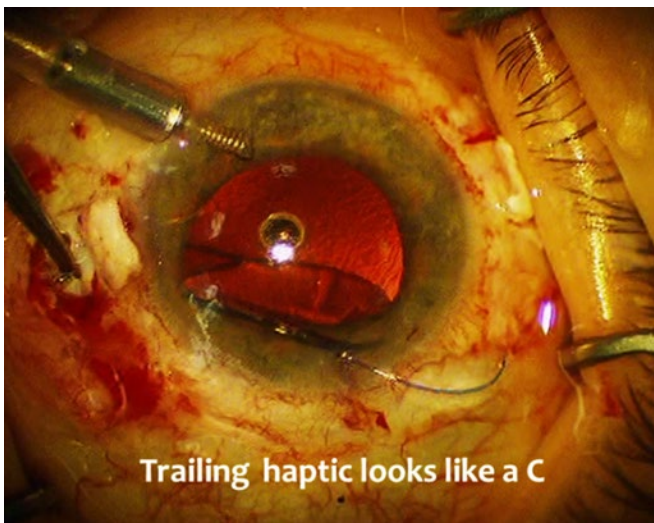

Figure 9. Trailing haptic looks like a C.

Secure IOL in Scleral Tuck Tunnels

Deliver IOL haptics into the side-tuck tunnels fashioned earlier (often marked). These side tunnels are sometimes hard to find and can be marked with ink to find more easily later. Center the IOL by tucking the haptic the same amount on both sides. If the IOL does not center, it is often because the sclerostomy sites were not 180° across from each other.

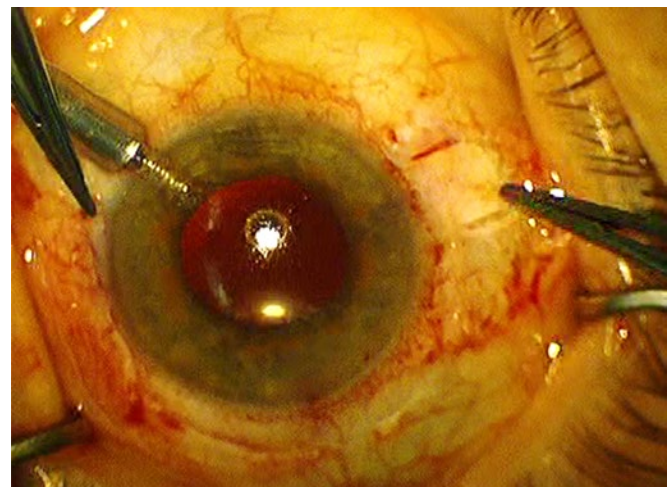


Figure 11.

Advantages

- Small, self-sealing incision using a foldable IOL, which lessens risk of iris prolapse, choroidal hemorrhage, effusion, and astigmatism
- Better IOL centration than scleral-sutured IOL (sclerostomies 180° across from each other)
- Possibly longer term stability than scleral-sutured IOL as it avoids iris prolapse; but not clearly better than sutured iris or AC IOL⁴

Disadvantages

- Almost a two-surgeon job. You need three hands to inject the IOL, so the scrub tech or a second surgeon needs to help. Need skilled help to hold one haptic while surgeon uses two hands to place the other haptic.
- Requires use of the handshake technique where 2 micro-graspers are used within the eye, which can be tricky and requires special instrumentation.
- Requires the use of fibrin sealant for scleral flaps and conjunctiva.

Complications

Complications are similar to scleral-sutured IOL and include³ hyphema, vitreous hemorrhage, decentration, optic capture, haptic disinsertion, and hypotony. Over time, haptics may erode through scleral flaps. Of course the surgeon must keep in mind that eyes that require this procedure are already in trouble and prone to glaucoma and corneal decompensation.

References

1. Gabor Scharioth, Pavlidis MM. Sutureless intrascleral posterior chamber intraocular lens fixation. *J Cataract Refract Surg.* 2007; 33(11):1851-1854.
2. Agarwal A, et al. Fibrin glue-assisted sutureless posterior chamber intraocular lens implantation in eyes with deficient posterior capsules. *J Cataract Refract Surg.* 2008; 34(9):1433-1438.
3. Kumar DA, Agarwal A, et al. Glued posterior chamber IOL in eyes with deficient capsular support: a retrospective analysis of 1-year post-operative outcomes. *Eye (Lond).* 2010; 24(7):1143-1148.
4. Holt DG, Young J, Stagg B, Ambati BK. Anterior chamber intraocular lens, sutured posterior chamber intraocular lens, or glued intraocular lens: where do we stand? *Curr Opin Ophthalmol.* 2012; 23(1):62-67.

Single-Pass Four-Throw Pupilloplasty

Amar Agarwal MD

Introduction

Single-pass four-throw (SFT) pupilloplasty technique¹⁻¹⁵ involves a single pass in the anterior chamber followed by 4 throws taken through the loop that is withdrawn from the anterior chamber. The procedure comprises the approximation loop with no securing loop taken to ensure a traditional knot formation. It works on the principle of creating a helical configuration by intertwining the loop that has a self-locking and a self-retaining mechanism. SFT technique creates a helical configuration that prevents it from opening up.

The SFT technique is applicable in all cases that require a pupil reconstruction following a traumatic or cosmetic disfigurement of the pupil architecture. The technique also has varied applications in other procedures like pre-Descemet endothelial keratoplasty or any endothelial keratoplasty procedure, Urrets-Zavalía syndrome, and in selected cases of angle-closure glaucoma.

SFT Pupilloplasty

Pupil reconstruction is essential to preventing photophobia and filtering the amount of light and is especially needed in cases with traumatic mydriasis and atonic pupils. Surgical repair is of substantial benefit as it has the potential to reduce visual glare and light sensitivity. Among various techniques¹⁻⁹ that have been described for pupil reconstruction, SFT is one of the newer techniques that can be employed for pupilloplasty.¹⁰ As the name suggests, a single pass of the Prolene 10-0 suture on a long-arm needle is passed through the iris tissue, followed by creation of a loop with 4 throws around it that slides inside the eye like a Siepser sliding knot technique. This creates a helical configuration that prevents the suture from opening up. A knot essentially consists of an initial approximating loop followed by a second throw of sutures that creates a securing loop. SFT technique employs the creation of only the initial approximating loop but it is comprised of four throws, thereby creating an intertwining of sutures that has a self-locking mechanism and prevents loosening of the suture loop.

The indications for SFT are vast, ranging from cases with traumatic mydriasis to optic capture and Urrets-Zavalía syndrome,¹¹ cases undergoing endothelial keratoplasty,¹² and in select cases of angle-closure glaucoma with peripheral anterior synechiae.¹³

The following list briefly summarizes the indications for pupilloplasty.

Indications

Pupilloplasty is indicated in the following conditions in symptomatic patients:

- Corneal indications
 - Endothelial keratoplasty like pre-Descemet endothelial keratoplasty, especially in aphakic eyes or those with a deficient posterior capsule, so as to prevent the graft from getting displaced in the posterior segment, and to maintain an adequate anterior chamber for graft unrolling and placement
- Glaucoma related
 - Angle-closure glaucoma
 - Plateau iris syndrome
 - Broad peripheral anterior synechiae
- Pupil-related indications
 - Traumatic mydriasis
 - Urrets-Zavalía syndrome
 - Iatrogenic iridectomies
 - Iris defect (congenital coloboma iris / correctopia / polycoria)
- IOL-related indications
 - Optic capture
 - Glued IOL
 - Prevention of posterior synechiae

Relative Contraindications

- Phakic eyes with clear lens
- Atrophic iris

Surgical Technique

The amount of iris defect should be initially assessed, and an imaginary line drawn from the intended edges of the defect to the limbus. This marks the paracentesis site. Another paracentesis should be made approximately 45° to 90° away (Figure 1A). In cases with traumatic mydriasis / Urrets-Zavalía syndrome / angle-closure glaucoma, pupillary stretching is performed with an end-opening forceps to pull the iris on every clock hour and break any possible synechiae that might be present. This step also helps in giving the immobile iris some elasticity (Figures 1-4).

It is a good practice to begin such surgeries with a trocar anterior chamber maintainer (T-ACM)¹⁴ or an anterior chamber maintainer (ACM), with infusion of fluid in the eye. Alternatively, the surgeon can also perform the procedure with viscoelastic in the anterior chamber (if the posterior capsule is intact). However, the same should be meticulously washed out from within the anterior chamber in order to avoid any postoperative inflammation or an IOP spike postoperatively. In the case of glued IOL or aphakic patients or those with a deficient posterior capsule, the author would refrain from the use of viscoelastic so

as to prevent any viscoelastic from entering the posterior segment. In such cases, a T-ACM / ACM can be used with infusion of BSS in the eye.

With an end-opening forceps introduced through the paracentesis, grasp one edge of the iris defect (Figure 1B). With the other hand, enter the eye using a 9-0 or 10-0 Prolene suture on a straight, long needle through clear cornea and advance the same needle through the iris. At this time, the needle can be released (Figure 1C). Introduce an end-opening forceps through the other paracentesis, and grasp the other edge of the iris defect. Pass a 26-gauge needle through the primary paracentesis, and then pass it through the iris. Now the surgeon can release the iris, and railroad the Prolene suture into the needle and externalize the 10-0 suture needle (Figure 1D, 1E, 1F). At this time, the intraocular Prolene suture can be divided into 3 parts: the distal part, the intermediate part, and the proximal part. Using

a dialer or a Sinsky hook, engage the distal part of the suture and form a loop in the anterior chamber (Figure 2A). Externalize this loop using micrograspers, taking care to maintain the externalized loop immediately outside the paracentesis (Figure 2B, 2C). At this stage, it is important to ensure that neither of the suture parts has crossed over each other.

The leading end of the suture can now be cut. This end is now passed into the loop of the suture 4 times (Figure 2D, 2E). This entails the 4 throws of the SFT technique. Once this is done, pull on both ends of the suture (Figure 2F). The helical knot that is thus formed slides into the eye, and the pupil approximation is achieved (Figure 3A). The microscissors are employed to cut the ends of the suture, making sure the suture ends are neither too short nor too long (Figure 3B, 3C). The SFT procedure (Figure 4) is then repeated in the other quadrant to achieve the suitable and required size of the pupil (Figure 3D).

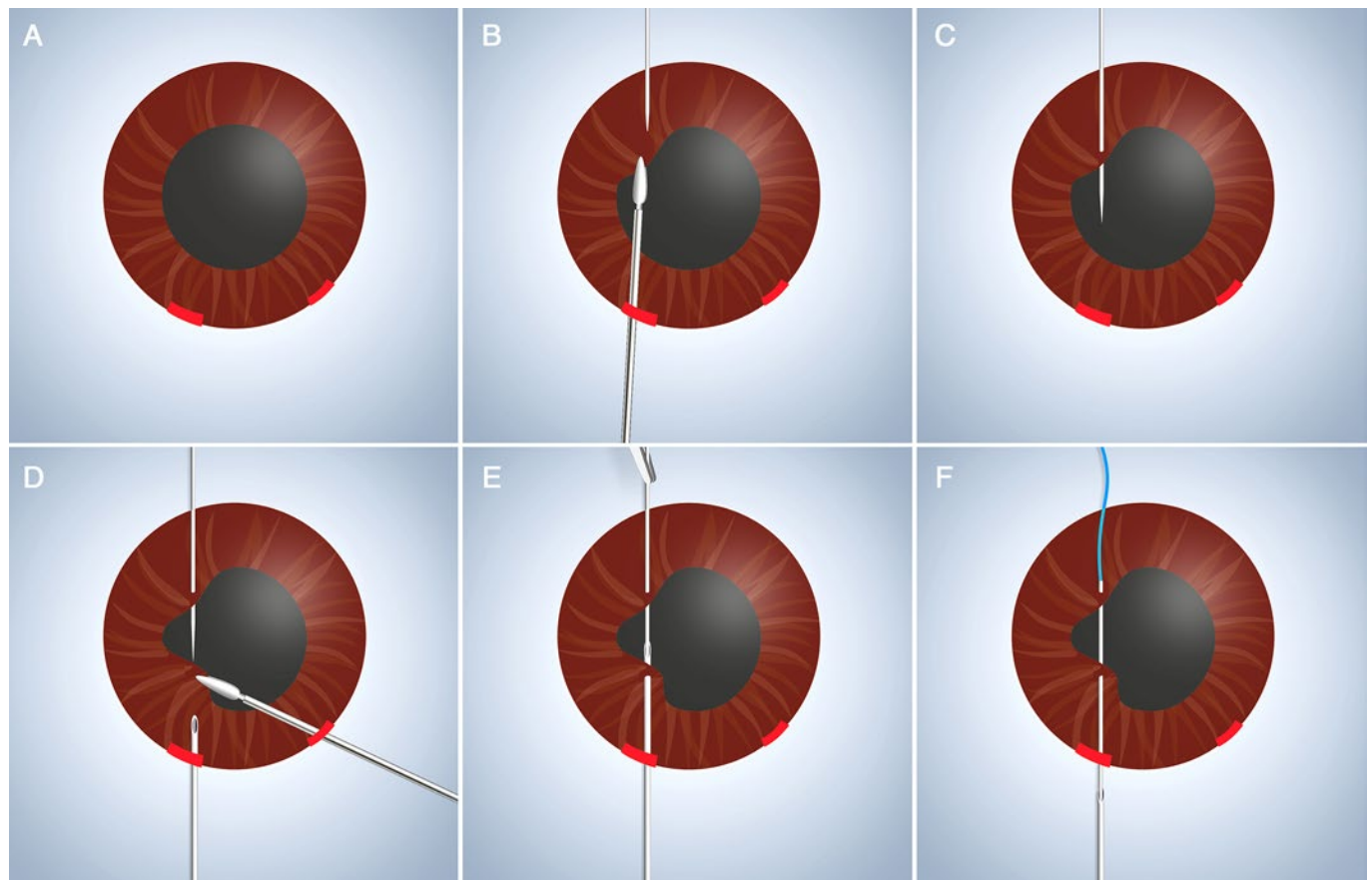


Figure 1. Animated description of single-pass four-throw (SFT) pupilloplasty.

(A) Two paracentesis incisions are framed that serve as the site for introduction of an end-opening forceps and a 26-gauge needle for performing pupilloplasty (paracentesis sites as marked in red). (B) A 10-0 suture attached to the long arm of the needle is passed through the clear cornea. An end-opening forceps is introduced from the opposite end, and the proximal part of the iris tissue that is to be repaired is held with the forceps. This makes the iris taut and facilitates its passage through the iris. (C) The 10-0 needle is passed through the proximal iris tissue. (D) A 26-gauge needle is introduced from the opposite side through the paracentesis incision, and the iris edge is grasped by an end-opening forceps introduced from the adjacent paracentesis incision. (E) The 10-0 needle is docked into the barrel of the 26-gauge needle. (F) The 10-0 needle is pulled and withdrawn from the anterior chamber through the paracentesis incision.

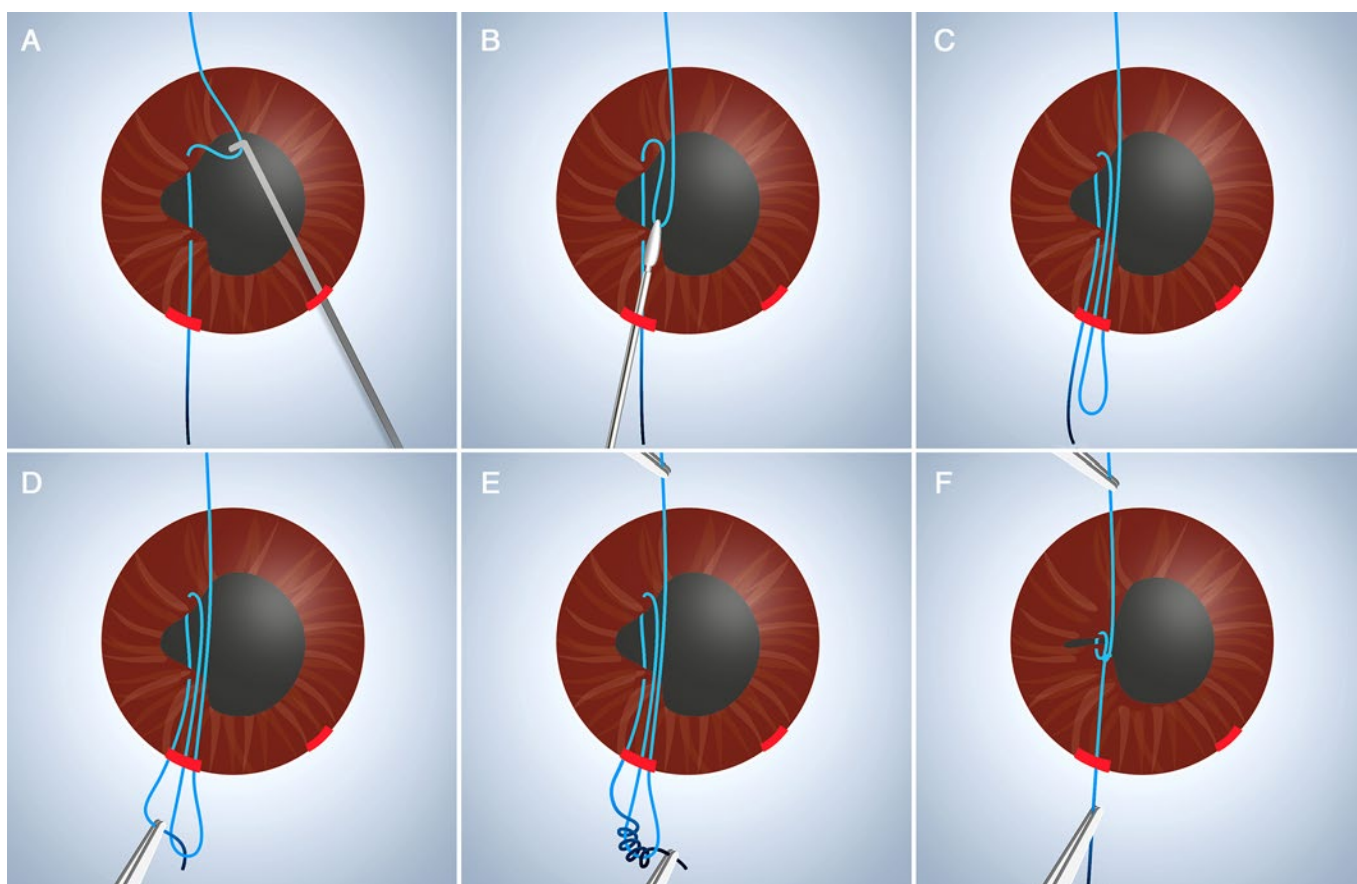


Figure 2. Animated description of single-pass four-throw pupilloplasty.

(A) Using a dialer, form a loop of the distal suture end intraocularly. (B) Using micrograspers / intraocular end-opening forceps, externalize the loop via the paracentesis. (C) Distal suture loop externalized through the paracentesis and maintained immediately outside the paracentesis. (D) The leading end of the suture is passed through the loop. (E) Four throws of the leading end are passed through the loop, with care being taken to pass the suture through the loop in the same direction. (F) Pull both the distal and proximal end of the suture, internalizing the helical knot.

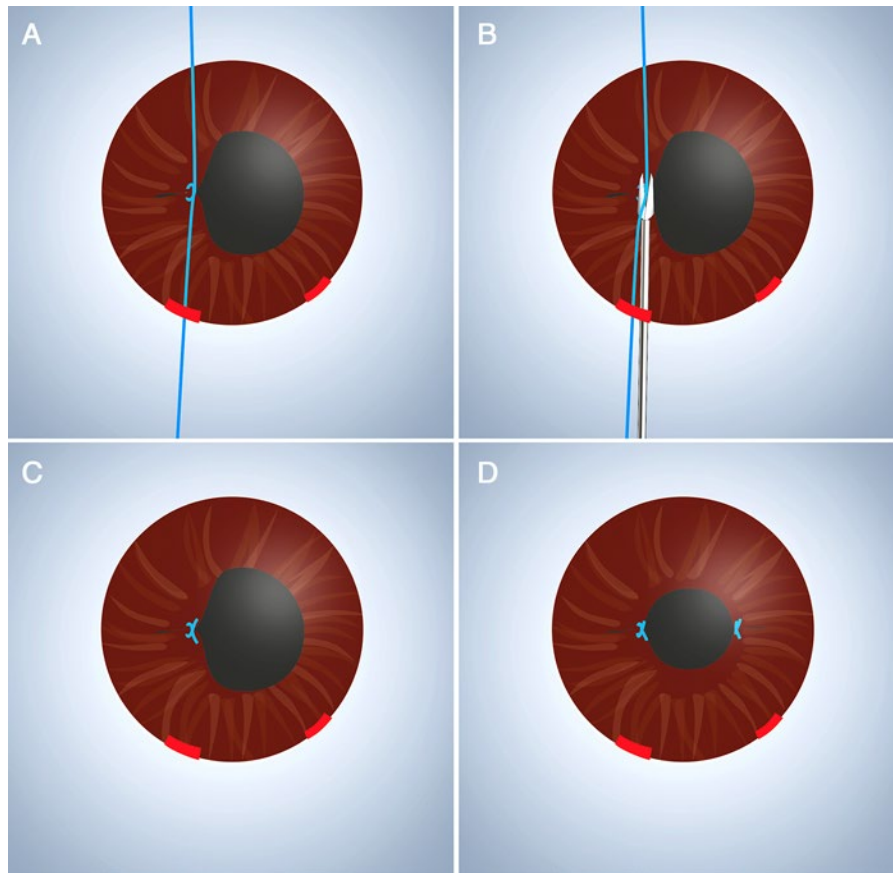


Figure 3. Animated description of single-pass four-throw pupilloplasty. (A) A helical knot is formed. (B) Microscissors are used to cut the ends of the knot. (C) Pupilloplasty is complete on one side. (D) Pupilloplasty is complete on the other side, with resultant desired pupil.

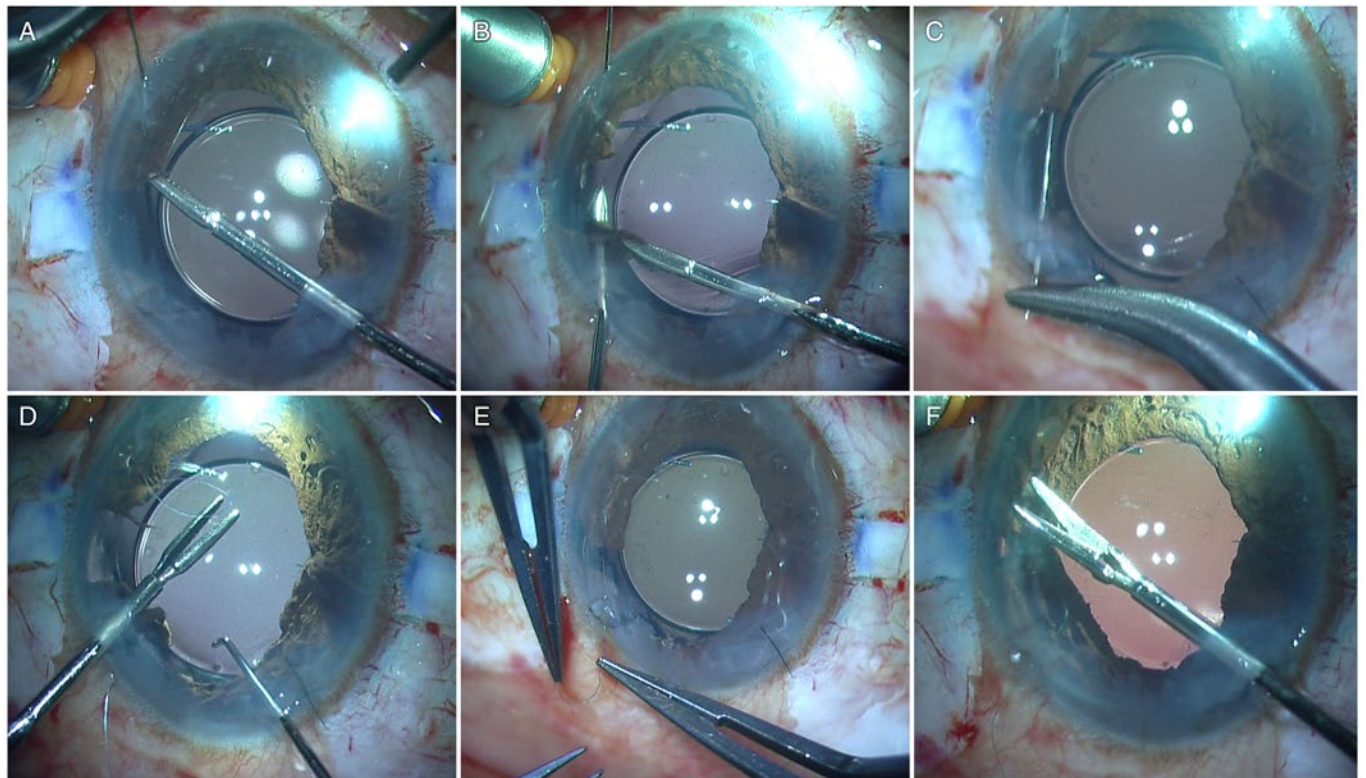


Figure 4. Single-pass four-throw pupilloplasty—surgical technique. (A) The proximal end of the iris leaflet is held with an end-opening forceps, and a 10-0 long-arm needle is passed through it from the side port incision. (B) A 26-gauge needle is passed through the opposite side, and it passes from the distal edge of the iris tissue. (C) The long-arm needle is passed into the barrel of the 26-gauge needle and is pulled out of the eye. (D) A Sinskey hook is passed, and it engages the suture that is pulled inside the anterior chamber, creating a loop. (E) The loop is pulled out, and the suture end is passed 4 times through the loop. (F) Both ends of the suture are pulled, and this leads to the sliding of the loops inside the anterior chamber. After the loops are secured, the suture is cut in a way that leaves 1 mm of end on either side.

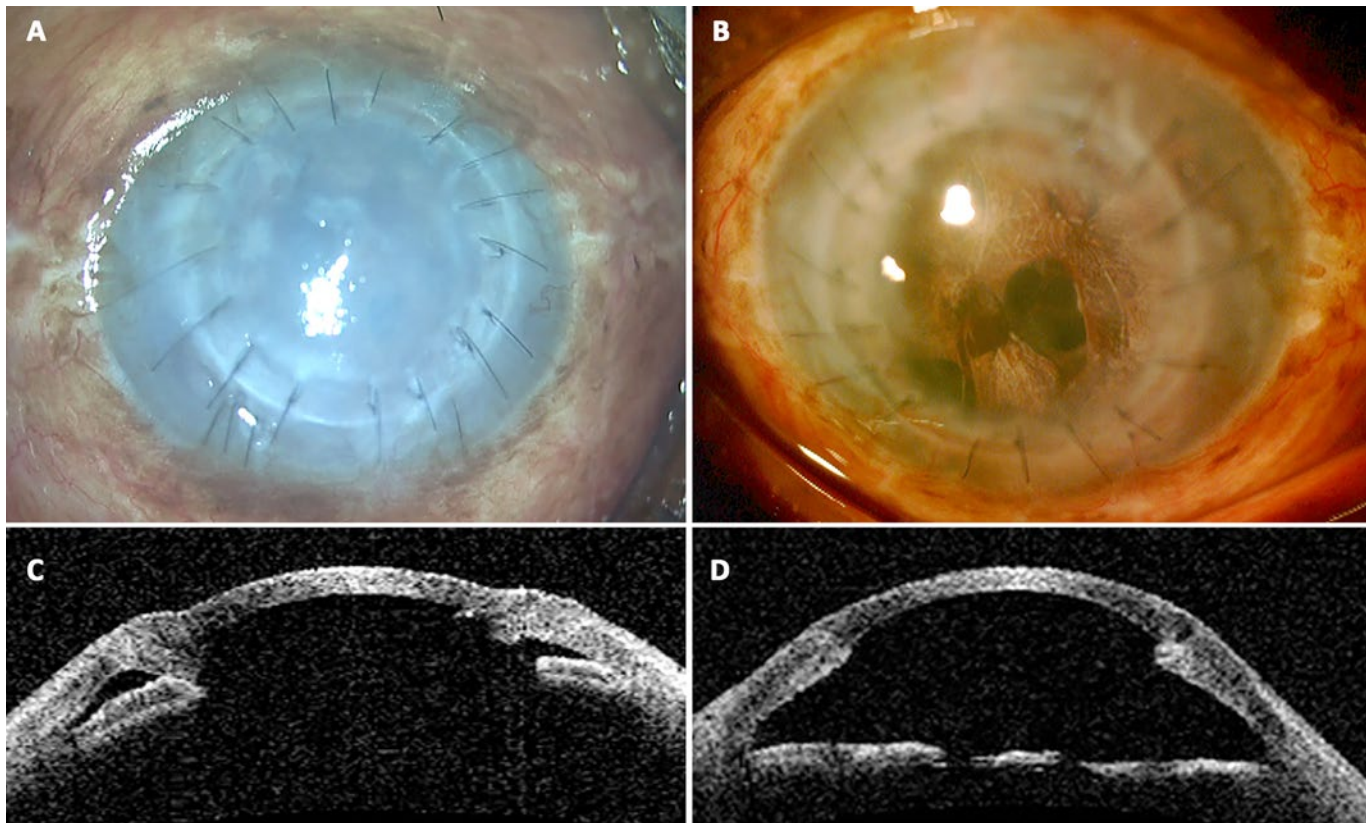


Figure 5. Single-pass four-throw (SFT) with pre-Descemet endothelial keratoplasty (PDEK) in failed penetrating keratoplasty in a one-eyed patient. (A) Failed graft of penetrating keratoplasty (one-eyed patient). (B) Postoperative image following SFT with PDEK. (C) Preoperative anterior segment OCT (AS-OCT) image. Note the closed angle. (D) Postoperative AS-OCT image demonstrating pupil reconstruction with decreased thickness of cornea due to resolution of edema. Note the open angle due to the SFT.

SFT for Pre-Descemet Endothelial Keratoplasty (PDEK)

The endothelial keratoplasty (EK) procedure involves the supplantation of the endothelial cell layer along with the Descemet membrane which may or may not be supported with the layer of stroma in the donor graft. An important consideration during the EK procedure is to prevent and minimize the loss of endothelial cells during the process of donor tissue preparation and also while inserting and repositioning the graft in the anterior chamber (AC). A pupilloplasty procedure is often performed to prevent the escape of air into the vitreous cavity, for maintaining the effective air tamponade in the AC, and also to prevent the posterior dislocation of the graft. The technical manipulation of graft unfolding is mainly performed in the central portion of the AC, where the knots of the pupilloplasty procedure are present, and for this reason Schoenberg and Price⁹ presented a pupilloplasty technique that is especially helpful in cases of EK with the knot directed toward the posterior aspect of the iris tissue in order to prevent the mechanical rubbing of the knot with the donor graft.

The SFT pupilloplasty procedure has been successfully employed in cases that underwent pre-Descemet EK (PDEK; Figure 5). The suture ends when trimmed are essentially parallel to the surface of the iris and do not protrude into the AC. Hence the chances of the knot rubbing onto the endothelial cells of the donor graft are negligible. Anterior segment OCT (AS-OCT) analysis done with the images taken at the level of the iris dem-

onstrated an elevation of around 136-160 μm in the longitudinal meridian and 160-175 μm in the cross-sectional meridian from the adjoining iris plane.¹² Thus the authors conceptualize that the SFT procedure has a definite role in cases undergoing EK, with virtually no damage from the knot of the suture that potentially lies parallel to the iris tissue.

References

1. Siepser SB. The closed-chamber slipping suture technique for iris repair. *Ann Ophthalmol*. 1994; 26:71-72.
2. Osher RH, Snyder ME, Cionni RJ. Modification of the Siepser slipknot technique. *J Cataract Refract Surg*. 2005; 31:1098-1100.
3. Snyder ME, Osher RH. Techniques and principles of surgical management of the traumatic cataract. In: Steinert RF, ed. *Cataract Surgery: Techniques, Complications and Management*, 2nd ed. Philadelphia: Saunders; 2004:331-329.
4. Chang DF. Siepser slipknot for McCannel iris-suture fixation of subluxated intraocular lenses. *J Cataract Refract Surg*. 2004; 30:1170-1176.
5. McCannel MA. A retrieval suture idea for anterior uveal problems. *Ophthalmic Surg*. 1976; 7:98-103.
6. Ogawa GSH. The iris cerclage suture for permanent mydriasis: a running suture technique. *Ophthalmic Surg Lasers*. 1998; 29:1001-1009.

7. Boxer Wachler BS, Krueger RR. Double-armed McCannel suture for repair of traumatic iridodialysis. *Am J Ophthalmol.* 1996; 122:109-110.
8. Kaufman SC, Insler MS. Surgical repair of a traumatic iridodialysis. *Ophthalmic Surg Lasers.* 1996; 27:963-966.
9. Schoenberg ED, Price FW Jr. Modification of Siepser sliding suture technique for iris repair and endothelial keratoplasty. *J Cataract Refract Surg.* 2014; 40:705-708.
10. Narang P, Agarwal A. Single-pass four-throw technique for pupilloplasty. *Eur J Ophthalmol.* 2017; 27:506-508.
11. Narang P, Agarwal A. Single pass four-throw pupilloplasty for Urrets-Zavalía syndrome. *Eur J Ophthalmol.* Epub ahead of print 2018 Mar 1. doi: 10.1177/1120672117747038.
12. Narang P, Agarwal A, Kumar DA. Single pass 4-throw pupilloplasty for endothelial keratoplasty. *Cornea* 2017; 36:1580-1583.
13. Narang P, Agarwal A, Kumar DA. Single pass four-throw pupilloplasty (SFT) for angle closure glaucoma. *Indian J Ophthalmol.* 2018; 66(1):120-124.
14. Agarwal A, Narang P, Kumar DA, Agarwal A. Trocar anterior chamber maintainer: improvised infusion technique. *J Cataract Refract Surg.* 2016; 42(2):185-189.
15. Kumar DA, Agarwal A, Srinivasan M, Narendrakumar J, Mohanavelu A, Krishnakumar A. Single pass four throw (SFT) pupilloplasty: postoperative mydriasis and fundus visibility in pseudophakic eyes. *J Cataract Refract Surg.* 2017; 43(10):1307-1312.

Explantation of an EDOF IOL

David F Chang MD

NOTES

Pre-Descemet Endothelial Keratoplasty

Ahad Mahootchi MD

The evolution of endothelial keratoplasty (EK) has moved toward thinner tissue. That trend has yielded smaller incision size, less rejection, less steroid use, and small improvements in BCVA.

There were obvious advantages of Descemet-stripping automated EK (DSAEK) over full-thickness penetrating keratoplasty (PK):

- A smaller wound size
- Predictable refractive result
- Faster visual recovery
- Less chance of rejection

Descemet membrane EK (DMEK) sought to improve on that, but there is a learning curve for the transition from DSAEK to DMEK as the tissue unfolding is quite different and the ideal anterior chamber characteristics are different.

Pre-Descemet EK (PDEK) is an evolution of DMEK. It basically is DMEK tissue (endothelium+ Descemet membrane) with the addition of the Dua layer (20 microns).

Harvesting your own tissue is possible but made unnecessary with easy eye bank preparation of tissue (precut, preloaded, prestamped, and preverified that the endothelium has survived processing). It fits through a 2-mm incision so it is very astigmatically neutral and friendly to prior premium IOLs.

Why PDEK? It takes the best of DMEK and DSAEK, reducing the disadvantages of both.

Advantages of DSAEK

- Easier to unfold than DMEK initially
- Works in deep chamber
- Very good BCSA
- 15% rejection rate
- Less steroid dependence than PK

Advantages of DMEK

- Smaller incision
- Slightly better BCSA
- 1%-2% rejection rate
- Even less intense and less long steroid use

Disadvantages of DSAEK

- Needs larger incision
- More need to consider glaucoma

Disadvantages of DMEK

- Needs older (>70 y/o) donor—tough to unfold if donor is young (under 70)
- Steeper learning curve
- Hard (if not impossible) to use with prior vitrectomy; chamber flattening can be impossible if prior vitrectomy.
- Chamber flattening can make vitreous come forward if prior YAG.

Advantages of PDEK

- PDEK shortens the learning curve toward thinner tissue.
- Stiffer tissue is easier to unscroll than with DMEK yet still fits though a 2-mm incision.
- The chamber doesn't have to be flattened as in DMEK.
- PDEK tissue can be used in vitrectomized eyes, open capsule—ie, chambers you don't want to and often can't shallow.
- PDEK expands pool of donors—younger donors are possible.
- Same fast visual recovery as both DMEK and DSAEK.

PDEK Disadvantages

- Smaller graft diameter (7.0 to 7.5 diameter)
- Not all eye banks offer it.
- Takes more skill on part of the eye bank staff
- Not as many current users for data and long-term studies

LASIK Nightmares

A John Kanellopoulos MD

- I. Inflammation of the Interface: Diffuse Lamellar Keratitis (DLK)
 - A. DLK / wavy infiltrate (sands of Sahara [SOS])
 - B. *Beware*: percolation of aqueous > malignant glaucoma
 - C. Pathogenesis
 1. Endotoxins (tears, spears, blade, instruments, plaster dust, dead microbe spores in autoclaves)
 2. Inflammation cells → enzymes → necrosis
 3. Prevention and management

Based on visual acuity, evolution, and confluence: Steroids (every 1 -3 hours), interface washing + steroids + cold BSS if it's grade 4. Treat up to 2 weeks, watch IOP and clean instruments, beware of high IOP masked by interface fluid that results in low measurements.
 - D. Differentiate from central toxic keratopathy!
- II. Transient Dry Eye

Lubrication, plugs, topical cyclosporine
- III. Flap Striae

Hyperthermic ironing and suturing the flap—the conclusive solution?
- IV. Infection Microbial Keratitis in LASIK
 - A. Incidence: 1/1000 to 1/5000 procedures (under-reported?)
 - B. Intraoperative intrastromal contamination likely
 - C. Sterility measures greatly vary, but are imperative.
 - D. ABTs prophylaxis is essential (Gram + eyelid flora and mycobacterial coverage)
 - E. Differential diagnosis: DLK, debris, ABT/steroid deposits
 - F. Fungal keratitis must be suspected when epithelium is intact ± multiple lesions (satellites), quiet eye (no pain!!).
 - G. Difficult to diagnose and treat! Results can be challenging:
 1. Flap necrosis
 2. Stromal scarring
 3. Visual loss
- V. Infection Fungal Keratitis (*Acremonium*)
- VI. Ectasia – Pearls
 - A. Pathogenesis / Randelman criteria maybe helpful.
 1. Thin residual stroma (< 250, < 480)
 2. Forme fruste keratoconus (Always read topographies carefully.)
 3. Stromal lamellae shift
 4. Refraction follow-up
 5. Elevation topography (Orbiscan) BFS > 55 D, Post Diff > 50 μm
 - B. Management
 1. Corneal crosslinking (CXL) is now the gold standard.
 2. Intracorneal ring segments or even ALTK, DALK/PK
 - C. Prevention
 1. Detection → phakic IOL for selected cases
 2. Beware of enhancement procedures thinning the cornea further, some “regressions” may be early ectasia.
- VII. Currently Sensitive Criteria for Cornea Irregularity and/or Early Ectasia That We Have Reported
 - A. Anterior corneal curvature topometric asymmetry indices IHD and ISV
 - B. Qualitative pachymetric asymmetry assessment (normal cornea thickens in circles and smoothly); Scheimpflug, OCT
 - C. ART-Max = TP/PPI-Max (essentially “steep” cornea pachymetry change)
 - D. Epithelial map profiles may be the most sensitive tool.
 - E. Biomechanical measurements-Brillouin may hold promise in the future
- VIII. Surgical Management of Ectasia UV-CXL and Maybe Additional Topo-guided PRK
 - A. Topo-guided partial PRK
 - B. The Athens Protocol (AP) (see Figure 1)
 - C. AP plus PiXL (variable fluence topo-guided CXL)
- IX. Decentered irregular ablations

Topography-guided therapeutic ablations may be the best solution.

X. Irregular Flaps

PRK after flap has healed may be the best solution.

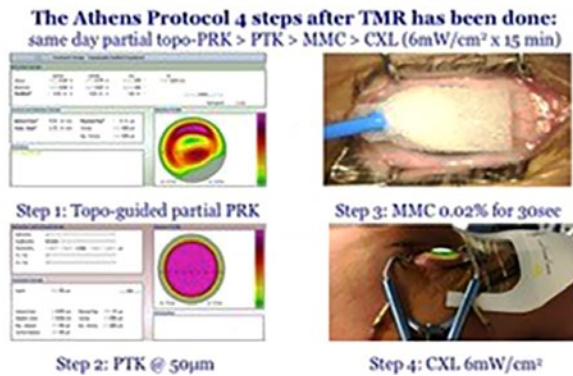


Figure 1. The four steps of the current Athens protocol.

Selected Readings

1. Kanellopoulos AJ, Binder PS. Management of corneal ectasia after LASIK with combined, same-day, topography-guided partial transepithelial PRK and collagen cross-linking: the Athens protocol. *J Refract Surg.* 2011; 27(5):323-331.
2. Kanellopoulos AJ, Skouteris VS. Secondary ectasia due to forceps injury at childbirth: management with combined topography-guided partial PRK and collagen cross-linking (Athens Protocol) and subsequent phakic IOL implantation. *J Refract Surg.* 2011; 27(9):635-636.
3. Kanellopoulos AJ, Aslanides IM, Asimellis G. Correlation between epithelial thickness in normal corneas, untreated ectatic corneas, and ectatic corneas previously treated with CXL; is over-all epithelial thickness a very early ectasia prognostic factor? *Clin Ophthalmol.* 2012; 6:789-800.

Phakic IOL Complications

Posterior Chamber Phakic IOLs

Alaa Eldanasoury MD

Introduction

Phakic IOLs (P-IOLs) have passed through many stages of innovation and development over the last 3 decades. Today they have a central place in refractive surgical practice and are considered a valuable option for patients seeking freedom from spectacles. It is of prime importance for refractive surgeons to be aware of the potential complications of P-IOLs.

Available Designs

Two P-IOL designs are currently available: the iris-fixated lens (Artisan, Ophtec; Groningen, Netherlands) and the posterior chamber P-IOL (ICL, Staar Surgical; Nidau, Switzerland). Each design has its advantages and potential disadvantages.

Potential Complications of Iris-Fixated P-IOLs

- Endothelial damage may occur in cases of shallow anterior chamber. It is agreed that 2.8 mm of central anterior chamber depth calculated from the endothelium is safe.
- Iris damage is an uncommon complication of iris-fixated IOLs and may be seen many years after the surgery. It may lead to piercing of the iris and sagging of the implant.
- Late dislocation due to trauma and/or poor enclavation
- Decentration. Centration of iris-fixated P-IOLs is the responsibility of the surgeon, and in some cases a small decentration can lead to incapacitating edge glare, especially with large pupil diameter.
- Low-grade chronic uveitis
- Postoperative astigmatism after nonfoldable implants

Potential Complications of Posterior Chamber P-IOLs

- Sizing complications. Sizing remains the main unsolved issue in ICL surgery. White-to-white is the most commonly used method for sizing; it can be measured with calipers or with imaging devices including Orbscan (Bausch + Lomb; Rochester, NY), Pentacam (Oculus; Wetzlar, Germany), and IOLMaster (Carl Zeiss; Oberkochen, Germany). Many studies showed no correlation between white-to-white measurements and sulcus diameter; however, clinical outcomes showed that the rate of over- or undersizing using the white-to-white measurement is less than 5%. More recent studies evaluated the use of high-frequency ultrasound and reported more reliable results compared to white-to-white measurement.⁸⁻¹⁰
- Lens-induced anterior subcapsular cataract. Although a rare complication, induced cataract remains an important complication of posterior chamber P-IOLs. The most important cause of cataract development is surgical trauma during a faulty surgical procedure. The second cause is poor sizing leading to peripheral touch between the implant and the crystalline lens, leading to poor aque-

ous circulation and accumulation of metabolites. The recently introduced model with a central hole is believed to improve the aqueous circulation and minimize the possibility of metabolic cataract.

- Postoperative IOP spikes. This may occur due to retained viscoelastic or, rarely, due to blockage of the central hole by inflammatory exudates in cases of severe postoperative inflammation. This must be treated immediately by decreasing the IOP through evacuation of viscoelastic through a paracentesis or anterior chamber wash if needed. In cases that are not promptly treated, this complication may end in a fixed and dilated pupil.
- Rotation of undersized posterior phakic IOL. This usually has a negative impact on the postoperative refractive outcome and commonly requires a lens exchange.

Selected Readings and References

1. Perez-Santonja JJ, Iradier MT, Benitez del Castillo JM, et al. Chronic subclinical inflammation in phakic eyes with intraocular lenses to correct myopia. *J Cataract Refract Surg.* 1996; 22(2):183-187.
2. Shimizu K, Kamiya K, Igarashi A, Shiratani T. Intraindividual comparison of visual performance after posterior chamber phakic intraocular lens with and without a central hole implantation for moderate to high myopia. *Am J Ophthalmol.* 2012; 154(3):486-494.
3. Pérez-Vives C, Ferrer-Blasco T, Madrid-Costa D, et al. Optical quality comparison of conventional and hole-Visian implantable collamer lens at different degrees of decentration. *Am J Ophthalmol.* 2013; 156(1):69-76.
4. Kamiya K, Shimizu K, Igarashi A, Hikita F, Komatsu M. Four-year follow-up of posterior chamber phakic intraocular lens implantation for moderate to high myopia. *Arch Ophthalmol.* 2009; 127(7):845-850.
5. Pesando PM, Ghiringhello MP, Di Meglio G, Fanton G. Posterior chamber phakic intraocular lens (ICL) for hyperopia: ten-year follow-up. *J Cataract Refract Surg.* 2007; 33(9):1579-1584.
6. Pérez-Vives C, Ferrer-Blasco T, Domínguez-Vicent A, García-Lázaro S, Montés-Micó R. Optical and visual quality of the Visian implantable collamer lens using an adaptive-optics visual simulator. *Am J Ophthalmol.* 2013; 155(3):499-507.
7. Kawamorita T, Uozato H, Kamiya K, Shimizu K. Relationship between ciliary sulcus diameter and anterior chamber diameter and corneal diameter. *J Cataract Refract Surg.* 2010; 36(4):617-624.
8. Reinstein DZ, Lovisolo CF, Archer TJ, Gobbe M. Comparison of postoperative vault height predictability using white-to-white or sulcus diameter-based sizing for the Visian implantable collamer lens. *J Refract Surg.* 2013; 29(1):30-35.
9. Choi KH, Chung SE, Chung TY, Chung ES. Ultrasound biomicroscopy for determining Visian implantable contact lens length in phakic IOL implantation. *J Refract Surg.* 2007; 23(4):362-367.

2018 Advocating for the Profession and Patients

Refractive Surgery Subspecialty Day

Vineet (Nick) Batra MD

Ophthalmology's goal to protect sight and empower lives requires active participation and commitment to advocacy from every ophthalmologist. Contributions to the following three critical funds are a part of that commitment:

- OPHTHPAC® Fund
- Surgical Scope Fund (SSF)
- State Eye PAC

Please join the dedicated community of ophthalmologists who are contributing to protect quality patient eye care for everyone. The OPHTHPAC Committee is identifying Congressional Advocates in each state to maintain close relationships with federal legislators in order to advance ophthalmology and patient causes. At Mid-Year Forum 2018, we honored nine of those legislators with the Academy's Visionary Award. This served to recognize them for addressing issues important to us and to our patients. The Academy's Secretariat for State Affairs is collaborating closely with state ophthalmology society leaders to protect Surgery by Surgeons at the state level.

Our mission of "protecting sight and empowering lives" requires robust funding of both the Surgical Scope Fund and the OPHTHPAC Fund. Each of us has a responsibility to ensure that these funds are strong.

OPHTHPAC® Fund

OPHTHPAC is a crucial part of the Academy's strategy to protect and advance ophthalmology's interests in key areas, including physician payments from Medicare and protecting ophthalmology from federal scope-of-practice threats. Established in 1985, OPHTHPAC is one of the oldest, largest, and most successful political action committees in the physician community. We are very successful in representing your profession to the U.S. Congress.

Advocating for our issues in Congress is a continuous battle, and OPHTHPAC is always under financial pressure to support our incumbent friends as well as to make new friends among candidates. These relationships allow us to have a seat at the table with legislators who are willing to work on issues important to us and our patients.

The relationships OPHTHPAC builds with members of Congress is contingent on the financial support we receive from Academy members. Academy member support of OPHTHPAC allows us to advance ophthalmology's federal issues. We need to increase the number of our colleagues who contribute to OPHTHPAC and to the other funds. Right now, major transformations are taking place in health care. To ensure that our federal fight and our PAC remain strong, we need the support of every ophthalmologist to better our profession and ensure quality eye care for our patients.

Among the significant impacts made by OPHTHPAC are the following:

- Secured relief from the burdens and penalties associated with the existing Medicare quality improvement programs for 2018
- Halted applications of MIPS penalties to Part B drug payments to physicians
- Convinced CMS to revisit drastic cuts to retina and glaucoma surgical codes
- Halted the flawed Part B Drug Demonstration
- Derailed an onerous global surgery payment data collection plan
- Continued efforts in collaboration with subspecialty societies to preserve access to compounded and repackaged drugs such as Avastin

Contributions to OPHTHPAC can be made here at AAO 2018, or online at www.aao.org/opthtpac by clicking "Join." You can also learn more by texting "OPHTH" to 51555.

Leaders of the American Society of Cataract & Refractive Surgery (ASCRS) are part of the American Academy of Ophthalmology's Ophthalmic Advocacy Leadership Group (OALG), which meets annually in January in Washington, D.C., to provide critical input and to discuss and collaborate on the Academy's advocacy agenda. At the January 2018 OALG meeting, panel discussions took place on the outlook for Medicare reimbursement and implementation of the Merit-based Incentive Payment System (MIPS), as well as specialty research related to the IRIS™ Registry. In addition, meeting participants discussed the changing paradigm for optometric scope battles, held a roundtable to discuss challenges for surgical subspecialties, and considered how telemedicine could impact ophthalmology.

At Mid-Year Forum 2018, the Academy and ASCRS ensured a strong presence of cataract and refractive specialists to support ophthalmology's priorities. Ophthalmologists visited members of Congress and their key health staff to discuss ophthalmology priorities as part of Congressional Advocacy Day. The ASCRS remains a crucial partner with the Academy in its ongoing federal and state advocacy initiatives.

Surgical Scope Fund

Thanks to 2018 contributions to the Surgical Scope Fund (SSF) from ophthalmologists across the country, the Academy's Surgery by Surgeons initiative has had a successful year preserving patient surgical safety and surgical standards in state legislatures across the country. The SSF is key to the Academy's Surgery by Surgeons campaign. *If you have not yet made a 2018 SSF contribution*, visit our contribution booth at AAO 2018 or contribute online at www.aao.org/ssf. If you already have made that 2018 contribution, please consider making a crucially needed supplemental contribution.

The SSF provides grants to state ophthalmology societies in support of their efforts to derail optometric surgery proposals that pose a threat to patient safety. Since its inception, the

Surgery by Surgeons campaign and the SSF, in partnership with state ophthalmology societies, has helped 34 state/territorial ophthalmology societies reject optometric scope-of-practice expansion into surgery.

To date in 2018, thanks to financial resources from the SSF, the Surgery by Surgeons campaign has netted patient safety and surgery standard preservation victories in the following battleground states:

- Florida
- Iowa
- Maryland
- Mississippi
- Nebraska
- North Carolina
- South Carolina
- Vermont
- Virginia

The 2018 battle is far from over, though. For example, California, Illinois, Massachusetts, and Pennsylvania are currently under assault. Furthermore, as of submission of this update in June 2018, the optometric surgery push had sprouted in six additional states.

Dollars from the SSF are critical in the state surgery campaigns. In each of these legislative battles, the benefits from SSF distributions are abundantly clear. The best lobbyists and public relations consultants are contracted as necessary. Additionally, media campaigns (including TV, radio, and social media) are launched to educate the voting public when needed. This helps to secure success in protecting patient safety by thwarting optometry's attempts at expanding its scope of practice to include surgery privileges.

Each of these endeavors is very expensive, and no one state has the resources to wage one of these battles on its own. Ophthalmologists must join together and donate to the SSF to fight for patient safety when a state faces a scope battle over optometric surgery.

The Secretariat for State Affairs thanks the ASCRS, which joined state ophthalmology societies in contributing to the SSF in 2017, and looks forward to its continued financial support. Subspecialty organizations like the ASCRS complete the necessary SSF support structure for the creation and implementation of successful Surgery by Surgeons campaigns.

State Eye PAC

It is increasingly important for all ophthalmologists to support their respective State Eye PACs because campaign contributions to legislators at the state level must come from individual ophthalmologists and cannot come from the Academy, OPHTHPAC, or the SSF. The presence of a strong State Eye PAC providing financial support for campaign contributions and legislative education to elect ophthalmology-friendly candidates to the state legislature is critical, as scope-of-practice battles and many regulatory issues are fought on the state level.

ACTION REQUESTED: Advocate for Your Profession & Your Patients

Academy SSF contributions are used to support the infrastructure necessary in state legislative / regulatory battles and for public education. State PAC and OPHTHPAC contributions

are necessary at the state and federal level, respectively, to help elect officials who will support the interests of our patients. Contributions to *each* of these three funds are necessary and help us protect sight and empower lives. SSF contributions are completely confidential and may be made with corporate checks or credit cards, unlike PAC contributions, which must be made by individuals and are subject to reporting requirements.

Please respond to your Academy colleagues and be part of the community that contributes to OPHTHPAC, the Surgical Scope Fund, and your State Eye PAC. Please be part of the community advocating for your patients now.

OPHTHPAC Committee

Jeffrey S Maltzman MD (AZ)—Chair
 Janet A Betchkal MD (FL)
 Sidney K Gicheru MD (TX)
 Sohail J Hasan MD PhD (IL)
 Gary S Hirshfield MD (NY)
 David W Johnson MD (CO)
 S Anna Kao MD (GA)
 Stephanie J Marioneaux MD (VA)
 Dorothy M Moore MD (DE)
 Niraj Patel MD (WA)
 John D Roarty MD (MI)
 Linda Schumacher-Feero MD (ME)
 Diana R Shiba MD (CA)
 Woodford S Van Meter MD (KY)
 Jeffrienne S Young MD (IA)

Ex-Officio Members

Keith D Carter MD (IA)
 Daniel J Briceland MD (AZ)
 Michael X Repka MD MBA (MD)
 George A Williams MD (MI)

Surgical Scope Fund Committee

Kenneth P Cheng MD (PA)—Chair
 Matthew F Appenzeller MD (NE)
 Vineet ("Nick") Batra MD (CA)
 Gareth Lema MD PhD (NY)
 Cecily A Lesko MD FACS (NJ)
 Amalia Miranda MD (OK)
 Lee A Snyder MD (MD)
 David E Vollman MD MBA (MO)

Ex-Officio Members

Daniel J Briceland MD (AZ)
 Kurt F Heitman MD (SC)

Surgical Scope Fund	OPHTHPAC® Fund	State EyePAC
To derail optometric surgical scope of practice initiatives that threaten patient safety and quality surgical care	Ophthalmology's interests at the federal level Support for candidates for U.S. Congress	Support for candidates for state House, Senate, and governor
Political grassroots activities, lobbyists, PR and media campaigns	Campaign contributions, legislative education	Campaign contributions, legislative education
No funds may be used for campaign contributions or PACs.		
Contributions: Unlimited Individual, practice, and organization	Contributions: Limited to \$5,000	Contribution limits vary based on state regulations.
Contributions are 100% confidential.	Contributions above \$200 are on the public record.	Contributions are on the public record depending upon state statutes.

SMILE Versus Optimized LASIK for Myopia and Astigmatism Correction

Leonardo Mastropasqua MD

NOTES

SMILE Advantages: From Theory to Clinical Reality

Beatrice Cochener MD

NOTES

[illegible]

Review and Management of Complications

Mario Nubile MD

NOTES

The Hope for a Hyperopic SMILE

Pavel Stodulka MD PhD

NOTES

This image shows a single sheet of white paper with horizontal ruling lines. The lines are evenly spaced and run across the width of the page. There are no margins, text, or other markings on the paper.

Histological and microRNA Signatures of Corneal Epithelium in Keratoconus

Yumeng Wang MM PhD, Tsz Kin Ng PhD, Kwong Wai Choy PhD, Hoi Kin Wong MPhil, Wai Kit Chu DPhil, Chi Pui Pang DPhil, and Vishal Jhanji MD FRCOphth

The etiology of keratoconus is complex and multifactorial, involving both genetic and environmental factors.¹⁻³ In vivo confocal images have shown abnormal features in every layer of the cornea, including abnormal epithelial keratinocytes.^{4,5} This lecture aims to illustrate the histopathology of keratoconic corneal epithelia and its microribonucleic acid (miRNA) regulation as compared to corneal epithelia of normal individuals.

In this study, corneal epithelia were collected from keratoconus patients and healthy subjects during surgery or by impression cytology for investigation of their histological structures. The miRNA profiles were resolved by microarray, and miRNA target genes were analyzed. The expressions of significant miRNAs were validated using TaqMan polymerase chain reaction (PCR), whereas protein localization and expression of the miRNA target genes were examined by immunofluorescence and immunoblotting analyses. In addition, the translational potential of the miRNA expression was evaluated in the corneal epithelial samples obtained by impression cytology.

Keratoconus patients were found having thinner corneal epithelia with loosely packed cells compared to normal patients. Microarray analysis revealed that 12 miRNAs were significantly downregulated in keratoconic corneal epithelia. TaqMan PCR validated the altered expression of six miRNAs in corneal epithelia from surgery (*hsa-miR-151a-3p*, *hsa-miR-138-5p*, *hsa-miR-146b-5p*, *hsa-miR-194-5p*, *hsa-miR-28-5p*, and *hsa-miR-181a-2-3p*) and four miRNAs in squamous corneal epithelial samples collected from impression cytology (*hsa-miR-151a-3p*, *hsa-miR-195-5p*, *hsa-miR-185-5p*, and *hsa-miR-194-5p*). In addition, higher S100A2 expression was found in the epithelial basal cell layer of keratoconic corneal epithelia.

In conclusion, we have revealed the histological features of keratoconic corneal epithelia as different from normal. There is a signature miRNA profile of keratoconus, with effects on protein expressions of specific signal pathways. In addition, impression cytology is a useful tool to collect corneal epithelial tissues for gene expression analysis.

References

1. Jhanji V, Sharma N, Vajpayee RB. Management of keratoconus: current scenario. *Br J Ophthalmol*. 2011; 95:1044-1050.
2. Kennedy RH, Bourne WM, Dyer JA. A 48-year clinical and epidemiologic study of keratoconus. *Am J Ophthalmol*. 1986; 101:267-273.
3. Lu Y, Vitart V, Burdon KP, et al. Genome-wide association analyses identify multiple loci associated with central corneal thickness and keratoconus. *Nat Genet*. 2013; 45:155-163.
4. Mocan MC, Yilmaz PT, Irkec M, Orhan M. In vivo confocal microscopy for the evaluation of corneal microstructure in keratoconus. *Curr Eye Res*. 2008; 33:933-939.
5. Mathew JH, Goosey JD, Bergmanson JP. Quantified histopathology of the keratoconic cornea. *Optom Vis Sci*. 2011; 88:988-997.

Corneal Allogenic Intrastromal Ring Segments Combined With Corneal Crosslinking for Keratoconus

Soosan Jacob MS FRCS DNB, Shaila R Patel DNB, Amar Agarwal MS FRCS FRCO, Arvind Ramalingam BOptom, A I Saijmol BSc, and John Michael Raj MSc

Abstract

Purpose

To describe a new technique for the treatment of keratoconus using corneal allogenic intrastromal ring segments (CAIRS).

Methods

CAIRS trephined from donor cornea using a double-bladed trephine were implanted into mid-depth femtosecond laser-dissected channels in the cornea of patients with keratoconus in the 6.5-mm optic zone, followed by accelerated corneal cross-linking (A-CXL)—either conventional or contact lens-assisted CXL (A-CACXL), depending on minimum corneal thickness.

Results

Twenty patients (24 eyes) with stage 1 to 4 keratoconus (Amsler-Krumeich grading) were included. Mean follow-up was 11.58 ± 3.6 months (range: 6 to 18 months). There was signifi-

cant improvement in uncorrected (2.79 ± 2.65 lines; range: 0 to 8 lines) and corrected (1.29 ± 1.33 lines; range: 0 to 5 lines) distance visual acuity, spherical equivalent, simulated maximum keratometry, steepest keratometry, topographic astigmatism, anterior and posterior best fit spheres, and mean power in the 3- and 5-mm zones. No eye showed progression during the entire follow-up. All segments remained well positioned, and no segment-induced complications were seen. No other major intraoperative or postoperative complications were observed.

Conclusions

This pilot study indicates that CAIRS with CXL may be a simple, safe, and effective option for treating keratoconus. Further studies are recommended to determine long-term outcomes.

Customized Corneal Crosslinking Using Different UVA Beam Profiles

Rohit Shetty MBBS, Natasha Pahuja MD, Thimmarayappa Roshan MD, Rashmi Deshmukh MD, Mathew Francis MTech, Arkasubhra Ghosh PhD, and Abhijit Sinha Roy PhD

Abstract

Purpose

To evaluate the performance of different customized corneal crosslinking (CXL) methods.

Methods

This was a single-center interventional, prospective, longitudinal case series. Four different customized CXL methods were evaluated in keratoconic eyes: (1) uniform (uniform intensity ultraviolet-A [UVA] beam [9 mW/cm²] for 10 minutes) ($n = 12$ eyes); (2) sector axial map (sector-based UVA irradiation) ($n = 12$ eyes); (3) ring axial map (concentric rings of UVA beam intensity centered at the steepest curvature of the anterior axial map) ($n = 12$ eyes); and ring tangential map (same as the ring axial map but centered at the steepest curvature of the anterior tangential map) ($n = 14$ eyes). Peak UVA energy density in the sector and ring axial map (and ring tangential map) protocols did not exceed 15.0 and 10.8 J/cm², respectively. A 0.1% riboflavin solution was applied after epithelium removal. Corneal tomography and visual acuity were assessed before and 6 months after CXL.

Results

Average and peak energy density was lowest in the ring tangential protocol and highest in the sector axial map group ($P < .001$). Treated area was lowest in the ring tangential map group and highest in the uniform group ($P < .001$). Decrease in curvature was similar among the uniform, sector axial map, and ring axial map groups ($P < .05$). The ring tangential map group had the greatest decrease in curvature per unit energy dose to the cornea ($P < .05$). Improvement in uncorrected (0.081 ± 0.056 logMAR) and corrected (0.041 ± 0.026 logMAR) distance visual acuity per unit energy density was greatest in the ring tangential map group ($P > .05$).

Conclusions

When normalized to the average energy density, the ring tangential map protocol appeared to provide maximum flattening and improvement in visual acuity. Further studies with larger sample sizes are needed to validate the findings of this pilot study.

Ciliary Muscle Electrostimulation to Restore Accommodation in Patients With Early Presbyopia: Preliminary Results

Luca Gualdi MD, Federica Gualdi MD, Dario Rusciano PhD, Renato Ambrósio Jr MD PhD, Marcella Q Salomão MD, Bernardo Lopes MD, Veronica Cappello MD, Tatiana Fintina MD, and Massimo Gualdi MD

Abstract

Purpose

To report short-term results of pulsed ciliary muscle electrostimulation to improve near vision, likely through restoring accommodation in patients with emmetropic presbyopia.

Methods

In a prospective nonrandomized trial, 27 patients from 40 to 51 years old were treated and 13 age- and refraction-matched individuals served as untreated controls. All patients had emmetropia and needed near sphere add between +0.75 and +1.50 diopters. The protocol included 4 sessions (1 every 2 weeks within a 2-month period) of bilateral pulsed (2 sec on; 6 sec off) micro-electrostimulation with 26 mA for 8 minutes, using a commercially available medical device. The uncorrected distance visual acuity (UDVA) (logMAR) for each eye, uncorrected near (40 cm) visual acuity in each eye (UNVA) and with both eyes (UNVA OU) (logMAR), and reading speed (number of words read per minute at 40 cm) were measured preoperatively and 2 weeks after each session. Overall satisfaction (0 to 4 scale) was assessed 2 weeks after the last session.

Results

UDVA did not change and no adverse events were noted in either group. Bilateral and monocular UNVA and reading speed were stable in the control group, whereas they continuously improved in the treated group (Friedman, $P < .00001$). Post-hoc significant differences were found for monocular and binocular UNVA after the second treatment and after the first treatment considering words read per minute ($P < .001$). One patient (3.7%) was not satisfied, and 18 patients (66.7%) were very satisfied (score of 4). Average satisfaction score was 3 (satisfied).

Conclusions

Ciliary muscle contraction to restore accommodation was safe and improved the short-term accommodative ability of patients with early emmetropic presbyopia.

Outcomes of Retreatment by LASIK After Small-Incision Lenticule Extraction

Dan Z Reinstein MD

Abstract

Purpose

To report the outcomes of LASIK retreatments after small incision lenticule extraction (SMILE).

Methods

Retrospective review of all eyes to have undergone a retreatment by LASIK after primary SMILE between September 2013 and January 2016. Thin-flap LASIK was used in most cases as long as sufficient tissue was available for safe flap creation between the maximum epithelial thickness and minimum cap thickness. Otherwise, the SMILE interface was converted into a LASIK flap by the Circle technique or side cut only. The multivariate nomogram for LASIK retreatments was used, including sphere, cylinder, age, and primary spherical equivalent (SEQ) as variables. Patients were observed for 1 year after surgery and standard outcomes analysis was performed.

Results

A total of 116 LASIK retreatments were performed in a population of 2643 consecutive SMILE procedures, indicating a retreatment rate of 4.39%. Mean attempted SEQ was -0.05 ± 0.99 diopters (D) (range: -1.88 to $+1.50$ D). Mean cylinder was

-0.70 ± 0.55 D (range: 0.00 to -2.25 D). Postoperative uncorrected distance visual acuity was 20/20 or better in 81% of eyes, for a population with corrected distance visual acuity (CDVA) of 20/20 or better in 95% before retreatment. Mean postoperative SEQ relative to the target was $+0.19 \pm 0.49$ D (range: -0.88 to $+2.13$ D), with 74% within ± 0.50 D. Mean postoperative cylinder was -0.29 ± 0.24 D (range: 0.00 to -1.25 D). There was 1-line loss of CDVA in 15% of eyes, but no eyes lost 2 or more lines. There was a small increase in contrast sensitivity ($P < .05$). Overcorrection was identified in myopic retreatments ($n = 20$) of -1.00 D or more; mean postoperative SEQ was $+0.59 \pm 0.64$ D (range: -0.63 to $+2.13$ D).

Conclusions

Retreatment after SMILE by LASIK achieved excellent visual and refractive outcomes, although these results indicate that myopic LASIK retreatment after primary myopic SMILE requires a different nomogram than for myopic LASIK retreatment after primary myopic LASIK.

Four-Year Visual Performance After Small-Aperture IOL Implantation in Cataract Patients

Robert Edward T Ang MD

Purpose

To prospectively evaluate long-term visual performance of a small-aperture IOL.

Methods

Thirty-two eyes of 22 subjects were implanted with the IC-8 small-aperture IOL (AcuFocus). Uncorrected visual acuity, refraction, contrast sensitivity (CS), symptoms, and satisfaction ratings are presented up to 48 months. A 7-point scale was used for satisfaction (7, extremely satisfied).

Results

At 48 months, the mean uncorrected distance (UCDVA), intermediate (UCIVA), and near (UCNVA) visual acuity in the IC-8 IOL eyes were 0.04 ± 0.09 , 0.05 ± 0.16 , and 0.11 ± 0.14 , respectively. The average manifest refraction spherical equivalent in the IC-8 IOL eyes was -0.34 ± 0.61 D. Photopic and mesopic CS testing showed similar scores between IC-8 IOL and monofocal IOL implanted eyes. Contralateral and bilateral groups also achieved comparable photopic and mesopic CS results. Overall patient satisfaction was 6.25 ± 1.05 .

Conclusion

The IC-8 IOL improves near, intermediate, and distance vision, with high overall satisfaction and low visual symptoms over the 48-month follow-up.

Effectiveness of a New Matrix Therapy Agent, Cacicol, on Re-epithelialization and Tolerability After PRK

Arturo J Ramirez-Miranda MD, Tania Albavera-Giles MD, Laura Elisa Toro MD, Ricardo Blas MD, Alejandro Navas MD, and Enrique O Graue Hernandez MD

Purpose

To compare the effectiveness of a new matrix therapy agent, Cacicol, in the re-epithelialization rate and alleviation of the local symptoms of post-PRK discomfort.

Methods

Randomized, parallel group study. Subjects who underwent PRK were divided into 2 groups: Group A included 30 patients treated with Cacicol, and Group B included 30 patients with 2% sodium hyaluronate. Epithelial defect size was measured at postoperative days 1, 3, and 7.

Results

Twenty-four hours after PRK, the Cacicol group had a mean area of epithelial defect of 35.27 mm vs. 42.15 mm in the control group ($P = .215$); at 72 hours, 0.10 mm² vs. 0.90 mm² ($P = .719$), respectively. At 120 hours, 100% of the Cacicol group eyes had no epithelial defect, compared to 85.2% in the control group.

Conclusion

Cacicol may improve the re-epithelialization rate after PRK, in order to lower the epithelial defect–related complications.

Distinguishing Highly Asymmetric Keratoconus Eyes Using Combined Scheimpflug and Spectral Domain OCT Analysis

J Bradley Randleman MD, Eric Hwang, Claudia E Perez-Straziota MD, Sang Woo Kim MD, and Marcony R Santhiago MD

Purpose

To determine optimal variables from Scheimpflug and spectral domain OCT (SD-OCT) to distinguish the clinically unaffected eye in patients with asymmetric keratoconus (AKC) from normal controls.

Methods

ROC curves were generated to determine area under the curve (AUC), sensitivity, and specificity for each variable. Logistic regression analysis was performed to find optimal variable combinations.

Results

In 30 AKC and 60 control eyes, no individual metric from either technology yielded an AUC > 0.75. Best Scheimpflug ($n = 5$) yielded AUC = 0.85, with sensitivity of 83% and specificity of 83%. Best SD-OCT ($n = 11$) yielded AUC = 0.95, with sensitivity of 89% and specificity of 89%. Best combined Scheimpflug / SD-OCT ($n = 13$) yielded AUC = 1.0, with sensitivity of 100% and specificity of 100%.

Conclusion

Combining Scheimpflug anterior curvature and asymmetry indices with SD-OCT regional total and epithelial thickness variability metrics clearly distinguished the 2 populations.

Incidence of Symptomatic Decentration and Small Optical Zone Over a 10,000-Eye Single-Practice Series and Outcomes of Topography-Guided Therapeutic Repair

Dan Z Reinstein MD

Purpose

To report the incidence of eyes needing topography-guided repair and subsequent outcomes.

Methods

Retrospective analysis of 73 eyes with night vision complaints due to decentration or small optical zone (OZ) after myopic laser surgery. The CRS-Master and Atlas topography were used for ablation planning. Follow-up was 12 months.

Results

The incidence of use during the study period was 0.79%. The mean OZ diameter was increased by 11%. Mean topographic decentration was reduced by 64%. There was a reduction in spherical aberration by 44%; coma, by 53%; and total higher-order aberrations, by 39%. A subjective improvement in night vision was reported by 93%. Eighty-two percent of eyes reached 20/20. No eyes lost 2 lines of corrected distance visual acuity.

Conclusion

Topography-guided ablation appears to be an effective method for retreating symptomatic patients after myopic LASIK.

Refractive Outcomes of Intraoperative Wavefront Aberrometry Compared With Preoperative Biometry for Cataract Surgery in Patients With Prior Refractive Surgery

Saman Nassiri MD and Frank S Hwang MD

Purpose

To compare intraoperative wavefront aberrometry (ORA) with a preoperative method in calculation of IOL power in patients with prior refractive surgery.

Methods

This is a retrospective longitudinal comparative study. Eyes in which preoperative method and ORA suggested the same power (Preop/ORA), those in which the preoperative calculation was selected (Preop), and those in which the ORA calculation was selected (ORA) were compared based on the difference between actual and predicted refractions 1 month after surgery.

Results

Fifty-two consecutive eyes were included in the analysis, with 17, 12, and 23 in each of the groups (Preop/ORA, Preop, and ORA), respectively. Median absolute errors were 0.610, 0.585, and 0.380 D, respectively (P , 0.827). The percentage of eyes within ± 0.5 D of the target refraction was 47.1%, 41.7%, and 60.9% for the three different groups, respectively (P , 0.496).

Conclusion

Intraoperative wavefront aberrometry is comparable to the newly incorporated preoperative formulas in calculation of IOL power in patients with prior refractive surgery.

To Evaluate Safety and Efficacy of SMILE Procedure: Seven-Year Follow-up

Osama I Ibrahim MD PhD, Ahmed A K El-Massry MD PhD, Kareem M Nagy MD, and Moones F Abdalla MD

Purpose

To evaluate the safety and efficacy of small-incision lenticule extraction (SMILE) with up to 7 years of follow-up.

Methods

Prospective, noncomparative case series carried out on 1028 eyes treated in 2010 for myopia and myopic astigmatism with SMILE. UCVA, BSCVA, manifest refraction, and contrast sensitivity were measured in all cases.

Results

Mean preoperative UCVA was 0.1 (range: 0.03-0.6), mean corrected distance VA was 0.8 (range: 0.4-1.2), and spherical equivalent of refraction (SEQ) was -5 (range: -1.5 to -14). All these parameters showed a statistically significant change in the postoperative period ($P < .01$). Mean postoperative UCVA, BSCVA, and SEQ were 0.88 (range: 0.5-1.2), 0.98 (range: 0.5-1.2), and -0.5 (range: -2.5 to +1.75), respectively. A few operative and postoperative complications were reported.

Conclusion

SMILE is a safe and effective procedure, with long-term refractive stability.

Financial Disclosure

The Academy has a profound duty to its members, the larger medical community, and the public to ensure the integrity of all of its scientific, educational, advocacy, and consumer information activities and materials. **Thus each Academy trustee, secretary, committee chair, committee member, taskforce chair, taskforce member, councilor, and representative to other organizations (“Academy Leaders”), as well as the Academy staff and those responsible for organizing and presenting CME activities, must disclose interactions with companies and manage conflicts of interest or the appearance of conflicts of interest that affect this integrity. Where such conflicts or perceived conflicts exist, they must be appropriately and fully disclosed and resolved.**

All contributors to Academy educational and leadership activities must disclose all financial relationships (defined below) to the Academy annually. The ACCME requires the Academy to disclose the following to participants prior to the activity:

- All financial relationships with commercial companies that contributors and their immediate family have had within the previous 12 months. A commercial company is any entity producing, marketing, reselling, or distributing health-care goods or services consumed by, or used on, patients.
- Meeting presenters, authors, contributors, or reviewers who report they have no known financial relationships to disclose.

The Academy will request disclosure information from meeting presenters, authors, contributors or reviewers, committee members, Board of Trustees members, and others involved in Academy leadership activities (“Contributors”) annually. Disclosure information will be kept on file and used during the calendar year in which it was collected for all Academy activities. Updates to the disclosure information file should be made whenever there is a change. At the time of submission of a Journal article or materials for an educational activity or nomination to a leadership position, each Contributor should specifically review his/her statement on file and notify the Academy of any changes to his/her financial disclosures. These requirements apply to relationships that are in place at the time of or were in place 12 months preceding the Contributor’s presentation, publication submission, or nomination to a leadership position. Any financial relationship that may constitute a conflict of interest will be resolved prior to the delivery of the activity.

Visit www.aao.org/about/policies for the Academy’s policy on identifying and resolving conflicts of interest.

Financial Relationship Disclosure

For purposes of this disclosure, a known financial relationship is defined as any financial gain or expectancy of financial gain brought to the Contributor or the Contributor’s immediate family (defined as spouse, domestic partner, parent, child or spouse of child, or sibling or spouse of sibling of the Contributor) by:

- Direct or indirect compensation;
- Ownership of stock in the producing company;
- Stock options and/or warrants in the producing company, even if they have not been exercised or they are not currently exercisable;
- Financial support or funding to the investigator, including research support from government agencies (e.g., NIH), device manufacturers, and/or pharmaceutical companies; or
- Involvement with any for-profit corporation that is likely to become involved in activities directly impacting the Academy where the Contributor or the Contributor’s family is a director or recipient

Description of Financial Interests

Category	Code	Description
Consultant / advisor	C	Consultant fees, paid advisory boards, or fees for attending a meeting
Employee	E	Employed by a commercial company
Lecture fees	L	Lecture and speakers bureau fees (honoraria), travel fees, or reimbursements when speaking at the invitation of a commercial company
Equity owner	O	Equity ownership/stock options (publicly or privately traded firms, excluding mutual funds)
Patents / royalty	P	Patents and/or royalties that might be viewed as creating a potential conflict of interest
Grant support	S	Grant support from all sources

Faculty Financial Disclosures

Control of Content

The American Academy of Ophthalmology considers presenting authors, not coauthors, to be in control of the educational content. It is Academy policy and traditional scientific publishing and professional courtesy to acknowledge all people contributing to the research, regardless of CME control of the live presentation of that content. This acknowledgement is made in a similar way in other Academy CME activities. Though coauthors are acknowledged, they do not have control of the CME content and their disclosures are not published or resolved. Portions of the meeting not eligible for credit include attending Break with the Experts and viewing E-posters.

Amar Agarwal MD

Bausch + Lomb: S
Jaypee-Highlights Medical Publishers: P
Mastel: P
Sanoculus: C
SLACK Inc.: P
Staar Surgical: C
Thieme Medical Publishers: P

Jorge L Alio MD PhD

Akkolens : C,S
Bloss: L
Bluegreen: O
Carevision: C,S
Carl Zeiss Meditec: S
CSO: C
Dompe: S
Hanita Lenses: C
International Ophthalmology Consulting: O
Jaypee Bros: P
KeraMed, Inc.: C,S
Magrabi hospital: C
Mediphacos: C
Novagali: S
Oculentis: C,S
Oftalcare Nutravision: O
Omeros: C
OPHTEC: L
Presbia: C
SCHWIND eye-tech-solutions: L,S
SLACK, Incorporated: C
Springer Verlag: P
Tekia, Inc.: P
Topcon: C

Renato Ambrósio Jr MD

Alcon Laboratories Inc.: C
Allergan: L
Carl Zeiss Inc.: L
Mediphacos: L
Oculus Inc.: C

Robert Edward T Ang MD

AcuFocus, Inc.: C,L,S
Alcon Laboratories, Inc.: L
Allergan, Inc.: L,S
Bausch + Lomb Surgical: C,L,S
Glaukos Corporation: S,L
Ivantis: S,L
Johnson & Johnson Vision: S
Physiol: L,S
STAAR Surgical: S

Vineet N Batra MD

Alcon Laboratories Inc.: C,L
Avedro Inc.: L
Bausch + Lomb: C,L
Optos Inc.: L
Strathspecy Crown: O

George Beiko MD

Bausch + Lomb: C,S
Glaukos Corp.: C
Infinite Vision: C
Johnson & Johnson Vision: C
Labtician: S
Ophtec: L
Zeiss: C

David F Chang MD

Carl Zeiss Inc.: C
Eyenovia: O
Iantech: C,O
Icon Bioscience: O
iDrops: C,O
Ivantis: C,O
Johnson & Johnson Vision: C
Mynosys: C,O
PowerVision Inc.: C,O
Presbyopia Therapies: O
RX Sight: C,O
SLACK Inc.: P
Versant Ventures: O

John So-Min Chang MD

Abbott Medical Optics: L
Alcon Laboratories Inc.: L
Avedro Inc.: L
Johnson & Johnson: L

Y Ralph Chu MD

Bausch + Lomb: C
Carl Zeiss Meditec: C
Keranova: C
PowerVision: C
Refocus Group Inc.: C
ReVision Optics: C

Beatrice Cochener MD

None

Deepinder K Dhaliwal MD

Bausch + Lomb: C
Kala: S
Novabay: S
Ocular Therapeutix: L
Shire: S
Sightlife: L
Staar Surgical: L

Burkhard Dick MD

None

Kendall E Donaldson MD

Alcon Laboratories Inc.: C,L
Allergan: C
Johnson & Johnson: C
Novabay: C
Omeros: C
Shire: C
Sun: C
Tear Lab: C

Eric D Donnenfeld MD

Alcon Laboratories Inc.: C
 Allergan: C,L
 Bausch + Lomb: C
 Glaukos Corp.: C
 Ivantis: C
 Johnson & Johnson: C
 Mynosys: C,O
 PRN Physician Recommended
 Nutriceuticals: C,O
 TLC Laser Center: C
 Zeiss: C

Daniel S Durrie MD

AcuFocus Inc.: C,L,O
 Alcon Laboratories Inc.: S
 Alphaeon: C,O
 Avedro: C,L,O
 Concierge Key Health: C,O
 Eyedotec Medical Inc.: C
 Eyegate Pharma: C
 Hoopes Durrie Rivera Research
 Center: C
 Johnson & Johnson Vision: C,L
 Strathspey Crown LLC: C,O

Alaa M Eldanasoury MD

Nidek Inc.: C
 PhysiOL: C
 Staar Surgical: C

William J Fishkind MD FACS

Bausch + Lomb: C
 Johnson & Johnson: C
 Thieme Medical Publishers: P

Luca Gualdi MD

Acevision: C

Bonnie An Henderson MD

Alcon Laboratories Inc.: C,L
 Allergan: C
 Kala: C
 Sun Pharmaceuticals: C
 Zeiss: C

Jack T Holladay MD MSEE FACS

Abbott Medical Optics: C
 AcuFocus Inc.: C,O
 Alcon Laboratories Inc.: C
 ArcScan: C,O
 Carl Zeiss Inc.: C
 Elenza: C,O
 M & S Technology: C
 Oculus Inc.: C
 RxSight Inc.: C,O
 Visiometrics: C,O

Osama I Ibrahim MD PhD

Carl Zeiss Inc.: C

Soosan Jacob FRCS

None

A John Kanellopoulos MD

A.R.C. Laser GmbH: C
 Alcon Laboratories Inc.: C
 Avedro: C
 Carl Zeiss Meditec: C
 KeraMed Inc.: C

Jennifer M Loh MD

Abbott Medical Optics Inc.: C
 Aerie Pharmaceuticals Inc.: L
 Allergan: C
 Novabay: L
 Shire: C,L
 Sun Ophthalmics: C,L

Ahad Mahootchi MD

Bausch + Lomb: C
 Ellex: C
 Imprimis: C,L
 Iridex: C,L
 New World Medical Inc.: C

Nick Mamalis MD

Aaren Scientific Inc.: S
 Advanced Vision Science: S
 Alcon Laboratories Inc.: S
 Anew Optics Inc.: C,S
 ClarVista: S
 CoDa Therapeutics: S
 Cord: S
 Genisphere: S
 Hoya: S
 LensGen: S
 Medicontur: S
 Mynosys: S
 Omega: S
 PerfectLens: S
 PowerVision: S
 Sharklet: S
 Shifamed: S
 Zeiss: S

Leonardo Mastropasqua MD

None

Marguerite B McDonald MD

Abbott: C
 Akorn Inc.: C
 Allergan: C
 Bausch + Lomb: C
 Bio-Tissue Inc.: C
 BlephEx: C
 Focus Labs: C
 Mallinckrodt Pharmaceuticals: C
 Oculus Inc.: C
 Shire: C

Jodhbir S Mehta MBBS PhD

Carl Zeiss Meditec: L,S
 Network Medical: P
 Santen Inc.: L
 Ziemer: L,S

Erik L Mertens MD FRACOPht

Allotex: C
 Capsulaser: C,O
 Medicem: C
 MicroSurgical Technology (MST): L
 Ophtec: L
 PhysiOL SA: C,L
 Staar Surgical: C
 Tearlab: L

Saman Nassiri MD

None

Mario Nubile MD

Carl Zeiss Meditec: L

Thomas A Oetting MD

None

Arturo J Ramirez-Miranda MD

Carl Zeiss Meditec: C,L,S
 Thea Laboratoires: C,L

J Bradley Randleman MD

None

Dan Z Reinstein MD

Arcscan Inc., Morrison, Colorado: O,P
 Carl Zeiss Meditec: C
 Optimo Medical AG: C
 Staar Surgical: C

Marcony R Santhiago MD

Alcon Laboratories Inc.: C,L
 Ziemer: C

Rohit Shetty MBBS

None

Sathish Srinivasan MBBS

AcuFocus Inc.: C
 Bausch + Lomb: C
 Medicontur: C
 Scope Ophthalmics: C

Pavel Stodulka MD PhD

Avedro, Inc.: C
 Bausch + Lomb: C

R Doyle Stulting MD PhD

Alcon Laboratories Inc.: C
 Avedro: C
 Calhoun Vision Inc.: C
 Cambium Medical Technologies: C
 CXL Ophthalmics: C
 EyeYon: C
 Hydrolenz: C
 Intelon: C
 Ocumetrics: C
 Ophtec: C
 Promisight: C
 TearLab: C

Vance Michael Thompson MD

AcuFocus Inc.: C,L,O
 Alcon Laboratories Inc.: C,L
 Allergan: C
 Allotex: C
 Bausch + Lomb: C
 Carl Zeiss Inc.: C
 Equinox: C,O
 Euclid Systems: C
 EyeBrain Medical Inc.: C,O
 Eyegate Pharma: C
 Imprimis: C
 Johnson & Johnson Vision: C
 Mynosys: C,O
 Oculeve: C
 Ophtec: C
 Precision Lens: C
 RxSight: C
 Tarsus Rx: C
 Treehouse Health: C,O

William B Trattler MD

Abbott Medical Optics: C,L
 Alcon Laboratories Inc.: C
 Allergan Inc.: C,L,S
 Alpheon: O
 ArcScan: O
 Avedro: L,O,C
 Bausch + Lomb: C,L
 CXLO: C,O
 CXLUSA: C
 Guardian Health: C,O
 Healthe: O
 LensAR: C
 Oculus Inc.: L
 Shire: C,L
 Sun: C,L
 Vmax Vision: C

John Allan Vukich MD

AcuFocus Inc.: C
 Carl Zeiss Inc.: C
 Johnson & Johnson: C
 Staar Surgical: C

Yumeng Wang MD PhD

None

George O Waring IV MD

Abbott Medical Optics Inc.: C,L
 ACE Vision Group: C
 AcuFocus Inc.: C,L
 Alcon Laboratories Inc.: C,L
 Allergan: C,L
 Avedro: C,L
 Bausch + Lomb: C,L
 Gerson Lehrman Group: C
 GlassesOff: C
 Glaukos Corp.: C,L
 Johnson & Johnson Vision: C,L
 Minosys: C
 Oasis Medical Inc.: C,L
 Oculus Inc.: L,C
 Omega Ophthalmics: C
 Perfect Lens LLC: C
 Refocus Group Inc.: C
 Strathpey Crown: O
 Visiometrics: C,O

William F Wiley MD

Abbott Medical Optics Inc.: C,L
 AcuFocus Inc.: C
 Alcon Laboratories Inc.: C,L
 Allergan: C
 Alpheon: O
 Calhoun Vision Inc.: S
 Cassini: C
 Equinox: C,O
 Iantech: C
 Imprimis: C,P
 Ivantis: C
 Lensar: C,L
 New World Medical Inc.: C
 Omega Lens: C
 Presbia: S
 Revision Optics: C
 Zeiss: C

Helen K Wu MD

Allergan: C
 Shire: C

Elizabeth Yeu MD

Alcon Laboratories Inc.: C,L
 Allergan: C,L
 ArcScan: C
 Bausch + Lomb: C
 Bio-Tissue Inc.: C,L
 Carl Zeiss Meditec: C,L
 Glaukos Corp.: C,L
 Innovation Labs: O
 iOptics: C,S
 Johnson & Johnson Vision: C,L
 Kala: C,S
 Katena Products Inc.: C
 Modernizing Medicine: O
 Novartis, Alcon Pharmaceuticals: C
 Ocular Science: C,O
 OcuSoft: C
 Omeros: L
 ScienceBased Health: C
 Shire: C,L
 Sight Sciences: C
 Sun Ophthalmics: L
 TearLab: C
 TearScience: C
 TissueTech Inc.: C,L
 Topcon Medical Systems Inc.: S
 TopCon: S

Presenter Index

Agarwal*, Amar 38
Ambrosio*, Renato 2
Ang*, Robert T 61
Batra*, Vineet N 49
Chang*, David F 44
Chang*, John So-Min 12
Chu*, Y Ralph 11
Cochener, Beatrice 53
Eldanasoury*, Alaa M 48
Fishkind*, William J 32
Gualdi*, Luca 59
Henderson*, Bonnie An 24
Holladay*, Jack T 25
Ibrahim*, Osama I 66
Jacob, Soosan 57
Kanellopoulos*, A John 21, 46
Mahootchi*, Ahad 45
Mamalis*, Nick 31
Mastropasqua, Leonardo 52
McDonald*, Marguerite B 1
Mehta*, Jodhbir S 10
Mertens*, Erik L 22
Nassiri, Saman 65
Nubile, Mario 54
Oetting, Thomas A 34
Ramirez-Miranda*, Arturo J 62
Randleman, J Bradley 63
Reinstein*, Dan Z 60, 64
Santhiago*, Marcony R 27
Shetty, Rohit 58
Stodulka*, Pavel 55
Stulting*, R Doyle 20
Thompson*, Vance Michael 30
Trattler*, William B 28
Vukich*, John Allan 5
Wang, Yumeng 56
Waring*, George O 14
Wiley*, William 13
Wu*, Helen K 26

Refractive Surgery ePosters and Break with the Experts

Refractive Surgery ePosters

Lakeside Center Lobby

View at the ePoster terminals or www.aao.org/mobile.

ePosters are not eligible for CME credit.

Break with the Experts

Hall D

Break with the Experts is not eligible for CME credit.

AM Session: 7:15 AM - 7:45 AM

PM Session: 3:10 PM - 3:55 PM

Refractive Surgery ePosters

Friday–Tuesday, Oct. 26–30

Lakeside Center Lobby

View at the ePoster terminals or www.aao.org/mobile.

ePosters are not eligible for CME credit.

Advances in Refractive Surgery

RP30057462	OCT-Guided, Femto-Assisted Micro-thin DSAEK: A High-Precision Endothelial Keratoplasty	Lional Raj Daniel Raj Ponniah MD	77
RP30057478	Comparison of Clinical Outcomes of Multifocal and Extended Depth-of-Focus IOLs in Post-Refractive Surgery Cataract Eyes	Neeraj Singh Chawla BS	77
RP30057491	Advanced Surface Ablation With a Irregularity-Reduction Software for the Treatment of Hyperopia	Paolo Vinciguerra MD	77
RP30057496	Conventional LASIK and Wavefront-Guided LASIK: Objective and Subjective Analysis	Ahmed A Abdou MD PhD	77
RP3005751	Optical Quality of 3 Trifocal IOL Models: An Optical Bench Comparison	Ramin Khoramnia MD	78
RP30057512	Visual Quality and Stereoacuity After Binocular Implantation of Extended-Range-of-Vision IOL	Jeewan S Titiyal MD	78
RP30057513	Comparative Evaluation of Visual Quality, Ocular Surface and Corneal Biomechanics With Small-Incision Lenticule Extraction and Femtosecond LASIK	Jeewan S Titiyal MD	78
RP30057516	Factors Predicting the Effect of TransPRK in Myopia: An 18-Month Study	Soheil Adib-Moghaddam	78
RP30057518	Changes in Higher-Order Aberrations Between Wavefront-Guided and Wavefront-Optimized PRK: A Prospective Study	Ryan Gregory Smith BA MD	79
RP30057524	Extending Depth of Focus With a Small-Aperture IOL	John Allan Vukich MD	79
RP30057537	Small-Aperture IOL in Irregular Corneas	Gabriel A Quesada Larez MD	79
RP30057556	Atomic Force Microscopy Analysis of the Corneal Stromal Roughness of a LASIK Flap Obtained With IntraLase vs. Visumax vs. LenSx	Miguel A Teus MD	79
RP30057563	Allograft-Based Intera Corneal Ring Segment for Treatment of Pellucid Marginal Degeneration	Mohammad Reza Jafarinasab MD	79
RP30057576	Distinguishing Eyes With Post-LASIK Ectasia Using Scheimpflug Analysis	Eric Hwang BS	80
RP30057578	Variable Shape and Energy Delivered, Topography-Customized Corneal Crosslinking: Five-Year Efficacy and Stability	A John Kanellopoulos MD	80
RP30057579	Topography Adjustment of Treated Cylinder vs. Using the Standard Clinical Refraction in Myopic Topo-guided LASIK	A John Kanellopoulos MD	80
RP30057582	Similarities and Differences of Longitudinal Corneal Epithelial Remodeling Over 2 Years in LASIK vs. Small-Incision Lenticule Extraction: A Contralateral Eye Study	Ioanna Kontari MD	80
RP30057583	Planned vs. Achieved Corneal Thickness Reduction in Myopic LASIK and Small-Incision Lenticule Extraction: A Contralateral Eye Study	Costas Karabatsas MD	80
RP30057584	Topography-Guided LASIK vs. Small-Incision Lenticule Extraction: Postoperative Digitized Centration Evaluation in Contralateral Eyes	Costas Karabatsas MD	81
RP30057585	Customized Corneal Crosslinking and Combined Topography-Guided Excimer Normalization for Keratoconus (Modified Athens Protocol)	Vasilis Skouteris MD	81

Complication Management

RP30057477	Analysis of Prolonged Corneal Interface Changes by Anterior Segment OCT After Explantation of a Shape-Changing Corneal Hydrogel Inlay	Saneha Kaur Chailert Borisuth	81
RP30057514	Double Edge Crescentic Separation in Cap-Lenticular Adhesion During Small-Incision Lenticule Extraction	Manpreet Kaur MD	81
RP30057531	Sulcus Implantation of Single-Piece Acrylic IOLs: Report of 5 Cases	Karime Perez Bailon MD	82
RP30057532	Auckland Cataract Study III: Refining Preoperative Assessment With Cataract Risk Stratification to Reduce Intraoperative Complications	Jina Han MBCHB	82
RP30057572	Managing Small-Incision Lenticule Extraction Complications: Smile More and Frown Less	Arturo J Ramirez-Miranda MD	82

The Journal of Refractive Surgery's Hot, Hotter, and Hottest—Late Breaking News

RP30057476	Corneal Collagen Crosslinking for Pediatric Keratoconus: Two-Year Data	Ronald N Gaster MD FACS	82
RP30057486	Reshaping and Customization of Small-Incision Lenticule Extraction–Derived Biological Lenticules for Implantation	Yu-Chi Liu MD	82
RP30057495	Femtosecond-Assisted Crosslinking vs. Conventional Crosslinking: Proof of Concept of “The Deeper, the Better”	Lional Raj Daniel Raj Ponniah MD	83
RP30057500	Comparison of Visual Outcomes and Complications of Posterior Chamber Phakic IOL With and Without a Central Hole Implantation for Correction of High Myopia and Myopic Astigmatism	Seyed Javad Hashemian MD	83
RP30057504	Analysis of Different Approaches to Enhance Range of Vision: Functional Results, Patient Satisfaction, Disphotopic Phenomena	Florian T A Kretz MD	83
RP30057505	Comparison of Visual Quality, Photopic Phenomena, and Patient Satisfaction in Different Presbyopia-Correcting Multifocal IOLs	Florian T A Kretz MD	83
RP30057506	Does the Bowman Layer Influence Corneal Biomechanics?	Emilio A Torres Netto MD	84
RP30057507	PACK-CXL Multicenter Trial: Preliminary Results	Emilio A Torres Netto MD	84
RP30057508	Prospective Comparative Study of Phakic IOL vs. Intacs Corneal Rings to Manage Anisometropic Myopic Amblyopia in Children	Mohamed M K Diab MD	84
RP30057510	Opacification of Hydrophilic IOL Material After Intraocular Gas or Air Injection	Ramin Khoramnia MD	84
RP30057528	The Visual Acuity Range of Eyes Implanted With Monofocal IOLs	Yaqin Jiang MD	84
RP30057534	Influence of Induced Astigmatism in Eyes Implanted With Small-Aperture and Trifocal IOLs	Robert Edward T Ang MD	85
RP30057535	Visual and Refractive Outcomes Following Cataract Surgery With a Small-Aperture IOL in Eyes With Previous Radial Keratotomies	Sathish Srinivasan MBBS	85
RP30057536	Posterior Segment Visualization in Eyes With Small-Aperture IOLs	Sathish Srinivasan MBBS	85
RP30057538	Visual Outcomes Comparison of Small-Aperture, Accommodating, and Multifocal IOLs	Jay Stuart Pepose MD PhD	85
RP30057541	Circle Enhancement After Small-Incision Lenticule Extraction: A Retrospective Study on Efficacy	Stine Funder Jespersen MD	85
RP30057546	Effectiveness and Safety of Combining LASIK and Corneal Inlay Implantation: Four-Year Follow-up	Mitsutoshi Ito MD PhD	86
RP30057549	Patient-Reported Refractive Surgery Outcomes in Contact Lens and Eyeglass Wearers	Rose Kristine C Sia MD	86
RP30057567	Enhancement Options After Small-Incision Lenticule Extraction: An Overview of Different Techniques	Moones Fathi Abdalla MD	86
RP30057569	Combined Phacoemulsification and Intravitreal Bevacizumab Injection for Prophylaxis of Macular Edema in Diabetic Patients	Ashraf H El Habbak MD	86

RP30057577	Outcome of Transepithelial PRK for High Myopia With High-Speed Excimer Laser and Advanced Laser Beam Profile	Simon P Holland MD	86
RP30057580	Effect of Curvature Gradient Between Treated and Untreated Corneas in Myopic Surface Ablation	Wen Zhou MD MS	87
RP30057581	Outcomes of Bilensectomy Following Iris Claw and Posterior Chamber Phakic IOL Surgery	Jorge L Alió MD PhD	87
RP30057587	Multifocal IOL Exchange by a Different Multifocal Technology: Is It Feasible?	Jorge L Alió MD PhD	87
RP30057589	Combined Flapless Refractive Lenticule Extraction (SMILE) and Intrastromal Corneal Crosslinking in Patients With Suspicious Topography and/or Thin Corneas: Refractive and Biomechanical Outcomes	Moones Fathi Abdalla MD	87
RP30057590	Achieving Refractive Perfection Using Multicomponent IOLs	Harvey S Uy MD	87
RP30057597	Two-Year Result of Topography-Guided PRK With Crosslinking for Keratoconus With High-Speed Laser	Murad M Al Obthani MBBS	88
RP30057598	Quality of Vision in 2 Different Military Occupational Populations	Bruce A Rivers MD	88
RP30057600	Refractive Surgery Symptoms Experienced and Limitations on Activity in LASIK and Surface Ablations	Denise Ryan COA MS	88
RP30057602	Topography-Guided PRK for Correction of Irregular Astigmatism Following Penetrating Keratoplasty	Murad M Al Obthani MBBS	88
RP30057603	Outcomes of Phototherapeutic Keratectomy vs. Topography-Guided PRK for Keratoconus With Crosslinking	David T C Lin MD	89
RP30057605	Comparison of Combined High-Fluence Corneal Crosslinking Stabilization With Penetrating Keratoplasty and Partial Topography-Guided Excimer Laser Normalization in the Management of Progressive Keratoconus: Cretan Protocol vs. Athens Protocol	Mariana Almeida Oliveira MD	89
RP30057606	Post-LASIK Ectasia Treated by Topography-Guided PRK and Crosslinking Using a New High-Speed Laser	Simon P Holland MD	89
RP30057607	Corneal Stromal Demarcation Line Depth in 2 Different Pulsed Accelerated Corneal Crosslinking Protocols in Patients With Progressive Keratoconus	Julio Hernandez Camarena MD	89
RP30057609	Topography-Guided PRK for Irregular astigmatism After Radial Keratotomy Using a High-Speed Laser	Albert T Coverley MD	90
RP30057610	Comparison of Outcomes With Standard and Accelerated Corneal Crosslinking Protocols for Progressive Keratoconus	J Bradley Randleman MD	90

ePoster Abstracts

Advances in Refractive Surgery

OCT-Guided, Femto-Assisted Micro-thin DSAEK: A High-Precision Endothelial Keratoplasty

Abstract #: RP30057462

Senior Author: *Lional Raj Daniel Raj Ponniah MD*

Purpose: To evaluate OCT-guided, femto-assisted, micro-thin DSAEK and to compare with ultrathin (UT)-DSAEK, Descemet membrane EK (DMEK), and DSAEK. **Methods:** Micro-thin, OCT-guided femto-dissected EK graft was transplanted after DM stripping. Vision, central corneal thickness (CCT), specular and postop anterior segment OCT for graft thickness and interface study, compared with DSAEK, UT-DSAEK, and DMEK. **Results:** $n = 19$. At 6 months, BCVA improved (0.72 to 0.11 logMAR) comparable to DMEK and UT-DSAEK and better than DSAEK. CCT: 554.32 ± 11.40 . Graft thickness was 68.47 ± 8.52 mic vs. 63 ± 29 in UT-DSAEK, $164\text{--}234$ in DSAEK, 20 in DMEK. Spherical error was -0.10 ± 0.47 D. No graft loss, detachments, or rejections were seen, and had excellent interfaces. **Conclusion:** Femto-DSAEK is effective, reproducible with good outcomes, better than DSAEK, comparable to UT-DSAEK and DMEK, and with excellent interfaces.

Comparison of Clinical Outcomes of Multifocal and Extended-Depth-of-Focus IOLs in Post-Refractive Surgery Cataract Eyes

Abstract #: RP30057478

Senior Author: *Neeraj Singh Chawla BS*

Coauthors: *Sanaha Kaur Chailert Borisuth and Navaneet S C Borisuth MD PhD*

Purpose: To compare the clinical results of extended-depth-of-focus (EDOF) IOL implantation to that of multifocal (MF) IOLs in post-refractive surgery (RS) eyes undergoing phacoemulsification (PE). **Methods:** Single-surgeon retrospective analysis of 53 eyes of 45 RS patients (31 myopic RS eyes and 22 hyperopic RS eyes) undergoing PE with EDOF (22 eyes) and MF (31 eyes). **Results:** There were 49 PRK and LASIK eyes, 3 conductive keratoplasty eyes, and 1 radial keratotom eye. Seventy-two percent of eyes were within ± 0.50 D, and 98% were within ± 1.0 D. In the EDOF and MF groups, mean uncorrected distance visual acuity (UDVA) was logMAR 0.08 ± 0.09 and 0.10 ± 0.12 , respectively ($P = .38$). Mean uncorrected near visual acuity (UNVA) was logMAR 0.14 ± 0.09 and 0.07 ± 0.09 , respectively ($P = .003$). Four patients (12.9%) in the MF group and 3 patients (13.6%) in the EDOF group required excimer laser enhancement after PE. **Conclusion:** In RS eyes undergoing PE with MF lenses, UNVA was statistically better than with EDOF lenses. There was no statistical difference in UDVA between the two groups.

Advanced Surface Ablation With Irregularity-Reduction Software for the Treatment of Hyperopia

Abstract #: RP30057491

Senior Author: *Paolo Vinciguerra MD*

Coauthors: *Fabrizio I Camesasca MD, Riccardo Vinciguerra MD, Samuel Arba Mosquera, and Ingrid Torres MD*

Purpose: We evaluated advanced surface ablation (ASA) with irregularity-reduction software (SPT) in the treatment of hyperopia. **Methods:** We retrospectively studied eyes that underwent transepithelial ASA with SPT for hyperopia. **Results:** Seventy eyes of 37 patients were evaluated. Mean preoperative VA was 0.06 ± 0.88 logMAR, with $+2.92$ D ± 1.15 D sph ($+5.50$ D to $+1.00$ D) and -1.38 D ± 1.39 D cyl (0.00 D to -5.00 D). At 6 months, UCVA was 0.05 ± 0.82 and BCVA, 0.02 with -0.20 D ± 0.35 D sph and -0.22 D ± 0.34 D cyl. Final uncorrected distance VA was the same as or better than preoperative BCVA in 80% of eyes. Spherical aberration increased, RMS decreased significantly. **Conclusion:** ASA with SPT is an effective method for hyperopia treatment.

Conventional LASIK and Wavefront-Guided LASIK: Objective and Subjective Analysis

Abstract #: RP30057496

Senior Author: *Ahmed A Abdou MD PhD*

Coauthors: *Ahmed F Omar MD, Hazem Abdelmotaal Hazem IV MD, Gamal Nouby MD PhD, Mahmoud M Ismail MD PhD, and Mohamed Abdelrahman MD*

Purpose: To analyze visual function and patient satisfaction after conventional and wavefront-guided (WFG) LASIK. **Methods:** Prospective case series study of 68 eyes that underwent LASIK for myopic astigmatism (35 conventional vs. 33 WFG). Objective analysis was done for higher-order aberrations (HOAs) and uncorrected distance visual acuity (UDVA). Night vision and patient satisfaction questionnaire was conducted. **Results:** Total RMS was higher in conventional group vs. the WFG group (0.702 ± 0.199 vs. 0.399 ± 0.184 ; $P < .05$). There was significant increase in postop UDVA after 3 months in comparison to the preop CDVA in the WFG group (0.209 ± 0.142 ; $P < .05$). As for sharpness, night vision, contrast sensitivity, and overall visual comfort: 11.4% were highly satisfied in the first group while 69.7% were highly satisfied in the second group ($P < .05$). **Conclusion:** WFG LASIK is more satisfactory for LASIK patients with a better HOA profile.

Optical Quality of 3 Trifocal IOL Models: An Optical Bench Comparison

Abstract #: RP30057511

Senior Author: Ramin Khoramnia MD

Coauthors: Timur Yildirim MD, Tamer Tandogan MD, Stephanie Liebing, Grzegorz Labuz PhD, Chul Young Choi MD, Hyeck-Soo Son MD, and Gerd U Auffarth MD

Purpose: To analyze the optical quality of 3 different trifocal IOLs. **Methods:** We analyzed the FineVision (PhysIOL; Belgium), the AT LISA tri 839MP (Zeiss; Germany), and the AcrySof IQ PanOptix (Alcon; USA) at the OptiSpheric optical bench (Trioptics). We evaluated the modulation transfer function (MTF) at a spatial frequency of 50 lp/mm, the trough focus scan, and the Strehl ratio using a 3-mm and 4.5-mm aperture. **Results:** The Strehl ratio (FineVision / AT Lisa / PanOptix) was 0.335 / 0.298 / 0.370 (3-mm aperture) and 0.243 / 0.180 / 0.270 (4.5-mm aperture) at the far focus. At the intermediate focus, the Strehl ratio was 0.189 / 0.185 / 0.162 (3-mm aperture) and 0.099 / 0.097 / 0.114 (4.5-mm aperture). At the near focus, the Strehl ratio was 0.305 / 0.283 / 0.464 (3-mm aperture) and 0.177 / 0.181 / 0.155 (4.5-mm aperture). **Conclusion:** Assessment of the 3 trifocal IOL models at the optical bench could show distinct peaks at the far, intermediate, and near focus. The performance was comparable.

Visual Quality and Stereoacuity After Binocular Implantation of Extended-Range-of-Vision IOL

Abstract #: RP30057512

Senior Author: Jeewan S Titiyal MD

Coauthors: Manpreet Kaur MD, Neha Bharti, and Namrata Sharma MD MBBS

Purpose: To evaluate visual quality and stereopsis after bilateral implantation of extended-range-of-vision (ERV) IOL. **Methods:** Prospective interventional study of 50 eyes (25 patients) implanted with ERV IOL after phacoemulsification. Primary outcome measures were visual quality (assessed by iTRACE) and stereopsis (distance and near Randot). Secondary outcome measures were visual acuity and patient satisfaction. Follow-up was performed on Day 1 and at 1, 3, 6, and 12 months. **Results:** At 1 year, mean distance and near stereopsis were $111.1 \pm 73.7'$ arc and $23.1 \pm 5.5'$ arc, respectively. Mean modulation transfer function was 0.53 ± 0.17 , Strehl ratio was 0.03 ± 0.02 , and coma was 0.35 ± 0.27 . Patient satisfaction score was 8.8 ± 1.2 , with 97% of patients reporting spectacle independence. Binocular distance, intermediate, and near visual acuities (decimal) were 0.97 ± 0.28 , 0.76 ± 0.13 , and 0.47 ± 0.08 , respectively. **Conclusion:** ERV IOL provides good visual quality, stereopsis, and spectacle independence over a wide range of distance.

Comparative Evaluation of Visual Quality, Ocular Surface and Corneal Biomechanics With Small-Incision Lenticule Extraction and Femtosecond LASIK

Abstract #: RP30057513

Senior Author: Jeewan S Titiyal MD

Coauthors: Anand Singh Brar MBBS, Manpreet Kaur MD, and Namrata Sharma MD MBBS

Purpose: To compare visual and anatomical outcomes of femtosecond LASIK (FS-LASIK) and small-incision lenticule extraction (SMILE) in moderate-high myopia. **Methods:** Prospective, comparative evaluation of 80 eyes undergoing FS-LASIK ($n = 40$) or SMILE ($n = 40$). Primary outcome measures were visual acuity and quality. Secondary outcome measures were ocular surface stability, corneal biomechanics, and sub-basal nerve fiber density (SNFD). Follow-up was performed on Days 1 and 30 and at 6 months. **Results:** At 6 months, UCVA was comparable in both groups ($P = .65$). Visual quality (higher-order aberrations) was significantly better with SMILE ($P < .001$). Tear-film breakup time ($P < .001$), Schirmer test ($P = .02$), and SNFD ($P < .001$) were significantly better in the SMILE group at all follow-up visits. Ocular hysteresis was better in the SMILE group ($P < .001$). **Conclusion:** SMILE leads to better visual quality, ocular surface, and biomechanical stability as compared with FS-LASIK.

Factors Predicting the Effect of TransPRK in Myopia: An 18-Month Study

Abstract #: RP30057516

Senior Author: Soheil Adib-Moghaddam

Coauthors: Saeed Soleiman-Jahi MD MPH, Ghazzale Tefagh MD, Marjan Razi-Khosroshahi, and Ali A Haydar MD

Purpose: To assess photopic (P) and mesopic (M) contrast sensitivity (CS) in myopia in TransPRK and its predicting factors. **Methods:** The Schwind Amaris 500 was used. Hosmer-Lemeshow test was applied to study effects of surgical and visual parameters on postop PCS and MCS. **Results:** PCS and MCS improved significantly, 0.96 and 1.21 to 0.82 ($P = .0015$) and 0.96 ($P = .002$) at 6 months postop. Based on postop PCS linear regression models, these predictors were made ($P < .001$): preop PCS (coefficient: 0.12 deteriorating [D]), transition zone (TZ) (0.27 D), optical zone (OZ) (0.3 improving [I]), and postop coma (0.3 D). Postop MCS matching model denoted that postop PCS (0.94 D; $P < .001$), ablation zone (AZ) (0.15 I; $P = .017$), TZ (0.13 D; $P = .047$), and pupil diameter (PD) (0.004 D; $P = .001$) were independent predictors. **Conclusion:** TransPRK significantly improves MCS and PCS in myopia.

Changes in Higher-Order Aberrations Between Wavefront-Guided and Wavefront-Optimized PRK: A Prospective Study
Abstract #: RP30057518

Senior Author: Ryan Gregory Smith BA MD

Coauthor: Edward E Manche MD

Purpose: To compare higher-order aberration outcomes in myopes using 2 different laser platforms for PRK. **Methods:** Forty eyes from 20 patients were prospectively randomized to receive wavefront-guided (WFG) vs. wavefront optimized (WFO) PRK with the WaveLight Allegretto Eye-Q 400-Hz excimer laser (Alcon, Inc.). Coma, trefoil, spherical aberration, RMS error, and astigmatism were recorded preoperatively and at 1, 3, 6, and 12 months. Subjective quality of vision was evaluated using a validated, Rasch-tested, linear-scaled 30-item quality of vision (QoV) questionnaire preoperatively and at 12 months. **Results:** There was no statistical significance ($P > .05$) between the WFO and WFG PRK groups in measured higher-order aberrations at 1, 3, 6, or 12 months postoperatively or in measured QoV preoperatively or at 1-year postoperative follow-up. Both groups showed statistically significant improvements in multiple visual symptoms. **Conclusion:** WFO and WFG PRK provided similar results in higher-order aberrations and self-reported visual symptoms in myopic patients.

Extending Depth of Focus With a Small-Aperture IOL

Abstract #: RP30057524

Senior Author: John Allan Vukich MD

Purpose: To describe the visual performance of subjects implanted with a small-aperture IOL. **Methods:** Prospective, open label, nonrandomized, multicenter, post-market clinical study. Uncorrected distance (UDVA), intermediate (UIVA), and near (UNVA) visual acuities, defocus curves, and patient-reported outcomes are reported on 105 subjects at 6 months. **Results:** UDVA, UIVA, and UNVA in the IC-8 eyes were 20/23, 20/24, and 20/30, respectively. Ninety-nine percent, 95%, and 79% of subjects achieved 20/32 or better binocular UDVA, UIVA, and UNVA, respectively; 95.9% of subjects reported they would have the procedure again. Tolerance for up to 1.50 D of cylinder was evident in vision performance. **Conclusion:** IOL shows excellent visual performance and patient satisfaction at 6 months.

Small-Aperture IOL in Irregular Corneas

Abstract #: RP30057537

Senior Author: Gabriel A Quesada Larez MD

Coauthors: Kevin Lee Waltz MD and Rodrigo A Quesada MD

Purpose: Changes in corneal shape after radial keratotomy (RK), penetrating keratoplasty (PKP), and keratoconus make it more challenging to pick the right IOL power; the small-aperture IOL presents an opportunity in these cases. **Methods:** Case reports: (1) after RK, (2) after PKP, and (3) in keratoconus. **Results:** Case 1: 68-year-old. Sixteen RK cuts. RE: BCVA 20/100, K1 28.92, K2 33.32. LE: BCVA 20/80, K1 32.52,

K2 34.34. IOL +18.0 both eyes. Postop VA 20/40 distance, intermediate, and near. Case 2: 56-year-old. PKP LE: BCVA 20/200, K1 35.85, K2 44.79. IOL +19.0. Postop VA 20/60. Case 3: 57-year-old. Keratoconus LE; BCVA 20/100, K1 43.32, K2 48.89. IOL +18.5. Postop VA 20/50. **Conclusion:** For irregular / unstable corneas, the small-aperture IOL can extend the depth of focus and provide excellent quality of vision, without side effects or intolerance to residual refractive error.

Atomic Force Microscopy Analysis of the Corneal Stromal Roughness of a LASIK Flap Obtained With IntraLase vs. Visumax vs. LenSx

Abstract #: RP30057556

Senior Author: Miguel A Teus MD

Coauthors: Juan Gros-Otero MD, Rafael Canones-Zafra MD, Montserrat Garcia-Gonzalez MD, and Alberto Parafita MD

Purpose: To compare the stromal roughness measured with atomic force microscopy (AFM) after a LASIK flap obtained with 3 femtosecond lasers (FSL). **Methods:** Experimental study using 9 enucleated porcine eyes, 3 with each FSL platform. We measured the stromal bed roughness with a JPK NanoWizard II AFM in contact mode. Measurements were made on 10 areas of 20 μm x 20 μm of the central stromal bed of each sample. We evaluated the surface roughness using the root-mean-square (RMS) deviation from a perfectly flat surface value, within the analyzed area. **Results:** The stromal bed roughness was 230 ± 100 nm for Visumax, 370 ± 100 nm for LenSx, and 360 ± 120 nm for IntraLase. The smoothest stromal bed surface was obtained with Visumax, which was statistically significantly different from the other groups ($P < .05$). **Conclusion:** The stromal bed roughness is different depending on the FSL used. Visumax is the one that obtains the smoothest surface among the FSLs analyzed in this study.

Allograft-Based Intera Corneal Ring Segment for Treatment of Pellucid Marginal Degeneration

Abstract #: RP30057563

Senior Author: Mohammad Reza Jafarinasab MD

Purpose: To evaluate refractive and visual outcomes of allograft-based Intera corneal ring segment (AGB-ICRS) for treatment of pellucid marginal degeneration (PMD). **Methods:** In 3 eyes with PMD, we impaneled a crescent-shaped, dried AGB-ICRS that was prepared by eye bank as ordered by the author. Before implantation we created a FLA canal in the cornea's stroma. The width of the canal measured 3.0 mm (5.5 to 8.5 mm from VAX), and the widest part of crescent measured 3 mm. The dried method leads to faster and easier implantation of the crescent. **Results:** Irregular astigmatism and refractive error were reduced in all 3 eyes; in addition, UCVA and BCVA increased in all eyes. **Conclusion:** AGB-ICRS is an alternative to PMMA-ICRS, with some benefits. The dried method causes faster and easier crescent implantation.

Distinguishing Eyes With Post-LASIK Ectasia Using Scheimpflug Analysis

Abstract #: RP30057576

Senior Author: Eric Hwang BS

Coauthors: J Bradley Randleman MD

Purpose: To evaluate Scheimpflug and clinical parameters to distinguish eyes with ectasia after LASIK from normal post-LASIK controls. **Methods:** Scheimpflug imaging was evaluated, and receiver operating characteristic curves were generated to determine area under the curve (AUC) for each variable. Logistic regression analysis was performed to combine variables. **Results:** In 43 ectasia and 920 control eyes, no individual Scheimpflug metric yielded an AUC > 0.77. Combining 11 Scheimpflug and clinical metrics (age, pachymetry min and apex, index of surface asymmetry, index of height decentration, IS-value, estimated residual bed thickness, BADD, ARTmax, thickness standard deviation, and curvature standard deviation), the maximum achievable yielded AUC 0.957. **Conclusion:** Individual Scheimpflug metrics poorly distinguished the two populations, while a combination of age, residual bed thickness, anterior curvature, pachymetric, and posterior surface metrics effectively distinguished the populations.

Variable Shape and Energy Delivered, Topography-Customized Corneal Crosslinking: Five-Year Efficacy and Stability

Abstract #: RP30057578

Senior Author: A John Kanellopoulos MD

Purpose: Variable shape and energy delivered (ED), topography-customized (TG) corneal crosslinking (CXL): 5-year efficacy and stability. **Methods:** Thirty-two consecutive poorly sighted eyes of 18 patients underwent TG-CXL. UV pattern included 3 areas of energy delivery of 15, 10, and 5 Joules, of 30 mW/cm² fluence. We evaluated age, acuity, autorefractive (aSE), endothelial cell density (ECD), Placido topography (PT), and Scheimpflug (S) and OCT tomography parameters for a mean of 3.8 years (3 to 4.2). **Results:** Mean age: 68.5, and changes: aSE, -2.5 D to -0.9 D; steepest OCT keratometry, 45.5 ± 3.71 D to 43.5 ± 1.81 D, similar with PT and S; ECD, 1850 to 1750 cells/mm², CXL OCT line effect was in average 30% depth. There were 2 cases with no recordable effect. **Conclusion:** TG-CXL appears to be safe, with variable efficacy. It may become an alternative in the management of low myopia without cornea incision or ablation.

Topography Adjustment of Treated Cylinder vs. Using the Standard Clinical Refraction in Myopic Topo-guided LASIK

Abstract #: RP30057579

Senior Author: A John Kanellopoulos MD

Purpose: To compare 50% and 100% topography-modified refraction (TMR) to the standard clinical refraction (SCR) in myopic LASIK. **Methods:** This prospective, randomized contralateral-eye study included 260 eyes: 1 eye of each patient was randomized to be treated with TMR either 50% (Group A) or 100% (Group B); the contralateral eye (Group C) was treated with the SCR. The 3-month perioperative visual performance and refractive data were compared for all groups. **Results:** Mean values: UDVA: Group A was 20/18; Group B, 20/16; and Group C, 20/20. CDVA: 20/16.75, 20/13.5, and 20/20, respectively. One line of vision gained: 41.7%, 55.6%, and 27.8%. Two

lines of vision gained: 8.7%, 11.1%, and 5.6%, respectively. In Group A, 17.7% of eyes had over -0.50 D of residual refractive astigmatism, 11.7% in Group B ($P < .01$), and 27.8% in Group C ($P < .01$). All values were statistically significantly different when Group A was compared to Group B. **Conclusion:** 100% TMR appears to be superior to partial TMR adjustment of the SCR.

Similarities and Differences of Longitudinal Corneal Epithelial Remodeling Over 2 Years in LASIK vs. Small-Incision Lenticule Extraction: A Contralateral Eye Study

Abstract #: RP30057582

Senior Author: Ioanna Kontari MD

Coauthor: A John Kanellopoulos MD

Purpose: To compare 3D epithelial remodeling in patients undergoing myopic laser vision correction, between two intra-stromal techniques. **Methods:** In a prospective randomized contralateral eye study of LASIK vs. SMILE procedures, 42 eyes were evaluated with 6 mm corneal epithelial mapping by AS-OCT preoperatively, up to 2 years follow-up. Zonal epithelial thickness was recorded including the epithelium thickness of the central region of 2 mm diameter, maximum, minimum, and epithelial thickness variation. **Results:** LASIK group: Average CET increased from 52.38 ± 2.57 µm preop up to 57 ± 4.23 µm in the first 3 months and remained stable for up to 24m postoperatively. SMILE group: The CET increased from 52.52 ± 3.01 µm preop up to 57.15 ± 4.57 µm in 3m and remained stable for up to 24m. The minimum thickness in 3, 6, and 12 months postoperatively were found statistically significant. **Conclusions:** Both LASIK and SMILE resulted in significant central epithelial increase and larger mid-peripheral, in a period of 24 months postoperatively.

Planned vs. Achieved Corneal Thickness Reduction in Myopic LASIK and Small-Incision Lenticule Extraction: A Contralateral Eye Study

Abstract #: RP30057583

Senior Author: Costas Karabatsas MD

Coauthor: A John Kanellopoulos MD

Purpose: To compare planned and achieved corneal stromal thickness reduction in topography-guided LASIK and small-incision lenticule extraction (SMILE) surgery in a contralateral eye study. **Methods:** Stromal thickness reduction was retrospectively investigated in 22 myopic patients: one eye was treated with the topo-guided LASIK, and the contralateral eye with the SMILE. OCT was employed to provide preop and postop pachymetry maps. Corneal thickness change was evaluated as the difference between minimum thickness in pre- to post-pachymetry. **Results:** Postop stromal reduction was on average 87.59 ± 29.45 µm, compared to the average programmed maximum ablation depth of 89.09 ± 25.41 µm for topo-guided LASIK and 84.91 ± 20.7 µm; 108.5 ± 22.98 µm for the SMILE cases, respectively. **Conclusion:** Actual objective corneal thickness reduction following topography-guided LASIK is more accurate than SMILE, as it correlates better with the attempted vs. the achieved refractive change.

Topography-Guided LASIK vs. Small-Incision Lenticule Extraction: Postoperative Digitized Centration Evaluation in Contralateral Eyes

Abstract #: RP30057584

Senior Author: *Costas Karabatsas MD*

Coauthor: *A John Kanellopoulos MD*

Purpose: To objectively define the effective centration of myopic LASIK ablation pattern and evaluate the difference between achieved and planned laser ablation centration. **Methods:** In 21 consecutive patients, one randomized eye had topography-guided (TG)-LASIK and the contralateral had small-incision lenticule extraction (SMILE). Digital image analysis was performed on Scheimpflug sagittal curvature maps. Centration was assessed via proprietary software digital analysis of the coordinate displacement between the achieved ablation geometric center and the planned ablation center, which was the corneal vertex. **Results:** Radial displacement was calculated for the LASIK group vs. SMILE on average: $458 \pm 265 \mu\text{m}$ vs. $699 \pm 373 \mu\text{m}$. IHD: 0.0095 ± 0.0062 vs. 0.0106 ± 0.0062 preoperatively and 0.0142 ± 0.0113 vs. 0.0225 ± 0.0099 postoperatively. Ocular scatter index (OSI) was almost the same preoperatively, while postoperatively OSI was 1.40 ± 1.39 vs. 1.14 ± 0.82 . **Conclusion:** Results presented showed that during LASIK treatment, the ablation centration is more accurate than in cases of SMILE.

Customized Corneal Crosslinking and Combined Topography-Guided Excimer Normalization for Keratoconus (Modified Athens Protocol)

Abstract #: RP30057585

Senior Author: *Vasilis Skouteris MD*

Coauthor: *A John Kanellopoulos MD*

Purpose: Safety and efficacy of this novel technique. **Methods:** 25 cases of 16 consecutive patients were evaluated perioperatively. Variable fluence and customized pattern customized corneal crosslinking (cCXL) was combined following topography-guided excimer normalization (tPRK) of max 40 μm . **Results:** Mean value changes from preop to 12 months postop: UDVA, 20/80 to 20/35; CDVA, 20/60 to 20/25; topographic max keratometry flattening, 7.8 D; IHD, 158 to 47. No adverse effect was noted besides delayed epithelial healing in 9, while all cases did not demonstrate progression. **Conclusion:** Combined cCXL and tPRK appears to offer increased visual rehabilitation with less tissue removal in keratoconus stabilization and visual rehabilitation.

Complication Management

Analysis of Prolonged Corneal Interface Changes by Anterior Segment OCT After Explantation of a Shape-Changing Corneal Hydrogel Inlay

Abstract #: RP30057477

Senior Author: *Sanaha Kaur Chailert Borisuth*

Coauthors: *Neeraj Singh Chawla BS and Navaneet S C Borisuth MD PhD*

Purpose: To describe the evolution of corneal interface haze and the clinical outcomes after explantation of a shape-changing corneal hydrogel inlay in 5 patients. **Methods:** Single-surgeon case series of serial spectral-domain OCT (AS-OCT) scans performed over a 6-month period on 5 eyes before and after corneal inlay explantation. **Results:** Five eyes out of a total of 30 eyes with a shape-changing corneal hydrogel inlay required explantation for recurrent haze despite multiple rounds of steroid treatment (2 eyes), ineffective presbyopic outcome (2 eyes), and decentration (1 eye). All eyes achieved a BDVA of 20/25 or better by 3 months. One patient had a persistent cast of the hydrogel inlay in the interface for 6 months after explantation, which demonstrated increased corneal optical intensity on AS-OCT. **Conclusion:** Explantation of a shape-changing corneal inlay has a good visual outcome but can be associated with structural interface changes that lag the visual outcome recovery.

Double Edge Crescentic Separation in Cap-Lenticular Adhesion During Small-Incision Lenticule Extraction

Abstract #: RP30057514

Senior Author: *Manpreet Kaur MD*

Coauthors: *Jeewan S Titilal MD, Farin Rajmohmad Shaikh Jr FRCS MD, and Anand Singh Brar MBBS*

Purpose: To describe a modified technique of lenticule extraction in cases with cap-lenticular adhesion (CLA) during small-incision lenticule extraction (SMILE). **Methods:** Diagnosis of CLA was confirmed by observing a meniscus-shaped gap on nudging the underside of the cap with a Sinskey hook. The Sinskey hook was then used to separate the lenticule from the overlying cap for 3 clock hours each along the right and left edges, and a crescentic gap was created along both edges. The lenticule was peeled off with microforceps till midline from both edges and extracted in a circumferential manner. **Results:** The technique was used to successfully extract the refractive lenticule in 7 eyes with CLA. No case developed retained lenticule fragments, lenticule, cap or side cut tear. **Conclusion:** In cases with CLA, separating the lenticule edge from the cap at both edges and peeling off the lenticule in a segmental fashion helps in smooth extraction of the lenticule.

Sulcus Implantation of Single-Piece Acrylic IOLs: Report of 5 Cases

Abstract #: RP30057531

Senior Author: *Karime Perez Bailon MD*

Coauthors: *Wendolyn Ramirez Estrada MD, Ricardo Chavez Sanchez MD, and Ana Isabel Ortiz*

Purpose: To present 5 patients who underwent phacoemulsification surgery and had posterior capsule rupture during surgery. We had to place a single-piece acrylic IOL (SPA IOL) into the ciliary sulcus. **Methods:** The cases of 5 patients who had the SPA IOL placed in sulcus were reviewed for pre- and postoperative visual acuity, postoperative refraction, IOP, inflammation, and centration. **Results:** Average postoperative acuity was 20/50; average BCVA was 20/25. The mean manifest refraction was -0.9 D. The longest follow-up is 2 years. None of the patients has IOL displacement, uveitis, glaucoma, or further complications. **Conclusion:** The placement of SPA IOL lenses into the ciliary sulcus seems to be a viable option when needed.

Auckland Cataract Study III: Refining Preoperative Assessment With Cataract Risk Stratification to Reduce Intraoperative Complications

Abstract #: RP30057532

Senior Author: *Jina Han MBChB*

Coauthors: *Dipika V Patel PhD MRCOphth, Henry B Wallace, Bia Kim MbChB MD, Trevor Sherwin PhD, and Charles McGhee FRCOphth FRANZCO PhD*

Purpose: To assess intraoperative complications of phacoemulsification cataract surgery in public teaching hospital settings using a modified preoperative risk stratification system. **Methods:** Preoperative risk stratification of 500 cases using the New Zealand Cataract Risk Stratification (NZCRS) system, with allocation of high-risk cases to senior surgeons. Main outcome measure: intraoperative complications. **Results:** NZCRS classified 192 cases (38%) as high risk, allocated to Fellows or Attendings. Primary surgeon was Residents in 28%, Fellows in 18%, Attendings in 54% of cases. Overall ($N = 500$) intraoperative complication rate was 5.0%. In "nonadherence" ($n = 52$, Residents performing high-risk cases), complications nearly doubled (9.6%). Overall complications were reduced by 40% (8.4% to 5%), posterior capsular tear rates were reduced from 2.6% to 0.6% (compared to baseline group, $N = 500$). **Conclusion:** Risk stratification appears to reduce intraoperative complications in a public teaching hospital setting.

Managing Small-Incision Lenticule Extraction Complications: Smile More and Frown Less

Abstract #: RP30057572

Senior Author: *Arturo J Ramirez-Miranda MD*

Coauthors: *Alejandro Navas MD and Enrique O Graue Hernandez MD*

Purpose: To report the complications associated with small-incision lenticule extraction (SMILE). **Methods:** Retrospective review of consecutive clinical case series. **Results:** The study enrolled 460 eyes of 231 patients with mean follow-up of around 72 months. In this series, which includes the surgeons' learning curve cases, 7% presented surgical complications, including epithelial defect, suction loss, opaque bubble layer, cap rupture, lenticule rupture, interface haze, residual refractive errors, and infectious keratitis. **Conclusion:** While SMILE complications can occur, most are related to inexperience and are

included in the learning curve of the technique, with favorable resolution, because the majority of them are mild and have no lasting effect on the patient's final visual acuity.

Journal of Refractive Surgery: Late Breaking News

Corneal Collagen Crosslinking for Pediatric Keratoconus: Two-Year Data

Abstract #: RP30057476

Senior Author: *Ronald N Gaster MD FACS*

Coauthor: *Yaron S Rabinowitz MD*

Purpose: To evaluate the safety and efficacy of corneal collagen crosslinking (CXL) in adolescents with progressive keratoconus (KC). **Methods:** Of 195 eyes of adolescent patients with KC, 104 eyes were evaluated at 12 months and 59 eyes were evaluated at 24 months post-CXL. Main outcome measures were uncorrected visual acuity (UCVA), corrected distance VA (CDVA), steep K, and minimum pachymetry. **Results:** LogMAR UCVA significantly improved, from 0.58 preop to 0.42 and 0.50 at 12 and 24 months post-CXL. LogMAR CDVA significantly improved, from 0.31 preop to 0.20 at 12 and 0.20 at 24 months post-CXL. Ksteep decreased from 52.1 D preop to 50.4 D and 49.7 D at 12 and 24 months post-CXL. Minimum pachymetry decreased from 453 microns preop to 440 and 450 microns at 12 and 24 months post-CXL. **Conclusion:** CXL in adolescents with KC is safe and efficacious, can improve VA, and should be considered early to halt progression of KC.

Reshaping and Customizing Small-Incision Lenticule Extraction-Derived Biological Lenticules for Implantation

Abstract #: RP30057486

Senior Author: *Yu-Chi Liu MD*

Coauthors: *Iben Bach Damgaard MD, Andri Riau PhD, Gary Yam PhD, and Jodhbir S Mehta MBBS PhD*

Purpose: To evaluate the feasibility of excimer laser reshaping of small-incision lenticule extraction (SMILE)-derived lenticules. **Methods:** Human lenticules underwent excimer ablation and were evaluated with respect to surface morphology (scanning electron microscopy and atomic force microscopy) and surface function (Fourier transform infrared spectroscopy, FTIR). Ten reshaped lenticules were implanted into porcine eyes. Corneal thickness and topography were assessed. **Results:** The lasered lenticules exhibited a more regular surface. FTIR illustrated prominent changes in lipid profiles, with no changes in collagen structure, after laser. The lasered lenticules were significantly thinner than the nonlasered ones, before and after implantation. After implantation, the nonlasered group showed a tendency toward a greater increase in axial keratometry and elevation than the lasered group. **Conclusion:** Excimer laser ablation for thinning or reshaping is feasible to customize a lenticule to desired power prior to reimplantation.

Femtosecond-Assisted Crosslinking vs. Conventional Crosslinking: Proof of Concept of “The Deeper, the Better”

Abstract #: RP30057495

Senior Author: *Lional Raj Daniel Raj Ponniah MD*

Purpose: To compare femto-assisted crosslinking (CXL) with conventional, and to prove that deeper cross-linking better dampens keratoconus. **Methods:** Conventional CXL (CC) compared with femto-CXL (FC; creation of bed 9.0-mm diameter, 140 mic deep, into which riboflavin is infused followed by UVA). Vision, pachymetry, K-max, SimK, anterior segment OCT-derived demarcation line (DL in mic.) were analyzed at 1 year. **Results:** 25 FC, 21 CC eyes. Vision improved by 2 and 1 lines in FC and CC. Pachymetry was maintained in FC and reduced by 28 mic in CC eyes. Corneas flattened in FC and CC. Astigmatism was reduced in FC by 0.31 D and increased by 0.27 D in CC. DL was 393 deep in FC vs. 243 in CC. No endothelial changes. **Conclusion:** Femto-laser assists deeper crosslinking than conventional procedures, favoring an effective stabilization as a proof of a “the deeper, the better” concept.

Comparison of Visual Outcomes and Complications of Posterior Chamber Phakic IOL With and Without a Central Hole Implantation for Correction of High Myopia and Myopic Astigmatism

Abstract #: RP30057500

Senior Author: *Seyed Javad Hashemian MD*

Purpose: To evaluate the visual outcomes and complications after implantation of V4c ICL (with CentraFlow) and V4 for correction of high myopic astigmatism. **Methods:** V4c and V4 ICL implantation was done for correction of high myopic astigmatism with at least 1 year of follow-up. The outcome measures that were evaluated included pre- and postoperative uncorrected distance visual acuity (UDVA), corrected distance VA (CDVA), endothelial cell count (ECC), lens opacification, IOP, and lens rotation. **Results:** Forty-six eyes underwent V4c ICL implantation, and 40 eyes had implantation of V4 ICL with PI. Mean preoperative SE was -8.65 and -8.51 D in the V4c and V4 groups, which was reduced to -0.16 and -0.33 D, respectively. Mean preoperative cylinder was -1.38 and -1.65 D, which respectively reduced to -0.51 and -0.46 D. At 1 year, mean ECC loss was 2.4% and 3.1%. One eye of the V4c group and 3 eyes of the V4 group required re-rotation surgery. Safety and efficacy indices were the same, and lens was clear in both groups. **Conclusion:** Both V4c and V4b Visian ICL implantations have the same result in terms of visual outcome and safety profile.

Analysis of Different Approaches to Enhance Range of Vision: Functional Results, Patient Satisfaction, Disphotopic Phenomena

Abstract #: RP30057504

Senior Author: *Florian T A Kretz MD*

Coauthors: *Matthias Gerl, Gerd U Auffarth MD, and Detlev R H Breyer MD*

Purpose: To evaluate the outcome after binocular implantation of an enhanced depth of field (EDOF) IOL compared with a mix-and-match approach with an EDOF and a trifocal IOL. **Methods:** Cataract patients received either an AT LARA 829 binocular or in combination with an AT LISA tri 839. Pre- and postoperative, monocular and binocular functional results—corrected distance visual acuity (CDVA), uncorrected distance VA (UDVA), distance-corrected intermediate VA (DCIVA; 90 cm, 80 cm, 60 cm), distance-corrected near VA (DCNVA), uncorrected near VA (UNVA), defocus curve (logMAR) refractive outcome, halo and glare simulator, and patient satisfaction scores were evaluated. **Results:** Mean binocular UDVA, CDVA, DCIVA (90 cm, 80 cm, and 60 cm), and DCNVA in the EDOF and the mix-and-match group were -0.03, -0.05, -0.02, 0.03, 0.05, 0.33 (EDOF group) and -0.05, 0.00, -0.05, 0.13, -0.08, 0.02 (mix-and-match group), respectively. **Conclusion:** Both groups showed a high degree of patient satisfaction.

Comparison of Visual Quality, Photopic Phenomena, and Patient Satisfaction in Different Presbyopia-Correcting Multifocal IOLs

Abstract #: RP30057505

Senior Author: *Florian T A Kretz MD*

Coauthors: *Matthias Gerl, Detlev R H Breyer MD, and Gerd U Auffarth MD*

Purpose: To evaluate visual quality, dysphotopsia, and satisfaction in patients implanted with different multifocal IOLs (MIOLs). **Methods:** Binocular implantations: FineVision trifocal, EDOF AT LARA, EDOF Lentis Comfort LS-313MF15, Mix and Match EDOF AT LARA, and AT LISA tri. We evaluated photic phenomena, optical quality with the HD Analyzer, and subjective satisfaction rate. **Results:** Mild strength of Halo and Glare were 49.97% in FineVision, 37.16% for the AT LARA 829, 26.98% for the Lentis Comfort, and 40.68% in the mix-and-match group. We found the best mean values of the ocular scatter index (1.61 ± 0.85) in the AT LARA eyes. In all groups, the surgeries offered high rates of spectacle independence in far and intermediate distances. Patients would choose the same IOL in 75% of FineVision, 93.33% of AT LARA, 81.81% of mix-and-match, and 72.72% of Lentis Comfort. **Conclusion:** The evaluation of visual side effects and optical quality in patients with different MIOL models helps to construct a better understanding of the outcomes on a qualitative scale.

Does the Bowman Layer Influence Corneal Biomechanics?

Abstract #: RP30057506

Senior Author: **Emilio A Torres Netto MD**

Coauthors: **Sabine Kling PhD, Bogdan V Spiru, Walter Sekundo MD, and Farhad Hafezi MD PhD**

Purpose: To test biomechanical properties of the Bowman layer (BL) in healthy ex vivo human corneas using stress-strain extensometry. **Methods:** Twenty-six healthy human corneas were obtained following Descemet membrane endothelial keratoplasty. In Group 1, BL was ablated (20- μ m thick, 10-mm optical zone). In Group 2, BL was left intact. Then in both groups, a 110- μ m thick lamella was cut. Elastic-viscoelastic properties were analyzed. **Results:** No significant differences between groups were observed in the elastic modulus, either during preconditioning or in destructive testing. Similarly, no significant differences were found in stress. **Conclusions:** The presence or absence of the Bowman layer did not alter the stiffness of a 110- μ m corneal lamella. These results may have implications not only in refractive laser surgeries but also for Bowman layer transplantation in keratoconus.

PACK-CXL Multicenter Trial: Preliminary Results

Abstract #: RP30057507

Senior Author: **Emilio A Torres Netto MD**

Coauthors: **Rohit Shetty MBBS, Harsha Nagaraja MBBS, Boris Knyazer, Shihao Chen, Sabine Kling PhD, and Farhad Hafezi MD PhD**

Purpose: To analyze corneal epithelialization time using collagen crosslinking with photoactivated chromophore (PACK-CXL) as a first-line treatment in early infectious corneal ulcers. **Methods:** This prospective, interventional, multicenter, randomized controlled clinical trial included ulcers up to 2 mm in diameter and 300- μ m depth. Patients were randomized into 2 groups: PACK-CXL only or Medication only. **Results:** Nineteen eyes were included, 7 in the PACK-CXL group and 12 in the Medication group. No differences in corneal epithelialization were observed (10.0 ± 7.3 vs. 7.0 ± 6.0 days). One patient (Medication group) developed corneal perforation and was removed from the analysis. **Conclusions:** PACK-CXL may be an alternative primary treatment for infectious corneal infiltrates and early corneal ulcers. Even with a tendency for longer healing, all PACK-CXL-treated eyes healed without use of antimicrobial therapy.

Prospective Comparative Study of Phakic IOL vs. Intacs Corneal Rings to Manage Anisometropic Myopic Amblyopia in Children

Abstract #: RP30057508

Senior Author: **Mohamed M K Diab MD**

Coauthor: **Selma Milisic MD**

Purpose: A purpose of this study is to compare the safety and efficacy of phakic IOL (PIOL) implantation vs. Intacs for correcting myopic anisometropia in amblyopic children who are noncompliant with traditional optical treatment. **Methods:** Prospective study including 56 children 3.5-13 years old, suffering from unilateral high myopic anisometropic amblyopia with refractive spherical power from -4.0 to -18.0 D and astigmatism from -1.0 to -5.5 D. **Results:** The PIOL group with patching revealed prevention of amblyopia with improvement in visual acuity of at least 6 lines in 81% of children and only 3

lines restricted to 19% of children. **Conclusions:** To eliminate significant anisometropic myopia in children who are non-compliant with traditional optical treatment, phakic anterior chamber IOL implantation or Intacs should be considered as an alternative modality of treatment.

Opacification of Hydrophilic IOL Material After Intraocular Gas or Air Injection

Abstract #: RP30057510

Senior Author: **Ramin Khoramnia MD**

Coauthors: **Timur Yildirim, Bert Constantin Giers MD, Hyeck-Soo Son, Grzegorz Labuz, and Gerd U Auffarth MD**

Purpose: We analyzed explanted hydrophilic IOLs that had shown opacification after intraocular gas injection. **Methods:** Twenty-three lenses were assessed. Ten IOLs had opacified after pars plana vitrectomy (PPV) and 13 IOLs after posterior lamellar keratoplasty. After optical quality assessment, the lenses were further analyzed using light microscopy (staining with von Kossa and Alizarin red), scanning electron microscopy, and energy-dispersive X-ray spectroscopy. **Results:** Accumulation of calcium phosphate underneath the optical surface of the IOL was the reason for opacification in all analyzed cases. We found different degrees of calcification that led to a dramatic decrease of optical quality in some of the cases. **Conclusion:** Hydrophilic IOL material has a higher risk of opacification when air or gas is injected into the eye. In cases that will likely require procedures with intraocular gas or air installation, it is recommended to avoid the use of hydrophilic acrylic IOLs.

The Visual Acuity Range of Eyes Implanted With Monofocal IOLs

Abstract #: RP30057528

Senior Author: **Yaqin Jiang MD**

Coauthors: **Canwei Zhang MD, Xudong Huang, and Yunfeng Zhang**

Purpose: To investigate the visual acuity range of eyes implanted with a monofocal IOL. **Methods:** Forty-four eyes (34 patients) were included in this study, and the age of the patients was from 45 to 70 years old. Uncorrected visual acuity (UCVA) and distance corrected VA (DCVA) at 5 m, 80 cm, and 40 cm, reading performance, and defocus curve were assessed 3 months after surgery. **Results:** UCVA averaged 0.015 logMAR at 5 m, 0.065 logMAR at 80 cm, and 0.302 logMAR at 40 cm, and DCVA was -0.07 ± 0.058 D. Defocus curve testing showed a flat monocular VA range from 0.015 ± 0.65 D to -1.61 ± 0.73 D (0.0 logMAR). The range of VA better than 0.1 logMAR was between 1.5 and 2.0 D in 37 eyes (84.1%), and between 2.0 and 2.5 D in 4 eyes (9.1%). Twenty-five patients were still spectacle dependent when they saw things at near distance. **Conclusion:** The eyes implanted with monofocal IOL showed good outcomes at a range of vision other than a point.

Influence of Induced Astigmatism in Eyes Implanted With Small-Aperture and Trifocal IOLs **Abstract #: RP30057534**

Senior Author: Robert Edward T Ang MD

Purpose: To evaluate the influence of induced astigmatism on outcomes for small-aperture and 2 different trifocal IOLs. **Methods:** Prospective evaluation of eyes implanted with Fine-Vision IOL ($n = 9$), LisaTri IOL ($n = 10$), or IC-8 IOL ($n = 12$). Manifest spherocylindrical refraction was performed to achieve BCVA. Influence of increasing levels of induced astigmatism (0.00 to 2.50 D in 0.50-D steps) on distance visual acuity was evaluated over 3 different axes: 90°, 180°, and oblique). **Results:** Visual acuity (VA) in the IC-8 eyes was better than in the Fine-Vision and LisaTri eyes at all dioptric steps ($P < .05$). With 2.50 D of induced astigmatism, the mean logMAR VA in the IC-8 IOL eyes was 0.29 logMAR or better for all tested axes. FineVision and LisaTri eyes achieved between 0.30 and 0.40 logMAR for the 90° and 180° axes and were 0.41 logMAR or worse with 2.50 D in the oblique axes. **Conclusion:** The small-aperture IOL showed greater tolerance to induced astigmatism compared to the trifocal IOLs.

Visual and Refractive Outcomes Following Cataract Surgery With a Small-Aperture IOL in Eyes With Previous Radial Keratotomy **Abstract #: RP30057535**

Senior Author: Sathish Srinivasan MBBS

Coauthors: Smita A Agarwal MBBS MS, Erin Thornell, and Allon Barsam MBBS FRCOphth

Purpose: To report the visual and refractive outcomes of a small-aperture IOL (IC-8, Acufocus; CA) in subjects undergoing cataract surgery with previous radial keratotomy (RK). **Methods:** Nine eyes of 7 patients with cataract and previous RK were included. All underwent implantation of the IC-8 IOL in the nondominant eye. The dominant eye was implanted with a monofocal or monofocal toric IOL. Four eyes of 2 subjects underwent bilateral IC-8 implantation. **Results:** The median monocular uncorrected distance visual acuity improved from 20/150 preoperatively to 20/25 postoperatively in the IC-8 and from 20/120 to 20/40 in the fellow eyes. The median uncorrected monocular intermediate and near visual acuities were 20/30 and 20/25, respectively, in the IC-8 eyes. **Conclusions:** Implantation of IC-8 IOL in eyes with previous RK is a safe and effective solution. Patients seem to achieve good unaided vision at distance, intermediate, and near distances, providing good functional vision.

Posterior Segment Visualization in Eyes With Small-Aperture IOLs **Abstract #: RP30057536**

Senior Author: Sathish Srinivasan MBBS

Coauthor: Zachariah Koshy MBBS

Purpose: To evaluate the posterior segment visualization in patients with a small-aperture IC-8 IOL. **Methods:** Fifteen subjects who had unilateral implantation of the IC-8 were recruited. The fellow eyes were pseudophakic (monofocal IOL) in 14 subjects and phakic in 1. Postoperatively all underwent fundus photography, perimetry, and OCT. The images were graded by a masked clinician. One subject developed postoperative endophthalmitis in the eye with the IC-8 IOL and underwent vitrectomy. The intraoperative view was evaluated by the

retinal surgeon. **Results:** All 15 subjects had successful image capture. The masked observer could not detect any difference in the image quality between the fellow and the IC-8 IOL eye. The small-aperture IOL did not subjectively obstruct the intraoperative view for the retinal surgeon during vitrectomy. **Conclusion:** Posterior segment investigations can be safely and effectively performed in eyes with small-aperture IOL.

Visual Outcomes Comparison of Small-Aperture, Accommodating, and Multifocal IOLs **Abstract #: RP30057538**

Senior Author: Jay Stuart Pepose MD PhD

Purpose: To compare outcomes of small-aperture, accommodating, and multifocal IOLs in cataract patients at 6 months. **Methods:** Comparison of visual acuity and contrast sensitivity (CS) of contralaterally implanted IC-8 IOL ($n = 105$, Acufocus) with an aspheric monofocal IOL to bilateral implanted Crystalens AO ($n = 26$, Bausch+Lomb), AcrySof ReSTOR +3.0 D ($n = 25$, Alcon), and Tecnis +4D Multifocal (MF) IOL ($n = 22$, J&J Vision). **Results:** IC-8 and Crystalens had mean uncorrected intermediate visual acuity of 0.08 and 0.07, nearly 2 lines better than ReSTOR and Tecnis MF (0.24, $P < .0001$). Mean uncorrected near VA (UNVA) for IC-8 and Tecnis MF was 0.18 and 0.19; ReSTOR had better UNVA at 0.01 and Crystalens had worse UNVA at 0.26 ($P < .01$). Functional range of vision was continuous across 4.5 D for IC-8, noncontinuous across 4.5 D for ReSTOR, 4.0 D for Tecnis MF, and 2.5 D for Crystalens. **Conclusion:** Small-aperture IOL patients achieved the broadest range of continuous functional range of vision and comparable binocular mesopic CS compared to either accommodating or multifocal IOLs.

Circle Enhancement After Small-Incision Lenticule Extraction: A Retrospective Study on Efficacy **Abstract #: RP30057541**

Senior Author: Stine Funder Jespersen MD

Coauthor: Nina Jacobsen IV MD

Purpose: To evaluate circle enhancement (CIRCLE) as retreatment after small-incision lenticule extraction (SMILE). **Methods:** Out of 2419 SMILE eyes, 35 eyes (1.4%) underwent CIRCLE (2015-2018). CIRCLE converts the cap into a flap, allowing stromal ablation with topography-guided excimer laser. Manifest refraction spherical equivalent (MRSE), visual acuity (Snellen chart), and higher-order aberrations (HOA) were measured. Follow-up was 1 month. Paired t test was used. **Results:** MRSE was -7.09 ± 2.35 D pre-SMILE, with improvement from -1.33 ± 0.97 D post-SMILE to -0.41 ± 0.58 D post-CIRCLE ($P < .0001$). Uncorrected distance visual acuity (UDVA) increased from 0.40 ± 0.23 to 0.83 ± 0.24 ($P < .0001$). Corrected distance visual acuity (CDVA) remained unchanged (from 1.04 ± 0.22 to 1.08 ± 0.25). Seven eyes lost 1 line of CDVA, no eye lost 2 or more lines, and 5 eyes gained 2 lines. HOA decreased from $0.41 \pm 0.21 \mu\text{m}$ to $0.31 \pm 0.21 \mu\text{m}$ ($P < .04$). **Conclusion:** CIRCLE is a safe and efficient method of improving UDVA when retreatment is needed after SMILE.

Effectiveness and Safety of Combining LASIK and Corneal Inlay Implantation: Four-Year Follow-up

Abstract #: RP30057546

Senior Author: Mitsutoshi Ito MD PhD

Purpose: To evaluate the 4-year effectiveness and safety of combined LASIK and small-aperture intracorneal inlay implantation (Kamra, Acufocus; Irvine, CA) in 2 stages for the surgical compensation of presbyopia and refractive errors. **Methods:** Retrospective chart review of all ametropic, presbyopic patients who underwent LASIK and Kamra inlay implantation on a later day from May 2011 to January 2014 was conducted. **Results:** In total, 2843 patients (mean age: 52.5 years \pm 5.6; range: 40 to 76 years) were treated. Mean preoperative MRSE was -3.23 ± 3.31 D. Preoperative mean uncorrected near visual acuity (UNVA) improved from $J8.4 \pm 5.0$ to $J2.5 \pm 1.8$ by Year 2 postoperatively, remaining stable through the 4-year follow-up. At last follow-up, 56% of patients achieved UNVA of J2 or better. At the last follow-up (Month 48), binocular UDVA was 20/20 in 91%. 179 inlays (6.3%) were removed. **Conclusion:** This procedure appears to be a safe, effective procedure for the treatment of presbyopia.

Patient-Reported Refractive Surgery Outcomes in Contact Lens and Eyeglass Wearers

Abstract #: RP30057549

Senior Author: Rose Kristine C Sia MD

Coauthors: Denise Ryan COA MS, Lorie A Logan OD, Jennifer Eaddy, Lamarr Peppers, Samantha B Rodgers MD, and Bruce A Rivers MD

Purpose: To assess functional outcomes and patient satisfaction after refractive surgery among different corrective lens users. **Methods:** Completed quality of vision questionnaires of active duty U.S. military service members treated from 2004 to 2017 were reviewed. Of 343 patients, 188 were former contact lens wearers (CW) and 155 were former eyeglass wearers (EW). **Results:** At 6 months postoperatively, scores measuring night vision and driving difficulty significantly improved among CW and EW (all P -values < 0.01). Far vision scores improved in both groups, but only CW reported significant change ($P < .01$). There were 149/179 CW and 112/148 EW who "completely agreed" being satisfied with surgery. **Conclusion:** Both previous CW and EW observed improved physical functions and seemed to be satisfied with refractive surgery.

Enhancement Options After Small-Incision Lenticule Extraction: An Overview of Different Techniques

Abstract #: RP30057567

Senior Author: Moones Fathi Abdalla MD

Coauthor: Osama I Ibrahim MD PhD

Purpose: To evaluate different techniques of enhancing small-incision lenticule extraction (SMILE): (1) PRK, flap creation (off label), (2) circle option (flap creation), (3) capless / cap-preserving re-SMILE (off label), and (4) sub-SMILE retreatment (SMILE at a deeper level; off label). **Methods:** Retrospective assessment of retreatment cases from more than 10,000 eyes performed. Time between primary surgery and retreatment had to be at least 3 months. Five eyes, PRK; 2 eyes, new flap creation; 3 eyes, circle option; 4 eyes, capless; 3 eyes, sub-SMILE retreatment. Each technique has its indications. Surgical challenges, visual recovery, and visual outcomes were assessed.

Results: All modalities had minimal surgical complications, and visual recovery varied widely between techniques, yet at 1-month follow-up all cases showed excellent visual outcome. **Conclusion:** Retreatment for SMILE visual outcome is very promising if it is taken into consideration that it is case-specific and that every technique has its indications.

Combined Phacoemulsification and Intravitreal Bevacizumab Injection for Prophylaxis of Macular Edema in Diabetic Patients

Abstract #: RP30057569

Senior Author: Ashraf H El Habbak MD

Coauthor: Mohamed Awwad MD

Purpose: To assess the efficacy of phacoemulsification combined with intravitreal bevacizumab in diabetic patients without macular edema as prophylaxis against postoperative macular edema. **Methods:** This is a prospective, interventional study in which 100 eyes of 65 diabetic patients with no diabetic maculopathy were randomly divided into 2 groups: a phacoemulsification group (Group A, 50 eyes) and a phacoemulsification / bevacizumab group (Group B, 50 eyes). Patients were followed-up for 1 year. Central macular thickness (CMT) using OCT was recorded. **Results:** At the end of the third follow-up month, CMT increased significantly in Group A, from 167.58 ± 7.36 mm preoperatively to 208.56 ± 25.99 mm ($P < .005$), while in Group B CMT showed no significant changes, from 165.86 ± 6.89 mm preoperatively to 160.12 ± 4.48 mm ($P > .005$). **Conclusion:** Use of intravitreal bevacizumab combined with phacoemulsification protects against development of macular edema in diabetic patients without diabetic maculopathy.

Outcome of Transepithelial PRK for High Myopia With High Speed Excimer Laser and Advanced Laser Beam Profile

Abstract #: RP30057577

Senior Author: Simon P Holland MD

Coauthors: David T C Lin MD and Albert T Covello MD

Purpose: To evaluate outcomes of PRK in eyes with moderate and high myopia undergoing Schwind Amaris SmartSurfACE PRK. **Methods:** 696 eyes with moderate myopia (≤ -8 D) and 111 eyes with high myopia (> -8 D) underwent transepithelial (TE) SmartSurfACE PRK. **Results:** At 12 months of follow-up, 88% and 63% of the moderate and high myopia subgroups achieved 20/20 uncorrected distance visual acuity (UDVA) postoperatively ($P < .05$), while 99% and 93% achieved 20/40 (< 0.05), respectively. Ninety-seven percent in the moderate myopia group and 89% in the high myopia group achieved 20/20 corrected distance visual acuity (CDVA) (< 0.05), while 19% and 23% gained lines, respectively, and none lost more than 1 line. No retreatments were required. **Conclusion:** TE-PRK with Schwind Amaris1050 SmartSurfACE showed good outcomes, with 88% achieving 20/20 UDVA in moderate myopia (≤ -8 D), 63% in high myopia (> -8 D). Good results with TE-PRK using the SA1050 are possible for moderate and high myopia using an advanced beam profile, offering an alternative to LASIK.

Effect of Curvature Gradient Between Treated and Untreated Corneas in Myopic Surface Ablation

Abstract #: RP30057580

Senior Author: Wen Zhou MD MS

Coauthor: Aleksandar Stojanovic MD

Purpose: To evaluate the effect of the transition gradient between the treated and untreated cornea on postoperative corneal optics and epithelial thickness profile after myopic surface ablation. **Methods:** Eighteen volunteers underwent topography-guided surface ablation using different transition zone designs in the contralateral eyes: eyes with low dioptric transition gradient were assigned to Group 1. Eyes with fixed transition zone size (1 mm larger than optical zone) were assigned to Group 2. **Results:** Ten months postoperatively, no statistical difference was detected between the 2 groups concerning subjective refraction or visual acuity. However, Group 1 showed significantly less higher-order aberration, less central epithelial thickening, and larger effective optical zone. **Conclusion:** A smoother transition gradient in myopic surface ablation provided better corneal optics and less epithelial remodeling, while the subjective refraction and visual acuity remained the same.

Outcomes of Bilensectomy Following Iris Claw and Posterior Chamber Phakic IOL Surgery

Abstract #: RP30057581

Senior Author: Jorge L Alió MD PhD

Coauthors: Veronica Vargas, Rafael I Barraquer Compte MD, Justin D'Antin, and Antonio A P Marinho MD PhD

Purpose: The aim of this study is to evaluate the safety, efficacy, and visual outcomes following phakic IOL bilensectomy, and the causes for the bilensectomy. **Methods:** This multicenter, retrospective study included 94 eyes that had bilensectomy; 49 eyes had a posterior chamber phakic IOL (PCP-IOL) and 45 eyes had an iris claw phakic IOL. The UCVA, CDVA, safety and efficacy index were assessed. **Results:** The main reason for bilensectomy for both phakic IOLs was cataract formation. Safety index was 1.3 for the Artisan bilensectomy and 1.5 for the PCP-IOL bilensectomy; the efficacy index was 0.9 and 1.1, respectively. There was an improvement in UCVA and BCVA after surgery for both groups. **Conclusion:** Both phakic IOLs had a good safety and efficacy index following bilensectomy surgery. Cataract is the main problem following the implantation of phakic IOLs.

Multifocal IOL Exchange by a Different Multifocal Technology: Is It Feasible?

Abstract #: RP30057587

Senior Author: Jorge L Alió MD PhD

Coauthor: Olena Al-Shymali

Purpose: To report causes and visual outcomes after multifocal (MF) IOL exchange by another MF technology. **Methods:** Twenty-seven eyes of 17 patients were included. Outcome measures were BCVA, types of IOL, causes of exchange, and patient satisfaction. **Results:** The explanted IOLs included refractive (51.9%), diffractive (33.3%), and extended depth of focus (14.8%), and the implanted were 44.4% refractive and 55.6% diffractive IOLs. The mean time implantation-explantation was 1 year. Exchange causes were neuroadaptation failure (92.6%) and IOL dislocation (7.4%). The BCVA changed from 20/30 to 20/22 ($P = 0$). The mean follow-up time was 6 months. Most

patients were satisfied. No postoperative complications were found. **Conclusion:** MF IOL exchange by another MF IOL technology may be considered a safe procedure. In patients with neuroadaptation failure, IOL exchange using a different optical MF technology can successfully treat the causes of neuroadaptation failure and provide good visual outcomes.

Combined Flapless Refractive Lenticule Extraction (SMILE) and Intrastromal Corneal Crosslinking in Patients With Suspicious Topography and/or Thin Corneas: Refractive and Biomechanical Outcomes

Abstract #: RP30057589

Senior Author: Moones Fathi Abdalla MD

Coauthors: Ahmed A K El-Massry MD, Karim A Gaballah MD, and Osama I Ibrahim MD PhD

Purpose: To report visual, refractive, topographic, and biomechanical outcomes of simultaneous small-incision lenticule extraction (SMILE) and intrastromal crosslinking in eyes with abnormal topography. **Methods:** Prospective case series of 118 eyes of 66 patients. SMILE was performed, intrapocket injection of isotonic riboflavin, then 3 min 30 mw/cm² UV crosslinking. Corvis ST measuring and correlating IOP and deformation amplitude. **Results:** Mean patient age was 29.4 ± 5.63 (22-35). Mean preoperative UCVA, 0.13 ± 0.08 and 0.82 ± 0.13 postoperatively. Mean preoperative refraction was -3.97 ± 1.87 D sphere (range: -6.0 to -1.25) and -2.85 D cylinder (range: -0.75 to -4.25); mean postoperative SER was -0.14 ± 0.73 D (range: -1.25 to $+1.5$); mean astigmatism was -0.18 ± 0.45 D. Seventy-two percent were within ± 0.5 , and 89% were within ± 1.0 D. Mean deformation amplitude was 1.38 ± 0.29 mm preop to 1.19 ± 0.29 mm postop. **Conclusion:** Combined SMILE and crosslinking is a safe, predictable, and stable treatment option in patients where conventional laser refractive surgery is contraindicated.

Achieving Refractive Perfection Using Multicomponent IOLs

Abstract #: RP30057590

Senior Author: Harvey S Uy MD

Purpose: Multicomponent IOLs (MC-IOLs) allow refinements after cataract surgery by surgical exchange of its refractive components. We present the results of refractive enhancement among eyes that received MC-IOL after cataract surgery. **Methods:** Three months after primary surgery, 50 eyes with manifest refraction spherical equivalent (MRSE) greater than 0.75 D underwent enhancement by replacing the primary front IOL optic with a new front optic with corrected refractive power. Main outcome measures: 3-month post-enhancement unaided distance visual acuity (UDVA) in logMAR, MRSE change, adverse events. **Results:** After enhancement, the mean (SD) preoperative UDVA of 0.2 (0.15) logMAR improved to 0.0 (0.07) ($P = .008$); mean pre-enhancement MRSE of $+1.4$ (0.9) D decreased to $+0.1$ (0.4) D ($P = .0002$); all eyes had UDVA of 0.1 or better. None developed significant adverse events. **Conclusion:** MC-IOL enhancement is a safe and consistent method of refractive enhancement that enables cataract surgeons to optimize outcomes.

Two-Year Result of Topography-Guided PRK With Crosslinking for Keratoconus With High-Speed Laser

Abstract #: RP30057597

Senior Author: Murad M Al Obthani MBBS

Coauthors: David T C Lin MD, Albert T Covello MD, and Samuel Arba Mosquera

Purpose: To evaluate the outcomes of topography-guided PRK (TG-PRK) for keratoconus (KC) with crosslinking (CXL) with Schwind Amaris 1050 (SA). **Methods:** Retrospective case series of 54 KC eyes treated with SA laser and CXL. Data were collected at 24 months for analysis; pre- and postoperative uncorrected distance (UDVA) and corrected distance (CDVA) visual acuity, manifest refraction, and topographic cylinder. **Results:** Twenty-seven of 54 (50%) showed UDVA \geq 20/40. Twenty-two (42%) showed improved CDVA, and 14 (26%) gained > 1 line ($P = .0003$), while 7 (13%) lost > 1 line. Mean astigmatism was reduced from 3.14 ± 1.58 D to 2.28 ± 1.87 D ($P < .0001$). Mean spherical equivalent was improved from -2.58 ± 3.89 D to -0.89 ± 2.88 D ($P < .0001$). **Conclusion:** TG-PRK CXL show efficacy and safety in treatment for eyes with keratoconus with results at 2 years. Half of the cases achieved 20/40 UDVA or better, and 42% had improved CDVA, with more than a quarter improving more than 1 line. This provides an alternative for contact lens-intolerant keratoconus patients.

Quality of Vision in 2 Different Military Occupational Populations

Abstract #: RP30057598

Senior Author: Bruce A Rivers MD

Coauthors: Denise Ryan COA MS, Rose Kristine C Sia MD, Lamarr Peppers, Jennifer Eaddy, Lorie A Logan OD, and Samantha B Rodgers MD

Purpose: To evaluate patient-reported quality of vision (QoV) following refractive surgery in combat arms (CA) and combat support (OS) elements in active duty U.S. military service members. **Methods:** Records from 2004-2017 were reviewed, and military occupational specialty was categorized as CA ($n = 104$) or CS ($n = 240$). **Results:** In CA, 15/100 preoperatively and 61/102 postoperatively completely agreed with "I see perfectly well"; in CS, there were 34/226 preoperatively compared to 149/234 postoperatively. There were 76/100 CA and 195/228 CS who completely agreed that "as a result of the operation, my main goal was achieved." **Conclusion:** Refractive surgery appears to enhance the QoV of warfighters in different operational statuses.

Refractive Surgery Symptoms Experienced and Limitations on Activity in LASIK and Surface Ablations

Abstract #: RP30057600

Senior Author: Denise Ryan COA MS

Coauthors: Rose Kristine C Sia MD, Lorie A Logan OD, Jennifer Eaddy, Lamarr Peppers, Samantha B Rodgers MD, and Bruce A Rivers MD

Purpose: To assess symptoms experienced (ie, tearing, ghost images) and life activity limitations after LASIK and surface ablation (SA). **Methods:** Records of active duty U.S. military service members treated from 2004 to 2017 were reviewed for completion of quality of vision questionnaires. Of 345 patients, 45 received LASIK and 300 had SA. **Results:** Evaluating symptoms before and 6 months postoperatively, limitations in work, social life, and sports activities improved after surgery among LASIK and SA patients (all P -values $< .01$). Symptoms experienced were not significantly different in SA but were worse in LASIK patients ($P = .02$). There were 37/45 LASIK and 255/286 SA patients who "completely agreed" that if given the choice to do it over, they would choose to have the surgery. **Conclusion:** While LASIK patients experienced an increase in symptoms, neither LASIK nor SA patients experienced a significant decline in activity.

Topography-Guided PRK for Correction of Irregular Astigmatism Following Penetrating Keratoplasty

Abstract #: RP30057602

Senior Author: Murad M Al Obthani MBBS

Coauthors: Simon P Holland MD and Samuel Arba Mosquera

Purpose: To evaluate efficacy and safety of topography-guided PRK (TG-PRK) for irregular astigmatism following penetrating keratoplasty (PK). **Methods:** Contact lens-intolerant eyes with irregular astigmatism following PK that underwent transepithelial TG-PRK with Schwind Amaris 1050 SmartSurFACE Excimer Laser were evaluated at 12 months for refraction, uncorrected (UDVA) and corrected (CDVA) distance visual acuity, and symptoms. **Results:** Forty-one eyes completed 12 months follow-up. Fifteen of 41 (37%) had UDVA \geq 20/40, while none did preoperatively. Eighteen (44%) had CDVA improved, 13 (32%) gained ≥ 2 lines, and 6 (15%) lost ≥ 2 lines. Reduction in astigmatism (RIA) was 2.44 ± 2.42 D. Mean spherical equivalent improved from -3.24 ± 3.98 D to -1.44 ± 2.22 D. No patient showed regression up to 12 months postoperatively. Five eyes had delayed epithelial healing without long-term sequelae. **Conclusion:** One-year results of TG-PRK with SA for post-PK astigmatism showed satisfactory efficacy and safety. About one-third gained 2 or more lines of CDVA and achieved 20/40 of UDVA.

Outcomes of Phototherapeutic Keratectomy vs. Topography-Guided PRK for Keratoconus With Crosslinking

Abstract #: RP30057603

Senior Author: David T C Lin MD

Coauthors: Simon P Holland MD and Samuel Arba Mosquera

Purpose: To compare keratoconic eyes undergoing combined topographic-guided photorefractive keratectomy (TG-PRK) vs. phototherapeutic keratectomy (PTK) with corneal collagen crosslinking (CXL). **Methods:** Thirty-one eyes underwent PTK CXL, and 305 had TG-PRK with Schwind Amaris 1050 laser SmartSurFACE followed by CXL. Data analyzed: Spherical and cylinder correction, spherical equivalent, uncorrected distance visual acuity (UDVA), corrected distance visual acuity (CDVA), and safety were evaluated at 12 months for both groups. **Results:** Sixty-one percent of the TG-PRK group achieved 20/40 UDVA, and 12% of the PTK group. Seventy-eight percent in the TG-PRK group had no change or gained ≥ 1 line CDVA, and 58% in the PTK group; 6% in the TG-PRK group lost ≥ 2 lines, and 13% in the PTK group. **Conclusion:** TG-PRK CXL therapy was superior to PTK CXL in visual correction. Our study suggests that TG-PRK with CXL was the option preferred to PTK in achieving better vision in keratoconus, but long-term follow-up is needed.

Comparison of Combined High-Fluence Corneal Crosslinking Stabilization With PTK and Partial Topography-Guided Excimer Laser Normalization in the Management of Progressive Keratoconus: Cretan Protocol vs. Athens Protocol

Abstract #: RP30057605

Senior Author: Mariana Almeida Oliveira MD

Coauthors: Amelia Sofia Correia Martins, Andreia Martins Rosa MD, Joao Manuel Beirão Cardoso Quadrado Gil MD, Esmeralda Costa MD, Maria João Quadrado MD, and Joaquim N Murta MD PhD

Purpose: To evaluate and compare visual, refractive, and topographic outcomes after corneal crosslinking (CXL) combined with PTK (Cretan Protocol) and CXL combined with T-PRK (Athens Protocol) for keratoconus treatment. **Methods:** Retrospective study. Patients with progressive keratoconus were included in 2 groups: Cretan and Athens. BCVA and tomography (Pentacam) were evaluated preoperatively and 12 months postoperatively. **Results:** Forty-nine eyes (19 Cretan, 30 Athens) from 49 patients were included. Both groups showed significant improvement of BCVA (Athens, 0.17 ± 0.18 logMAR, $P < .001$; Cretan, 0.13 ± 0.21 logMAR, $P = .050$), although the difference was not statistically significant between groups ($P = .597$). Topographical parameters (K1, K2, Kmax) improved in both groups, but it was statistically significant only in the Athens group. **Conclusion:** PTK and TG-PRK protocols in combination with CXL were effective in stabilization of keratoconus. Treatment with TG-PRK demonstrated better visual and topographic outcomes.

Post-LASIK Ectasia Treated by Topography-Guided PRK and Crosslinking Using a New High-Speed Laser

Abstract #: RP30057606

Senior Author: Simon P Holland MD

Coauthor: Murad M Al Obthani MBBS

Purpose: To evaluate early results of topography-guided PRK (TG-PRK) for post-LASIK ectasia (EC) with crosslinking (CXL) with Schwind Amaris 1050 (SA). **Methods:** Retrospective case series of 52 EC eyes treated with SA laser and CXL. Data collected: pre- and postoperative uncorrected (UDVA) and corrected (CDVA) distance visual acuity, manifest refraction, and topographic cylinder. **Results:** Twenty-three had sufficient data at 12 months for analysis. Thirteen of 23 (57%) showed UDVA $\geq 20/40$ postoperatively. Eleven (48%) had improved CDVA, and 6 (26%) gained ≥ 2 lines ($P = .03$). No patient showed progression. Mean astigmatism was reduced from 3.05 ± 1.45 D to 1.27 ± 1.07 D ($P = .0008$). Mean spherical equivalent was improved from -2.33 ± 4.06 D to -0.49 ± 1.99 D ($P = .05$). **Conclusion:** Early results of TG-PRK CXL with SA show efficacy and safety in treating post-LASIK ectasia. More than half (57%) had UDVA $\geq 20/40$ at 1 year, and a quarter had CDVA improved ≥ 2 lines. The technique may be an alternative treatment for post-LASIK ectasia with contact lens intolerance.

Corneal Stromal Demarcation Line Depth in 2 Different Pulsed Accelerated Corneal Crosslinking Protocols in Patients With Progressive Keratoconus

Abstract #: RP30057607

Senior Author: Julio Hernandez Camarena MD

Coauthors: Denise Loya MD and Jorge E Valdez-Garcia MD

Purpose: To compare the depth of the stromal demarcation line (CDL) and visual / refractive outcomes in keratoconus (KC) patients between 2 different accelerated corneal crosslinking (CXL) protocols. **Methods:** Retrospective cohort, patients with progressive KC. Two epi-off pulsed CXL protocols: irradiance 30 mW/cm^2 (G1)-8 min, 45 mW/cm^2 (G2)-4 min (7.2 J/cm^2). CDL was measured 1 month postop. Stat: ANOVA, Pearson correlation: $P < .05$. **Results:** Forty-seven eyes (25 patients): 23 eyes in Group 1, 24 eyes in Group 2. Mean age (years), 19.09 ± 4.82 and 20.12 ± 4.12 ; mean follow-up (months), 12.26 ± 3.29 . CDL depth (μm), 200.63 ± 10.01 , Group 1; 184.53 ± 19.68 , Group 2 ($P < .001$). Significant improvement in uncorrected (UDVA) and corrected (CDVA) distance visual acuity, astigmatism, and Km in both groups. No difference between groups in UDVA, CDVA, anterior curvature, central corneal thickness, or endothelial cell density. A negative correlation was observed between CDL depth and final UDVA. **Conclusion:** Both protocols seem to be safe and effective at halting KC progression and improving UDVA, CDVA, Km, and topographic astigmatism. Deeper CDL was associated with a better UDVA at the final visit.

Topography-Guided Photorefractive Keratectomy for Irregular Astigmatism After Radial Keratotomy Using a High-Speed Laser

Abstract #: RP30057609

Senior Author: Albert T Coverley MD**Coauthor: Simon P Holland MD**

Purpose: To evaluate topography-guided PRK (TG-PRK) for irregular astigmatism after radial keratotomy (RK) with Schwind Amaris 1050 (SA). **Methods:** Retrospective case series of 33 RK eyes treated with SA laser and CXL. Data collected at 12 months for analysis: pre- and postoperative uncorrected (UDVA) and corrected (CDVA) distance visual acuity, manifest refraction, and topographic cylinder. **Results:** Nineteen of 33 (58%) showed UCVA $\geq 20/40$ postoperatively. Seventeen (52%) had improved CDVA and 9 (27%) gained ≥ 2 lines, while 1 (3%) lost 2 lines or more. Mean astigmatism was reduced from 2.07 ± 1.76 D to 0.95 ± 1.00 D. Mean spherical equivalent was improved from 2.46 ± 1.95 D to -0.40 ± 1.97 D. **Conclusion:** Early results of TG-PRK CXL with Schwind Amaris 1050 show efficacy and safety in treating post-RK irregular astigmatism. More than a half (58%) had UDVA $\geq 20/40$ at 1 year, and 25% had CDVA improved ≥ 2 lines. The technique maybe an alternative treatment for post-RK with contact lens intolerance.

Comparison of Outcomes With Standard and Accelerated Corneal Crosslinking Protocols for Progressive Keratoconus

Abstract #: RP30057610

Senior Author: J Bradley Randleman MD**Coauthors: Paul Lang BA and Farhad Hafezi MD PhD**

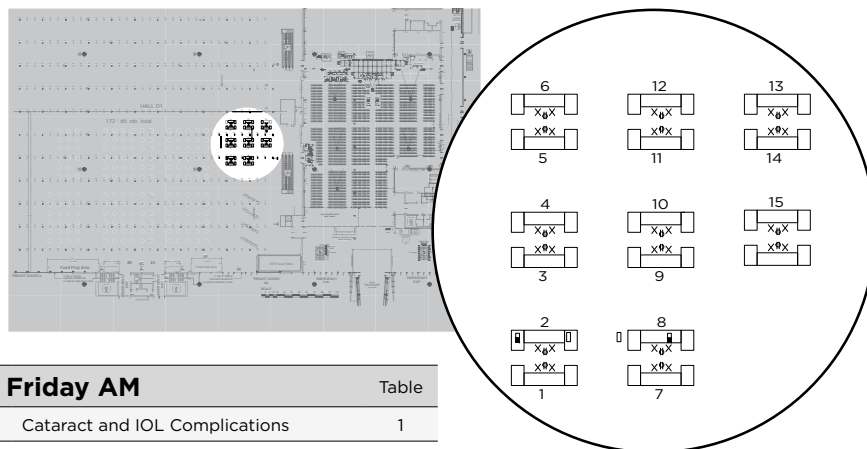
Purpose: To compare outcomes after corneal crosslinking (CXL) using standard or accelerated protocol in patients with progressive keratoconus. **Methods:** Visual acuity and Scheimpflug-based measurements were compared 12 months postoperatively on patients with progressive keratoconus receiving either standard protocol CXL (S-CXL, 3 mW/30 minutes) or 1 of 2 accelerated protocols (SA9-CXL, 9 mW/10 minutes or IA30-CXL, 30 mW/4 minutes). **Results:** Ninety-three eyes (67 patients) total were evaluated. Each protocol had significant improvements without worsening in numerous measurements, with S-CXL improving in the most variables. Compared to the accelerated protocols, S-CXL had better outcomes in surface asymmetry, but not in any other measurement or visual acuity. **Conclusion:** Both standard and accelerated CXL protocols are effective at halting keratoconus progression. S-CXL induced greater measurable corneal changes, although these changes did not lead to significantly different clinical outcomes.

Subspecialty Day 2018

Refractive Surgery — Hall D

Break with the Experts Schedule & Floor Plan

AAO 2018
ART + SCIENCE
SUBSPECIALTY DAY



Break with Experts Friday AM		Table
Burkhard Dick MD	Cataract and IOL Complications	1
Priya Narang MS	Cataract and IOL Complications	1
Renato Ambrosio Jr MD	Elevation Corneal Tomography and Topography	2
Damien Gatinel MD	Elevation Corneal Tomography and Topography	2
Sheraz M Daya MD	Femtosecond LASIK: Tips for Optimizing Visual Outcomes and Avoiding Complications	3
Kendall E Donaldson MD	Femtosecond LASIK: Tips for Optimizing Visual Outcomes and Avoiding Complications	3
Aylin Kilic MD	Intracorneal Rings	4
Mitchell A Jackson MD	Intracorneal Rings	4
Eric D Donnenfeld MD	Laser Vision Correction Enhancements	5
Paolo Vinciguerra MD	Laser Vision Correction Enhancements	5
Beatrice Cochener MD	Management of the Ocular Surface in Refractive Surgery Patients	6
Jennifer M Loh MD	Management of the Ocular Surface in Refractive Surgery Patients	6
Dan Z Reinstein MD	Managing SMILE Complications	7
William F Wiley MD	Managing SMILE Complications	7
Helen K Wu MD	Pediatric Refractive Surgery	8
Erin D Stahl MD	Pediatric Refractive Surgery	8
Erik L Mertens MD FRACOPHTH	Phakic IOLs	9
Gregory D Parkhurst MD	Phakic IOLs	9
Daniel S Durrie MD	Refractive Surgery Enhancements	10
Parag A Majmudar MD	Refractive Surgery Enhancements	10
Robert Edward T Ang MD	Small Aperture Procedures	11
John Allan Vukich MD	Small Aperture Procedures	11
David Smadja MD	Surface Ablation and CXL Combined and Sequential Procedures	12
A John Kanellopoulos MD	Surface Ablation and CXL Combined and Sequential Procedures	12
George Beiko MD	Toric IOL Pearls	13
Neda Shamie MD	Toric IOL Pearls	13
Glauco H Reggiani Mello MD	Visual Quality Assessment	14
Roger Zaldivar MD	Visual Quality Assessment	14
Break with Experts Friday PM		
Soosan Jacob FRCS	Allogenic Corneal Inlays	1
Ronald R Krueger MD	Allogenic Corneal Inlays	1

Break with Experts Friday PM, continued		Table
Roy Scott Rubinfeld MD	Collagen Crosslinking	2
Paolo Vinciguerra MD	Collagen Crosslinking	2
Ronald Luke Rebenitsch MD	Corneal Inlays	3
George O Waring IV MD	Corneal Inlays	3
Dan Z Reinstein MD	Epithelial Mapping Prior to Corneal Refractive Surgery	4
Sumitra S Khandelwal MD	Epithelial Mapping Prior to Corneal Refractive Surgery	4
John P Berdahl MD	How to Communicate with the Unhappy Patient	5
William F Wiley MD	How to Communicate with the Unhappy Patient	5
Tat-Keong Chan MD FRCS FRCOPHTH	Intracameral Antibiotics for Endophthalmitis Prophylaxis	6
David F Chang MD	Intracameral Antibiotics for Endophthalmitis Prophylaxis	6
Burkhard Dick MD	Laser Refractive Lens Surgery	7
Sumit Garg MD	Laser Refractive Lens Surgery	7
Parag A Majmudar MD	Modulation of Corneal Wound Healing after Refractive Surgery	8
Helen K Wu MD	Modulation of Corneal Wound Healing after Refractive Surgery	8
Maria A Henriquez MD	Ocular Surface Management	9
Marguerite B McDonald MD	Ocular Surface Management	9
Mitchell A Jackson MD	Patient Selection for Refractive Lens Exchange	10
Jason E Stahl MD	Patient Selection for Refractive Lens Exchange	10
Daniel H Chang MD	Planning IOL Powers	11
Jack T Holladay MD MSEE FACS	Planning IOL Powers	11
Ashvin Agarwal MD	SMILE	12
Steven C Schallhorn MD	SMILE	12
Aylin Kilic MD	Surface Ablation Pearls	13
Riccardo Vinciguerra MD	Surface Ablation Pearls	13
Terry Kim MD	Therapeutic Corneal Refractive Surgery, Including Phototherapeutic Keratectomy	14
William B Trattler MD	Therapeutic Corneal Refractive Surgery, Including Phototherapeutic Keratectomy	14