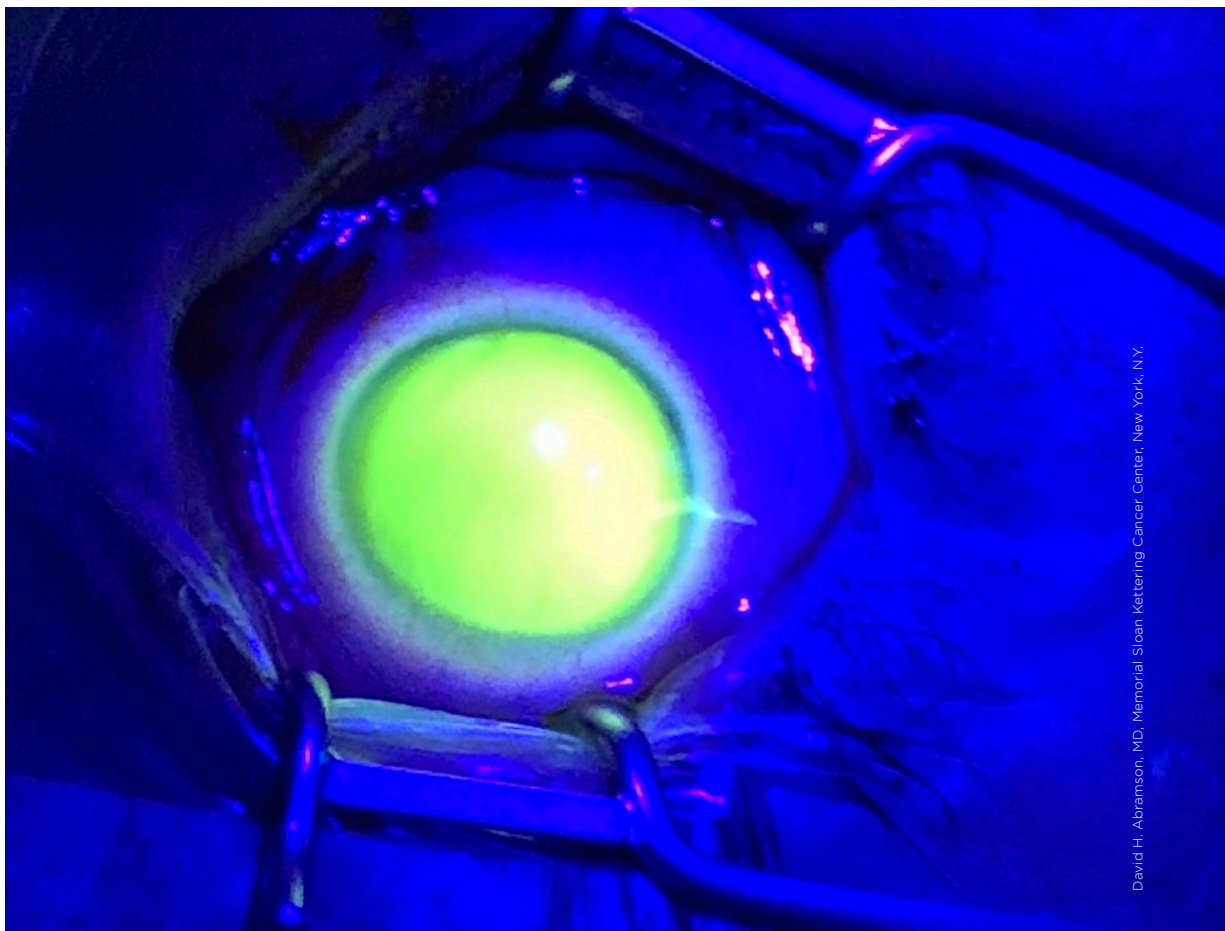

David H. Abramson, MD, Memorial Sloan Kettering Cancer Center, New York, N.Y.

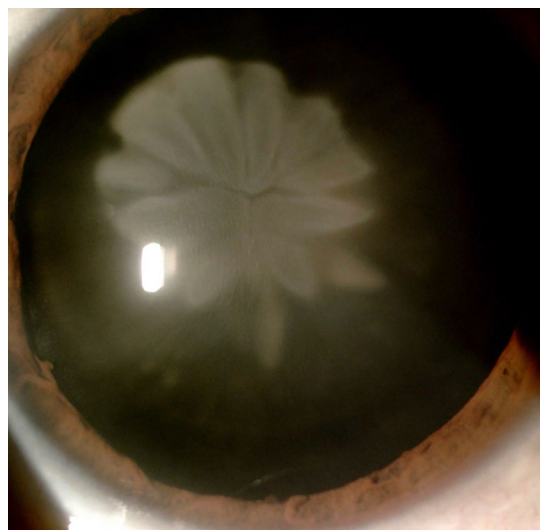
**WHAT IS THIS MONTH'S MYSTERY CONDITION?** Visit [aao.org/eyenet](http://aao.org/eyenet) to make your diagnosis in the comments.

#### LAST MONTH'S BLINK

## Rosette-Shaped Cataract

**A** 71-year-old man with a history of dyslipidemia and pulmonary tuberculosis presented with progressive, bilateral, deteriorating vision that was worse in the left eye. His best-corrected visual acuity (BCVA) was 20/40 in the right eye and counting fingers at 3 feet in the left. Intraocular pressure was normal in both eyes.

Slit-lamp examination after pharmacologic mydriasis revealed a nuclear cataract in the right eye and a rosette-shaped cataract in the left eye. Bilateral funduscopy was normal. When asked about any ocular injuries, he said that he had suffered blunt trauma to the left eye five years earlier. We performed phacoemulsification cataract surgery and IOL implantation in the left eye. One month later, we performed the same surgery in



the right eye. After surgery, the BCVA was 20/20 in both eyes.

WRITTEN BY **DIOGO LOPES, MD**, AND **TOMÁS LOUREIRO, MD**. PHOTOGRAPH BY **DIOGO LOPES, MD**. BOTH ARE AT GARCIA DE ORTA HOSPITAL, LISBON, PORTUGAL.