



To help medical students continue their ophthalmic studies during the COVID-19 pandemic, the Academy is providing this three-chapter excerpt from *Basic Ophthalmology*, a key text for primary care residents and physicians who want to broaden their knowledge of eye disease diagnosis and treatment.

Topics in this free sample include:

1. Acute Vision Loss
2. The Red Eye
3. Ocular and Orbital Injuries

To purchase the full print or eBook, visit the [Academy Store](#).



AMERICAN ACADEMY™  
OF OPHTHALMOLOGY

TENTH  
EDITION

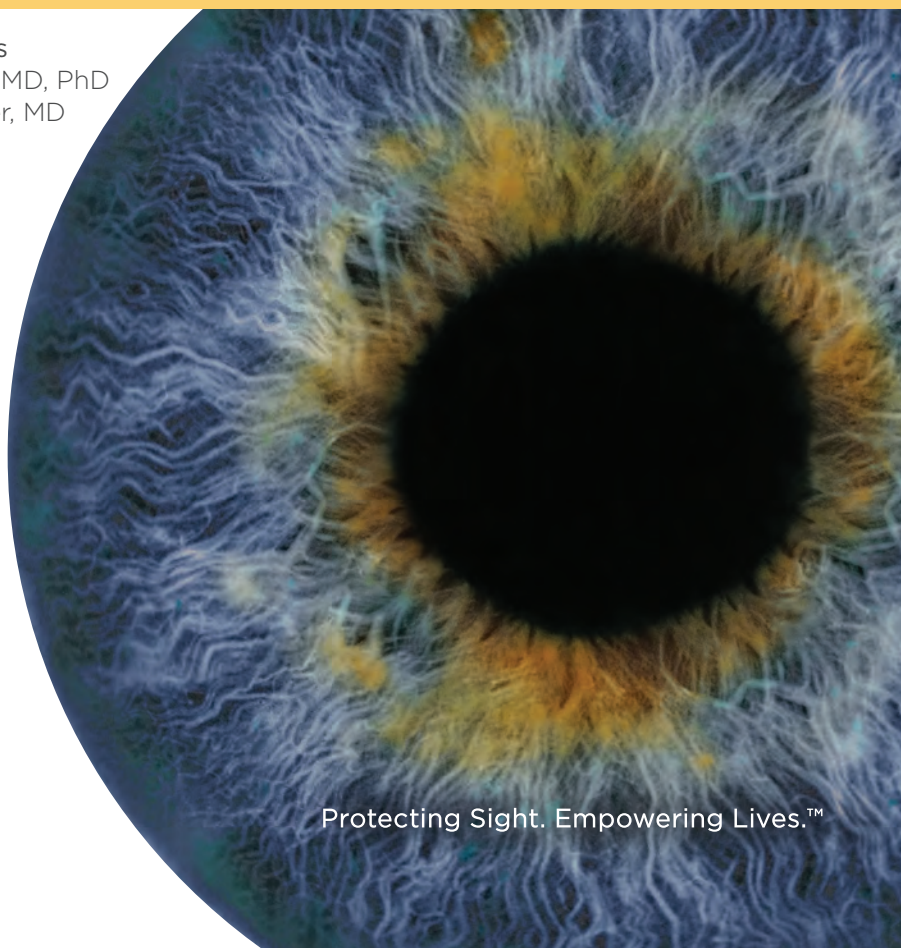
# Basic Ophthalmology

Essentials for Medical Students

Executive Editors

Richard C. Allen, MD, PhD

Richard A. Harper, MD



Protecting Sight. Empowering Lives.™



AMERICAN ACADEMY™  
OF OPHTHALMOLOGY

# Basic Ophthalmology

Essentials for Medical Students

TENTH EDITION

Executive Editors

Richard C. Allen, MD, PhD

Richard A. Harper, MD

Protecting Sight. Empowering Lives.™

American Academy of Ophthalmology  
655 Beach Street  
P.O. Box 7424  
San Francisco, CA 94120-7424

### Clinical Education Secretaries

Louis B. Cantor, MD, *Senior Secretary for Clinical Education*  
Christopher J. Rapuano, MD, *Secretary for Ophthalmic Knowledge*

### Ophthalmology Liaisons Committee

Samuel P. Solish, MD, *Chair*  
Richard C. Allen, MD, PhD  
Rebecca Sands Braverman, MD  
Humeyra Karacal, MD  
Joseph T. Nezgoda, MD, MBA  
Martha P. Schatz, MD  
Howard S. Weiss, MD  
Diana J. Shamis, COMT, *Consultant*

### Academy Staff

Dale E. Fajardo, *Vice President, Education*  
Beth Wilson, *Director, Continuing Professional Development*  
Daniel Mummert, *Director, Online Education*  
Susan R. Keller, *Acquisitions Editor*  
Kim Torgerson, *Publications Editor*  
D. Jean Ray, *Production Manager*  
Jasmine Chen, *Manager, E-Learning*  
Donna Scism, *E-Editor/Proofreader*  
Eric Gerdes, *Interactive Designer*  
Debra Marchi, *Administrative Assistant*

The Academy provides this material for educational purposes only. It is not intended to represent the only or best method or procedure in every case, nor to replace a physician's own judgment or give specific advice for case management. Including all indications, contraindications, side effects, and alternative agents for each drug or treatment is beyond the scope of this material. All information and recommendations should be verified, prior to use, with current information included in the manufacturers' package inserts or other independent sources, and considered in light of the patient's condition and history. Reference to certain drugs, instruments, and other products in this publication is made for illustrative purposes only and is not intended to constitute an endorsement of such. Some materials may include information on applications that are not considered community standard, that reflect indications not included in approved FDA labeling, or that are approved for use only in restricted research settings. **The FDA has stated that it is the responsibility of the physician to determine the FDA status of each drug or device he or she wishes to use, and to use them with appropriate informed patient consent in compliance with applicable law.** The Academy specifically disclaims any and all liability for injury or other damages of any kind, from negligence or otherwise, for any and all claims that may arise out of the use of any recommendations or other information contained herein.

AAO, AAOE, American Academy of Ophthalmology, Basic and Clinical Science Course, BCSC, EyeCare America, EyeNet, EyeSmart, EyeWiki, Focal Points, IRIS, ISRS, OKAP, ONE, Ophthalmic Technology Assessments, *Ophthalmology*, Preferred Practice Pattern, ProVision, SmartSight, The Ophthalmic News & Education Network, and the AAO logo (shown on cover) and tagline (Protecting Sight. Empowering Lives) are, among other marks, the registered trademarks and trademarks of the American Academy of Ophthalmology.

Copyright © 2016 American Academy of Ophthalmology®. All rights reserved.

### Financial Disclosures

Authors, reviewers, and academy staff members who contributed to the development of this product state that within the 12 months prior to their contributions to this book and for the duration of development, they have had no financial interest in or other relationship with any entity discussed in this course that produces, markets, resells, or distributes ophthalmic health care goods or services consumed by or used in patients, or with any competing commercial product or service.

### Library of Congress Cataloging-in-Publication Data

Names: Allen, Richard C. (Richard Cutler), 1965- editor. | Harper, Richard A., 1958- editor. | American Academy of Ophthalmology, issuing body.  
Title: Basic ophthalmology : essentials for medical students / Richard C. Allen, Richard A. Harper, executive editors.  
Other titles: Basic ophthalmology (Bradford)  
Description: Tenth edition. | San Francisco, CA : American Academy of Ophthalmology, [2016] | Includes bibliographical references and index.  
Identifiers: LCCN 2016020313 | ISBN 9781615258048 (alk. paper)  
Subjects: | MESH: Eye Diseases--diagnosis | Diagnostic Techniques, Ophthalmological  
Classification: LCC RE46 | NLM WW 141 | DDC 617.7--dc23 LC record available at <https://lccn.loc.gov/2016020313>

Printed in the United States of America

20 19 18 17 16

1 2 3 4

# CONTENTS

Preface .....	ix
Acknowledgments .....	x
About the Executive Editors .....	x
<b>Introduction to Ophthalmology .....</b>	<b>1</b>
Resources from the American Academy of Ophthalmology .....	1
Meet the Eye Care Team .....	1
Eye Myths .....	3
 <b>1 The Eye Examination .....</b>	 <b>7</b>
Objectives .....	7
Relevance .....	7
Basic Information .....	8
The Patient's History .....	8
Ocular Anatomy .....	9
Anatomic Aging Changes .....	9
Optics .....	14
When to Examine .....	16
Additional Tests .....	16
How to Examine .....	17
Visual Acuity .....	17
Distance Visual Acuity Testing .....	17
Near Visual Acuity Testing .....	20
Visual Acuity Estimation in an Uncooperative Patient .....	22
Confrontation Visual Field Testing .....	22
Amsler Grid Testing .....	22
External Inspection .....	23
Upper Eyelid Eversion .....	23
Ocular Motility Testing .....	24
Pupillary Reaction Testing .....	25
Anterior Chamber Depth Assessment .....	25
Intraocular Pressure Measurement .....	26
Color Vision Testing .....	28
Fluorescein Staining of Cornea .....	28
Ophthalmoscopy .....	30
Summary of Steps in the Eye Examination .....	34
Management or Referral .....	34

Reduced Visual Acuity .....	35
Abnormal Fundus Appearance .....	35
Shallow Anterior Chamber Depth/Elevated Intraocular Pressure .....	36
Points to Remember .....	36
Sample Problems .....	36
Annotated Resources .....	38

## **2 Acute Vision Loss ..... 41**

Objectives .....	41
Relevance .....	41
Basic Information .....	42
Narrowing the Diagnosis From the History .....	42
How to Examine .....	43
Visual Acuity Testing .....	43
Confrontation Visual Field Testing .....	43
Pupillary Reactions .....	43
Red Reflex Evaluation and Ophthalmoscopy .....	44
Penlight Examination .....	44
Tonometry .....	44
How to Interpret the Findings .....	44
Acute Vision Loss Associated With Pain .....	44
Acute Vision Loss Without Pain .....	45
Painless, Acute Vision Loss Without Clear Media .....	45
Painless, Acute Vision Loss With Clear Media .....	47
Functional Disorders .....	55
Points to Remember .....	55
Sample Problems .....	56
Annotated Resources .....	57

## **3 Chronic Vision Loss ..... 59**

Objectives .....	59
Relevance .....	59
Basic Information .....	60
Glaucoma .....	60
Overview .....	63
When to Examine .....	66
How to Examine .....	66
How to Interpret the Findings .....	67
Management or Referral .....	69
Cataract .....	69
Overview .....	70
When to Examine .....	72
How to Examine .....	73
How to Interpret the Findings .....	73
Management or Referral .....	74
Macular Degeneration .....	74
Overview .....	74
When to Examine .....	77
How to Examine .....	78

How to Interpret the Findings .....	79
Management or Referral .....	79
The Visually Impaired Patient .....	80
Points to Remember .....	81
Sample Problems .....	81
Annotated Resources .....	83

## **4 The Red Eye ..... 87**

Objectives .....	87
Relevance .....	87
Basic Information .....	88
History .....	88
How to Examine .....	88
Disorders Associated With a Red Eye .....	91
The Acute, Painful Red Eye .....	91
Acute, Nonpainful Red Eye .....	93
Chronic, Irritated Red Eye .....	95
Chronic Red Eye Without Irritation .....	96
Adnexal Disease .....	96
Further Interpretation of the Findings .....	97
Symptoms of a Red Eye .....	97
Signs of a Red Eye .....	99
Associated Systemic Problems .....	101
Laboratory Diagnosis .....	102
Management or Referral .....	102
Blepharitis .....	103
Stye and Chalazion .....	105
Subconjunctival Hemorrhage .....	106
Conjunctivitis .....	106
Therapeutic Warnings .....	107
Points to Remember .....	107
Sample Problems .....	108
Annotated Resources .....	112

## **5 Ocular and Orbital Injuries ..... 113**

Objectives .....	113
Relevance .....	113
Basic Information .....	114
Anatomy and Function .....	114
When to Examine .....	117
How to Examine .....	117
History .....	118
Visual Acuity Testing .....	118
External Examination .....	119
Pupillary Reactions .....	120
Ocular Motility Testing .....	121
Ophthalmoscopy .....	121
Radiologic Studies .....	121
Management or Referral .....	121
True Emergency .....	122

Urgent Situations .....	122
Treatment Skills .....	125
Ocular Irrigation .....	126
Foreign-Body Removal .....	126
Prescribing Eye Medication .....	126
Patching .....	128
Points to Remember .....	129
Sample Problems .....	130
Annotated Resources .....	134

## **6 Amblyopia and Strabismus ..... 137**

Objectives .....	137
Relevance .....	137
Basic Information .....	138
Amblyopia .....	138
Strabismus .....	140
How to Examine and Interpret the Findings .....	142
Amblyopia Testing .....	143
Strabismus Testing .....	145
Other Tests .....	149
Management or Referral .....	150
Amblyopia .....	150
Strabismus .....	151
Serious Intraocular Lesions .....	152
Points to Remember .....	152
Sample Problems .....	153
Annotated Resources .....	155

## **7 Neuro-Ophthalmology ..... 157**

Objectives .....	157
Relevance .....	157
Basic Information .....	157
How to Examine .....	158
Visual Acuity Testing .....	158
Visual Field Testing .....	158
Color Perception and Saturation .....	159
Pupillary Examination .....	159
Ocular Motility Testing .....	162
Ophthalmoscopy .....	163
How to Interpret the Findings .....	163
Pupillary Disorders .....	163
Motility Disorders .....	167
Optic Nerve Disease .....	172
Optic Disc Elevation .....	173
Visual Field Defects .....	180
Visual Hallucinations .....	182
Cognitive Vision Loss: The Visual Variant of Alzheimer's Disease .....	182
Points to Remember .....	183



Sample Problems .....	183
Annotated Resources .....	187
<b>8 Eyelid, Lacrimal, and Orbital Disease .....</b>	<b>189</b>
Objectives .....	189
Relevance .....	189
Eyelid Disorders .....	190
Eyelid Infections .....	190
Eyelid Malpositions .....	191
Eyelid Neoplasms .....	197
Lacrimal Disease .....	198
Orbital Disease .....	200
How to Examine .....	200
Orbital Neoplasms .....	201
Inflammatory Processes of the Orbit .....	203
Vascular Malformations .....	204
Points to Remember .....	205
Sample Problems .....	206
Annotated Resources .....	209
<b>9 Ocular Manifestations of Systemic Disease .....</b>	<b>211</b>
Objectives .....	211
Relevance .....	211
Diabetes Mellitus .....	212
Hypertension .....	216
Arteriolar Sclerosis .....	216
Elevated Blood Pressure .....	217
Diagnostic Concerns .....	218
Management .....	218
Pregnancy .....	219
Sickle Cell Anemia .....	220
Thyroid Disease .....	220
Sarcoidosis and Other Inflammatory and Autoimmune Conditions .....	221
Dry Eye Syndrome .....	222
Malignancy .....	223
Acquired Immunodeficiency Syndrome .....	223
Syphilis .....	225
Other Systemic Infections .....	226
Points to Remember .....	227
Sample Problems .....	227
Annotated Resources .....	229
<b>10 Drugs and the Eye .....</b>	<b>231</b>
Objectives .....	231
Relevance .....	231
Basic Information .....	233
Topical Ocular Diagnostic Drugs .....	234

Fluorescein Dye .....	234
Anesthetics .....	235
Mydriatics .....	235
Topical Ocular Therapeutic Drugs .....	236
Decongestants .....	236
Agents for Relief of Allergic Conjunctivitis .....	237
Anti-inflammatory Agents .....	237
Agents for the Relief of Dry Eye Symptoms .....	237
Antibiotics .....	238
Antiviral Agents .....	238
Systemic Side Effects of Glaucoma Medications .....	238
$\beta$ -Adrenergic Antagonists .....	239
Cholinergic-Stimulating Drugs .....	240
$\alpha_2$ -Adrenoceptor Agonists .....	240
Adrenergic-Stimulating Drugs .....	241
Prostaglandin Analogues .....	241
Carbonic Anhydrase Inhibitors .....	241
Ocular Side Effects of Systemic Drugs .....	242
Amiodarone .....	242
Bisphosphonates .....	242
Chloroquines .....	243
Chlorpromazine .....	244
Corticosteroids .....	244
Digitalis .....	244
Diphenylhydantoin .....	244
Ethambutol .....	245
HMG-COA Reductase Inhibitors (Statins) .....	245
Rifabutin .....	246
Sildenafil, Tadalafil, Vardenafil, and Avanafil .....	246
Tamoxifen .....	246
Tamsulosin .....	247
Thioridazine .....	247
Topiramate .....	247
Points to Remember .....	248
Sample Problems .....	248
Annotated Resources.....	251
Index .....	253

## PREFACE

*Basic Ophthalmology: Essentials for Medical Students* is an ideal complement to the medical student curriculum and a key text for primary care providers and residents who want to broaden their knowledge of eye disease diagnosis and treatment. The book describes how to obtain an appropriate ocular history and perform a complete eye evaluation. From the history and clinical findings, the clinician should be able to diagnose and manage or refer common ocular disorders such as vision loss, red eye, ocular and orbital injuries, and amblyopia and strabismus. This edition includes content updates as well as a new chapter on eyelid, orbital, and lacrimal disease. Other features include 140+ figures, access to 19 video clips, key points to remember, sample problems to test knowledge, plus updated annotated resources. Where appropriate, tables are presented to summarize textual information and facilitate study.

Population growth in persons 65 years and older in the United States is placing increasing demands on primary care providers to manage age-related disease. Because many ocular disorders are more prevalent in this age group, primary care providers will need to have a solid understanding of the most commonly encountered disorders so that patients' conditions will be effectively diagnosed, treated, and/or referred. To complicate this situation, there has been a decline in the number of medical schools requiring a formal ophthalmology rotation, thus reducing the opportunity for medical students to obtain this essential information. Fortunately, many ophthalmology departments around the country are taking an active role in reemphasizing the importance of ophthalmology in the medical student curriculum. *Basic Ophthalmology* provides an excellent resource for this effort, by establishing curricular content and later acting as a ready reference for practitioners encountering patients with ocular disorders.

This book can be used in a variety of settings. The concise presentation of information makes it ideal for brief ophthalmology rotations. If greater time is available, the resources can be consulted for more detail. This book is intended to be a flexible instrument that summarizes the important concepts, techniques, and facts of ophthalmology for nonophthalmic physicians and residents, especially those in primary care. The Ophthalmology Liaisons Committee anticipates that medical students will use this book in conjunction with comprehensive texts and other related resources listed at the end of each chapter.

New to this edition are videos related to topics covered in the book (see Chapters 1, 3, 6, 7, 9, and 10). The videos are available to readers of the print and electronic versions at [www.aao.org/basicvideo](http://www.aao.org/basicvideo). For the print version, mobile-device users can scan the QR codes shown in text (a QR-code reader must already be installed on the device) to access the video content. In addition, you are invited to test your knowledge of anatomy through interactive versions of some figures in this book. Visit [www.aao.org/basicinteractive](http://www.aao.org/basicinteractive).

## Acknowledgments

The executive editors of this edition thank the members of the Ophthalmology Liaisons Committee who reviewed the previous edition for currency and offered feedback for this edition: Samuel P. Solish, MD, chair; Richard C. Allen, MD, PhD; Rebecca Sands Braverman, MD; Humeyra Karacal, MD; Joseph T. Nezgoda, MD, MBA; Martha P. Schatz, MD; Howard S. Weiss, MD; and Diana J. Shamis, COMT, consultant.

## About the Executive Editors

Richard C. Allen, MD, PhD, is professor of ophthalmology in the Department of Head and Neck Surgery at MD Anderson Cancer Center in Houston, Texas. He is editor of the oculoplastics and orbit section for *Current Opinion in Ophthalmology* and is a member of committees in the American Society of Ophthalmic Plastic & Reconstructive Surgery, the American Academy of Ophthalmology, and the International Council of Ophthalmology.

Richard A. Harper, MD, is professor of ophthalmology at the Harvey & Bernice Jones Eye Institute of the University of Arkansas for Medical Sciences in Little Rock, Arkansas, where he served, until recently, as director of the residency program and the low vision clinic. He is a recipient of the Straatsma Award for excellence in resident education, established through the American Academy of Ophthalmology and the Association of University Professors of Ophthalmology.



# Introduction to Ophthalmology

## Resources from the American Academy of Ophthalmology

The mission of the American Academy of Ophthalmology is to protect sight and empower lives by serving as an advocate for patients and the public, leading ophthalmic education, and advancing the profession of ophthalmology. The following are trusted resources for additional information:

- Information for medical students interested in pursuing a career in ophthalmology: [www.aao.org/medical-students](http://www.aao.org/medical-students)
- Quality clinical ophthalmic content from EyeWiki™ collaborative online encyclopedia: [www.aao.org/eyewiki](http://www.aao.org/eyewiki)
- Clinical information and education for pediatric eye care: [www.aao.org/pediatric-ophthalmology-education-center](http://www.aao.org/pediatric-ophthalmology-education-center)
- EyeSmart® eye health information for patients and the public: [www.aao.org/eye-health](http://www.aao.org/eye-health)
- EyeCare America® eye care for patients in need: [www.aao.org/eyecare-america](http://www.aao.org/eyecare-america)

## Meet the Eye Care Team

Many participants have important roles in the delivery of eye care. **The support staff of the clinic, hospital, and operating room are critical. There are also specialized ophthalmic nurses and technicians.** The levels of training and expertise are quite different for each type of care provider.

## Ophthalmologist

An ophthalmologist is a medical or osteopathic doctor who specializes in eye and vision care. Ophthalmologists differ from optometrists and opticians in their levels of training and in what they can diagnose and treat. As a medical doctor who has completed college and at least eight years of additional medical training, an ophthalmologist is licensed to practice medicine and surgery. An ophthalmologist diagnoses and treats all eye diseases, performs eye surgery, and prescribes and fits eyeglasses and contact lenses to correct vision problems. Many ophthalmologists are also involved in scientific research on the causes of and cures for eye diseases and vision disorders.

## Subspecialists

Whereas ophthalmologists are trained to care for all eye problems and conditions, some ophthalmologists specialize in a specific area of medical or surgical eye care. A subspecialist usually completes 1 or 2 years of additional, more in-depth training called a fellowship in one of the main subspecialty areas such as glaucoma, retina, cornea, pediatrics, neurology, and plastic surgery, as well as others. This added training and knowledge prepares an ophthalmologist to take care of more complex or specific conditions in certain areas of the eye or in certain groups of patients.

## Optometrist

Optometrists are healthcare professionals who provide primary vision care ranging from sight testing and correction to the diagnosis, treatment, and management of vision changes. An optometrist is not a medical doctor. An optometrist receives a doctor of optometry (OD) degree after completing four years of optometry school, preceded by three years or more years of college. They are licensed to practice optometry, which primarily involves performing eye exams and vision tests, prescribing and dispensing corrective lenses, detecting certain eye abnormalities, and prescribing medications for certain eye diseases.

## Optician

Opticians are technicians trained to design, verify and fit eyeglass lenses and frames, contact lenses, and other devices to correct eyesight. They use prescriptions supplied by ophthalmologists, who are medical doctors and surgeons, or by optometrists, but they do

not test vision or write prescriptions for visual correction. Opticians are not permitted to diagnose or treat eye diseases.

### Ophthalmic Medical Assistant

These technicians work in the ophthalmologist's office and are trained to perform a variety of tests and help the physician with examining and treating patients.

### Ophthalmic Technicians/Technologists

These are highly trained or experienced medical assistants who assist the physician with more complicated or technical medical tests and minor office surgery.

### Ophthalmic Registered Nurse

These clinicians have undergone special nursing training and may have additional training in ophthalmic nursing. They may assist the physician in more technical tasks, such as injecting medications or assisting with hospital or office surgery. Some ophthalmic registered nurses also serve as clinic or hospital administrators.

### Ophthalmic Photographer

These individuals use specialized cameras and photographic methods to document eye conditions in photographs.

## Eye Myths

The following statements are oft-repeated myths. They are presented here, with counterpoint, in the event patients may report to you what they have heard.

- **Reading for prolonged periods in dim light can be harmful to the eyes.**
  - Reading in dim light does not harm the eyes any more than taking a photograph in dim light would harm a camera.
- **Children should be taught not to hold their books too close when reading, because doing so can harm their eyes.**
  - Holding books close to the eyes to read is common in children, and no harm can come of it. Their eyes can accommodate (focus on near objects) easily and can keep near objects in sharp focus. In rare cases, holding a book close

could be a sign of severe nearsightedness, which should be investigated; however, the habit of close reading itself will not cause nearsightedness in children.

- **Wearing glasses that are of the incorrect prescription can damage the eyes.**
  - Because glasses are placed in front of the eyes, they affect sight, not the eye. Looking through them cannot harm the eyes. However, an incorrect prescription may result in blurred vision, which can be uncomfortable.
- **If children sit too close to the television set, they may damage their eyes.**
  - Children with normal sight commonly want to sit close to the television set, just as they want to get close to reading material. This will not harm their eyes. Individuals will typically hold reading material or watch television at a distance that is comfortable for them.
- **Older people who may be having trouble seeing should not use their eyes too much because they can wear them out sooner.**
  - The eyes are made for seeing. No evidence exists that using them for their purpose will wear them out.
- **People with weak eyes should rest their eyes often to strengthen them.**
  - Eyes that are “weak” for whatever reason did not become so from overuse, so they cannot be improved by rest.
- **In time, children usually outgrow crossed eyes.**
  - Crossed eyes in children should always be considered serious; in fact, the condition requires referral to an ophthalmologist. Some children have apparent but not truly crossed eyes. In such cases, the apparent crossing is due to a broad bridge of the nose in young children. As the nose matures, this apparent crossing lessens and disappears. However, truly crossed eyes should never be ignored, as the condition will not improve with time.
- **Contact lenses can correct nearsightedness, so that eventually neither contact lenses nor eyeglasses will be needed.**
  - Incorrectly fitted contact lenses can change the shape of the cornea but do not thereby correct myopia. Intentionally fitting contact lenses incorrectly to change corneal shape can cause permanent harm to the eyes.
- **Children who have a problem learning to read are likely to have an eye coordination problem and can be helped with special exercises.**
  - The idea that reading problems are due to poor eye coordination is a misconception, as the results of many controlled studies have indicated.
- **A cataract can sometimes grow back after cataract surgery.**
  - Because a cataract is an opacity in the lens of the eye, the cataract cannot grow back when the entire lens is removed (intracapsular extraction). However, the posterior capsule of the lens may opacify when the lens capsule is left in place after removing the lens material (extracapsular



extraction). This latter technique is nevertheless currently preferred because it best permits the placement of an intraocular lens implant; if posterior capsule opacity develops, it can be easily addressed with an outpatient laser procedure.

- **A cataract has to be “ripe” before surgery can be done.**
  - The need for cataract surgery is indicated principally by the degree of functional impairment caused by the cataract, not by any criteria related to its duration.
- **Nearsighted people become farsighted as they age, and farsighted people become nearsighted.**
  - All individuals become presbyopic as they age. Presbyopia is the gradual loss of the ability to accommodate (focus on near objects), and it occurs irrespective of the person’s underlying refractive error.
- **In older people, a sign of healthy eyes is the ability to read the newspaper without glasses.**
  - The ability of older persons to read without glasses may show only that they have myopia in at least one eye with reasonably good visual acuity. The nearsightedness could be caused by a cataract. Despite this ability, the person could also have a serious ocular disorder that was not yet symptomatic, such as glaucoma.
- **People who wear glasses should have their vision checked every year to determine whether a change in prescription is needed.**
  - Glasses do not affect the health of the eyes. As long as an individual is satisfied with the vision provided by the present glasses, routine tests to measure their glasses prescription are generally unnecessary.
- **Watching a bright television picture in a dimly lighted room can be harmful to the eyes if done for long periods.**
  - The eye cannot be harmed by the way in which light enters it. The eye merely deals with light, regardless of contrast. Watching television with or without illumination is a matter of comfort rather than harm. An individual who finds the marked contrast of a bright television picture in a dimly lighted room uncomfortable should turn on a light, but neither situation will harm the eyes.
- **Ideally, all people should use an eyewash regularly to cleanse their eyes.**
  - Eyewash should be used as infrequently as possible. As long as it is functioning properly, the eyes’ natural lubrication system is adequate for cleansing them.
- **A blue eye should not be selected for transplantation into a brown-eyed person.**
  - Only the cornea can be transplanted, and the cornea is colorless in all eyes. (The iris gives eyes their color.)

- **In rare instances, a contact lens can be lost behind the eye and even work its way into the brain.**
  - The conjunctiva prevents a contact lens from passing behind the eye.
- **A cataract is actually a film over the eye that can be peeled off with surgery.**
  - A cataract is a loss of the transparency of the normal lens of the eye, not a “growth” or “film” that covers the eye. If the lens becomes opaque enough to significantly impair a person’s functional vision, the lens can be surgically removed and replaced with an intraocular lens implant. Nothing is “peeled” away.
- **Headaches are usually due to eye strain.**
  - Headaches are not usually caused by ocular factors. You will find more detailed and specific rationales for these answers in the various chapters of this text and in the resources suggested at the end of each chapter.



## CHAPTER 2

# Acute Vision Loss

### OBJECTIVES

As a primary care provider, you should be able to evaluate a patient complaining of a sudden decrease in visual acuity or visual field, to construct a differential diagnosis, and to recognize situations requiring emergent or urgent action. To achieve these objectives, you should learn

- which questions to ask the patient
- which examination techniques are appropriate, with special attention to pupillary responses, visual field testing, red reflex, and ophthalmoscopy
- which conditions are most likely to cause acute vision loss

### Relevance

For most people, sudden vision loss is a devastating occurrence. The primary care provider needs to recognize the conditions responsible for acute vision loss in order to make urgent referrals to an ophthalmologist and to initiate therapy, when appropriate. The ultimate visual outcome may well depend on early, accurate diagnosis and timely treatment.

As introduced in this chapter and used throughout the book, there are 3 grades of urgency:

- **Emergent:** management should be instituted immediately by the provider and an ophthalmologist should be called.
- **Urgent:** the provider should discuss the patient's findings with an ophthalmologist before the patient leaves the office or emergency room.

- **Nonurgent:** an appointment should be made with an ophthalmologist within 2 weeks.

## Basic Information

Obtaining the patient's history is vitally important in determining the cause of acute vision loss. The value of a thorough history cannot be overstated; although the physical examination provides necessary information, often the history itself guides the clinician to the correct diagnosis. Questions to ask the patient in the wake of sudden vision loss include

- Is there any pain associated with the vision loss?
- Is the vision loss transient, persistent, or progressive?
- Is the vision loss monocular or binocular?
- How severe is the loss of vision? Is all, or part, of the visual field affected?
- What was the tempo? Did the vision loss occur abruptly, or did it develop over hours, days, or weeks?
- When was normal vision last noted from the eye?
- What is the patient's age and medical condition?
- Is there a history of previous ocular disease or surgery, including contact lens wear?

## Narrowing the Diagnosis From the History

### Pain

Pain in or around the eye is usually associated with inflammation that can be infectious or noninfectious in etiology. In general, most painful vision loss will be associated with relatively anterior portions of the eye (cornea, anterior chamber). Although there are some posterior ocular processes that produce painful vision loss, these are less common, such as endophthalmitis and retrobulbar optic neuritis.

### Sudden recognition of vision loss

Some patients will have a chronic process causing vision loss that was not recognized by the patient until the contralateral eye was covered. It is useful to determine the last time the patient could confidently say that good vision was noted from the eye.

### Previous medical history

A number of systemic medical problems predispose the patient to vision loss. This includes diabetes mellitus, cardiovascular disease, autoimmune disease, and hypertension.

Chronic medical conditions, especially if not well controlled, predispose the patient to the vision loss associated with these conditions.

### Previous ocular history

Patients who have had known previous ocular conditions and/or surgeries are more likely to have vision loss related to these previous conditions. Known histories of diabetic retinopathy, glaucoma, intraocular surgery, and contact lens use will narrow the differential diagnosis of the vision loss.

## How to Examine

The following examination techniques aid in your evaluation of vision loss.

### Visual Acuity Testing

The first thing to be determined in evaluating acute vision loss is the visual acuity, with best available correction, in each eye. (For detailed information on visual acuity testing, see Chapter 1.)

### Confrontation Visual Field Testing

Normal acuity does not assure that significant vision has not been lost, because the entire visual field, including peripheral vision, must be considered. For example, a patient who has lost all of the peripheral vision on 1 side in both eyes—a homonymous hemianopia—may have normal visual acuity. (For instructions on assessing the visual field through confrontation visual field testing, see Chapter 1.)

### Pupillary Reactions

The reaction of the pupils to light is useful in the evaluation of vision loss, especially when that reaction is asymmetric. In the swinging-flashlight test, a bright light is moved from 1 eye to the other, and the pupillary reactions are observed. When there is a significant lesion in the retina or the optic nerve of 1 eye, the brainstem centers controlling pupillary size perceive the light as being brighter in the normal eye. Thus, when the light beam is moved from the normal eye to the abnormal eye, the pupil of the abnormal eye may continue to dilate. This positive swinging-flashlight test indicates a relative afferent pupillary defect, also known as a *Marcus Gunn pupil*. The presence or absence of a relative afferent pupillary defect is an important piece of information in the evaluation of monocular vision loss. (For more information on pupillary reactions and the swinging-flashlight test, see Chapter 7.)

## Red Reflex Evaluation and Ophthalmoscopy

Using the ophthalmoscope, one can examine the red reflex of the eye and compare it to the other eye, especially if the vision loss is asymmetric. Dulling of the red reflex indicates a media opacity, which could be due to decreased clarity of the cornea, lens, or vitreous. Ophthalmoscopy allows direct inspection of the fundus. (For information on the technique of direct ophthalmoscopy, see Chapter 1.)

## Penlight Examination

Simple penlight examination may detect corneal disease responsible for acute vision loss.

## Tonometry

Tonometry to measure intraocular pressure (IOP) may help confirm the presence of angle-closure glaucoma. (For more information about performing tonometry, see Chapter 1.)

## How to Interpret the Findings

Acute vision loss can be categorized into 3 groups: (1) vision loss associated with pain; (2) vision loss not associated with pain, without a clear media; and (3) vision loss not associated with pain, with a clear media.

An anatomic approach to each of these groups allows the clinician to systematically evaluate the patient.

## Acute Vision Loss Associated With Pain

Pain associated with vision loss usually indicates ongoing ocular inflammation. Inflammation can be due to infectious or noninfectious etiologies and will result in the eye being injected (red). Inflammation associated with trauma is usually obvious from the history and/or exam. In approaching the patient with pain, determining the anatomic location of the inflammation will lead to the etiology of the vision loss. In general, all acute vision loss associated with pain should prompt an urgent referral to the ophthalmologist.

### Corneal disease

The cornea is an exquisitely sensitive structure. Pain from corneal damage is a protective adaption to alert the individual to any potentially blinding process. Acute vision loss from

corneal processes can be due to corneal abrasions, infections, or edema. In addition, the cornea can become “starved of oxygen” due to contact lens over-wear, leading to corneal inflammation and pain. Evaluation of the integrity of the corneal epithelium is performed with fluorescein staining. (For more information on fluorescein staining, see Chapter 1.) Slit-lamp examination may be required to evaluate corneal infections and edema.

### **Anterior segment inflammation**

Uveitis can be secondary to a number of causes or be idiopathic. Inflammation of the iris and ciliary body results in an unclear media and a decline in vision. Patients will avoid light (photophobia) due to the pain associated with the movement of the iris. Anterior segment inflammation can best be appreciated with slit lamp evaluation.

### **Acute glaucoma**

A sudden rise in IOP associated with acute glaucoma will result in vision loss due to secondary corneal edema. Pain is associated with the elevated pressure in the eye, but rather than true eye pain, patients will often have referred pain to the forehead or brow. Evaluation of the IOP is performed with tonometry. (For more information on the procedure for evaluating IOP, see Chapter 1.)

## **Acute Vision Loss Without Pain**

Vision loss not associated with pain can be categorized depending on whether the patient has a clear media or not. Using the ophthalmoscope to evaluate the red reflex, the examiner can determine the clarity of the cornea, anterior chamber, lens, and vitreous. Dulling of the reflex when compared to the noninvolved eye indicates a media opacity. In cases of bilateral vision loss, the examiner may not have a normal eye to compare; however, with practice, determination of the quality of the red reflex can be performed without a reference eye. The differential diagnosis of the vision loss can then be approached anatomically depending on the presence or absence of a media opacity.

### **Painless, Acute Vision Loss Without Clear Media**

Any significant irregularity or opacity of the clear refractive media of the eye (cornea, anterior chamber, lens, vitreous) causes symptoms of blurred vision, and on examination there is a reduction of visual acuity and a darkening of the red reflex. These opacities do not cause relative afferent pupillary defects, although pupillary reflexes may be altered (eg, miosis in acute iritis or mid-dilated and fixed pupils in acute angle-closure



glaucoma). Acute vision loss may result from conditions that cause rapid changes in the transparency of these tissues.

### **Corneal edema**

One cause of sudden opacification of the cornea is corneal edema, which is recognized by a dulling of the normally crisp reflection of incident light off the cornea. The cornea, crystal-clear when healthy, takes on a ground-glass appearance.

A common cause of corneal edema is increased IOP. Acute vision loss accompanying an attack of angle-closure glaucoma (an ocular emergency) is largely the result of corneal edema (see Fig 4-10), but should be associated with pain. Corneal endothelial cell dysfunction due to dystrophies, or sometimes following intraocular surgery, can result in corneal edema, but the vision loss generally has a gradual onset. Any acute infection or inflammation of the cornea (eg, herpes simplex keratitis) may mimic corneal edema. Vision loss without pain due to a corneal opacity is nonurgent.

### **Hyphema**

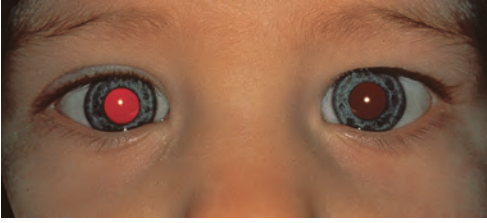
Blood in the anterior chamber is known as a *hyphema* (see Fig 5-3). Any significant hyphema reduces vision, and a complete hyphema will reduce vision to light perception only. Lesser degrees of hyphema may not affect visual acuity. Most hyphemas are the direct consequence of blunt trauma to a normal eye; however, the presence of abnormal iris vessels (which occurs with tumors, diabetes mellitus, intraocular surgery, and chronic inflammation—all causes of neovascularization) predisposes the patient to hyphema, which may be spontaneous (not associated with trauma). A hyphema is an urgent condition.

### **Cataract**

Most cataracts develop slowly. The rare patient may interpret rapid progression of a cataract as sudden vision loss. Even in a patient with a clear lens, sudden changes in blood sugar or serum electrolytes can alter the hydration of the lens. These changes in lens hydration can result in large fluctuations in refractive error, which may be interpreted by the patient as vision loss. In this situation, acuity may simply be improved with refraction. Vision loss secondary to a cataract is nonurgent.

### **Vitreous hemorrhage**

Bleeding into the vitreous (Fig 2-1) reduces vision in the same way that hyphema does: in relation to the amount and location of opaque blood. Large vitreous hemorrhages may occur after trauma and in any condition causing retinal neovascularization (eg, proliferative diabetic retinopathy, retinal vein occlusion, or proliferative sickle cell retinopathy).



**FIGURE 2-1** Vitreous hemorrhage seen in red reflex. Ophthalmoscopic examination reveals a darkened red reflex from the patient's left eye resulting from a vitreous hemorrhage. (Courtesy of Kellogg Eye Center, University of Michigan.)

Retinal tears may present with a vitreous hemorrhage. In addition, vitreous hemorrhage may accompany subarachnoid hemorrhage and is one cause of vision loss from intracranial aneurysms. Vitreous hemorrhage may be difficult to appreciate when viewed with the ophthalmoscope, especially through an undilated pupil. If the red reflex cannot be seen but the lens appears clear, vitreous hemorrhage should be suspected. Diagnosis can be confirmed by an ophthalmologist with slit-lamp examination through a dilated pupil. A vitreous hemorrhage is an urgent condition.

### Painless, Acute Vision Loss With Clear Media

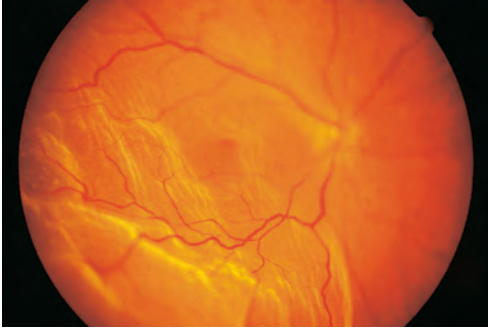
Painless acute vision loss with a clear media is a result of a retina, optic nerve, or visual pathways process.

#### Retinal disease

Retinal detachment, macular disease, and retinal vascular occlusion are all associated with painless, sudden vision loss. Acute vision loss may develop in any inflammatory process that affects the retina, including infectious chorioretinitis, vasculitides, and idiopathic inflammation. These conditions may be distinguished from other causes of acute vision loss by their ophthalmoscopic findings.

**RETINAL DETACHMENT** Acute vision loss is a feature of an extensive retinal detachment. Typically, the patient with a retinal detachment (Fig 2-2) complains of flashing lights, called *photopsia*, followed by many floaters and then a shade over the vision in 1 eye. A detachment extensive enough to reduce visual acuity may exhibit a relative afferent pupillary defect in the involved eye. The diagnosis of an extensive retinal detachment is made by ophthalmoscopy through the dilated pupil. The retina appears elevated, sometimes with folds, and the choroidal background is indistinct. However, the findings may not be obvious, and urgent ophthalmologic consultation is indicated if retinal detachment is suspected.

**MACULAR DISEASE** Macular disease reduces visual acuity, but unless the disease is extensive, a relative afferent pupillary defect may not be present. Sudden vision loss or

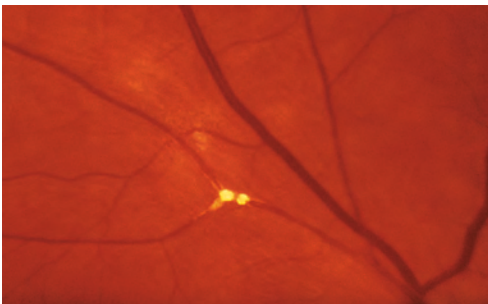

**FIGURE 2-2** Retinal detachment. A wide-angle photograph of the fundus reveals folds of retina extending into the macula inferotemporal to the disc. In this photograph, the focus is on the elevated retina, which renders the disc slightly out of focus.

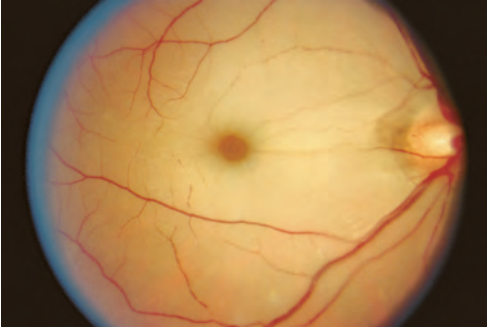
metamorphopsia (a defect of central vision in which the shapes of objects appear distorted) from macular disease is often a sign of bleeding from a neovascular net formed as part of the process of age-related macular degeneration (see Chapter 3). If neovascularization is identified it may be treated with an injection of a medication that causes inhibition and regression of the pathologic vessels, or with laser surgery. Macular disease is, in general, a nonurgent condition.

**RETINAL VASCULAR OCCLUSION** Retinal vascular occlusion is a relatively common cause of sudden vision loss and may be transient or permanent. Transient monocular vision loss due to arterial insufficiency is called *amaurosis fugax* and is a very important symptom. In a patient over age 50, the report of vision loss in 1 eye lasting for several minutes should lead to investigation of the ipsilateral carotid circulation, looking for an atheroma. The valves and chambers of the heart should also be investigated, looking for an embolic source causing transient interruption of blood flow to the retina (Fig 2-3). The evaluation and management of such a patient raises complicated issues, and referral should be made to an ophthalmologist, a neurologist, or a vascular surgeon, depending on the results of the workup.

**CENTRAL RETINAL ARTERY OCCLUSION** Prolonged interruption of retinal arterial blood flow causes permanent damage to the ganglion cells and other tissue elements. Central retinal artery occlusion (CRAO, Fig 2-4) is manifested as a sudden, painless, and often severe



**FIGURE 2-3** Cholesterol embolus in retinal arteriole. In the elderly, the most common sources of emboli are fibrin and cholesterol from ulcerated plaques in the wall of the carotid artery. The so-called *Hollenhorst plaque* is a cholesterol embolus that lodges at an arterial bifurcation, as shown here.



**FIGURE 2-4** Central retinal artery occlusion. The retina is opaque, except for the relatively thin area within the macula, producing the “cherry-red spot.”

vision loss. The ophthalmoscopic appearance depends on how soon after the vision loss the fundus is examined. Within minutes to hours, the only findings may be vascular stasis: narrowing of arterial blood columns and interruption of venous blood columns with the appearance of “boxcarring” as rows of corpuscles are separated by clear intervals.

Some hours after a CRAO, the inner layer of the retina becomes opalescent. The loss of the normal transparency of the retina is most visible ophthalmoscopically where the retina is thickest around the fovea. In the fovea itself, the inner layers are attenuated, and the underlying intact choroidal circulation is seen. Pallor of the perifoveal retina stands in contrast to the normal color of the fovea, causing the characteristic “cherry-red spot” of CRAO. (A chronic cherry-red spot is also a feature of storage diseases, such as Tay-Sachs disease, and some variants of Niemann-Pick disease, in which the ganglion cells become opalescent because of the deposition of intermediate metabolites.)

The optic disc, which is supplied by other branches of the ophthalmic artery, does not swell unless the occlusion is in the ophthalmic or carotid artery, proximal to the origin of the central retinal artery or in the small vessels supplying the disc. The peculiarities of the eye’s vascular supply also can explain the possible preservation of some vision in the presence of a complete CRAO. If part of the retina derives its blood supply from the choroidal circulation via a cilioretinal artery, its function is spared. After a CRAO, the retinal edema slowly resolves, and the death of the ganglion cells and their axons leads to optic atrophy. Months later, the characteristic ophthalmoscopic appearance is a pale disc in a blind eye.

When ophthalmoscopy reveals an acute CRAO, immediate treatment is warranted unless circulation has already been restored spontaneously. *This is a true ophthalmic emergency*; restoration of blood flow may preserve vision if the occlusion is only a few hours old. Instances have been reported in which vision returned after treatment of an occlusion that had been present for several days. In a blind eye, there is little to lose by aggressive measures, and an ophthalmologist’s advice should be obtained emergently.

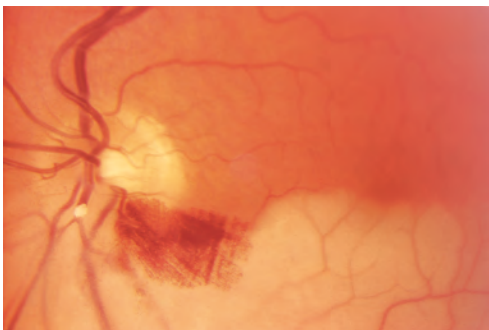
As an emergency measure, the primary care physician may wish to compress the eye with the heel of the hand, pressing firmly for 10 seconds and then releasing for 10 seconds

over a period of approximately 5 minutes. The sudden rise and fall in IOP could serve to dislodge a small embolus in the central retinal artery and restore circulation before the retinal tissues sustain irreversible damage. An ophthalmologist might employ more vigorous and invasive techniques, such as medications to lower IOP, vasodilators, and paracentesis of the anterior chamber. Although most retinal artery occlusions are embolic in nature, central or branch retinal artery occlusion in an elderly patient without a visible embolus should be evaluated for giant cell arteritis.

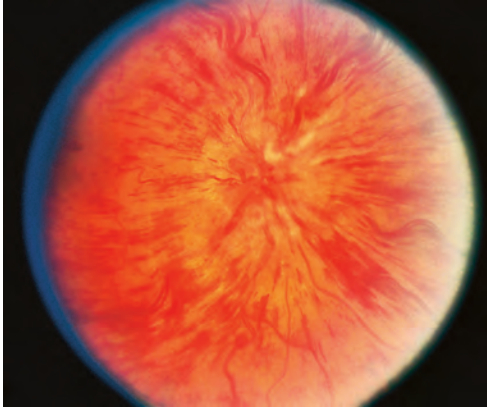
**BRANCH RETINAL ARTERY OCCLUSION** When only a branch of the central retinal artery is occluded, only a sector of the retina opacifies, producing only a partial loss of vision. The patient often knows the moment of vision loss and may be able to describe or draw the exact outline of the missing area of vision. A branch retinal artery occlusion (BRAO, Fig 2-5) is more likely to be the result of an embolus than is a CRAO, and a source should be sought. If visual acuity is affected, attempts should be made to dislodge the embolus by ocular massage, as discussed above. A BRAO is an urgent condition.

**CENTRAL RETINAL VEIN OCCLUSION** The ophthalmoscopic picture of disc swelling, venous engorgement, cotton-wool spots (which appear as small white patches on the retina), and diffuse retinal hemorrhages indicates a central retinal vein occlusion (CRVO, Fig 2-6). Vision loss may be severe, although the onset is generally subacute, unlike the dramatic sudden blindness of CRAO. The fundus picture can be so striking that the description “blood and thunder” is applied. Despite its dramatic appearance, there is no generally accepted acute management. A CRVO is not a true ophthalmic emergency and should be seen by the ophthalmologist on an urgent basis.

A CRVO is most often encountered in older patients with hypertension and arteriosclerotic vascular disease, and the patient’s blood pressure should be checked. Carotid artery occlusion may produce a similar but milder fundus picture. In rare cases, diseases that increase blood viscosity—such as polycythemia vera, sickle-cell disease, and lymphoma-leukemia—induce a CRVO.



**FIGURE 2-5** Branch retinal artery occlusion. Inferotemporal branch retinal artery obstruction. (Courtesy of Cynthia A. Bradford, MD.)



**FIGURE 2-6** Central retinal vein occlusion. Dilated and tortuous veins, flame-shaped hemorrhages, and cotton-wool spots characterize this condition. Sometimes this is referred to as a “blood and thunder” retinal appearance.

The acute hemorrhages and disc swelling resolve with time; however, they may be followed by the development of shunt vessels from the retinal to the choroidal circulation or by ocular neovascularization. The patient with a CRVO needs a general medical evaluation and follow-up by an ophthalmologist, who may be able to prevent the late complication of neovascular glaucoma in susceptible patients by performing laser photocoagulation surgery of the ischemic retina.

### Optic nerve disease

Conditions affecting the optic nerve can often result in acute vision loss. Although the optic nerve head may or may not appear normal initially by ophthalmoscopy, pupillary responses are usually abnormal in unilateral disease.

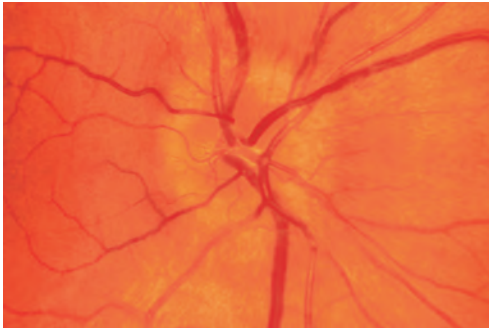
**OPTIC NEURITIS** Optic neuritis is an inflammation of the optic nerve that is usually idiopathic but may be associated with multiple sclerosis in a significant number of cases. Reduced visual acuity and a relative afferent pupillary defect are regular features of optic neuritis. The patient may complain that colors appear desaturated or washed out and that things appear darker when viewed with the affected eye. The optic disc appears hyperemic and swollen (the disc margin is blurred and no discrete edge can be discerned). The prognosis for the return of vision after a single attack of optic neuritis is good. Patients with suspected optic neuritis should be referred to an ophthalmologist for further evaluation. Certain patients with optic neuritis may benefit from high-dose intravenous corticosteroids (oral corticosteroids are contraindicated) and should be evaluated on an urgent basis.

**RETROBULBAR OPTIC NEURITIS** A young adult who is experiencing a monocular, stepwise, progressive loss of vision that has developed over hours to days and that is often accompanied by pain on movement of the eye but who shows no abnormalities on ophthalmoscopic examination probably has retrobulbar optic neuritis. Again, vision

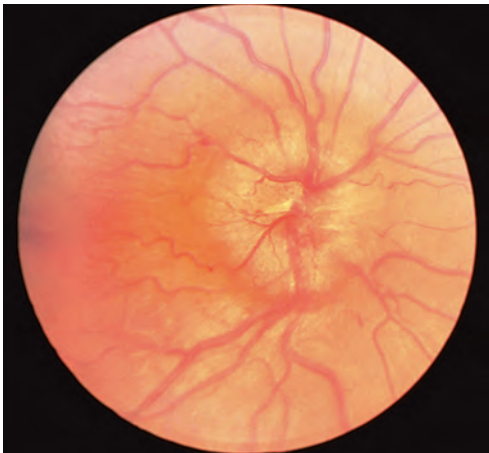


is usually poor and an afferent pupillary defect is present. Evaluation and treatment is similar to optic neuritis. Included in the differential diagnosis of retrobulbar optic neuritis is *compressive optic neuropathy*, which can appear as acute vision loss. The pattern of visual field loss may point to a noninflammatory cause, for example, by a finding of visual field loss in the other eye. Computed tomography or magnetic resonance imaging of the orbits and chiasmal region will identify most compressive lesions, which are potentially treatable with surgery.

**PAPILLITIS AND PAPILLEDEMA** Like retrobulbar optic neuritis, papillitis (Fig 2-7) is a subtype of optic neuritis. Specifically, *papillitis* is an inflammation of the optic disc, or papilla. *Papilledema* (Fig 2-8), on the other hand, refers to swelling of the optic disc from increased intracranial pressure; both optic discs are affected. In optic neuritis (either retrobulbar neuritis or papillitis), vision is usually (but not always) significantly decreased, and examination of the pupils will reveal a relative afferent pupillary defect. In papilledema, the visual acuity and the pupillary reflexes are usually normal. In both conditions, fundus examination will reveal blurred optic disc margins, and the optic disc cupping is typically obliterated. Urgent referral is recommended.



**FIGURE 2-7** Papillitis. The disc is swollen, with blurred disc margins. In papillitis, the disc is hyperemic, rather than pale as in ischemic optic neuropathy. Papillitis is usually unilateral. Bilateral papillitis can be differentiated from papilledema based on decreased visual acuity in papillitis.



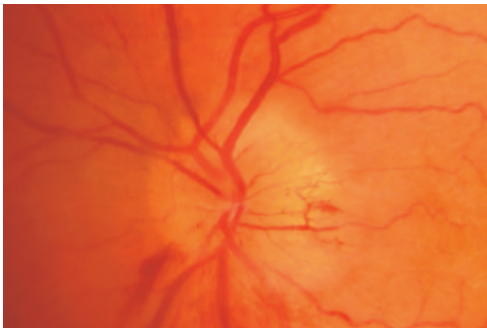
**FIGURE 2-8** Papilledema. The optic disc is elevated and the margins are indistinct. There is microvascular congestion on the disc, the retinal veins are dilated, and flame-shaped hemorrhages are present. The appearance in the other eye should be similar.

Some patients with acute papilledema complain of momentary blurring or transient obscurations of vision. Although chronic papilledema may lead to loss of vision, most patients with acute papilledema suffer only minor alterations in vision. Emergent imaging of the head to identify an intracranial mass is indicated. Patients with pseudotumor cerebri (idiopathic intracranial hypertension) will have papilledema without a midline shift on imaging, and a spinal tap is necessary to document increased intracranial pressure.

**ISCHEMIC OPTIC NEUROPATHY** Swelling of the disc accompanied by vision loss in an older adult is likely to represent a vascular event rather than inflammation. *Ischemic optic neuropathy* (Fig 2-9) is a vascular disorder that presents as a pale, swollen disc, often accompanied by splinter hemorrhages and loss of visual acuity and visual field. The field loss with ischemic neuropathy is often predominantly in the superior or inferior field, a pattern known as *altitudinal*. Emergent management is recommended to evaluate for possible giant cell arteritis.

**GIANT CELL ARTERITIS** The development of acute ischemic optic neuropathy in a patient over age 50 raises the possibility of giant cell, or temporal, arteritis. Patients being considered for the diagnosis of giant cell arteritis should undergo a focused review of systems. Common complaints associated with giant cell arteritis are temporal headache or tenderness, often causing pain while resting on a pillow; scalp tenderness with hair brushing; ear or anterior neck discomfort (carotidynia); fatigue or pain in the tongue or jaw with chewing (jaw claudication); and episodes of transient diplopia or vision loss. Other complaints include anorexia, weight loss, general malaise, and aching/fatigue of the upper arms or legs (polymyalgia rheumatica).

Even in an otherwise asymptomatic elderly patient who has ischemic optic neuropathy (or, for that matter, a central retinal artery occlusion or an unexplained ophthalmoplegia, a paresis of extraocular movement), an erythrocyte sedimentation rate and a C-reactive protein level should be obtained immediately. Many elderly people with giant cell arteritis have markedly elevated sedimentation rates, to greater than 60 mm per hour. If the



**FIGURE 2-9** Ischemic optic neuropathy. This figure shows pale swelling of the optic disc, with associated flame-shaped hemorrhages.



sedimentation rate is elevated or if there are other symptoms or signs of giant cell arteritis, treatment with high-dose systemic corticosteroids is mandatory unless there is a very strong contraindication to their use. This course of treatment may preserve vision in the remaining eye and prevent vascular occlusions elsewhere that would cause stroke or myocardial infarction. *Immediate referral to an ophthalmologist is indicated if giant cell arteritis is a strong diagnostic possibility.* Biopsy of the temporal artery may demonstrate pathologic changes that confirm the diagnosis: giant cells, fragmentation of the internal elastic lamina with surrounding chronic inflammation, and, sometimes, occlusion of the vessel.

If no systemic arteritis is demonstrated, there is no clear evidence that systemic corticosteroids benefit patients with ischemic optic neuropathy. Unfortunately, there is an approximately 40% chance that the other eye will become involved with nonarteritic ischemic optic neuropathy, with or without treatment.

**TRAUMA** Another potential cause of vision loss due to involvement of the optic nerve (traumatic optic neuropathy) is trauma. Vision loss may be mild to severe and may recover spontaneously. In a small number of cases, concussive head trauma shears the vascular supply to the optic nerve, producing blindness. Treatment with high-dose intravenous corticosteroids or surgical decompression of the optic canal may be undertaken in selected cases. Urgent referral is recommended in these patients.

### Visual pathway disorders

The following disorders should be considered in occurrences of acute, painless vision loss with a clear media. In general, visual pathway disorders should be evaluated emergently for cerebral vascular accidents.

**HEMIANOPIA** The cerebral visual pathways are susceptible to involvement by vascular events or tumors. In older people, a *homonymous* hemianopia, defined as loss of vision on 1 side of both visual fields, may result from occlusion of 1 of the posterior cerebral arteries with infarction of the occipital lobe. Other vascular events occurring in the middle cerebral artery distribution also may produce a hemianopia, but usually other neurologic signs are prominent. Almost any patient with a hemianopia warrants examination by cerebral computed tomography or magnetic resonance imaging to localize and identify the cause. (See Chapter 7 for more information about hemianopic visual field loss.)

**CORTICAL BLINDNESS** Much rarer than a hemianopia is extensive bilateral damage to the cerebral visual pathways resulting in complete loss of vision. This condition is referred to variously as *cortical*, *central*, or *cerebral blindness*. Because the pathways serving the pupillary light reflex separate from those carrying visual information at the level

of the optic tracts, a cortically blind patient has normal pupillary reactions. This finding, along with a normal fundus on ophthalmoscopic examination, helps make the diagnosis of cortical blindness. Transient cortical blindness has been observed in children after concussive head trauma.

## Functional Disorders

The adjective *functional* is used in preference to *hysterical* or *malinger* to describe vision loss without organic basis. Often the diagnosis is apparent because the examination produces results incompatible with organic blindness. For example, the patient who reports complete blindness in 1 eye and normal vision in the other but has normal stereopsis and no relative afferent pupillary defect most likely has a functional disorder. In other patients, sophisticated ophthalmologic examinations may be necessary to make an accurate diagnosis.

### Acute discovery of chronic vision loss

A surprising number of cases of chronic vision loss turn up as acute discoveries. Because the eyes usually function together, this sudden discovery of what has actually been an ongoing problem is most likely to occur when the vision in 1 eye is normal. A person who claims acute vision loss in 1 eye but has advanced optic atrophy must have had a prolonged but unrecognized problem. In doubtful cases, it is desirable to obtain records of previous formal eye examinations before accepting vision loss as an acute event and proceeding with expensive or invasive workups.

## ●●● POINTS TO REMEMBER

- Early, accurate diagnosis and timely treatment are critical to a positive visual outcome in cases of acute vision loss.
- Patient ocular history, including timing, tempo, pain, and unilaterality or bilaterality of vision loss, as well as medical history and prior visual acuity, are important to making an accurate diagnosis.
- Pupillary responses, visual field testing, and ophthalmoscopy to evaluate the red reflex and the fundus are particularly valuable in determining the causes of acute vision loss.
- The following conditions require emergency measures and referral: acute central retinal artery occlusion, ischemic optic neuropathy if suspected to be related to giant cell arteritis, and suspected cerebral vascular accidents.

## SAMPLE PROBLEMS

1. A 70-year-old man notes sudden profound loss of vision in his right eye, with onset 2 hours ago. The vision loss has not changed since the onset. The patient has a past medical history of hypertension. On examination, the visual acuity is OD hand motion and OS 20/20. The right pupil does not respond to light directly but does react consensually. The left pupil reacts to light directly but not consensually. The swinging-flashlight test confirms a right relative afferent pupillary defect (Marcus Gunn pupil). The direct ophthalmoscope shows that the red reflex is clear in both eyes. Retinal examination reveals a white, opacified retina with a cherry-red macular spot. The left retina is normal. You diagnose a central retinal artery occlusion. What is the proper management?

**Answer:** You apply pressure to the patient's right eye by placing the heel of your hand on the patient's closed eyelid and pressing and releasing several times. The goal of this ocular massage is to dislodge a retinal embolus. Lowering the IOP using intravenous acetazolamide or topical glaucoma drops may also help dislodge the embolus. Immediate ophthalmologic consultation is indicated. The patient should be evaluated for the cause of this retinal vascular event. Because the retina is neural tissue and survives complete circulatory deprivation poorly, the prognosis for recovery of useful vision in the affected eye is guarded. It is important to detect underlying disease or a site of embolus formation (eg, carotid atheroma, cardiac valvular disease) that might lead to future vascular occlusions. Less commonly, a central retinal artery occlusion may be caused by giant cell arteritis.

2. A 24-year-old woman notes sudden vision loss in her left eye. She is in otherwise good health. On examination, her visual acuity is OD 20/20, OS 20/100. Examination of the pupillary light reflexes with the swinging-flashlight test reveals a relative afferent pupillary defect OS. The anterior segment examination is normal. The red reflex is clear in both eyes. The retinal examination is normal in the right eye but reveals a swollen optic disc in the left eye. What is your course of action?

**Answer:** The findings of sudden reduced acuity, clear ocular media, a relative afferent pupillary defect, and a swollen optic disc in a healthy young woman suggest a diagnosis of optic neuritis. Consultation with a neurologist and an ophthalmologist or a neuro-ophthalmologist is indicated. After a neurologic assessment, the patient may need additional testing such as magnetic resonance imaging and assessment of cerebrospinal fluid. In some cases, treatment with intravenous corticosteroids is indicated. The majority of patients with optic neuritis can expect improvement in their vision. Some patients with optic neuritis develop multiple sclerosis.

3. A 90-year-old woman has recently noticed vision loss OD, along with a persistent right-sided headache, generalized fatigue, and a 10-pound weight loss. Your examination reveals a visual acuity of OD 20/80 and OS 20/30. There is a right relative afferent pupillary defect. Confrontation visual field assessment shows inferior visual field loss in the right eye; the left eye is normal. On dilated retinal examination, the right optic disc is swollen, and there are flame-shaped hemorrhages around the disc. What is your course of action?

**Answer:** Your index of suspicion should be high for giant cell arteritis in this elderly patient, due to the sudden vision loss, afferent pupillary defect, swollen disc, weight loss, and headache. You should obtain stat erythrocyte sedimentation rate and C-reactive protein tests and refer the patient to an ophthalmologist immediately. The patient will need high-dose corticosteroid treatment to preserve vision in the fellow eye and prevent other systemic complications. A biopsy of the temporal artery should be obtained to confirm the clinical diagnosis of giant cell arteritis.

4. A healthy 48-year-old man complains of seeing “floating black dots” in the field of vision of his right eye for 2 days, associated with the sensation of brief flashing lights in the periphery of his visual field. He states that he has a disturbance in the temporal field of vision of his right eye, “like a curtain coming down.” His visual acuity is OU 20/20. Pupils are normal. Confrontation visual field examination shows mild temporal visual field loss in the right eye only. Anterior segment exam is normal. The red reflex is clear in the left eye, but the red reflex in the right eye reveals mobile opacities. A retinal examination with the direct ophthalmoscope is normal. What is your course of action?

**Answer:** This patient needs prompt ophthalmologic consultation. The symptoms of new onset of floaters, flashing lights, and peripheral visual field loss are suggestive of retinal detachment. Floaters sometimes indicate red blood cells in the vitreous due to a retinal tear. Floaters may be visible to the patient but difficult to appreciate with the ophthalmoscope. If the vitreous blood is significant, it can be visualized in the red reflex as dark, mobile spots. Because the retina has no sensitivity to pain and is, in fact, limited to the sensation of light, the patient may report flashes of light as the retina tears or detaches. Retinal tears and early retinal detachments are usually located in the far periphery of the retina and may not be visible with the direct ophthalmoscope. In this patient, even though the initial examination is normal, the symptoms alone indicate the need for referral.

## ANNOTATED RESOURCES

Beck RW, Cleary PA, Trobe JD, et al. The effect of corticosteroids for acute optic neuritis on the subsequent development of multiple sclerosis. The Optic Neuritis Study Group. *N Engl J Med.*

- 1993;329:1764–69. In this multicenter randomized controlled clinical trial involving 389 patients without known multiple sclerosis, short-term, high-dose, intravenous corticosteroid administration appeared to reduce the rate of development of the disease over a 2-year period. Gal RL, Vedula SS, Beck R. Corticosteroids for treating optic neuritis. *Cochrane Database Syst Rev*. 2015;8:CD001430. doi: 10.1001/archneur.65.6.727.
- Optic Neuritis Study Group. Multiple sclerosis risk after optic neuritis: final optic neuritis treatment trial follow-up. *Arch Neurol*. 2008;65(6):727–32. This is the 15-year follow-up of the 389 patients without known multiple sclerosis (MS). The presence of brain MRI abnormalities at the time of an optic neuritis attack was found to be a strong predictor of the 15-year risk of MS.
- Miller NR, Subramanian P, Patel V, eds. *Walsh & Hoyt's Clinical Neuro-Ophthalmology: The Essentials*. 3rd ed. Philadelphia: Wolter Kluwer Health/Lippincott Williams & Wilkins; 2016. This book distills the extensive 3-volume text for easier reading and quicker reference of neuro-ophthalmologic disorders. Section I provides information on disorders of the optic nerve and acute vision loss.
- Riordan-Eva P, Cunningham ET Jr, eds. *Vaughan and Asbury's General Ophthalmology*. 18th ed. New York: McGraw Hill Medical; 2011. The chapter on neuro-ophthalmology provides additional information on causes of acute vision loss.
- Salvarani C, Cantini F, Boiardi L, et al. Polymyalgia rheumatica and giant cell arteritis. *N Engl J Med*. 2002;347:261–71. A review of ocular and systemic manifestation of these disorders.

## CHAPTER 4

# The Red Eye

### OBJECTIVES

As a primary care provider, you should be able to determine whether a patient with a red eye requires the prompt attention of an ophthalmologist or whether you can appropriately evaluate and treat the condition. To achieve this objective, you should learn to

- obtain an accurate ocular history and perform an examination
- differentiate between acute and chronic conditions
- recognize the signs of a red eye that indicate a vision-threatening condition
- describe the treatment for those cases you can manage and recognize the more serious problems that should be referred
- describe the serious complications of prolonged use of topical anesthetic and corticosteroid drops

### Relevance

A primary care provider frequently encounters patients who complain of a red eye. The condition causing the red eye is often a simple disorder, such as a subconjunctival hemorrhage or an infectious conjunctivitis. These conditions either resolve spontaneously or can be treated easily by the primary care provider. Occasionally, the condition causing a red eye is a more serious disorder, such as intraocular inflammation, corneal inflammation, or acute glaucoma. A patient with one of these vision-threatening conditions requires the urgent attention of an ophthalmologist, whose specialized skills, knowledge, and examining instruments are needed in order to make correct therapeutic decisions.

## Basic Information

Red eye refers to *hyperemia*, or injection of the superficially visible vessels, of the conjunctiva, episclera, or sclera. Hyperemia can be caused by disorders of these outer structures or of the cornea, iris, ciliary body, and ocular adnexa. An accurate history followed by exam will aid in narrowing the differential diagnosis and instituting appropriate management.

## History

When a patient presents with a red eye, taking a thorough history is essential. Occasionally a red eye may indicate systemic disease; therefore, a complete medical history and review of systems is required.

Additional questions to ask include

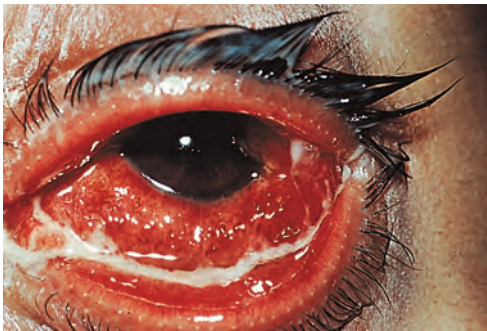- Was the onset sudden or progressive?
- What is the timeline of symptoms; hours, days, or intermittent?
- Any family members with a red eye recently (ie, exposure to people with the same symptoms)?
- Is the patient using any over-the-counter or prescription eye medications?
- Is there a history of trauma or out-of-the-ordinary activity recently?
- Has the patient had recent eye surgery? (If so, immediately refer the patient to the surgeon who performed the procedure.)
- Does the patient wear contact lenses? If so, does the patient sleep in the contacts; when were the contacts last changed, and has anything recently changed regarding care of the lens?
- Has the patient had a recent cold or upper respiratory tract infection?
- Has the vision decreased?
- Is there pain? If so, can the patient describe the pain?
- Is there discharge from the involved eye(s)?
- Is the eye itching?
- Is there light sensitivity?
- Do the symptoms change with environment?

## How to Examine

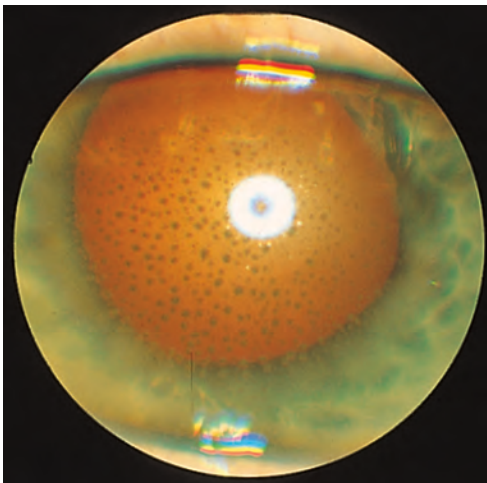
Nine diagnostic steps are used to evaluate a patient with a red eye:

1. Determine whether the visual acuity is normal or decreased, using a Snellen chart (see Chapter 1) or near card.

2. Decide by inspection what pattern of redness is present and whether it is due to subconjunctival hemorrhage, conjunctival hyperemia, ciliary flush, or a combination of these.
3. Detect the presence of conjunctival discharge and categorize it as to amount—profuse or scant—and character—purulent (Fig 4-1), mucopurulent, or serous.
4. Detect opacities of the cornea, including large keratic precipitates (inflammatory deposits on the corneal endothelium, Fig 4-2); corneal edema (Fig 4-3); corneal leukoma (a white opacity caused by scar tissue or corneal infiltrate, Fig 4-4); and irregular corneal reflection (Fig 4-5). Examination is done using a penlight, transilluminator, or slit lamp.
5. Search for disruption of the corneal epithelium by staining the cornea with fluorescein (see Chapter 1).
6. Estimate the depth of the anterior chamber as normal or shallow (see Chapter 1); detect any layered blood or pus, which would indicate either hyphema or hypopyon, respectively. (Compare Fig 4-6, a corneal ulcer with hypopyon, with hyphema, Fig 5-3.)

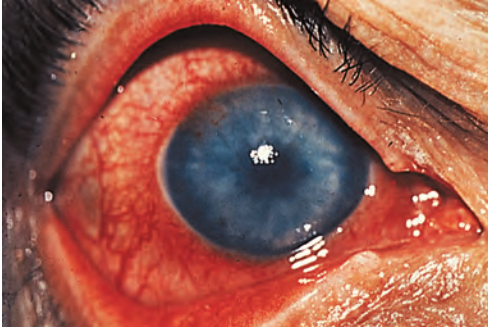


**FIGURE 4-1** Purulent conjunctivitis. With the lower eyelid everted, a creamy-white exudate is visible, highlighted by the conjunctival hyperemia.

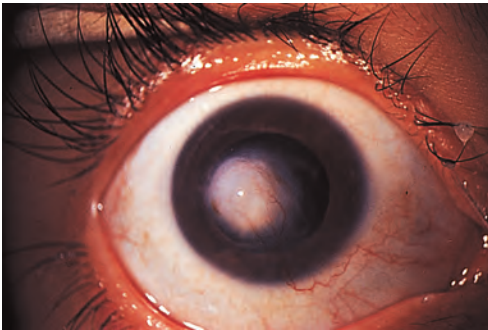


**FIGURE 4-2** Large keratic precipitates. Multiple gray-white opacities on the back surface of the cornea are seen against the background of the red reflex. These precipitates can result from chronic iridocyclitis.

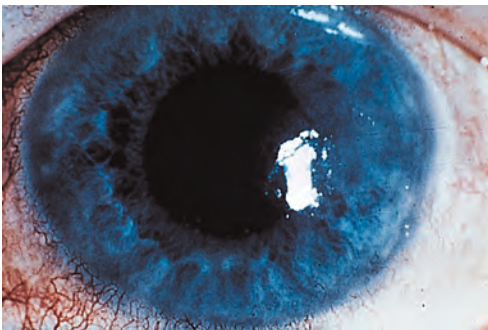




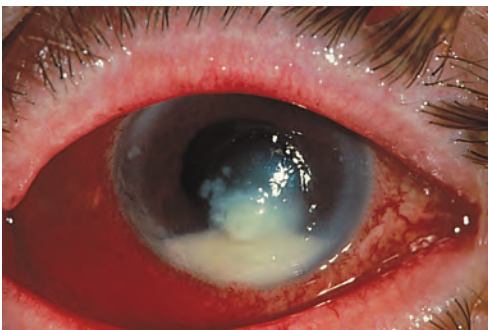
**FIGURE 4-3** Corneal edema. In this fiery red eye, the normally sharp corneal reflex is replaced by a diffuse, hazy appearance. Iris details are not as clear as in a healthy eye.



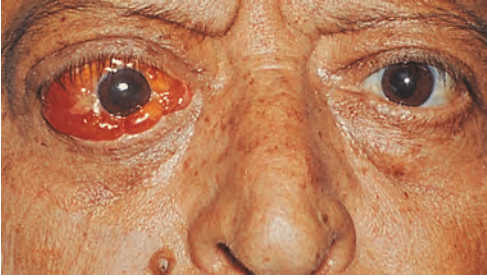**FIGURE 4-4** Corneal leukoma. This dense, white corneal scar represents fibrosis secondary to a previous corneal insult, most frequently trauma or infection. Outside the scar, the cornea is clear. If the scar encroaches on the visual axis, acuity may be impaired.



**FIGURE 4-5** Irregular corneal reflection. This localized irregularity of the normally sharp corneal light reflection indicates local disruption of the corneal epithelium.



**FIGURE 4-6** Corneal ulcer with hypopyon. This inflamed eye shows a white corneal opacity associated with an irregular corneal reflex. In addition, a prominent layering of purulent material appears in the inferior aspect of the anterior chamber, a hypopyon.



**FIGURE 4-7** Chronic proptosis. The right eye of this patient is proptotic, or anteriorly displaced. Marked edema (chemosis) with hyperemia of the conjunctiva is also evident, with tissue prolapse over the lower eyelid margin. The patient has an orbital tumor.

7. Detect irregularity of the pupils and determine whether 1 pupil is larger than the other. Observe the reactivity of the pupils to light to determine whether one pupil is more sluggish than the other or is nonreactive (see Chapters 1 and 7).
8. If elevated intraocular pressure (IOP) is suspected, as in angle-closure glaucoma, and reliable tonometry is available, then measurement of IOP can help confirm the diagnosis. (Tonometry is omitted when there is an obvious external infection.)
9. Detect the presence of proptosis (Fig 4-7), eyelid malfunction, or any limitations of eye movement.

## Disorders Associated With a Red Eye

Classification of a red eye depends primarily on whether the condition is acute or chronic. *Acute* is defined by symptoms starting within days, and *chronic* is defined by symptoms being present for longer than a week.

### The Acute, Painful Red Eye

Symptoms that have begun within days should be assessed primarily for the presence of pain. The painful, red eye is an urgent situation and should be discussed with an ophthalmologist. Arriving to a diagnosis with an acute, painful red eye will rely on the provider assessing each of the anatomic structures of the eye to determine the etiology, starting with the cornea and progressing to the sclera, anterior chamber, and posterior segment.

#### Corneal disorders

Disruption of the corneal epithelium results in significant pain for the patient. This disruption can occur due to trauma, causing a **corneal abrasion** or **foreign body injury**, or due to bacterial or viral infections.

A patient with an abrasion or foreign body will usually give a history of trauma causing the pain. An infectious keratitis will usually occur in a cornea that has been compromised through contact lens use or a previous ocular disorder.

A red eye **associated with soft contact lenses** can be due to poor fit or inadequate lens hygiene. Symptoms can range from mild conjunctival or superficial corneal irritation to a more serious, vision-threatening infection of the cornea. Referral to an ophthalmologist is advised to interpret the subtle slit-lamp findings.

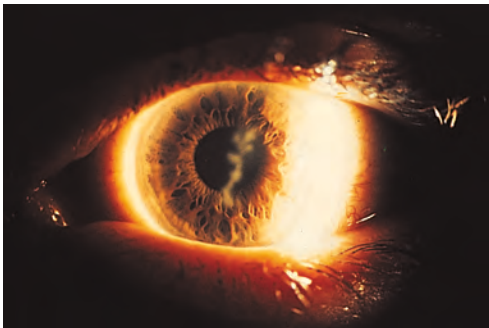Loss of the integrity of the corneal epithelium accompanied with infection or inflammation can result in an **ulcer** with associated hyperemia. Often the normally clear cornea appears hazy or white in the area of the ulcer. Mucus secretions in the eye (called *mattering*) and pain are common as well as photophobia.

**Herpes simplex keratitis** is an infection of the cornea caused by the herpes simplex virus (Fig 4-8). This form of keratitis is common, potentially serious, and can lead to corneal ulceration or scarring. Characteristic dendrites can often be seen in the corneal epithelium.

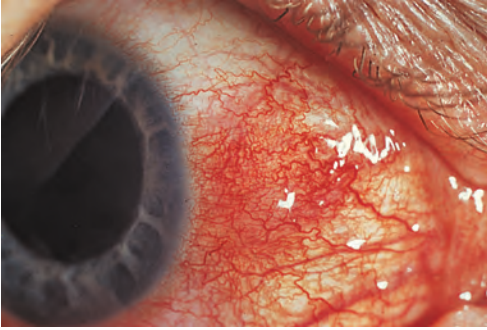
### Scleral inflammations

The sclera is the “white of the eye” and can become inflamed with or without associated autoimmune disease (eg, rheumatoid arthritis, granulomatosis with polyangiitis). **Scleritis** is an inflammation (localized or diffuse) of the sclera (Fig 4-9) that is uncommon, often protracted, and usually accompanied by pain, which may be severe. A violaceous hue of sclera may indicate serious systemic disease such as a collagen vascular disorder.

**Episcleritis** is an inflammation (often sectoral) of the episclera, the vascular layer between the conjunctiva and the sclera. The condition is uncommon and has the following features: no discharge, not vision threatening, and often tender over the inflamed area. If recurrent, it may be associated with an underlying systemic inflammatory disease.



**FIGURE 4-8** Herpes simplex keratitis. In the center of the cornea is an irregular, dendritic (branchlike) lesion of the corneal epithelium.



**FIGURE 4-9** Scleritis. This localized, raised hyperemic lesion is characteristic of scleritis, which is associated with collagen vascular disorders and rheumatoid diseases. In contrast, episcleritis appears flat, involves more superficial tissue, and is usually not associated with serious systemic disease.

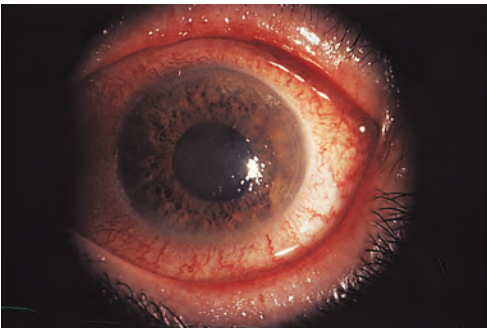
### Anterior chamber disorders

The acute, painful red eye associated with anterior chamber disorders can be categorized into acute glaucoma or acute inflammation. **Acute angle-closure glaucoma** is an uncommon form of glaucoma due to sudden and complete occlusion of the anterior chamber angle by iris tissue (Fig 4-10). The condition is serious. The more common chronic open-angle glaucoma causes no redness of the eye. (See Chapter 3 for a discussion of glaucoma.)

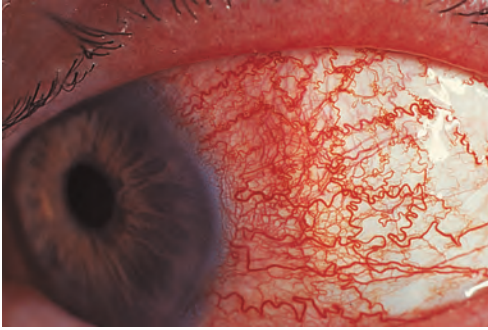
**Iritis** (more strictly iridocyclitis) is an inflammation of the iris alone or of the iris and ciliary body, often manifested by ciliary flush (Fig 4-11). This is a serious condition that requires attention.

### Acute, Nonpainful Red Eye

The nonpainful red eye that develops within days should not be associated with any inflammation of the globe. The condition should be limited to the conjunctiva and is nonurgent. Exceptions to this are patients who cannot “feel” their eye, as in patients with a fifth cranial nerve palsy. Patients who have poor corneal sensitivity and a red eye should be referred urgently to an ophthalmologist.



**FIGURE 4-10** Acute angle-closure glaucoma. The irregular corneal reflection and hazy cornea suggest edema. The pupil is mid-dilated; the iris appears to be displaced anteriorly, with shallowing of the anterior chamber. These findings plus elevated intraocular pressure are diagnostic of acute angle-closure glaucoma.



**FIGURE 4-11** Ciliary flush. Dilated deep conjunctival and episcleral vessels adjacent and circumferential to the corneal limbus cast a violet hue characteristic of ciliary flush and best seen in natural light.

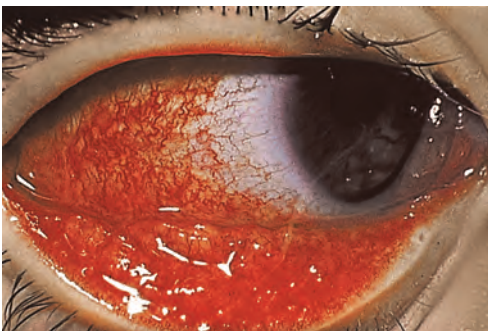
### Subconjunctival hemorrhage

A **subconjunctival hemorrhage** is an accumulation of blood in the potential space between the conjunctiva and the sclera (see Fig 5-9). Although this condition may look alarming, it is rarely vision threatening unless associated with significant ocular trauma. The patient may note some ocular irritation but should not complain of significant pain. Vision should be unaffected.

### Conjunctivitis

**Conjunctivitis** is hyperemia of the conjunctival blood vessels (Fig 4-12). Causes fall into several categories, including bacterial, viral, or allergic; exposure to chemical irritants (including eyedrops); or mechanical irritation (eg, eyelashes or foreign bodies). Conjunctivitis is common and often not serious.

History should guide the provider to the correct diagnosis. A history of a cold or contact with others who have similar symptoms suggests a viral conjunctivitis; in addition, the eyelids will often be stuck together in the morning. Itching is strongly suggestive of an



**FIGURE 4-12** Conjunctivitis. The hyperemia seen here is produced by a diffuse dilation of the conjunctival blood vessels. The dilation tends to be less intense in the perilimbal region, in contrast to the perilimbal dilation of deeper vessels characteristic of ciliary flush.



allergic reaction to topical remedies or environmental exposure. Bacterial conjunctivitis is relatively uncommon; however, a chronic unilateral conjunctivitis should be evaluated for chlamydia while hyperpurulent conjunctivitis suggests gonorrhea and is an urgent condition.

## Chronic, Irritated Red Eye

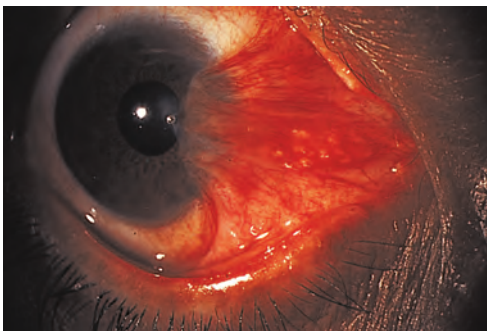The chronic red eye is, in general, a nonurgent condition. Patients can be categorized into whether they experience ocular irritation or not. Ocular irritation associated with a red eye can be due to any process that disrupts a smooth tear film across the surface of the cornea. A systematic approach should closely examine the ocular surface to determine the etiology of the irritation. The surface of the conjunctiva should be examined for any source of the irritation including foreign bodies. The function of the meibomian glands should be assessed to determine if an adequate lipid layer is being produced for the tear film. The surface of the cornea should be examined for evidence of keratopathy using fluorescein. (See Video 1-10.)

### Keratoconjunctivitis sicca

**Keratoconjunctivitis sicca**, commonly called *dry eye*, is a disorder resulting from tear deficiency or dysfunction. It causes pain, blurred vision, light sensitivity (photophobia), and ocular redness.

### Pterygium

**Pterygium** is an abnormal growth consisting of a triangular fold of tissue that advances progressively over the cornea, usually from the nasal side (Fig 4-13). It is usually not serious. Localized conjunctival inflammation may be associated with pterygium. It is



**FIGURE 4-13** Pterygium. This wedge-shaped growth of vascularized conjunctiva extends onto the cornea. The initial sign of pterygium may be a localized chronic conjunctivitis.

associated with ultraviolet exposure and occurs more frequently in tropical climates. Surgical excision is indicated if the pterygium starts to encroach on the visual axis.

## Chronic Red Eye Without Irritation

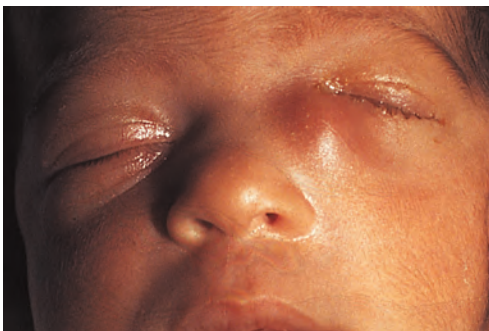The red eye that has no associated irritation is usually due to a congestive process that has resulted in decreased flow of blood in the veins that drain the orbit. Orbital processes that cause a red eye are discussed below.

## Adnexal Disease

Adnexal disease affects the eyelids, lacrimal apparatus, and orbit. Eyelid inflammations include **stye** (hordeolum) and **blepharitis**. A red eye can also occur secondary to **eyelid lesions** (such as basal cell carcinoma, squamous cell carcinoma, or molluscum contagiosum). In general, eyelid inflammations and lesions can be referred to the ophthalmologist nonurgently.

Abnormal **eyelid function**, as seen in Bell palsy and thyroid eye disease, cause ocular exposure and corneal breakdown and may present with a red eye. *Lagophthalmos*, or poor eyelid closure, is also commonly seen in comatose patients. It can result in exposure keratitis, corneal ulceration, and blindness. An eyelid that turns in toward the eye with the lashes contacting the globe surface (entropion) can result in pain, photophobia, tearing, and redness of the eye. A red eye secondary to an eyelid malposition should be discussed with the ophthalmologist urgently.

Lacrimal diseases that can cause a red eye include **dacryocystitis** (Fig 4-14) and **canaliculitis**. **Orbital inflammations**, such as thyroid eye disease, and **vascular lesions** in the orbit may cause a red eye as well. Any lacrimal or orbital disease that causes a red eye should be urgently referred to the ophthalmologist.




**FIGURE 4-14** Dacryocystitis. This obvious, raised erythematous mass represents an acute inflammation of the lacrimal sac, usually secondary to a nasolacrimal duct obstruction. A purulent discharge may be extruded from the eyelid puncta by massage over the lacrimal sac.

## Further Interpretation of the Findings

As noted earlier, several signs and symptoms of a red eye warrant immediate attention. The presence of 1 or more of these findings should alert the provider that the patient has a disorder requiring an ophthalmologist's attention. Tables 4-1 and 4-2 summarize significant symptoms and signs in the differential diagnosis of a red eye.

### Symptoms of a Red Eye

In the symptoms of a red eye that follow, a red symbol  by the heading indicates a danger signal.

#### Blurred vision

Blurred vision often indicates serious ocular disease (see “Reduced Visual Acuity” in the following section, “Signs of a Red Eye”). Blurred vision that improves with blinking suggests a discharge or mucus on the ocular surface.

#### Severe pain

Pain may indicate keratitis, ulcer, iridocyclitis, scleritis, or acute glaucoma. Patients with conjunctivitis may complain of a scratchiness or mild irritation but not of severe pain.

#### Photophobia

Photophobia is an abnormal sensitivity to light that accompanies iridocyclitis, either alone or secondary to corneal inflammation. Patients with conjunctivitis have normal light sensitivity.

#### Colored halos

Rainbow-like fringes or colored halos seen around a point of light are usually a symptom of corneal edema, often resulting from an abrupt rise in IOP. Therefore, colored halos are a danger signal suggesting acute glaucoma as the cause of a red eye.

### Exudation

Exudation, also called *mattering*, is a typical result of conjunctival or eyelid inflammation and does not occur in iridocyclitis or glaucoma. Patients will often complain that their eyelids are “stuck together” on awakening from sleep. Corneal ulcer is a serious condition that may or may not be accompanied by exudate.



TABLE 4-1 Symptoms of a Red Eye							
SYMPTOM	REFERRAL ADVISABLE IF PRESENT	ACUTE GLAUCOMA	ACUTE IRIDO- CYCLITIS	KERATITIS	BACTERIAL CONJUNC- TIVITIS	VIRAL CONJUNC- TIVITIS	ALLERGIC CONJUNC- TIVITIS
Blurred vision	Yes	3	1–2	3	0	0	0
Pain	Yes	2–3	2–3	2	0	0	0
Photophobia	Yes	1	3	3	0	0	0
Colored halos	Yes	2–3	0	0	0	0	0
Exudation	No	0	0	0–3	3	2	1
Itching	No	0	0	0	0	0	2–3

Note: The range of severity of the symptom is indicated by 0 (absent) to 3 (severe).


TABLE 4-2 Signs of a Red Eye							
SIGN	REFERRAL ADVISABLE IF PRESENT	ACUTE GLAUCOMA	ACUTE IRIDO- CYCLITIS	KERATITIS	BACTERIAL CONJUNC- TIVITIS	VIRAL CONJUNC- TIVITIS	ALLERGIC CONJUNC- TIVITIS
Ciliary flush	Yes	+	+	+	–	–	–
Conjunctival hyperemia	No	+	+	+	+	+	+
Corneal opacification	Yes	+	–	+	–	+/–	–
Corneal epithelial disruption	Yes	–	–	+	–	+/–	–
Pupillary abnormalities	Yes	+	+	+/–	–	–	–
Shallow anterior chamber	Yes	+	–	–	–	–	–
Elevated intraocular pressure	Yes	+	+/–	–	–	–	–
Proptosis	Yes	–	–	–	–	–	–
Discharge	No	–	–	+/–	+	+	+
Preauricular lymph-node enlargement	No	–	–	–	–	+	–

Note:   + = Usually has sign  
      – = Does not usually have sign  
      +/– = May or may not have sign

## Itching

Although it is a nonspecific symptom, itching usually indicates an allergic conjunctivitis.

## Signs of a Red Eye

In the signs of a red eye that follow, a red symbol  indicates a danger signal.

### Reduced visual acuity

Reduced visual acuity suggests a serious ocular disease, such as an inflamed or infected cornea, iridocyclitis, or glaucoma. It never occurs in simple conjunctivitis unless there is associated corneal involvement.

### Ciliary flush

Ciliary flush (see Fig 4-11) is an injection of the deep conjunctival and episcleral vessels surrounding the cornea. Seen most easily in daylight, ciliary flush appears as a faint violaceous ring in which individual vessels are indiscernible to the unaided eye. Ciliary flush is a danger sign often seen in eyes with corneal inflammation, iridocyclitis, or acute glaucoma. Usually, ciliary flush is not present in conjunctivitis.

## Conjunctival hyperemia

Conjunctival hyperemia (see Fig 4-12) is an engorgement of the larger and more superficial bulbar conjunctival vessels. A nonspecific sign, it may be seen in almost any of the conditions causing a red eye.

### Corneal opacification

In a patient with a red eye, corneal opacities always denote disease. These opacities may be detected by direct illumination with a penlight, or they may be seen with a direct ophthalmoscope (with a plus lens in the viewing aperture) outlined against the red fundus reflex. Several types of corneal opacities may occur:

- Keratic precipitates, or cellular deposits on the corneal endothelium, usually too small to be visible but occasionally forming large clumps; these precipitates can result from iritis or from chronic iridocyclitis (see Fig 4-2).
- A diffuse haze obscuring the pupil and iris markings, characteristic of corneal edema (see Fig 4-3) and frequently seen in acute glaucoma.
- Localized opacities due to keratitis or ulcer (see Fig 4-6).

### ! Corneal epithelial disruption

Disruption of the corneal epithelium occurs in corneal inflammations and trauma. It can be detected in 2 ways:

1. Position yourself so that you can observe the reflection from the cornea of a single light source (eg, window, penlight) as the patient moves the eye into various positions. Epithelial disruptions cause distortion and irregularity of the reflection (see Fig 4-5).
2. Apply fluorescein to the eye. Diseased epithelium or areas denuded of epithelium will stain a bright green. (See Figs 1-14 and 1-15, Video 1-10, and accompanying text in Chapter 1 for the technique of fluorescein staining.)

### ! Pupillary abnormalities

The pupil in an eye with iridocyclitis typically is somewhat smaller than that of the other eye, due to reflex spasm of the iris sphincter muscle. The pupil is also distorted occasionally by posterior synechiae, which are inflammatory adhesions between the lens and the iris. In acute glaucoma, the pupil is usually fixed, mid-dilated (5–6 mm), and slightly irregular. Conjunctivitis does not affect the pupil.

### ! Shallow anterior chamber depth

In a red eye, a shallow anterior chamber should always suggest the possibility of acute angle-closure glaucoma (see Fig 4-10). Anterior chamber depth can be estimated through side illumination with a penlight. If possible, compare the anterior chamber depth of the red eye with that of the other, unaffected eye. (See Chapter 1 for details on estimating the depth of the anterior chamber.)

### ! Elevated intraocular pressure

IOP is unaffected by common causes of red eye other than iridocyclitis (IOP often low) and glaucoma (IOP often elevated). IOP should be measured when angle-closure glaucoma is suspected. (See Chapter 1 for details on the use of tonometry to measure IOP; also see Video 1-8.)

### ! Proptosis

Proptosis is a forward displacement of the globe. Sudden proptosis suggests serious orbital or cavernous sinus disease; in children, orbital infection or tumor should be suspected.

The most common cause of chronic proptosis is thyroid disease; however, orbital mass lesions also result in proptosis. These lesions should be ruled out early in the diagnosis (see Fig 4-7). Proptosis may be accompanied by conjunctival hyperemia or limitation of eye movement. Small amounts of proptosis are detected most easily by tilting the chin up and looking from the chin over the maxilla at the relative corneal position.

### **Discharge**

The type of discharge may be an important clue to the cause of a patient's conjunctivitis. Purulent (creamy-white, see Fig 4-1) or mucopurulent (yellowish) exudate suggests a bacterial cause. Serous (watery, clear, or yellow-tinged) discharge suggests a viral cause. Scant, white, stringy discharge sometimes occurs in allergic conjunctivitis and in keratoconjunctivitis sicca, a condition commonly known as *dry eye*.

### **Preauricular lymph-node enlargement**

Enlargement of the lymph node just in front of the auricle is a frequent sign of viral conjunctivitis. Usually, such enlargement does not occur in acute bacterial conjunctivitis. Preauricular node enlargement can be a prominent feature of some unusual varieties of chronic granulomatous conjunctivitis, known collectively as *Parinaud oculoglandular syndrome*. Cat-scratch fever can present with these findings.

## **Associated Systemic Problems**

The primary care provider should be aware that systemic conditions may include ocular involvement. (See Chapter 9 for additional details.)

### **Upper respiratory tract infection and fever**

Infection of the upper respiratory tract accompanied by fever may be associated with conjunctivitis, particularly when these symptoms are due to adenovirus type 3 or type 7 (both of which cause pharyngoconjunctival fever). Allergic conjunctivitis may be associated with the seasonal rhinitis of hay fever.

### **Erythema multiforme**

Erythema multiforme is an acute, immune-mediated condition characterized by the appearance of distinctive target-like lesions on the skin. These lesions are often accompanied by erosions or bullae involving the oral, genital, and/or ocular mucosae. Erythema multiforme can result in severe conjunctivitis, irreversible conjunctival scarring, and

blindness. Stevens-Johnson syndrome and toxic epidermal necrolysis are severe mucocutaneous reactions, triggered by medications or infections, characterized by extensive necrosis and detachment of the epidermis. Ocular involvement may include severe conjunctivitis with a purulent discharge. Corneal ulceration is frequent, and anterior uveitis or panophthalmitis may occur. Pain and photophobia are common presenting symptoms. Scarring with the development of synechiae between the eyelids and conjunctiva (symblepharon) may be late sequelae. These conditions should be attended to by an ophthalmologist.

### Laboratory Diagnosis

In practice, most mild cases of conjunctivitis are managed without laboratory assistance. This approach represents a compromise with ideal management, but it is justified by the economic waste of obtaining routine smears and cultures in such a common and benign disease. Most clinicians, after making a presumptive clinical diagnosis of bacterial conjunctivitis, proceed directly to broad-spectrum topical ophthalmic antibiotic treatment. Cases of presumed bacterial conjunctivitis that do not improve after 2 days of antibiotic treatment should be referred to an ophthalmologist for confirmation of the diagnosis and appropriate laboratory studies. In addition, in cases of hyperpurulent conjunctivitis, when copious purulent discharge is produced, conjunctival cultures, and ophthalmologic consultation are indicated due to a possible gonococcal cause. Gonococcal hyperpurulent conjunctivitis is a serious, potentially blinding disease.

In doubtful cases, smears of exudate or conjunctival scrapings can confirm clinical impressions regarding the type of conjunctivitis. Typical findings include polymorphonuclear cells and bacteria in bacterial conjunctivitis, lymphocytes in viral conjunctivitis, and eosinophils in allergic conjunctivitis. Cultures for bacteria and determinations of antibiotic sensitivity are useful in cases resistant to therapy.

### Management or Referral

The following conditions either require no treatment or may be appropriately treated by a primary care provider. Patients with chronic, unilateral blepharitis should be referred to an ophthalmologist to rule out a malignant process such as sebaceous cell carcinoma or squamous cell carcinoma.

Cases requiring prolonged treatment or those in which the expected response to treatment does not occur promptly should also be referred to an ophthalmologist. (See Table 4-3 for a summary of instructions for patients to follow.)

**TABLE 4-3** Summary of Patient Instructions for Conditions Related to a Red Eye

CONDITION	PATIENT INSTRUCTION
Blepharitis	Apply warm compresses and eyelid margin scrubs each morning and before bedtime. Apply ointments or take oral medications as prescribed.
Stye and chalazion	Apply warm compresses to the affected eyelid 2 to 4 times daily. Return for further evaluation if the mass fails to disappear after several weeks. Call sooner if the eyelid mass enlarges, becomes more tender, or begins draining purulent material.
Subconjunctival hemorrhage	Know that without treatment the hemorrhage will resolve in 1 to 2 weeks without any damage to the eye.
Viral conjunctivitis	Apply cool compresses periodically. Use artificial tears if needed. Wash hands frequently and avoid touching eyes and sharing towels. Avoid communal activities as long as discharge is present. Return for referral if symptoms appear to worsen.
Bacterial conjunctivitis	Apply cool compresses periodically and keep eyelids and lashes free of discharge. Use artificial tears as needed for surface irritation. Apply antibiotic eyedrops as prescribed.

## Blepharitis

Response to the treatment of blepharitis, or inflammation of the eyelid, is often frustratingly slow, and relapses are common. The inflammation of the eyelid can primarily be in the anterior aspect of the eyelid, as in staphylococcal blepharitis, or the posterior aspect of the eyelid, as in blepharitis secondary to acne rosacea. Treatment should address the following considerations.

### Eyelid hygiene

Warm compresses (tap water on clean washcloth) can be applied for 3–5 minutes, each morning and before bedtime. If eyelids are oily, follow with eyelid scrubs using dilute baby shampoo (2 drops of shampoo in 2 oz of water).

### Staphylococcal infection

Staphylococcal infection (Fig 4-15) may be present. If so, it should be treated with application of appropriate antibiotic ointment (bacitracin or erythromycin) to the eyelid margin at night for 1 week.

### Associated acne rosacea/meibomian gland dysfunction

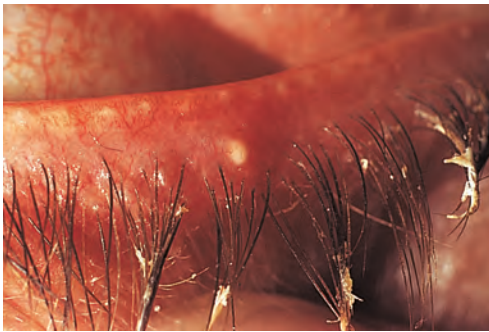
These symptoms should be treated with doxycycline 100 mg twice a day and tapered to once a day for 2 months or longer. Artificial tears may be applied 4–8 times a day as needed for symptoms of dryness.

### Scalp seborrhea

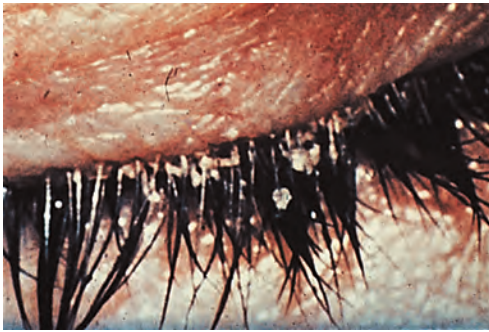
Treatment with antidandruff shampoos can improve symptoms of seborrheic blepharitis (Fig 4-16).

### Contact dermatitis

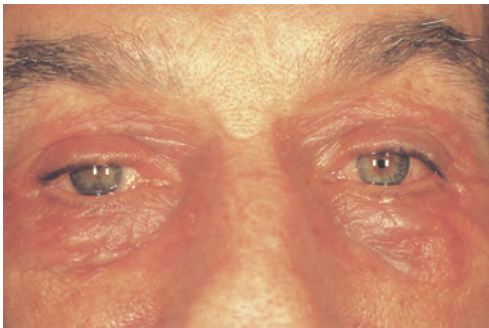
Contact dermatitis (Fig 4-17) can masquerade as blepharitis. A careful history of the eyelid redness associated with application of medication helps make the diagnosis. For example, the glaucoma medication brimonidine can produce a red eye with erythematous, swollen eyelids that have a dry “leathery” texture. Any ocular medication or cosmetics can



**FIGURE 4-15** Staphylococcal blepharitis. Chronic staphylococcal eyelid infection produces inflamed, swollen eyelids that may ulcerate. The oily discharge binds the lashes and sometimes condenses to form a collarette around a lash.



**FIGURE 4-16** Seborrheic blepharitis. The dry, flaky lashes and red eyelid margins seen here are characteristic of seborrheic blepharitis.

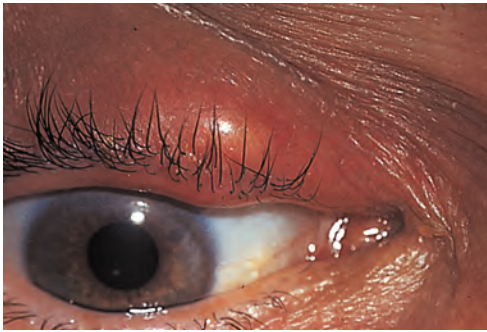


**FIGURE 4-17** Contact dermatitis. Allergic contact dermatitis shown here is secondary to topical ophthalmic medication.

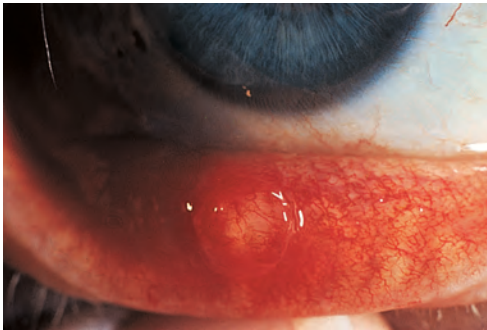
be associated with similar clinical findings. Discontinuing the offending product should result in improvement in symptoms within 48 hours, but healing may take up to 2 weeks.

### Stye and Chalazion

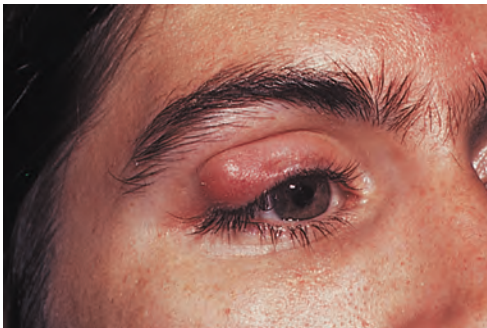A stye, or *hordeolum*, is an acute, usually sterile, inflammation of the glands or hair follicles in the eyelid. Hordeola can be categorized as external or internal, according to where the inflammation is located in the eyelid (Figs 4-18, 4-19). A chalazion is a chronic inflammation of a meibomian gland in the eyelid that may develop spontaneously or may follow a hordeolum (Fig 4-20). A persistent or recurring eyelid mass should undergo



**FIGURE 4-18** External hordeolum. This large, acute swelling, which is red and painful, involves the hair follicles or associated glands of Zeis or Moll and points toward the skin.



**FIGURE 4-19** Internal hordeolum. An acute infection of a meibomian gland produces a swelling directed internally toward the conjunctiva. This figure demonstrates a discrete, circumscribed area of inflammation highlighted by a hyperemic conjunctiva.



**FIGURE 4-20** Chalazion. This large, nontender eyelid mass is a chronic granulomatous inflammation of a meibomian gland.



biopsy because it may be a rare sebaceous gland carcinoma, squamous cell carcinoma, or basal cell carcinoma of the eyelid rather than a benign chalazion.

The mainstays of treatment are the following:

- Apply warm compresses to the eyelid 4 times a day for 3–5 minutes.
- Massage the eyelid and lash line to encourage the glands to open up and drain.
- Apply topical ocular antibiotic ointment to the lash line and over the area if there is tenderness and infection is suspected. Rarely, oral antibiotics may be indicated if there is a secondary bacterial infection.
- Refer the patient for incision and curettage of the lesion if there is no resolution in 3–4 weeks.

### Subconjunctival Hemorrhage

In the absence of blunt trauma, hemorrhage into the subconjunctival space, the potential space between the conjunctiva and the sclera, requires no treatment and, unless recurrent, no evaluation (see Fig 5-9). Causes include a sudden increase in ocular venous pressure, such as occurs with coughing, sneezing, vomiting, or vigorous rubbing of the eye. Many subconjunctival hemorrhages occur during sleep. Some patients may note mild tenderness with the onset of the hemorrhage, but this resolves in 1 or 2 days. If recurrent, an underlying bleeding disorder should be considered. Blood pressure should be measured, as marked elevation can result in subconjunctival hemorrhage.

### Conjunctivitis

There is no specific medicinal treatment for viral conjunctivitis, although patients should be instructed in proper precautions to prevent contagion. Here are some treatments often recommended:

- Apply cool compresses periodically throughout the day.
- Use artificial tears if irritation occurs.
- Apply antibiotic eyedrops (eg, trimethoprim/sulfacetamide or fluoroquinolones) 4–6 times a day if bacterial infection is suspected.
- Minimize spread to other family members and co-workers (eg, washing hands after touching eye secretions, no sharing of towels).

Corticosteroids have limited use in treatment of infectious conjunctivitis. Eyedrops containing a combination of antibiotics and corticosteroids should be used only under the close observation of an ophthalmologist.

## Therapeutic Warnings

Because of possible serious health risks, caution is required in the use of the following therapeutic agents.

### Topical anesthetics

Topical anesthetics should never be prescribed for prolonged analgesia in ocular inflammations and injuries for 3 reasons:

- Topical anesthetics inhibit growth and healing of the corneal epithelium.
- Although rare, severe allergic reaction may result from instillation of topical anesthetics.
- Corneal anesthesia eliminates the protective blink reflex, exposing the cornea to dehydration, injury, and infection.

### Topical corticosteroids

Topical corticosteroids have 3 potentially serious ocular side effects:

- Both herpes simplex keratitis (see Fig 4-8) and fungal keratitis are markedly potentiated by corticosteroids. Corticosteroids may mask symptoms of inflammation, making the patient “feel” better, while the cornea may be melting away or even perforating.
- Prolonged use of corticosteroids, locally or systemically, often leads to cataract formation.
- Local application of corticosteroids for 2–6 weeks may cause an elevation of IOP in approximately one-third of the population. The pressure rise may be severe in a small percentage of cases. Optic nerve damage and permanent loss of vision can occur. The combination of a corticosteroid and an antibiotic carries the same risk. Topical corticosteroids alone or in combination with antibiotics should not be administered to the eye by a primary care provider. They can be very helpful when used under the close supervision of an ophthalmologist.

## ●●● POINTS TO REMEMBER

- If visual acuity is acutely and significantly reduced, a diagnosis of conjunctivitis is extremely unlikely.
- Fluorescein should always be instilled in a red eye to test for integrity of the corneal epithelium.

- A pupillary inequality or irregularity in a patient with red eye(s) is a danger signal for serious ocular disease.
- If the patient wears soft contact lenses, referral to an ophthalmologist is advised because differentiation between mild and severe complications of contact lens wear requires experienced interpretation of slit-lamp findings.
- In obtaining a history for the red eye, the examiner should document all medications applied in and around the eye and then consider them as the potential source of the red eye.

## SAMPLE PROBLEMS

1. A 23-year-old teacher complains that her right eye is red and irritated. You note moderate injection of the larger conjunctival vessels, watery discharge, and a palpable preauricular lymph node.

- A. From this information alone, what tentative diagnosis would you make?

**Answer:** The conjunctival injection and discharge suggest conjunctivitis. The serous nature of the discharge, plus the preauricular adenopathy, indicate that she has viral conjunctivitis.

- B. Again based on the above information, which of the following symptoms or facts might be elicited by careful history-taking?

- a. blurred vision
- b. sore throat
- c. exposure to children with colds
- d. itching

**Answer:** b and c. Sore throat often accompanies viral conjunctivitis; in such cases, a history of exposure to other individuals with upper respiratory tract infections can often be elicited. Blurred vision, a danger signal of serious ocular disease, is not a feature of simple conjunctivitis. Itching is a symptom of allergic, not viral, conjunctivitis.

- C. Management consists of which of the following?

- a. corticosteroid eyedrops
- b. broad-spectrum antibiotic eyedrops
- c. referral to an ophthalmologist
- d. instruction to the patient to use cool compresses and stay home from school until the redness resolves

**Answer:** d. Because the disease is contagious, the patient should be instructed to remain home from work. There is no specific medicinal treatment for viral

conjunctivitis. Corticosteroids may be used only under the close supervision of an ophthalmologist, due to the potential adverse effects of the drop.

2. A young woman complains of a red eye and associated pain above the eye. The patient's mother has chronic open-angle glaucoma and the patient wants to know whether she has the same thing. The patient describes several bouts of having a red, painful, left eye that is relieved by sleeping.
  - A. You notice an irregular pupil in addition to the injection of her left eye. This would be more consistent with which of the following?
    - a. angle-closure glaucoma
    - b. iridocyclitis
    - c. conjunctivitis
    - d. keratoconjunctivitis sicca
    - e. chronic open-angle glaucoma

**Answer:** a and b. Both angle-closure glaucoma and iridocyclitis can have an irregular pupil, pain, and redness. Anterior surface problems like conjunctivitis and keratoconjunctivitis sicca (dry eye) should not result in an irregular pupil. Chronic open-angle glaucoma does not present with a red, inflamed eye. It does not give an irregular pupil.

- B. On further questioning, the patient describes seeing colored halos around lights. What is the most likely diagnosis of those listed in part A, above?

**Answer:** a. angle-closure glaucoma.

3. A 45-year-old man reports a 2-day history of redness, severe pain, and photophobia of his left eye. He denies any trauma to the eye.
  - A. Which signs convince you the patient does not have conjunctivitis?
    - a. visual acuity of 20/200
    - b. conjunctival injection
    - c. ciliary flush
    - d. serous discharge

**Answer:** a and c. Reduced visual acuity, as well as ciliary flush, often signals ocular disease more serious than conjunctivitis.

- B. You note that there is staining of the cornea in a branching pattern. What is the most likely diagnosis?

**Answer:** Keratitis, possibly herpes simplex keratitis.

- C. In possible herpes simplex keratitis, what would your management be?
      - a. a telephone request to an ophthalmologist for immediate examination
      - b. corticosteroid drops to decrease inflammation and follow-up with an ophthalmologist in 3–5 days
      - c. an oral antiviral like acyclovir and follow-up in a week

**Answer:** a. Herpes simplex keratitis is a serious infection and can be vision threatening. Immediate referral is indicated to decrease the potential scarring and permanent loss of vision. Corticosteroid drops are not used initially in a patient with active disease and epithelial staining.

4. A 38-year-old woman complains of a 3-day history of a red, tender right eyelid. Physical examination reveals a tender nodule of the right lower eyelid with minimal injection of the inferior conjunctiva.

A. Which of the following would constitute appropriate management by the primary care provider?

- a. warm compresses
- b. broad-spectrum systemic antibiotics
- c. topical antibiotics
- d. immediate surgical incision and drainage to prevent cellulitis

**Answer:** a and c. The patient has a sty. Because she has only had symptoms for 3 days and the lesion is tender to touch, she would benefit from warm compresses. Topical antibiotic ointment might benefit a small percentage of patients. Incision and drainage is indicated only when lesions do not resolve spontaneously or with medical therapy. Usually surgical intervention occurs only after the lesion has been present for several weeks. Systemic antibiotics are not indicated.

- B. If the patient reports she has had numerous nodules in this same area over the last 5 years, how should the primary care provider change the management plan?

**Answer:** A persistent or recurring eyelid mass should undergo biopsy to rule out an eyelid malignancy. Referral to an ophthalmologist is indicated.

5. An 88-year-old nursing home patient has had red, irritated eyes for months. She feels as if she has “sand in her eyes” all the time. On examination, all eyelid margins are inflamed and edematous with debris on the lashes.

A. What is the most likely diagnosis?

**Answer:** Blepharitis.

B. Treatment would consist of which of the following?

- a. immediate referral to an ophthalmologist
- b. cleansing of the eyelids daily
- c. antibiotic ointment to alleviate any staphylococcal infection

**Answer:** b and c. Blepharitis is a chronic, often relapsing, inflammation of the eyelids that can irritate the eyes. A low-grade bacterial infection may be involved. It is not an ophthalmologic emergency and treatment is long-term daily eyelid hygiene. For difficult cases, an appointment with an ophthalmologist is indicated.

6. A 65-year-old man with history of a recent bronchitis awoke this morning with a red eye and has no other symptoms. He has no significant medical problems.

- A. On examination, the patient has a sector of the eye that is solid red without injection of the conjunctival vessels. What is the most likely diagnosis?
- a. scleritis
  - b. subconjunctival hemorrhage
  - c. early viral conjunctivitis
  - d. pterygium

**Answer:** b. A subconjunctival hemorrhage is in the potential space between the conjunctiva and sclera. The conjunctival and deeper vessels are not injected or inflamed as in conjunctivitis or scleritis. Scleritis can appear in a sector pattern, but is usually associated with pain or tenderness. A pterygium forms due to chronic ultraviolet light exposure and presents over years, not overnight.

- B. The recent bronchitis may be associated with the subconjunctival hemorrhage in what way?

**Answer:** The patient may have had an episode of coughing during the night, resulting in a sudden increase in ocular venous pressure that can cause a subconjunctival hemorrhage. Aggressive eye rubbing can cause a subconjunctival hemorrhage, but more commonly, it occurs without any identifiable precipitating event. Patients with subconjunctival hemorrhage should be questioned about easy bruising, and the blood pressure should be checked.

7. You are called to a nursing home to see an 84-year-old woman with a red, painful eye. When you examine her, you note that visual acuity is decreased in the affected eye and that the lower eyelid appears to be turning in toward the eye.

- A. The cornea appears white and hazy inferiorly, and the patient is complaining of photophobia. What is the most likely diagnosis?
- a. conjunctivitis
  - b. corneal ulcer
  - c. old corneal scar
  - d. scleritis

**Answer:** b. Corneal ulcer. A white and hazy cornea represents either active inflammation or a scar. Pain and photophobia are associated with an active process, not an old corneal scar. Conjunctivitis and scleritis are inflammatory disorders of other parts of the eye, not the cornea.

- B. What is the most likely underlying cause of the corneal problem in this patient?
- a. the eyelid and lashes scraping the cornea with resulting ulceration and infection
  - b. cat-scratch fever
  - c. chronic open-angle glaucoma

**Answer:** a. Entropion is the inward turning of the eyelid in which the lashes may abrade the cornea and cause an epithelial defect. Bacteria can then infect the exposed corneal stroma with resulting inflammation and opacity of the normally clear cornea. Inferior corneal ulceration implicates the lower eyelid as the source of the ulcer. Cat-scratch fever does not usually cause a corneal ulcer, and chronic open-angle glaucoma is not associated with a red eye.

## ANNOTATED RESOURCES

Albert DM, Jakobiec FA, eds. *Principles and Practice of Ophthalmology: Clinical Practice*. 3rd ed. Philadelphia: WB Saunders Co; 2008. This comprehensive text includes information relevant to conditions presenting with red eye.

Tasman W, Jaeger EA, eds. *Duane's Ophthalmology on DVD-ROM: 2013 Edition*. Philadelphia: Lippincott Williams & Wilkins; 2013. This comprehensive work includes discussions of various forms of conjunctivitis and anterior uveitis.

Trobe JD. "The Eyes Have It." Website hosted by the University of Michigan, Kellogg Eye Center. This interactive tool features an instructional mode, where one reviews topics that cover a range of eye problems and manifestations, and a quiz mode that covers eye problems as well as anatomy, the screening examination, signs and symptoms, and more. Available at [www.kellogg.umich.edu/theeyeshaveit/](http://www.kellogg.umich.edu/theeyeshaveit/).

## CHAPTER 5

# Ocular and Orbital Injuries

This chapter includes a related video, which can be accessed by scanning the QR code provided in the text or going to [www.aaio.org/basicvideo](http://www.aaio.org/basicvideo).



## OBJECTIVES

As a primary care provider, you should be able to evaluate the common ocular and orbital injuries and to determine whether the problem requires the prompt attention of an ophthalmologist. In situations of true ocular emergency, such as chemical burns, you should be able to institute therapy. To achieve these objectives, you should learn to

- recognize which problems are emergent or urgent and deal with them accordingly
- obtain the salient historical facts
- examine the traumatized eye
- record the visual acuity as accurately as possible
- competently manage or appropriately refer the most common injuries

## Relevance

One day, whether in your own home or yard or while on duty in the emergency center, you will be confronted with an unexpected ocular injury. Your skill in dealing with major eye injuries can mean the difference between preservation and loss of a patient's vision. The purpose of this chapter is to assist you in developing confidence when approaching minor or major eye injuries; it will further your competence in acquiring the basic techniques and knowledge necessary to assess and initiate treatment of the eye and its surrounding structures.



## Basic Information

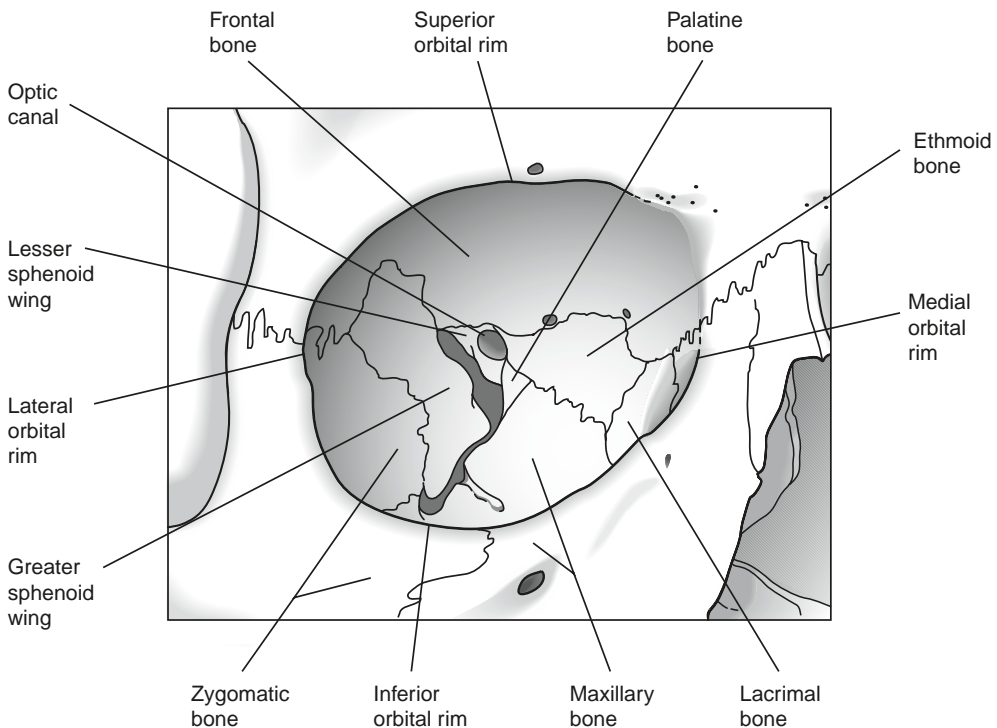
This section introduces ocular and periocular anatomy and helps you identify emergent or urgent ocular problems.

## Anatomy and Function

The following lists structures of the eye, their role, and how they might be impacted by injury.

### Bony orbit

- The orbit is the bony, concave cavity in the skull housing the globe, extraocular muscles, orbital fat, and blood vessels and nerves of the eye (Fig 5-1).
- The rim of the orbit protects the globe from impact with large objects.
- A rim fracture is usually associated with other facial fractures.
- The very thin orbital floor (consisting of the maxillary, palatine, and zygomatic bones) may “blow out” into the maxillary sinus from blunt impact to the orbit,



**FIGURE 5-1** The bony orbit.

for instance, from a fist or tennis ball. Orbital contents, including the inferior rectus and inferior oblique muscles, may become trapped, restricting vertical eye movement and causing double vision (diplopia). An orbital floor fracture is often associated with decreased sensation or numbness of the cheek and teeth on the ipsilateral side. In medial wall and floor fractures, bleeding from the nose may occur acutely after the injury.

- A medial fracture of the thin ethmoid bone may be associated with subcutaneous emphysema of the eyelids. The patient with an acute orbital fracture should avoid blowing the nose.
- A fracture at or near the optic canal, through which the optic nerve and ophthalmic artery pass, may cause damage to the optic nerve or the vessels that supply it (traumatic optic neuropathy), with resulting vision loss.
- A significant percentage (4%–11%) of patients with orbital fractures also have globe injury.

### **Eyelids**

- The eyelids close reflexively when the eyes are threatened.
- The act of blinking rewets the cornea through constant surface contact and tear production.
- In the case of a facial nerve palsy, the globe may be exposed to drying or other injury due to poor eyelid closure
- Eyelid margins must be intact to ensure proper eyelid closure and tear drainage.

### **Lacrimal apparatus**

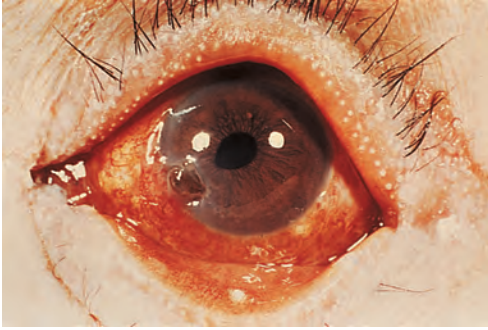
- Tear drainage occurs at the medial aspect of the eyelids, through the upper and lower lacrimal puncta, and continues through the canaliculi to the lacrimal sac, and via the nasolacrimal duct to the nose (see Fig 1-2).
- Recognizing and properly repairing a canalicular laceration is essential to preventing chronic tearing (epiphora).

### **Conjunctiva and cornea**

- The corneal epithelium usually heals quickly following an abrasion.
- Small lacerations of the conjunctiva heal quickly and, consequently, may conceal a penetrating injury of the globe.

### **Anterior chamber**

- The aqueous humor often escapes in penetrating corneal injuries, sometimes resulting in a shallow or flat anterior chamber (see Fig 1-1).



**FIGURE 5-2** Corneal perforation with iris prolapse. Slight distortion of the pupil, irregularity of the corneal reflection, and a knuckle of soft, brown tissue at the limbus indicate a corneal perforation through which the iris has prolapsed.

### Iris and ciliary body

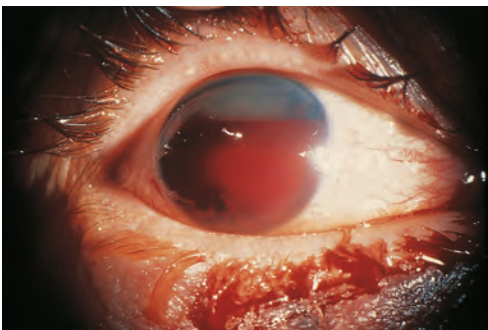
- Following laceration or perforation of the cornea or limbus, the iris may prolapse into the wound (Fig 5-2), resulting in an irregular pupil.
- Blunt trauma to the eyeball may produce iritis, resulting in pain, redness, photophobia, and a small pupil (miosis).
- Contusions may deform the pupil by tearing the iris root or by notching the pupillary margin.
- Contusions may result in tearing of small vessels in the anterior chamber angle, causing hemorrhage into the anterior chamber (hyphema, Fig 5-3). A hyphema is generally the result of trauma and usually resolves spontaneously in 3–5 days, but it may result in an elevated intraocular pressure (IOP).

### Lens

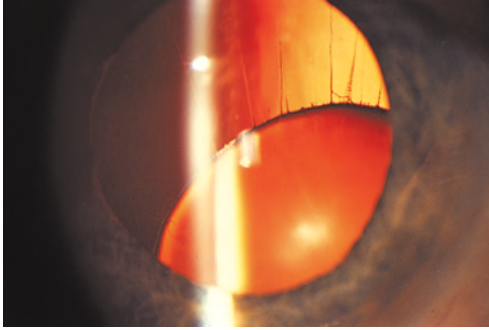
- Injuries to the lens usually proceed to rapid cataract formation.
- Blunt trauma to the globe can cause a partial dislocation (subluxation) of the lens (Fig 5-4).

### Vitreous humor

- Loss of transparency may be observed in the presence of hemorrhage, inflammation, or infection.



**FIGURE 5-3** Hyphema. Hyphema, or blood in the anterior chamber, can result from a tear in peripheral iris vessels and is a potentially serious complication of blunt ocular trauma. Most hyphemas can be readily identified by careful penlight inspection.



**FIGURE 5-4** Subluxated lens. Light reflected off the fundus and back through a dilated pupil silhouettes the edge of a subluxated lens with stretched zonular fibers. Ordinarily, the edge of the lens is not visible even if the pupil is widely dilated.

### Retina

- The retina is protected externally by the sclera (a tough outer layer) and the choroid (an underlying vascular layer, see Fig 1-1).
- The retina is thin and vulnerable. If penetrated by a foreign body, retinal detachment may occur. (See discussion and Fig 2-2 in Chapter 2.)
- Retinal hemorrhage may develop due to direct or indirect trauma.
- The retina turns white when edematous.
- Macular damage will reduce visual acuity without producing complete blindness.

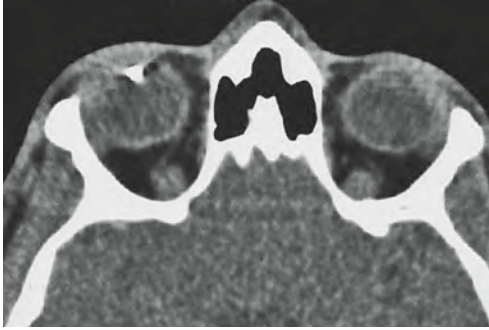
## When to Examine

Most ocular injuries present with obvious redness and pain. However, not all injuries provide such obvious warning signs. For example, a sharp perforation may produce minimal redness and escape attention. The examiner should be especially alert to perforating injuries caused by small projectiles resulting from “striking metal on metal.” If there is a history of metal striking metal with something hitting the eye, the patient should be referred to an ophthalmologist for evaluation urgently even if the vision is normal and the eye looks quiet. An intraocular foreign body (Fig 5-5) produces no pain because the lens, retina, and vitreous have no nerve endings to conduct sensations of pain. A complete and thorough history is essential in the diagnosis and treatment of ocular injuries.

If damage to the posterior segment is suspected, including retinal detachment or intraocular foreign body, urgent referral to an ophthalmologist is indicated. The ophthalmologist’s examination of the fundus will be facilitated if you do not use ointment in the eye.

## How to Examine

When a patient presents with an eye injury, the provider should obtain the patient’s history, if possible, and perform a complete examination of the eyes and surrounding



**FIGURE 5-5** Computed tomography scan of foreign body. A small, radiopaque intraocular foreign body is visible in the anterior segment of the eye.

structures. This should include visual acuity testing, external examination, assessment of the pupils and eye movements, and ophthalmoscopy. Two sample examinations are in Tables 5-1 and 5-2.

## History

In the evaluation of ocular injuries, it is important to document the type of traumatic event as well as the time of onset and the nature of the symptoms. Specific historical information to obtain includes the time, place, and type of injury (eg, blunt or sharp trauma; acid or alkali burn) and the patient's history of eye conditions, drug allergies, and tetanus immunization. Maintain a high level of suspicion for an open (punctured) globe based on the mechanism of trauma. For example, a history of pounding metal on metal, the patient's statement that something was "pulled out of the eye," or blunt ocular trauma in a patient who has undergone past eye surgery are suggestive of more severe injury. As in any trauma situation, you should not delay prompt treatment to obtain a detailed history if an obvious injury is present, such as a chemical burn.

After significant trauma has occurred, the patient may be unconscious or unable to answer questions. In this case, the provider can question whoever accompanied the patient for as much historical information as possible, but must be prepared to assess the injury and proceed with treatment or referral in the absence of adequate historical information.

## Visual Acuity Testing

Visual acuity should be recorded as specifically as possible. Refer to Chapter 1 for detailed instructions on assessing visual acuity, including use of the Snellen eye chart. If a Snellen chart is unavailable, determine the patient's ability to read available print material and record the type of print used (eg, newspaper, telephone book) and the distance at which

**TABLE 5-1** Sample Examination: Foreign-Body Sensation

AREA	NOTES
<b>History</b>	
Type of injury, time, and place	Foreign-body sensation, 3:15 am, seen in emergency center.
Pertinent chain of events; is trauma centered in OD, OS, or OU?	At about 2:45 am, patient awoke with severe foreign-body sensation OU.
Subjective vision loss, if any, and amount of visual decrease; associated complaints, symptoms	No injury, although admits to using sunlamp to tan face for 20 minutes previous evening. Now unable to open eyes, which aggravates burning foreign-body sensation. Unable to see well but uncertain about degree of vision loss.
Was vision normal prior to injury?	Patient states vision has been normal until now.
<b>Examination</b>	
Best correctable VA for both eyes (ie, with glasses if available, with pinhole if necessary)	Unable to cooperate until 1 drop topical anesthetic (proparacaine 0.5%) administered OU. VA: OD 20/25; OS 20/20
<b>Appearance and function of:</b>	
Bony orbit and eyelids	Bony orbit intact. Marked eyelid spasm until anesthetic drops given.
Cornea and conjunctiva	Cornea stains irregularly with fluorescein. Conjunctival injection OU, pronounced near limbus.
Media (aqueous, lens, vitreous)	Media clear on gross inspection.
<b>Diagnosis</b>	Ultraviolet conjunctival and corneal injury.
<b>Management</b>	Cycloplegic drops, antibiotic ointment, and possibly a pressure dressing. Because these injuries are often bilateral, patch only the worse eye—it is difficult for the patient to function with both eyes patched. A prescription for oral analgesic may be indicated.

it was read. Note in particular whether vision is equal in both eyes. If vision is below reading level, determine the patient's ability to count fingers, perceive hand motions, or respond to light.

## External Examination

An examination of the external structures of the eye may include palpation, penlight inspection, eyelid eversion, fluorescein staining, and topical anesthesia. Palpation of the orbital rims should be performed if a blunt injury or fracture is suspected. A penlight is used to inspect the eye for signs of perforation, such as reduced depth of the anterior chamber or iris prolapse (see Fig 5-2). Hyphema (see Fig 5-3) may be present without perforation and, in fact, often accompanies blunt injury. Eyelid eversion (retraction and

**TABLE 5-2** Sample Examination: Double Vision

AREA	NOTES
<b>History</b>	
Approximate onset of symptoms	A 16-year-old boy complains that he awoke 2 days ago with a feeling of fullness OS.
Type of symptoms, frequency, regularity	Later, he noted vertical double vision when looking straight up, up and right, and up and left; no double vision when looking straight ahead. No other problem except mild aching when looking up. Hit by knee in left eye in wrestling class 3 days earlier.
Increasing or decreasing severity?	Symptoms unchanged since first noted.
<b>Examination</b>	
Ocular findings	Perform complete eye examination, with particular attention to testing extraocular muscles. Rule out possible damage to the globe. Patient unable to elevate left eye beyond primary gaze. Globe examination unremarkable except for localized subconjunctival hemorrhage. Visual acuity normal.
Radiology exam	Maxillofacial CT scan (axial cuts with coronal reconstructions) more clearly delineates fracture of orbital floor.
<b>Diagnosis</b>	Blowout fracture left orbit with muscle entrapment.
<b>Management</b>	Urgent referral to an ophthalmologist for evaluation and consideration of surgical repair. Instruct the patient to avoid blowing his nose.

eversion of the upper and lower eyelids) will facilitate inspection for a foreign body or chemical burn.

*Do not manipulate the eyelids if you suspect a penetrating injury of the globe.*

If the patient has a foreign-body sensation or if there is a history of blunt or sharp injury, fluorescein is used to stain the cornea to identify any corneal epithelial defects. (See Chapter 1 for the technique of fluorescein staining.)

Eyedrops can be used to provide topical anesthesia, especially to relieve foreign-body sensation or discomfort due to radiant energy burns or prolonged wear of contact lenses. Use of 1 drop of proparacaine hydrochloride 0.5% provides almost instantaneous pain relief and allows you to proceed with an adequate evaluation, including determination of visual acuity, which would otherwise be impossible due to discomfort. Do not prescribe or distribute samples of anesthetic drops or ointment because prolonged use can result in corneal ulceration.

## Pupillary Reactions

Always check pupillary reactions in trauma cases. Diminished direct pupillary reaction to light with an intact consensual response (a relative afferent pupillary defect) may indicate an optic nerve injury (see Chapter 7).

## Ocular Motility Testing

Movement of the eye may be generally restricted in the case of orbital hematoma. If there is a history of blunt trauma, vertical restriction combined with vertical diplopia should make you suspect a blowout fracture. If limitation of eye movements is accompanied by proptosis, auscultate the head and eye for a bruit, which would be suggestive of a carotid-cavernous sinus fistula (see “Vascular Malformations” in Chapter 8).

*To avoid extrusion of intraocular contents, do not perform motility testing in suspected globe laceration.*

## Ophthalmoscopy

If the fundus is visible, look for edema, retinal hemorrhages, retinal detachment, and, if penetration is suspected, a foreign body. In the event of a positive finding or the suspicion of a penetrating injury or foreign body, refer the patient to an ophthalmologist urgently.

The normal red reflex from the fundus is evenly colored and not interrupted by shadows (see Fig 1-16). If the red reflex is absent, urgent referral to an ophthalmologist is indicated. Absence of the red reflex may be due to hyphema, cataract from acute swelling of the lens, or vitreous hemorrhage. Hyphema is visible on external examination with a penlight, whereas the detection of cataract and vitreous hemorrhage requires assessment with an ophthalmoscope.

Pupillary dilation to permit evaluation of the fundus should be routine. The only general exceptions to this rule would be in patients with head trauma where pupillary signs might be important for neurologic evaluation and patients whose shallow anterior chamber predisposes them to narrow-angle glaucoma.

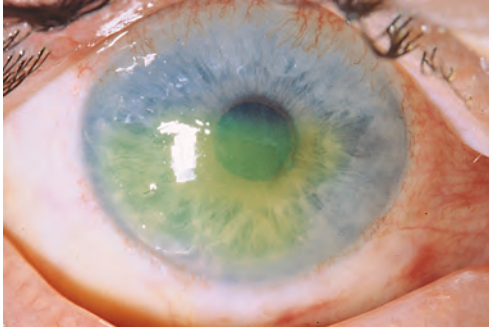
## Radiologic Studies

Radiologic evaluation is suggested if there is any question of facial or orbital fracture or of ocular or orbital foreign body. A maxillofacial computed tomography (CT) scan with coronal reconstructions is the appropriate test to order. Magnetic resonance imaging (MRI) should not be ordered for ocular or orbital trauma.

## Management or Referral

The primary care provider may not be able to provide definitive care for each of the following entities, but should be able to initiate treatment in every case. Please follow the definitions of emergent, urgent, and nonurgent outlined in the beginning of Chapter 2.





**FIGURE 5-6** Alkali burn. Blanching of the conjunctiva and a large corneal epithelial defect, demonstrated by application of fluorescein, indicate a relatively serious injury.

## True Emergency

Therapy must be instituted within minutes. A chemical burn of the conjunctiva and cornea represents one of the true ocular emergencies. An alkali burn (Fig 5-6) usually results in greater damage to the eye than an acid burn, because alkali compounds (eg, lye, anhydrous ammonia) penetrate ocular tissues more rapidly. All chemical burns require immediate and profuse irrigation, followed by referral to an ophthalmologist. Irrigation should be performed for 20 minutes with at least 2 liters of the available aqueous solution (preferably, normal saline or lactated Ringer's solution, but care should not be delayed).

## Urgent Situations

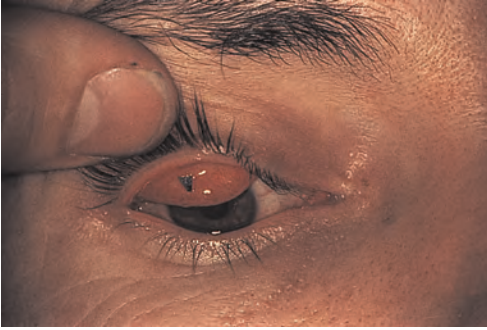Urgent situations require therapy to be instituted within a few hours and discussion with the ophthalmologist prior to the patient leaving the office or emergency center. The following paragraphs describe common urgent ocular situations and appropriate actions to take for each.

### Penetrating injuries of the globe

Penetrating injuries of the globe, whether actual or suspected, necessitate the protection of an eye shield. Neither a patch nor ointment is advisable. The patient should be prevented from eating or drinking anything in anticipation of surgical intervention. A maxillofacial CT scan should be ordered to rule out radiopaque foreign bodies (see Fig 5-5). Urgent referral to an ophthalmologist is indicated.

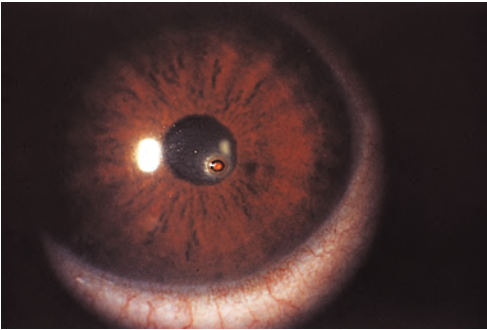
### Conjunctival or corneal foreign body

Conjunctival (Fig 5-7) or corneal (Fig 5-8) foreign bodies require topical anesthesia followed by removal of the object with either vigorous irrigation or a cotton-tipped



**FIGURE 5-7** Conjunctival foreign body.

A foreign body often lodges under the edge of the upper eyelid. As this figure shows, the foreign body is easily seen and removed upon eversion of the eyelid.



**FIGURE 5-8** Corneal foreign body. Visible here is a small piece of iron embedded in the surface of the cornea. Surrounding the iron are a ring of rust and grayish corneal edema.

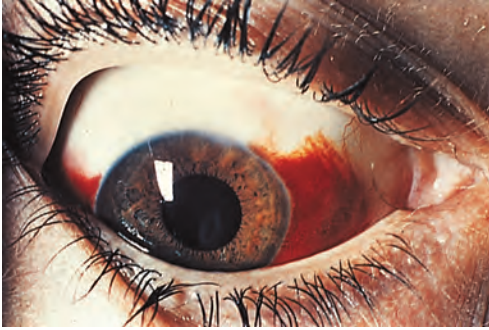applicator. (See “Foreign-Body Removal” under “Treatment Skills” later in this chapter for specific instructions.)

For corneal abrasions, take the following steps:

1. Anesthetize with proparacaine 0.5%.
2. Perform a gross examination.
3. Stain with fluorescein to enhance the view. (For a depiction of a fluorescein stain delineating a corneal abrasion, see Figs 1-14 and 1-15 and Video 1-10.)
4. Instill ocular antibiotic drops or ointment; instill short-acting cycloplegic (tropicamide 1% or cyclopentolate 1%) drops for the relief of pain as indicated.
5. Some providers apply a pressure patch to maintain eyelid closure for 24 hours, although others feel that abrasions less than 10 mm in diameter heal better and more quickly without a pressure patch. No patch should be applied if the abrasion is associated with contact lens wear.
6. Refer severe cases to an ophthalmologist.

### Subconjunctival hemorrhage

Although an isolated subconjunctival hemorrhage (Fig 5-9) is generally a benign condition, in the setting of trauma one should have a suspicion of underlying globe injury,



**FIGURE 5-9** Subconjunctival hemorrhage. This circumscribed hemorrhage is located between the conjunctiva and the sclera; the history of a sudden appearance and the bright red color are characteristic.

including globe rupture or intraocular hemorrhage, and urgent referral to an ophthalmologist is indicated.

### Hyphema

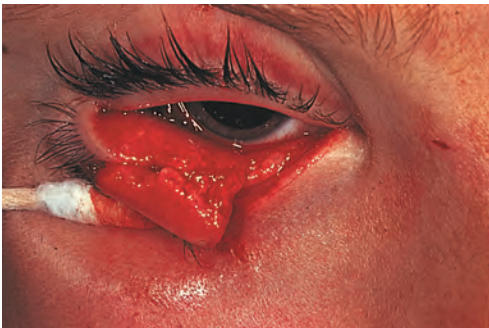Hyphema requires urgent referral to an ophthalmologist. Elevation of IOP may necessitate medical or surgical intervention. Also, the hyphema may be a sign of globe rupture or a more serious ocular injury, such as dislocated lens or retinal detachment.

### Eyelid laceration

An eyelid laceration can be sutured if not deep and neither the eyelid margin nor the canaliculi are involved; otherwise, refer to an ophthalmologist. (The eyelid laceration shown in Fig 5-10 would require referral because it is a full-thickness laceration and involves the eyelid margin. There is also a possibility of canalicular involvement because the laceration is close to the medial canthus.)

### Radiant energy burn

Radiant energy burns, such as welder's burn, burn due to a tanning booth, or snow blindness, require topical anesthesia, examination, topical antibiotic and cycloplegic agents,



**FIGURE 5-10** Full-thickness eyelid laceration. The lower eyelid is partially everted with the applicator stick, revealing an irregular laceration of the eyelid margin, orbicularis muscle, tarsal plate, and conjunctiva. Note the proximity of the laceration to the medial canthus, indicating possible canalicular involvement.

and possibly patching. Topical anesthesia is used to provide immediate comfort and to facilitate the examination; it should not be prescribed for patient use. Because these injuries are often bilateral, it is difficult for the patient to function with both eyes patched. Many patients prefer simply closing the eyes. The corneal epithelium regenerates quickly, and after several hours the pain is much less intense. (See Chapter 10 for information about instilling ocular medications.)

### **Traumatic optic neuropathy**

Traumatic optic neuropathy, although uncommon, should always be considered in patients with cranial or maxillofacial trauma. Patients present with a history of facial or frontal trauma, usually with unilateral decreased vision and a relative afferent pupillary defect, but further examination reveals no clear ocular origin. High-resolution CT scanning of the orbital apex, optic canal, and cavernous sinus is essential if traumatic optic neuropathy is suspected. If a patient is suspected of having traumatic optic neuropathy, a prompt referral to an ophthalmologist is indicated.

### **Orbital fracture**

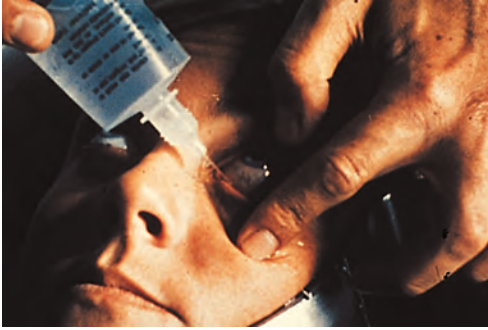An orbital fracture should be referred to the ophthalmologist urgently to rule out any associated globe trauma. Although treatment of orbital fractures in adults is usually nonurgent, orbital fractures in children may require more urgent intervention.

### **Orbital hematoma**

An orbital hematoma is a potentially sight-threatening situation. The patient may present with proptosis and decreased ocular motility. Orbital pressure is directly transferred to the globe, and if the IOP increases to a point that the eye can no longer be perfused with blood, the patient will have decreased vision and an afferent pupillary defect, and measurement of the IOP will be high. This is an urgent situation (the ophthalmologist should be consulted immediately), treated with a lateral canthotomy with upper and lower cantholyses. This results in release of the eyelids from the lateral orbital rim to allow the eye to prolapse forward, expanding the orbital volume and therefore decreasing the orbital pressure.

## **Treatment Skills**

To manage eye injuries properly, every provider should be proficient in ocular irrigation, foreign-body removal, eye medication prescription, and patching.



**FIGURE 5-11** Irrigation. Here the clinician uses a plastic squeeze bottle of water or normal saline to irrigate the eye. The patient is instructed to look in various directions while the opposite portions of the conjunctival cul-de-sac are flushed vigorously.

## Ocular Irrigation

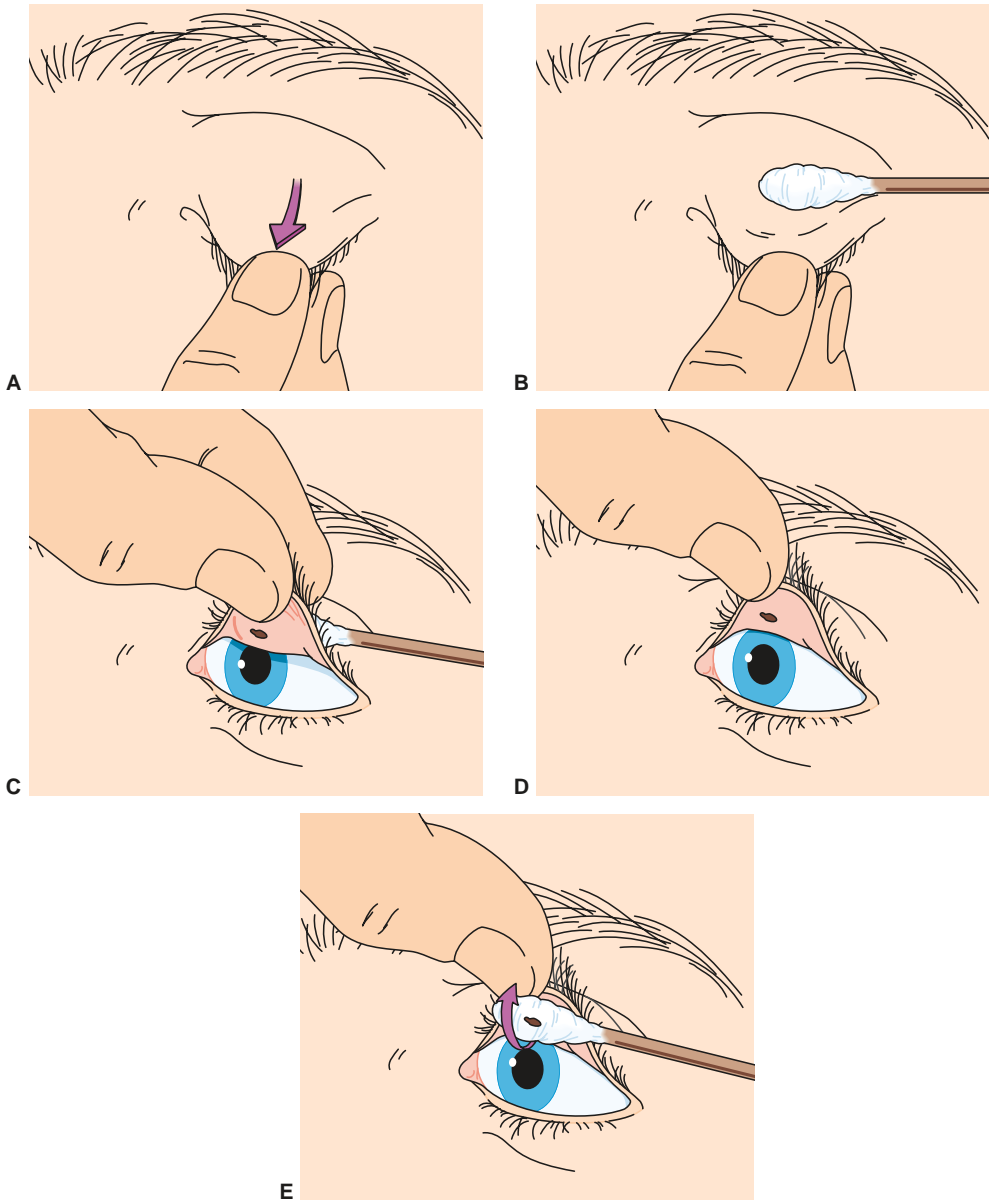
Plastic squeeze bottles (Fig 5-11) of eye irrigation solutions and normal saline intravenous drip with plastic tubing are ideal for ocular irrigation. Irrigation may be facilitated by the use of a topical anesthetic. However, first aid for chemical injuries of the eye may demand the earliest possible irrigation using any source of water available, such as a garden hose, drinking fountain, or faucet. It cannot be overstated that chemical burns require immediate and profuse irrigation. Always direct the irrigating stream toward the temple and away from an unaffected fellow eye. Once the patient is in a health-care setting, prolonged irrigation should continue until the patient is assessed by the ophthalmologist.

## Foreign-Body Removal

To remove a superficial foreign body from the cornea or conjunctiva, instill a topical anesthetic, such as proparacaine 0.5%, and then gently roll a cotton-tipped applicator across the globe to pick up the object. A forceful stream of irrigating solution delivered from a squeeze bottle will often dislodge a superficial conjunctival or corneal foreign body. A sharper instrument may be required if the foreign body remains embedded, and the patient should be referred to an ophthalmologist. The orange-brown “rust ring” resulting from an embedded iron foreign body is a common problem that requires special attention. Eversion of the upper eyelid is required to evaluate the upper palpebral conjunctiva (Fig 5-12).

## Prescribing Eye Medication

All providers should be able to prescribe or administer confidently the following ocular drugs. (See Chapter 10 for more detailed discussions and for the method of administering topical ocular drugs.)



**FIGURE 5-12** Eversion of the upper eyelid and removal of a tarsal foreign body. **A**, After instructing the patient to look down, grasp the eyelashes of the upper eyelid and pull down and away from the eye. **B**, With the other hand, place a moistened applicator in the upper eyelid fold, one-half inch above the eyelid margin. **C**, Evert the upper eyelid over the applicator. **D**, Remove the applicator, keeping the upper eyelid everted with your thumb. **E**, Inspect the tarsal conjunctiva with a penlight and remove the foreign body by using a rolling motion of the applicator.

### Cycloplegics

Homatropine hydrobromide 5% or cyclopentolate hydrochloride 1% may be used to relax the iris and ciliary body and to relieve the pain and discomfort of most forms of nonpenetrating ocular injuries. Longer-acting cycloplegics (eg, atropine) are usually contraindicated.

### Antibiotic ointment

In general, if employed for 1-time use in clean wounds, antibiotic ointments can be used safely without side effects. If more frequent use is necessary, the possibility of allergic reactions or superinfections must be considered. Gentamicin and neomycin are frequently associated with allergic reaction if used longer than 5–7 days.

### Anesthetic eyedrops and ointment

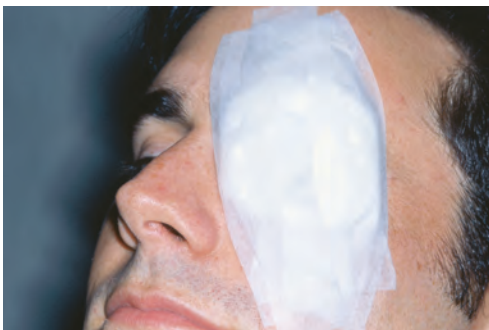Ocular anesthetics should never be prescribed for home use because they are toxic to the corneal epithelium when used repeatedly. Prolonged use could result in secondary infection and/or corneal ulceration.

### Patching

Use of a pressure patch or a protective eye shield is indicated in some situations.

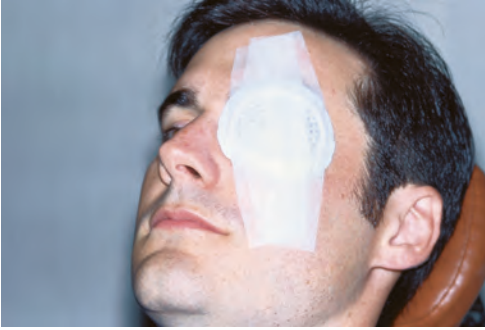#### Pressure patch

A moderate pressure patch is used following injuries that affect the corneal epithelium (eg, corneal abrasions) and after removal of foreign bodies. Two eye patches or a single eye patch plus a fluffed piece of gauze is applied by putting moderate tension on the strips of tape used (Fig 5-13). Make sure the patch is tight enough to prevent the patient from inadvertently opening the eye under it. The patch should not be so tight as to cause the



**FIGURE 5-13** Pressure patch. The patient is instructed to close both eyes while 1 or more oval, gauze eye patches are taped firmly enough to immobilize the eyelid of the affected eye in a closed position.





**FIGURE 5-14** Shield. Shown here is the Fox shield, made of malleable metal and perforated. The shield is carefully shaped so that the rim of the orbit supports it when taped in place.

patient discomfort or severely compress the globe, which can compromise the retinal blood flow. Video 5-1 demonstrates use of a pressure patch.



**VIDEO 5-1 Pressure Patching (01:00)**

*(Courtesy of Richard C. Allen, MD, PhD, FACS)*



### Shield

For more serious ocular injuries, such as penetration of the globe or hyphema, a shield should be taped over the eye as an interim measure to protect the eye from rubbing, pressure, and further injury prior to treatment by an ophthalmologist. The shield may consist of a perforated, malleable piece of metal (Fig 5-14), plastic, or a trimmed-down paper cup.

### Suturing

The primary care provider can perform suturing of any eyelid skin laceration that does not involve the eyelid margin or the lacrimal canaliculi. More complicated eyelid lacerations should be referred to an ophthalmologist.

## ●●● POINTS TO REMEMBER

- Know your limits: do not attempt complex repair, and know the results of inadequate repair.
- Almost without fail, a teardrop-shaped pupil and a flat anterior chamber in an injured eye are associated with a perforating injury of the cornea or of the limbal area. Look for prolapse of dark tissue (either iris or ciliary body) at the point of the teardrop.



- Avoid digital palpation of the globe in any patient who may have a corneal laceration or other perforating injury.
- In a patient with a chemical burn, immediate irrigation is crucial as soon as the nature of the injury has been identified. Do not attempt to neutralize or buffer the chemical substance. The goal is simply to dilute the chemical as thoroughly as possible by copious flushing.
- Traumatic abrasions are generally located in the central or inferior cornea due to the Bell phenomenon (eye rotates superiorly on eyelid closure). A corneal abrasion without a history of trauma or an abrasion located in the superior cornea is unusual and may actually represent herpetic epithelial disease, a foreign body under the upper eyelid, a corneal epithelial dystrophy, or a contact lens–associated disorder.

## SAMPLE PROBLEMS

1. Your neighbor, a 43-year-old woman, is cleaning her swimming pool. While she is pouring some concentrated algaecide into the pool, a large dollop of this solution splashes into her right eye. You are mowing your lawn when you hear her screams. You come to her aid less than 30 seconds after the injury. Which of the following should you do first?
  - a. Bundle her into your car and speed off for the nearest emergency center.
  - b. Run back home to get your medical bag where you keep a squeeze bottle of ophthalmic irrigating solution that you can use to flush out her eye.
  - c. Run back to your study to look up the specific antidote for algaecide.
  - d. Carefully examine her eye for evidence of ocular hyperemia.
  - e. Dunk her head into the swimming pool, instructing her to hold her eyes open to flush out the chemical.

**Answer:** e. This is one of the few true emergencies of all the ocular injuries that you must know. Early and copious irrigation with whatever source of water is handy is the right approach to this problem. Even with prompt treatment, serious ocular injuries and visual damage may result, depending on the offending chemical. Time is of the essence. Do not resort to methods that will cause delay.

2. A 32-year-old man comes to the emergency room with a painful, red eye. He reports that he was riding his bike earlier that morning and felt something hit his eye. He immediately washed the eye with water, but could not relieve the discomfort.
  - A. If you suspect that a foreign body is causing the symptoms, what is the best way to examine under the upper eyelid?

**Answer:** The best way to examine for a foreign body under the upper eyelid is to apply topical anesthetic, evert the eyelid, and inspect directly.

- B. If he sustained a corneal abrasion and no foreign body is identified, what would you expect on examination?
- a. increased tearing
  - b. decreased vision
  - c. epithelial defect/staining
  - d. cloudy cornea
  - e. itching

**Answer:** a, b, and c. Due to the increased tearing and epithelial defect, the vision is often blurred. A recent corneal abrasion should not be cloudy unless it is an ulcer, which would rarely occur so soon after injury. Itching is a sign of allergic conjunctivitis and is not seen with this diagnosis.

- C. Appropriate treatment for a corneal abrasion would be which of the following?
- a. topical anesthetics to control the pain
  - b. antibiotic eye drops or ointment
  - c. oral antibiotics
  - d. possibly an eye patch to keep eyelid closed

**Answer:** b and d. Topical anesthetics should never be prescribed for prolonged use, and oral antibiotics are rarely indicated. The eye may be patched with care to be sure the eyelid remains shut when the other eye is open.

3. If you suspect that a patient has a perforation of the eye, what signs might you expect to see?
- a. irregular shape to the pupil
  - b. shallow anterior chamber
  - c. low IOP by digital palpation
  - d. uveal tissue prolapse
  - e. hyphema

**Answer:** a, b, d, and e. If you suspect a perforation of the eye, digital palpation or any procedure that puts pressure on the eye should not be done.

4. You are on duty in the emergency center when an 18-year-old high school student comes in because of pain, tearing, sensitivity to light, and blurred vision in his right eye. His symptoms began sometime that afternoon. Earlier, he had been working on his car and he remembers something flying into his right eye while he was trying to knock a rivet off the chassis with a hammer and chisel. You examine his eye and take visual acuity measurements. You determine that visual acuity is 20/50 in the right eye and 20/20 in the left eye. There is some conjunctival hyperemia. The pupil of the right eye seems to be peaked and pointing to the 7 o'clock position of the limbus. There is a small, dark, slightly elevated body at the 7 o'clock position of the limbus. You cannot

see fundus details of the right eye, but the left eye appears normal. Which of the following would be the appropriate initial management for this situation?

- a. irrigation of the limbal foreign body
- b. application of a protective shield
- c. removal of the limbal foreign body using a cotton-tipped applicator
- d. removal of the limbal foreign body using forceps
- e. a prescription for topical anesthetic (eg, proparacaine 0.5%) to relieve the patient's symptoms, with strict instructions that he return to see you if his blurred vision continues into the week

**Answer:** b. Any patient whose recent activities involve striking metal on metal should be suspected of having a foreign body, even with minimal signs and symptoms. However, the case illustrated includes a giveaway sign, namely, peaking of the pupil toward the 7 o'clock position. At that position, the dark body is likely to be iris or ciliary body rather than a foreign body. This indicates a penetrating ocular injury, and the patient should be protected from further eye trauma by a protective shield. A CT scan will confirm the diagnosis of ocular or orbital foreign body. The patient should be referred urgently to an ophthalmologist.

5. While cutting his roses, a neighbor develops a sudden pain in his left eye. Inspection is limited because his eyes are closed, but nothing is visible on external examination.

A. What do you think might have happened?

**Answer:** Possibilities include a foreign body on the eye or under the eyelid; a superficial abrasion; or, less likely but still possible, perforation by a thorn.

B. What steps would you need to take to assess and treat this problem?

**Answer:**

1. Open the eyelids gently; never force them open, and never apply pressure to the globe if perforation is suspected. Instill a drop of topical anesthetic, if necessary, to facilitate examination.
2. Inspect the cornea and the sclera for a foreign body or possible perforation.
3. Evert the eyelids to look for a foreign body, unless perforation is suspected.
4. Remove the foreign body by irrigation or with a cotton-tipped applicator.
5. Act on any indications for drops, ointment, or patching.
6. If a possibility of ocular penetration exists, by examination or history, referral to an ophthalmologist is indicated.

Clinical findings in such cases can be very subtle. Ocular penetration with vegetable matter such as a thorn carries not only the usual risks of ocular penetration (ie, endophthalmitis, cataract, and corneal scar) but also the possibility of a fungal infection.

6. While you are on duty in the emergency center, a patient is brought in who has been involved in a car accident. His face is bloody, especially around the eyes. His history is unclear.

A. What would you do? What would you avoid?

**Answer:** Cleanse carefully. Avoid pressure of any kind on the eye.

- B. While cleansing, you find a cut in the eyelid. It seems easy to stitch, but the eyelids are swollen and the patient cannot open his eye. What next? Do you stitch the eyelid?

**Answer:** First, inspect the eye for possible perforation. Because the eyelid laceration is not an emergency, stitching is not immediately necessary.

- C. If the eye is normal, how should you analyze the problem of the eyelid laceration?

**Answer:** The appropriate choice of treatment depends on the level of damage. If only the skin is involved, you may be able to stitch the eyelid. If the laceration is full-thickness or involves the eyelid margin, referral to an ophthalmologist is preferred. Any involvement of the canaliculi requires exquisite repair in order to avoid a chronic tearing problem for the rest of the patient's life; referral to an ophthalmologist is mandatory.

7. A 25-year-old man visits the emergency room complaining of decreased vision and pain in his right eye after being involved in a fist fight. Although he has edema and ecchymosis of the eyelids, you are able to examine his eye. His visual acuity is OD 20/70 and OS 20/20, and his pupils are round and reactive. However, the right pupil is sluggish, and shining a light in either eye causes pain in his right eye. He has no restriction of motility. On examination of the anterior segment, you notice a diffuse haze in the anterior chamber and early layering of blood inferiorly. Direct ophthalmoscopy reveals an absent red reflex and no view of the retina is possible. Which of the following would be the most appropriate treatment?

- a. Instill antibiotic ointment and cycloplegic drops, apply a pressure patch, and have the patient follow up with an ophthalmologist in a few days.
- b. Prescribe steroid drops and cycloplegic drops, and tell the patient to keep his head elevated at all times.
- c. Immediately refer the patient to an ophthalmologist to rule out ruptured globe or increased IOP.

**Answer:** c. Although option b may represent appropriate treatment for hyphema, the patient needs to be adequately evaluated for a ruptured globe and peripheral retinal tears. Option a represents treatment for corneal abrasion, not hyphema.

8. An elderly woman falls and hits her face on the coffee table at home. She had some nose bleeding on that side after the fall. She presents to your office 2 hours later

with edema and ecchymosis of the eyelids with numbness of the cheek and teeth on that side.

- A. What should be the first priority in the examination?
- Palpate the globe to see if the pressure is normal.
  - Repair any eyelid lacerations.
  - Send the patient for a CT scan to rule out fractures.
  - Carefully open the eyelids and examine for a ruptured globe.

**Answer:** d. The first step in any ocular or orbital trauma is to assess the status of the eye and avoid any manipulation of the eye until it is found to be intact.

- B. The patient sees 20/20, the pupil is regular, and the eye sustained only a subconjunctival hemorrhage. After appropriate tests, the diagnosis of orbital fracture is made. What would treatment include?
- ice packs to the orbit
  - avoiding blowing the nose
  - immediate surgical intervention
  - oral antibiotics

**Answer:** a, b, and d. Surgical repair of orbital fractures in adults is not an emergency and can be handled over the next 1 or 2 weeks. An urgent referral to an ophthalmologist is indicated. Blowing the nose can cause intraorbital emphysema and should be avoided. Ice packs often decrease swelling in an acute event.

## ANNOTATED RESOURCES

*Basic and Clinical Science Course*, Section 8: External Disease and Cornea. San Francisco: American Academy of Ophthalmology; updated annually. An excellent summary of anterior segment trauma, covering general principles, burns, superficial injuries, blunt trauma, and perforating injuries.

Bagheri N, Wajda BN. *The Wills Eye Manual: Office and Emergency Room Diagnosis and Treatment of Eye Disease*. 7th ed. Philadelphia: Wolter Kluwer Health/Lippincott Williams & Wilkins; 2016.

Kaiser PK, Corneal Abrasion Patching Study Group. A comparison of pressure patching versus no patching for corneal abrasions due to trauma or foreign body removal. *Ophthalmology*. 1995;102(12):1936–42. Patients with noninfected non–contact-lens-related traumatic corneal abrasions and abrasions secondary to foreign body removal healed faster with less pain using antibiotics and mydriatics alone, without the need for a pressure patch.

Kaiser PK, Pineda R, Corneal Abrasion Patching Study Group. A study of topical nonsteroidal anti-inflammatory drops and no pressure patching in the treatment of corneal abrasions. *Ophthalmology*. 1997;104(8):1353–9. The addition of a topical NSAID to antibiotic treatment of non–contact-lens-related traumatic corneal abrasions increased patient comfort and sped time to resumption of normal activities.

- MacCumber MW, ed. *Management of Ocular Injuries and Emergencies*. 4th ed. Philadelphia: Lippincott Williams & Wilkins; 1998. Used widely by ophthalmology residents, this book contains extensive information useful to the student or emergency center physician who desires more information on serious eye trauma.
- Newell FW. *Ophthalmology: Principles and Concepts*. 8th ed. St Louis, MO: CV Mosby; 1996. Ocular injuries are summarized succinctly in “Injuries of the Eye” in this comprehensive textbook.
- Trobe JD. “The Eyes Have It.” Website hosted by the University of Michigan, Kellogg Eye Center. This interactive tool features an instructional mode, where one reviews topics that cover a range of eye problems and manifestations, and a quiz mode that covers eye problems as well as anatomy, the screening examination, signs and symptoms, and more. Available at [www.kellogg.umich.edu/theeyeshaveit/](http://www.kellogg.umich.edu/theeyeshaveit/).

