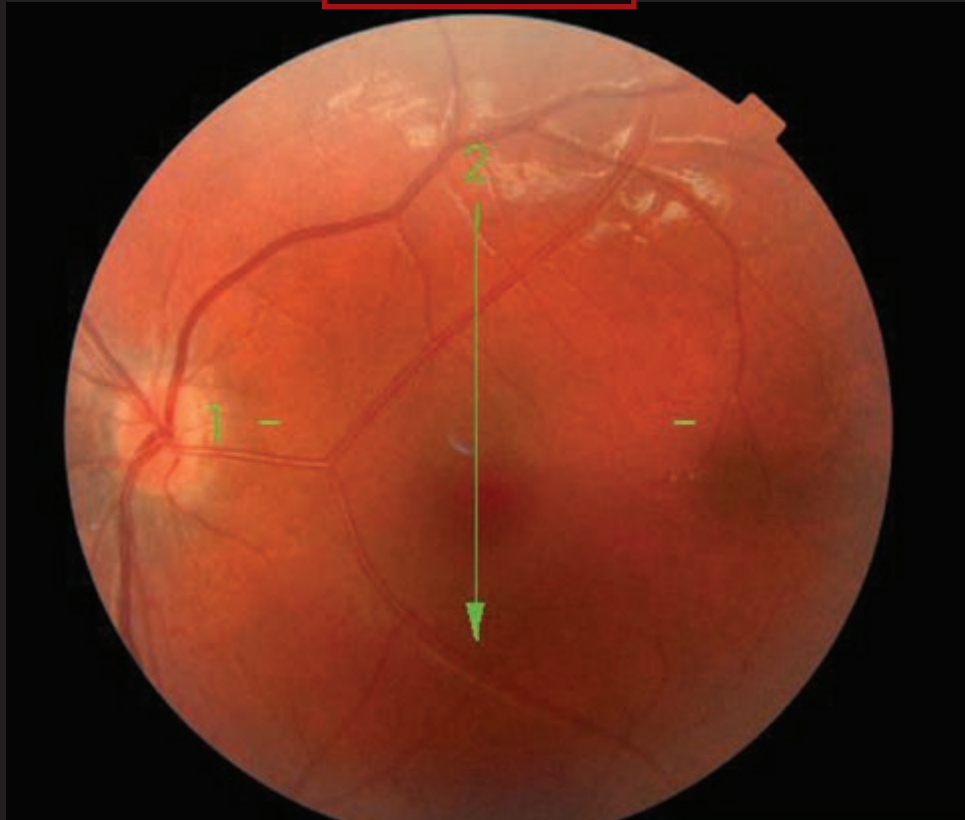


Blink



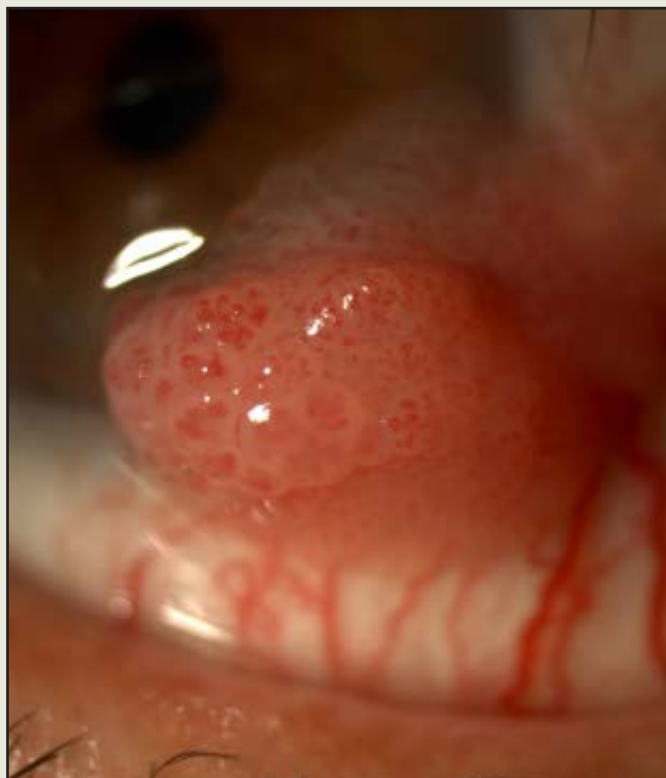EMILIO DORRONSORO RAMÍREZ, MD, MORALEJA HOSPITAL, MADRID

WHAT IS THIS MONTH'S MYSTERY CONDITION? Join the conversation at www.eyenet.org, where you can post a comment about this image.

LAST MONTH'S BLINK Conjunctival Papilloma

A 73-year-old man presented to the clinic with a two-week history of a progressively enlarging ocular surface lesion causing foreign body sensation. A sessile conjunctival tumor involving the limbus was observed. Ocular motility and slit-lamp examination were otherwise unremarkable. Surgical excision was the chosen treatment. The pathology revealed papilloma with severe intraepithelial dysplasia. Nine months after excision, there was no sign of recurrence.

Written by Cristina Santos, MD, Susana Pina, MD, and Rita Oliveira, MD, Hospital Professor Doutor Fernando Fonseca, Epe, Amadora, Portugal.



Cristina Moreira, MD, Hospital Professor Doutor Fernando Fonseca, Epe, Amadora, Portugal

