

CATARACT

Strategies for Preventing Intraoperative Miosis

BY LINDA ROACH, CONTRIBUTING WRITER

INTERVIEWING ANDERS BEHNDIG, MD, PHD, ERIC D. DONNENFELD, MD, DAVID B. GLASSER, MD, THOMAS A. OETTING, MS, MD, AND JOSHUA P. VRABEC, MD

Keeping the pupil adequately dilated throughout cataract surgery is a crucial prerequisite for giving patients good visual outcomes without complications. Fortunately, careful preoperative planning can enable surgeons to maintain mydriasis even in eyes with known risks for intraoperative miosis, clinical research shows.

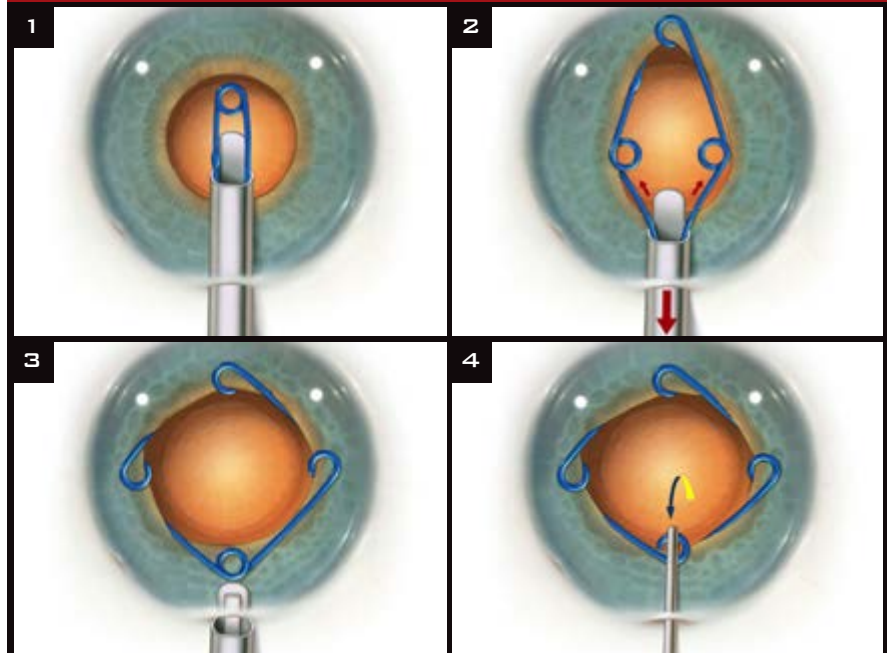
But what about eyes in which the pupil constricts without any presurgical red flags? Pharmacologic prevention of these intraoperative surprises will get increased attention in the United States, as the first combined mydriatic/anti-inflammatory drug approved by the FDA for use in the surgical irrigation fluid, Omidria (Omeros), became available commercially in April.

Planning Is the Best Medicine

“Large pupils make good surgeons great, and small pupils make good surgeons anxious,” said Eric D. Donnenfeld, MD, who practices in Rockville Centre, N.Y. So when systemic or ocular risk factors for miosis during surgery are present (see “Risk Factors for Small Pupils”), the surgeon must plan ahead to prevent complications, he and others said.

“Preoperative recognition of the possibility [of miosis] is important because you have to prepare your operating room staff for the devices you may need, and so on,” said Joshua P. Vrabec, MD, at the University of Michigan Kellogg Eye Center.

Mechanical Approach



(1) Inject the Malyugin Ring 2 mm and pause, then move injector forward and engage the distal iris margin. (2) Inject approximately another 3 mm, and engage the lateral scrolls. (3) Lay the proximal scroll on top of the iris. (4) Put an Osher/Malyugin Ring Manipulator in the proximal scroll, push distally and a bit to the posterior, then guide the scroll into place proximally.

Size matters. A pupil that fails to dilate to at least 5 mm in the clinic suggests that, intraoperatively, the pupil might become too small to allow an adequately sized capsulorrhexis, Dr. Vrabec said. “A small pupil also often is a predictor for intraoperative floppy iris syndrome [IFIS], which is much easier to deal with if you think about it ahead of time—rather than trying to deal with it when you have miosis of the pupil and iris prolapse through

your incision,” he said.

Dr. Vrabec added that he remains cautious about pupils in which the maximal dilation is moderate. “If the pupil is less than 7 mm, I will notate in the chart that we may possibly need to use pupil expansion devices for the surgery,” he said.

IFIS-related surprises. Dr. Vrabec and Thomas A. Oetting, MS, MD, at the University of Iowa, in Iowa City, say that it’s important to be ready to

act quickly against IFIS-related miosis, even if the pupil dilated well before surgery. The hard thing is when patients have been on a selective alpha blocker, but the pupil starts out big enough, said Dr. Oetting. “That can kind of lull you to sleep.”

Sometimes a patient does not recall taking an alpha-1-adrenergic receptor antagonist because the exposure was brief, Dr. Vrabcic said. “Trying an alpha blocker for just a couple of days, even in the distant past, can lead to IFIS forever. So you have to really press the patient when taking the history.”

The femtosecond laser issue. In the early days of femtosecond laser–assisted cataract surgery, users reported that small pupils could lead to complications such as an incomplete capsulorrhexis. Although small pupils remain listed as a contraindication, experienced surgeons have reported developing techniques to enable the procedure in these eyes.¹

Surgical Aids: Mechanical Solutions

During surgery, several devices can be helpful in cases of intraoperative miosis.

Viscoelastics. If it is a borderline decision whether the pupil is large enough, instillation of a high-molecular-weight ophthalmic viscoelastic, such as Healon G (Abbott Medical Optics), can open it sufficiently for an effective and safer surgery, Dr. Donnenfeld said.

Pupil-expanding devices. Familiar tools for coping with small pupils include iris hooks; stretching devices such as the Beehler Pupil Dilator (Moria); and pupillary rings such as Perfect Pupil (Milvella) and the Malyugin Ring (MicroSurgical Technology).^{2,3}

Both Dr. Oetting and Dr. Vrabcic prefer the disposable polypropylene Malyugin device. Dr. Oetting said that he tends to use the Malyugin as opposed to iris hooks, “It is easier to get in and out; you don’t have to make any additional incisions; and the fluidics is better because there is no leakage [that might otherwise occur] through the wounds made for the iris hooks.”

Dr. Vrabcic agreed, “I used hooks

in the past, during my residency, but I converted quickly to the Malyugin after I came to Michigan because of the ease of use and the good results.”

Potential drawbacks. With hooks or any other device that requires mechanical manipulation, there is a risk of damaging the iris, these surgeons said. “The surgeon has to be careful,” Dr. Vrabcic said. He added that with the Malyugin Ring, the surgeon must take care not to snag the capsule in the device, particularly if it is being placed after the capsulorrhexis in the scenario of intraoperative miosis.

Off-Label Prevention: 3 Approaches

Various off-label drug regimens to prevent intraoperative miosis have been proposed in the phacoemulsification literature; however, widespread consensus on drug choice and delivery route (injection vs. irrigation) has been elusive. The preoperative topical nonsteroidal anti-inflammatory drugs (NSAIDs) that are used to prevent inflammation also have been investigated for their ability to prevent miosis.

1. Intracameral: In the Irrigant

Phenylephrine + lidocaine. In Sweden, researchers at Umeå University first reported in 2003 on intracameral administration of a mydriatic mixture containing preservative-free cyclopentolate 0.1 percent, phenylephrine 1.5 percent, and lidocaine 1.0 percent (to paralyze the pupil sphincter).⁴ Later, they concluded that the cyclopentolate was unnecessary.⁵

Today, their phenylephrine/lidocaine combination is added to the irrigating bottle in about one-third of Sweden’s cataract surgeries, said coinvestigator Anders Behndig, MD, PhD, at the Umeå University Hospital. “It is also used to a lesser extent in our neighboring Nordic countries, but, as far as I know, to a much lesser extent in the rest of Europe.”

Epinephrine. Intracameral epinephrine also is commonplace in Europe, even in patients without risk factors for intraoperative miosis, Dr. Behndig said. “Epinephrine addition to the irrigation solution has been routinely used by many surgeons—at least

in Europe—since the 1990s.”

Dr. Oetting and Dr. Vrabcic said they, too, add epinephrine to the irrigation fluid. Dr. Oetting said, “We use 0.5 cc of 1:1,000 epinephrine [1 mg/mL; JHP Pharmaceuticals] in the 500-cc BSS bottle for every case.” Dr. Vrabcic said he prefers a slightly more dilute preparation: 0.25 cc of 1:1,000 epinephrine in the 500-cc bottle of BSS.

2. Intracameral: By Injection

Lidocaine/epinephrine as surgery begins. In the United States, ad hoc preparations commonly mentioned for intracameral injection are “Shugarcaine” and “epi-Shugarcaine,” named after the Florida ophthalmologist who devised them, Joel K. Shugar, MD. The solutions contain either preservative-free lidocaine 0.75 percent alone, or lidocaine plus preservative-free, bisulfite-free epinephrine 0.025 percent, mixed in fortified BSS.

Epinephrine injection. Dr. Vrabcic said that he injects a dose of 1:4,000, preservative-free epinephrine, diluted in BSS, in every eye that is at risk for IFIS, regardless of pupil size. “I’m a firm believer in this. So I inject this at the beginning of these surgeries, right after the intracameral anesthetic, and then wait 60 seconds before proceeding with the case,” he said.

3. Adjunctive topicals: NSAIDs

Because topical NSAIDs have been shown to support mydriasis,⁶ Dr. Vrabcic’s presurgical eyedrop regimen for all patients includes an inexpensive NSAID drop, flurbiprofen. “This is the standard-of-care that we have agreed on in our group,” he said.

Dr. Oetting said his topical NSAID of choice is another generic, ketorolac. “There is not really good, unbiased evidence about which NSAID is better to use,” he said.

FDA-Approved Prophylaxis

The brand-new Omidria is intended to prevent miosis, as well as to reduce postoperative pain. It contains a mydriatic, phenylephrine, and the NSAID ketorolac (respectively 1 percent and 0.3 percent weight per volume when added to 500 mL of ophthalmic ir-

rigating fluid). Last spring, the U.S. Food and Drug Administration approved Omidria for addition to the irrigation bottle during cataract surgery, and sales began in April.

The data. The FDA clinical trials randomized 808 cataract surgery patients to placebo or Omeros' phenylephrine/ketorolac mixture in the irrigation fluid. The studies showed:⁷

- Eyes that received Omidria maintained mydriasis throughout phacoemulsification surgery, whereas in untreated controls, the pupils began narrowing steadily when the incision commenced.
- 23 percent of placebo-treated subjects and 4 percent of those who received Omidria had a pupil diameter less than 6 mm after cortical cleanup ($p < .01$).
- Pupils in the placebo group constricted by a mean of 0.5 mm at 5 minutes and 1.5 mm at 10 minutes, compared with less than 0.1 mm in the Omidria group at both time points.
- 26 percent of the treated patients reported having no pain in the 10 to 12 hours after the surgery, compared with 17 percent of the placebo patients ($p < .01$).

Dr. Donnenfeld noted that the impact of pain on the patient's overall experience should be appreciated. "Surgeons view success in terms of visual acuity, but patients view it also in terms of the discomfort they felt. And the patients who had Omidria had a statistically significant reduction in pain compared to placebo," he said.

Question of costs. Omidria is subject to a "pass-through" ruling by the Centers for Medicare & Medicaid Services (CMS). With this pass-through status, ambulatory surgery centers and other outpatient facilities will be

reimbursed for Omidria's cost (\$465 wholesale per single-use vial) in cataract surgeries on patients covered by Medicare Part B. (As always, Medicare Advantage plans and commercial carriers may or may not follow the guidelines set forth by Medicare Part B.) Pass-through status expires after three years.⁸

Dr. Donnenfeld, who was an investigator in the FDA clinical trials and is a consultant to Omeros, manufacturer of Omidria, said that the CMS ruling makes Omidria a "win-win" for cataract surgeons and their Medicare patients. "The government has determined that this new medication has value," he said. "It's an opportunity to improve quality of care."

David B. Glasser, MD, Academy chair of the Health Policy Committee, said that, on the surface, it may seem that Medicare will reimburse in all cases. Yet in reality, the eight carriers that process Medicare Part B will each decide whether to reimburse for the drug. When Medicare does reimburse for the pass-through, the patient must make a copayment of 20 percent, or, in this case, \$93. "The irony is that the drugs ketorolac and phenylephrine cost only pennies per dose when used separately—and, so far, there is no evidence that the combined drug yields better outcomes," he said.

Cataract surgery under pressure. Of greater concern to Dr. Glasser is the potential for ophthalmologists to misconstrue the pass-through as implicit government encouragement of widespread adoption of this drug. Considering that CMS reimbursements for cataract surgery have seen sharp declines in the last few years, Dr. Glasser is worried about an almost \$500 increase to the total cost of cataract sur-

gery. "It's possible that the agency will look for ways to pare back payments elsewhere—specifically, to the procedure itself. I fear that ophthalmologists may wind up covering the cost of this drug in the form of further reimbursement cuts," he said. ■

1 Conrad-Hengerer I et al. *J Cataract Refract Surg.* 2013;39(9):1314-1320.

2 Goldman JM, Karp CL. *Curr Opin Ophthalmol.* 2007;18(1):44-51.

3 Chang DF. *J Cataract Refract Surg.* 2008;34(5):835-841.

4 Lundberg B, Behndig A. *J Cataract Refract Surg.* 2003;29(12):2366-2371.

5 Lundberg B, Behndig A. *J Cataract Refract Surg.* 2008;34(2):280-283.

6 Donnenfeld ED et al. *J Cataract Refract Surg.* 2006;32(9):1474-1482.

7 www.omidria.com/wp-content/uploads/OMIDRIA-Prescribing-Information.pdf.

8 www.corcoranccg.com/products/faqs/omidria.

Anders Behndig, MD, PhD, is professor of ophthalmology and chief physician in the Department of Clinical Sciences/Ophthalmology at Umeå University Hospital, in Umeå, Sweden. Financial disclosure: None.

Eric D. Donnenfeld, MD, is a cataract and refractive surgeon practicing at Ophthalmic Consultants of Long Island, in Rockville Centre, N.Y.; clinical professor of ophthalmology at New York University Medical Center; and a trustee of Dartmouth Medical School. Financial disclosure: Consultant for Alcon, Allergan, Bausch + Lomb, and Omeros.

David B. Glasser, MD, is assistant professor of ophthalmology, Johns Hopkins University School of Medicine in Baltimore; managing partner, Patapasco Eye MDs in Columbia, Md.; Academy chair of the Health Policy Committee. Financial disclosure: None.

Thomas A. Oetting, MS, MD, is professor of clinical ophthalmology and director of the ophthalmology residency program at the University of Iowa, and chief of eye service and deputy director of surgery service at the Veterans Administration Medical Center, in Iowa City. Financial disclosure: None.

Joshua P. Vrabec, MD, is a comprehensive ophthalmologist, cataract surgeon, and assistant professor of ophthalmology at the University of Michigan's Kellogg Eye Center, in Ann Arbor. Financial disclosure: None.

Risk Factors for Small Pupils

Diabetes mellitus	Surgical trauma
Femtosecond laser use for capsulorrhexis/phacofragmentation	Synechia
Miotic therapy	Systemic conditions with associated ocular pathology (e.g., Horner syndrome, myotonic dystrophy)
Prior laser photocoagulation	Tamsulosin and other alpha blockers
Pseudoexfoliation	