

Blink

FRANCISCA CARRAGÉIS, HOSPITAL ESPÍRITO SANTO EPE, ÉVORA, PORTUGAL

WHAT IS THIS MONTH'S MYSTERY CONDITION? Join the conversation at www.eyenet.org, where you can post a comment on this image.

LAST MONTH'S BLINK

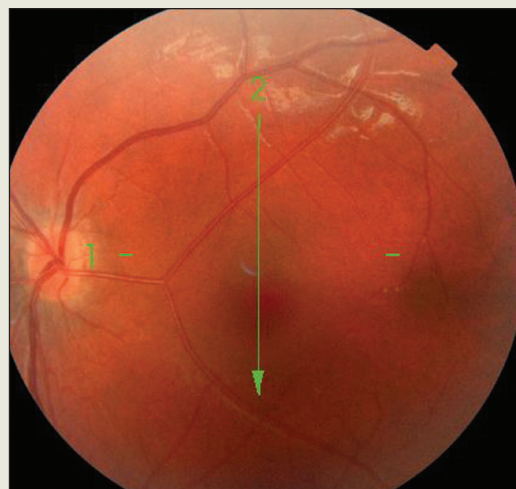
Congenital Vascular Anomaly

A 1-year-old child was referred to our hospital to rule out strabismus. The exam revealed an overaction of the left inferior oblique muscle without deviation in primary gaze position.

On further examination, we encountered incidental findings unrelated to the patient's presentation. A dilated exam of the left fundus revealed a prominent artery crossing temporally from optic nerve to macula that branched without affecting the avascular foveal zone, and the right fundus showed a prominent cilioretinal artery. Optical coherence tomography demonstrated a preserved foveal contour in both eyes.

We performed a nuclear magnetic resonance angiography under sedation, but it did not reveal any vascular alterations in the orbits or the brain.

Written by **Emilio Dorronzoro Ramírez, MD, Moraleja Hospital, Madrid.**



Emilio Dorronzoro Ramírez, MD, Moraleja Hospital, Madrid