

## REFRACTIVE SURGERY

# 15 Years of MMC for Surface Ablation: Tips and Techniques

BY MIRIAM KARMEL, CONTRIBUTING WRITER

INTERVIEWING DAVID R. HARDTEN, MD, FACS, ELIZABETH M. HOFMEISTER, MD, MC, USN, PARAG A. MAJMUDAR, MD, AND STEVEN E. WILSON, MD

Even though ophthalmologists have 15 years of experience with mitomycin C (MMC) to treat and prevent corneal haze following surface ablation, questions still abound regarding its optimal use and long-term safety.

Yet cornea specialists suggest that the longer they use this potent anti-metabolite, the more comfortable they are with it. Used judiciously, MMC is something of a wonder drug for preventing the visually significant corneal subepithelial fibrosis that can occur after surface ablation procedures, from photorefractive keratectomy (PRK) to epi-LASIK and phototherapeutic keratectomy (PTK).

“We continue to find it increasingly safe and useful,” said David R. Hardten, MD, FACS, director of refractive surgery at Minnesota Eye Consultants in Minneapolis. More than a decade ago, Dr. Hardten reported that MMC has such a narrow therapeutic range that toxicity “is seen more often with this medication than with many other medications used in ophthalmology.”<sup>1</sup> Today, he uses MMC in every surface ablation.

Capt. Elizabeth M. Hofmeister, MD, MC, USN, also uses MMC with every surface ablation, although her situation—treating Navy and Marine Corps service members bound for Afghanistan—is unusual.

Still, she is anything but sanguine about its use. “The problem with haze is we don’t know exactly what the

risk factors are,” said Dr. Hofmeister, refractive surgery advisor for Naval Ophthalmology and assistant professor of surgery at the Uniformed Services University of Health Sciences in Bethesda, Md. A large study is needed to determine who gets MMC and for how long, she said.

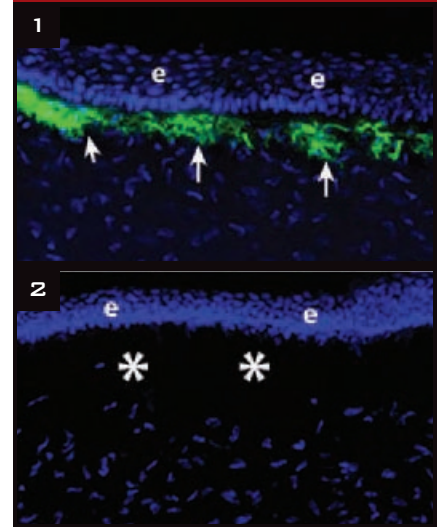
Given MMC’s potential toxicity, a successful outcome hinges on knowing the optimal drug concentration and application, the ideal adjustment of nomograms, and how to select patients appropriately and monitor for potential toxicity, said Parag A. Majmudar, MD, associate professor of ophthalmology at Rush University Medical Center in Chicago.

### How It Works

MMC is a mitotic inhibitor that blocks keratocyte activation and proliferation as well as myofibroblast differentiation. Its predominant effect is to inhibit or treat haze by blocking the repopulation of keratocytes or other progenitor cells of myofibroblasts, the cells that produce the most haze in the cornea,<sup>2</sup> noted Steven E. Wilson, MD, professor of ophthalmology and director of corneal research at the Cleveland Clinic.

In cases of post-PRK scarring, mitomycin doesn’t eliminate haze. “It prevents keratocytes from developing new haze,” Dr. Majmudar said. Existing scar tissue must be fully removed first, then MMC is applied to ensure against the proliferation of keratocytes that could create new haze, he said.

### Haze in Detail



Rabbit corneas were treated with –9 D PRK and then treated with vehicle control or 0.02 percent MMC for 60 seconds. After one month, corneas were removed and stained for the myofibroblast marker alpha-smooth muscle actin (green, arrows) and all cell nuclei. (1) In a vehicle-treated cornea, many myofibroblasts that produce haze were generated beneath the epithelium (e). (2) In the MMC-treated cornea, no myofibroblasts were generated. Note the acellular zone (\*) in the anterior stroma of the MMC-treated cornea. Magnification x400.

### The Haze Conundrum

“We don’t know who’s going to get haze,” Dr. Majmudar said. “There are probably cases where you don’t use mitomycin and don’t get haze.” But the one case in which you don’t use it

and haze develops will be the case that haunts you, he said.

Dr. Wilson agreed. Perhaps only 5 percent of patients would develop haze without MMC, depending on the level of correction, he said. But haze is such a long-term, serious problem that doctors tend to use MMC more often than not.

**There are trade-offs.** Corneas treated with MMC have a lower keratocyte cell density for some time after they heal. “Nobody knows if this is important or not,” Dr. Wilson said, adding that confocal microscopy has shown that density is restored at five years. Some, however, suggest that it is never restored, he said. The upshot: Usage varies widely, with some surgeons limiting their use of MMC, and others using it on everybody.

### Rules of Thumb for MMC Use

**Consider the surface.** Although Dr. Wilson limits his overall use of MMC, he always applies it in enhancement procedures because they’re more prone to haze development. “It doesn’t matter if the previous work was PRK or LASIK. If they’re getting a surface ablation enhancement, they get MMC.”

In virgin eyes, Dr. Wilson usually applies MMC only to patients with more than 5 D of myopia and/or more than 1.5 D of astigmatism. “People above those ranges, with my Visx laser, have a possibility of developing haze.” He added that, in the past, when he used the Autonomous laser, patients with even 1 D correction tended to get haze. Thus, you have to know at what level of myopia and astigmatism your patients can develop haze with your particular laser, he said.

**Why does laser choice matter?** The newer lasers tend to create smoother surfaces. “If it’s smooth, the basement membrane can heal normally, and you don’t get haze because there is lower penetration of epithelial-derived cytokines like transforming growth factor-beta that drive myofibroblast generation,” Dr. Wilson said. But any irregularity of the surface can affect the complete healing of the basement membrane. “That’s a critical factor of

whether the cornea gets haze.”

Some theories posit that heat from a laser’s energy is a factor in haze development. Dr. Wilson disagrees. “Our studies showed that the total energy delivered, at least in the normal treatment ranges from 0.5 to 10 D of myopia with a normally functioning excimer laser, was not important. Rather, it was surface irregularity, which tended to be directly related to the level of attempted correction and resulting surface irregularity, that was important in myofibroblast and haze generation.”<sup>2</sup>

**Consider the depth.** Dr. Hofmeister said that while the modern laser did not eliminate haze, “modern ablation profiles—wavefront guided or wavefront optimized—cause less thermal damage than older models.”

However, Dr. Majmudar does believe that the amount of laser energy delivered to a susceptible cornea is likely the key factor in haze development. Since there is no way to gauge the laser energy delivered in a given case, he lets the ablation depth be his guide. He applies MMC to any ablation deeper than 75  $\mu\text{m}$ . This figure is

## Expert Insights on MMC Use

**Track the meds on your table.** Dr. Hardten suspects that medical error may be behind reports of acute endothelial cell loss the day after surface ablation with MMC. In some of those cases, a surgeon might have mistakenly switched MMC with the alcohol used to remove epithelium—and doing so would significantly damage the endothelium, he said.

**His advice:** “When using more than one medication on the table, keep a line of identification.”

**Use caution when compounding.** Most surgeons speak in terms of MMC 0.02 percent. But some refer to the equivalent, 0.2 mg/cc. Pay attention to the difference, Dr. Majmudar warned. If you’re doing your own compounding and mistakenly use MMC 0.2 percent instead of 0.02 percent, you’re applying 10 times the correct concentration, which can be toxic to the corneal endothelium and other structures in the eye.

**His advice:** “We don’t recommend self-compounding of MMC. A pharmacy should do it, because it’s very easy to make dilutional mistakes.”

**Avoid overcorrection.** Dr. Majmudar has found that MMC after PRK results in a slight overcorrection. “MMC does affect the wound healing. With PRK, there’s often a flattening effect from the excimer laser followed by an immediate, mild steepening effect. With MMC, you may not get that compensatory steepening, so the slight hyperopia that occurs after PRK may not regress.”

**His advice:** Reduce the spherical correction by 10 percent and track your outcomes to ensure refractive accuracy.

derived from the days of broad-beam lasers when the risk of developing haze was thought to be greatest in patients requiring more than –6 D of correction, which correlates to approximately 75  $\mu\text{m}$  of ablation depth.

**Consider concentration and timing.** The question of concentration “is pretty much resolved,” said Dr. Wilson, who uses MMC 0.02 percent in all cases. Only the timing varies. He applies it for 30 seconds in all eyes without previous surgeries or injuries and in cases of routine enhancement. He leaves it on for 60 seconds in cases that involve previous penetrating keratoplasty or incisional surgery in the cornea, such as radial keratotomy, as well as in any situation in which there is a greater chance of scarring.

“That’s the standard of care now,” agreed Dr. Majmudar, who applies MMC 0.02 percent for 12 to 120 seconds. The shorter application is for virgin eyes receiving PRK. “You don’t need as much MMC to quiet keratocytes that have not been previously activated,” he said.

Keratocytes are dormant until injury or insult. But keratocytes that have

been activated, as in cases of existing corneal haze, may require a longer duration of application in order to prevent recurrence.

Dr. Hofmeister goes against the grain by using a lower concentration—MMC 0.01 percent for 15 seconds in every eye she treats. She tested the dose in a study of 28 patients in which one eye received 0.01 percent solution while the other eye got placebo.<sup>3</sup> Neither eye developed more than trace haze.

Dr. Hofmeister's approach isn't standard of care or even standard Navy policy. But her patients are deploying to very austere environments without access to subspecialist care, so she delivers a prophylactic dose of MMC with every PRK. "We don't know who is going to get haze, but if they do get it, it's a show stopper."

For enhancements, Dr. Hofmeister extends the application time to 30 seconds. For existing haze, she applies MMC 0.02 percent.

**Consider preexisting disease.** Dr. Majmudar recommends exercising caution when using MMC on patients who have severe dry eye from an autoimmune disease or in cases in which the ocular surface is compromised.

### Application Methods

**What to avoid.** "The method of application of MMC is critical," said Dr. Majmudar. He warned against letting MMC come into contact with limbal stem cells or other ocular structures. Limbal stem cells are the source for corneal epithelial cell regeneration, and damage to this area may delay re-epithelialization.

It's also important to avoid contact with the sclera, which is highly vascular, Dr. Majmudar said, because ischemia can be a trigger for melting. He noted that one theory suggests that confining MMC to the avascular central cornea would eliminate cases of corneal melting. "Worldwide experience over 15 years has borne that out."

**What to do.** Dr. Majmudar soaks a 6-mm round sponge, squeezing out the excess solution before placing it on the central cornea after the excimer laser ablation. Then he aggressively irrigates

the surface of the cornea with 30 cc (two 15-cc bottles) of saline solution to remove excess MMC.

Dr. Hardten paints MMC 0.01 to 0.02 percent on the cornea with a cellulose sponge, then dries any excess off the surface before irrigating the eye. He varies the application from 10 seconds for a 10- $\mu$ m ablation to 120 seconds in eyes that have had corneal transplants, other lamellar procedures, or prior LASIK flaps. The time depends on his assessment of the risk of postoperative scar formation.

### What We Don't Know

"We're doing surface ablations in patients who are 21 years old. We really don't know what effect this will have when they're 70," Dr. Wilson said. Forty years from now, will ophthalmologists be seeing stromal melting or unhealthy epithelium in these eyes? "I've never seen anything to suggest that it's going to be a problem, but my understanding of corneal biology makes me continue to worry about it."

Dr. Majmudar agreed that long-term safety remains a concern. Nonetheless, he noted, "We've seen enough patients treated over the past 15 years that if problems were going to occur, we would likely have seen some hint of them by now."

While it's reassuring to see patients who are doing well many years later, Dr. Hofmeister stressed that MMC is used off label. "It's an area of extreme controversy," she said. "We're taking healthy eyes that see well [and treating them]. Above all, we don't want to harm people."

1 Hardten DR, Samuelson TW. *Int Ophthalmol Clin.* 1999;39(2):79-90.

2 Netto MV et al. *J Refract Surg.* 2006;22(6):562-574.

3 Hofmeister EM et al. Best Paper of Session, ASCRS 2011. Abstract available at: [www.ascrs.org/best-paper-session-bpos-winners-2011](http://www.ascrs.org/best-paper-session-bpos-winners-2011).

*Drs. Hardten, Hofmeister, and Wilson report no financial interests. Dr. Majmudar consults for Mobius Therapeutics but has no financial interest in this subject matter.*

## Write for Us! EyeNet

### Got Pearls?

Share your knowledge with your colleagues! Ophthalmic Pearls articles provide a literature review and offer helpful tips on disease management or procedures in widespread use.

### Are you a resident?

Authorship of an Ophthalmic Pearls will satisfy the RRC requirements for resident scholarly activity.



### HOW TO WRITE AN OPHTHALMIC PEARLS ARTICLE

1. Come up with a topic, and e-mail Patty Ames (pames@aao.org) to clear it before writing.
2. Medical students, residents, and fellows: Team up with a faculty member who can provide pearls from experience.
3. Send at least one photo or illustration.
4. Use subheadings to help readers easily navigate your 1,500-word article.
5. Keep references to five or fewer, if possible.

### SUBMISSIONS

E-mail your manuscript and art to [pames@aao.org](mailto:pames@aao.org).