



Telemedicine for Evaluation of Retinopathy of Prematurity

Walter M. Fierson, MD, FAAP, Antonio Capone Jr, MD, the AMERICAN ACADEMY OF PEDIATRICS SECTION ON OPHTHALMOLOGY, AMERICAN ACADEMY OF OPHTHALMOLOGY, and AMERICAN ASSOCIATION OF CERTIFIED ORTHOPTISTS

abstract

Retinopathy of prematurity (ROP) remains a significant threat to vision for extremely premature infants despite the availability of therapeutic modalities capable, in most cases, of managing this disorder. It has been shown in many controlled trials that application of therapies at the appropriate time is essential to successful outcomes in premature infants affected by ROP. Bedside binocular indirect ophthalmoscopy has been the standard technique for diagnosis and monitoring of ROP in these patients. However, implementation of routine use of this screening method for at-risk premature infants has presented challenges within our existing care systems, including relative local scarcity of qualified ophthalmologist examiners in some locations and the remote location of some NICUs. Modern technology, including the development of wide-angle ocular digital fundus photography, coupled with the ability to send digital images electronically to remote locations, has led to the development of telemedicine-based remote digital fundus imaging (RDFI-TM) evaluation techniques. These techniques have the potential to allow the diagnosis and monitoring of ROP to occur in lieu of the necessity for some repeated on-site examinations in NICUs. This report reviews the currently available literature on RDFI-TM evaluations for ROP and outlines pertinent practical and risk management considerations that should be used when including RDFI-TM in any new or existing ROP care structure.

FREE

This document is copyrighted and is property of the American Academy of Pediatrics and its Board of Directors. All authors have filed conflict of interest statements with the American Academy of Pediatrics. Any conflicts have been resolved through a process approved by the Board of Directors. The American Academy of Pediatrics has neither solicited nor accepted any commercial involvement in the development of the content of this publication.

The guidance in this report does not indicate an exclusive course of treatment or serve as a standard of medical care. Variations, taking into account individual circumstances, may be appropriate.

Technical reports from the American Academy of Pediatrics benefit from expertise and resources of liaisons and internal (AAP) and external reviewers. However, technical reports from the American Academy of Pediatrics may not reflect the views of the liaisons or the organizations or government agencies that they represent.

All clinical reports from the American Academy of Pediatrics automatically expire 5 years after publication unless reaffirmed, revised, or retired at or before that time.

www.pediatrics.org/cgi/doi/10.1542/peds.2014-0978

DOI: 10.1542/peds.2014-0978

Accepted for publication Apr 2, 2014

PEDIATRICS (ISSN Numbers: Print, 0031-4005; Online, 1098-4275).

Copyright © 2015 by the American Academy of Pediatrics

I. INTRODUCTION

The elimination of preventable blindness attributable to retinopathy of prematurity (ROP) continues to be an ongoing challenge for both ophthalmologists and neonatologists. The clinical benefits of appropriate and accurate periodic retinal evaluations to establish the presence of treatable ROP have been well documented through the use of well-controlled multicenter studies. Bedside binocular indirect ophthalmoscopy (BIO) has been the standard technique for retinal evaluation in premature infants.

A combination of factors has fueled interest in telemedicine (TM)-based remote digital fundus imaging (RDFI-TM) evaluations for ROP. ROP

remains a leading cause of morbidity despite, as well as because of, advances in neonatal care, which have improved survival rates of at-risk infants born prematurely.¹ Although there is an ongoing need for screening for ROP, reimbursement issues, liability concerns, and the complexities associated with coordinating ROP services are possibly resulting in insufficient numbers of qualified ophthalmologists willing to provide screening for infants at risk for developing ROP. Although malpractice claims against ophthalmologists and neonatologists for failure of diagnosis or mismanagement of ROP are relatively uncommon, awards can be extremely high because of the age of the patients involved and the severity of visual disability that may occur. Approximately 9% of infants with high-risk prethreshold ROP will have an unfavorable structural outcome despite timely treatment,² which compounds the problem. In addition, decentralization of neonatal care to community hospitals offering higher level NICUs for premature neonates requires ophthalmologists to service one or more facilities with a small number of infants requiring care in these units. The duty of the ophthalmologist providing ROP evaluation services to coordinate and track ongoing care is complex.³ Lastly, reimbursement may be inadequate to address the liability, travel, and tracking aspects of ROP care.

II. PROBLEM STATEMENT

From a health policy perspective, an ideal approach to assessing an RDFI-TM paradigm for ROP evaluation would define the purpose of the system, determine the performance relative to a criterion standard, measure technical validity, determine associated risks, and include cost analyses.⁴ A number of reports have addressed various aspects of this issue.^{5–11} However, the pace of implementation of RDFI with TM for ROP evaluation in the ophthalmic

community has outstripped the pace of systematic evaluation of the approach. A consensus “standard of care” has not yet been established.

The purpose of the present assessment was twofold: to systematically review the available literature on RDFI-TM evaluation for ROP and to outline pertinent practical, financial, and risk management considerations that should be included in a new or existing ROP care structure that uses RDFI-TM.

III. LITERATURE REVIEW

A. Background

There is ample precedent for the use of fundus imaging in the diagnosis of retinal disease. There is a more than 25-year history of fundus imaging for the evaluation of diabetic retinopathy, first defined for the Diabetic Retinopathy Study.¹² The gold standard for the detection and classification of diabetic retinopathy is 7 standard field stereoscopic 35-mm color fundus photographs, as defined by the Early Treatment Diabetic Retinopathy Study group.¹³ A TM approach for diabetic retinopathy has been deployed within the Veterans Health Administration,¹⁴ in Native American health facilities,¹⁵ and by a growing number of primary care providers.¹⁶ Unfortunately, an analysis of the effectiveness of these programs has not been published.

The prospect of using RDFI to supplement face-to-face evaluations is enticing. Proponents contend that serial imaging would improve access to and frequency of evaluation, facilitate objective dialogue regarding recorded findings, potentially bring a high level of expertise to each child evaluated, provide outcomes data, and mitigate liability exposure in the event that vision loss does occur despite appropriate care. Detractors of the use of RDFI in ROP evaluation cite the difficulty in imaging the retinal periphery, limited image

quality in certain circumstances (eyes with poor dilation, media haze, or dark fundus pigmentation), variability in image interpretation even among experienced clinicians,¹⁷ insufficient evidence,¹⁸ and high implementation cost (hardware, software, and nonphysician personnel). However, the results of the recently published e-ROP Study¹¹ provide strong support for an RDFI paradigm.

B. Description of the Technique

By definition, TM is “the use of electronic information and communications technologies to provide and support health care when distance separates the participants.”¹⁹ The current electronic information in ROP evaluations consists of fundus images acquired with a digital, fiber optic, wide-angle, color fundus camera. Images are taken in the NICU and then transmitted to a remote location for interpretation.⁷ Further technical detail is provided in Section IV.

C. Resource Requirements

See Section IV-A below.

D. Question for Assessment

This assessment is directed to address the following question: Is an RDFI-TM evaluation approach effective in identifying infants with ROP who need to be referred for BIO? This report does not suggest that RDFI screening can completely replace or eliminate the need for bedside BIO in the examination process for infants at risk for ROP.

E. Description of Evidence

PubMed and the Cochrane Library were searched on August 1, 2008; August 4, 2008; April 14, 2009; and June 26, 2014.²⁰ The search strategy used the following Medical Subject Headings (MeSH) and text terms. An asterisk represents a truncated term.

(“Infant”[MeSH] OR pediatric* OR baby OR babies OR neonat* OR prematur* OR “Gestational Age”[MeSH] OR newborn*) AND

("Telemedicine"[MeSH] OR telemedic* OR "retinal image*" OR "Telepathology"[MeSH] OR telephotoscreen* OR "Image Processing, Computer-Assisted"[MeSH] OR "fundus image*" OR "RetCam" OR "Photography"[MeSH] OR "Remote Consultation"[MeSH] OR "fundus camera*" OR "wide-angle camera*" OR "wide-angle contact photograph*" OR "Image Interpretation, Computer-Assisted"[MeSH] OR "Diagnosis, Computer-Assisted"[MeSH] OR "teleophthalmology" OR "retinal photograph*" OR "computer-based image analysis" OR "digital image*" OR "digital photo*" OR "wide-angle image*" OR "wide-angle retinal photo*" OR "clinical photo*" OR photo* OR camera*) AND ("Retinopathy of Prematurity"[MeSH] OR "retinopathy of prematurity" OR "ROP" OR "RoP" OR "Retinal Diseases/diagnosis"[MeSH])

The searches retrieved 486 references in all languages. Fifty-six of these were written in languages other than English, and these articles were not reviewed further. Ten of these retrieved citations were meeting abstracts and were not considered in the assessment.

The authors independently assessed the abstracts retrieved from the electronic searches and marked 84 that potentially met the following inclusion criteria: original research that evaluates a clinical ROP diagnosis with digital retinal photography using a wide-angle camera. These 84 studies were reviewed in full text, and 30 met the inclusion criteria. The authors extracted information from these 30 studies about study design, interventions, outcomes, and study quality. After the data were abstracted, 9 studies were excluded for the following reasons: the reference standard was not indirect ophthalmoscopy (4 studies), the study was a case report (2 studies), the study reported outcomes other than ROP diagnosis (2 studies), and the study reported only study design/baseline characteristics (1 study). An additional 2 studies reported use of digital retinal photography for diagnosis of any ROP but not for

clinically significant ROP, and these articles were also excluded. Of the remaining 19 studies, 8 were supplanted by more recent publications speaking to the same data set. Of these, only the most recent publication in a series was selected, leaving 11 studies that were included in this assessment.

A methodologist (Michele Melia, ScM, Jaeb Center for Health Research, Tampa, FL) reviewed the 11 studies and the data abstraction forms and assigned ratings based on the Oxford Centre for Evidence-based Medicine Levels of Evidence.²¹ Eight studies were rated as level I, and 3 were rated as level III. No articles were given a level II rating.

The level I-rated studies all had an independent masked comparison of a cohort of consecutive subjects who were representative of the population requiring screening, and all subjects received both wide-angle digital retinal photography and the reference standard ophthalmoscopic examination. The level III studies were rated as such because of a lack of independence between the reference standard and digital retinal photography. In one of these studies, only infants already diagnosed with ROP according to indirect ophthalmoscopy were photographed.²² In another study, the gold standard indirect ophthalmoscopy examination was not performed on all infants.²³ In the third study, indirect ophthalmoscopy was performed immediately if the photographs indicated referral-warranted ROP (ie, ROP possibly requiring treatment); otherwise, ophthalmoscopy was not performed until discharge.²⁴

All studies described in the present assessment evaluated detection of any ROP by using wide-angle digital retinal photography (RetCam 120, RetCam II, or RetCam 3; Clarity Medical Systems, Inc, Pleasanton, CA). In general, all studies compared the accuracy of image-based diagnosis by remote readers versus a reference

standard of dilated ophthalmoscopic examinations by an expert.

The study designs differed in 5 aspects: (1) the number of wide-angle retinal photographs taken, which ranged from 1 to 15 per eye examination; (2) the background of personnel, who included ophthalmologists, ophthalmic photographers, and trained NICU nurses, who captured retinal photographs; (3) the image readers, who included retinal specialists, pediatric ophthalmologists, and general ophthalmologists; (4) the diagnostic outcome measures, which included detection of moderate ROP (eg, presence of type 2 or worse disease) and detection of severe ROP (eg, presence of treatment-requiring disease); and (5) the metrics of accuracy. These accuracy metrics included sensitivity (likelihood that a patient with disease, on the basis of the reference standard examination, is identified by using digital photography), specificity (likelihood that a patient without disease, on the basis of the reference standard examination, is ruled out by using digital photography), positive predictive value (likelihood that a patient identified by using digital photography has the disease, on the basis of the reference standard examination), negative predictive value (likelihood that a patient ruled out for the disease by using digital photography does not have the disease, on the basis of the reference standard examination), absolute agreement (percentage of cases in which different graders agree on diagnosis), and the κ statistic (chance-corrected agreement among graders in which 1 represents perfect agreement and 0 represents agreement by pure chance).

The published studies used several measures of accuracy. For purposes of cross-study comparison, the sensitivity, specificity, positive predictive value, negative predictive value, and corresponding

95% confidence intervals (CIs) were abstracted directly from each article or calculated by the methodologist on the basis of data provided in the article. When possible, 95% CIs were calculated by using the binomial exact method; otherwise, the normal approximation was used.

1. Level I Studies

Table 1 summarizes the level I studies, which evaluated detection of moderate and severe ROP by using wide-angle digital retinal photography.

Ells et al⁵ (371 examinations from 44 infants) examined detection of

referral-warranted ROP (defined as any ROP in zone I, presence of plus disease, or presence of stage 3 ROP at any time during the infant's hospital course) during longitudinal inpatient examinations. Digital photographs were taken after standard ophthalmoscopic examination by the

TABLE 1 Level I Studies Examining Detection of Moderate to Severe ROP by Using Digital Retinal Photography

| Author (Year) | Institution/Time Period | No. of Patients | Eligibility Criteria | Outcome/% With Outcome by Reference Standard | Sensitivity %/(95% CI) | Specificity %/(95% CI) | PPV % (95% CI) | NPV % (95% CI) |
|-------------------------------------|-------------------------------------------------------------------------------------|-----------------|--------------------------------------------------------|-----------------------------------------------------------------------------------------------------------------------------------------------------------------------------------------------------------------------------------------------------------------|-------------------------------------------------------------------------------------------------------|------------------------------------------------------------------------------------------------------------------|--------------------------------------------------------------------------------------------------------------------|-------------------------------------------------------------------------------------------------------------------------|
| Ells et al ⁵ (2003) | Foothills Hospital and Alberta Children's Hospital/Nov 2000–Nov 2001 | 44 | Gestational age <30 wk and <1500 g or at risk for ROP | Referral-warranted ROP ^a /32% | 100 (85–100) [§] | 96 (86–100) ^b | 92 (74–99) ^b | 100 (92–100) ^b |
| Chiang et al ⁷ (2006) | Jackson Memorial Hospital/Jan 1999–Dec 2000 | 64 | <1300 g or 1300–1800 g with >72 h oxygen therapy | Type 2 or worse ROP ^a /21% Type 1 or worse ROP ^a (ie, treatment-requiring)/11% | 77 (70–84) ^{b,c} 87 (79–95) ^{b,c} | 96 (94–98) ^{b,c} 96 (95–98) ^{b,c} | 83 (76–90) ^{b,c} 74 (64–83) ^{b,c} | 94 (92–96) ^{b,c} 98 (97–99) ^{b,c} |
| Wu et al ⁸ (2006) | Children's Hospital Boston and Brigham and Women's Hospital NICUs/Aug 2003–Jan 2004 | 43 | Gestational age <32 wk or <1500 g or high risk for ROP | Type 2 or worse ROP ^a /5% | 100 (16–100) | 97 (87–100) | 67 (9–99) | 100 (91–100) |
| Chiang et al ²⁵ (2007) | Columbia University/Nov 2005–Oct 2006 | 67 | Met existing criteria for examination | Type 2 or worse ROP at 31–33 wk ^a /6% Type 2 or worse ROP ^a at 35–37 wk/22% Type 1 or worse ROP ^a (ie, treatment-requiring) at 31–33 wk/0% Type 1 or worse ROP ^a (ie, treatment-requiring) at 35–37 wk/10% | 76 (70–82) ^{b,c} 100 (87–100) ^{b,c} NA (N = 0) 100 (74–100) ^{b,c} | 96 (93–98) ^{b,c} 91 (88–94) ^{b,c} 97 (95–99) ^{b,c} 89 (86–92) ^{b,c} | 55 (39–71) ^{b,c} 76 (68–83) ^{b,c} 100 (48–100) ^{b,c} 52 (42–63) ^{b,c} | 98 (97–100) ^{b,c} 100 (96–100) ^{b,c} 100 (96–100) ^{b,c} 100 (96–100) ^{b,c} |
| Photo-ROP ¹⁰ (2008) | 6 study sites/Feb 2001–Feb 2002 | 51 | <31 wk gestational age and <1000 g | Clinically significant ROP ^a /58% | 92 (81–97) ^b | 37 (23–52) ^b | 67 (55–77) ^b | 76 (53–92) ^b |
| Dhaliwal et al ²⁷ (2009) | Edinburgh Royal Infirmary NICU/Jun 2004–May 2007 | 81 | <32 wk gestational age or <1500 g | Stage 3/6% Plus disease/4% | 57 (29–82) ^b 80 (44–97) ^b | 68 (63–73) ^b 98 (95–99) ^b | 62 (32–86) ^b 62 (32–86) ^b | 68 (63–73) ^b 99 (97–100) ^b |
| Dai et al ²⁸ (2011) | Auckland City Hospital/June 2006–Dec 2007 | 108 | Met criteria for examination | Type 1 or worse ROP ^a (ie, treatment-requiring)/10% | 100 (72–100) | 98 (93–100) | 85 (55–98) | 100 (96–100) |
| Quinn et al ¹¹ (2014) | 12 US centers and 1 Canadian center/May 2011–October 2013 | 1257 | <1251 g | Zone 1 ROP, Stage 3 ROP or worse or plus disease/19.4% | 90 (85–94) | 87 (84–90) | 62.5 | 97.3 |

NA = not applicable; NPV = negative predictive value; PPV = positive predictive value.

^a Type 1 (treatment-requiring) ROP is defined as zone I, any stage ROP with plus disease; zone I, stage 3 ROP with or without plus disease; or zone II, stage 2 or 3 ROP with plus disease. Type 2 ROP is defined as zone I, stage 1 or 2 ROP without plus disease; or zone II, stage 3 ROP without plus disease. "Referral-warranted" ROP was defined by study authors as any stage ROP in zone I, presence of plus disease, or presence of any stage 3 ROP. "Clinically significant ROP" was defined by study authors as zone I, any stage ROP, without vascular dilation or tortuosity; zone II, stage 2 ROP, with up to 1 quadrant of vascular dilation and tortuosity; zone II, stage 3 ROP, with up to 1 quadrant of vascular dilation and tortuosity; any vascular dilation and tortuosity in eyes for which ridge characteristics were not interpretable (not imaged or poor image quality); or any stage ROP in eyes for which disc features (plus disease) were not interpretable (not imaged or poor image quality).

^b CIs were not corrected for correlation between eyes and/or multiple examinations per eye.

^c Sensitivity and specificity were reported as average for 3 individual graders.

same examiner. Hence, the technical execution of photography could conceivably have been influenced by knowledge of the severity of the ROP case. A masked independent pediatric ophthalmologist grader interpreted the photographs, with a sensitivity of 100% and a specificity of 96% compared with indirect ophthalmoscopy.

Chiang et al⁷ (163 examinations from 64 infants) examined a study cohort in which wide-angle retinal photographs were captured by an ophthalmic photographer. The accuracy of masked image interpretation was compared with a reference standard of dilated ophthalmoscopic examination by a pediatric ophthalmologist. Masked interpretation of wide-angle photographs by 3 image readers (1 general ophthalmologist and 2 retinal specialists) resulted in an average sensitivity of 77% and a specificity of 96% for detection of type 2 or worse ROP. For detection of treatment-requiring ROP (defined as type 1 or worse disease), the image readers had an average sensitivity of 87% and a specificity of 96%.

Wu et al⁸ (43 infants) examined the accuracy of wide-angle photography for detection of prethreshold or worse ROP in a longitudinal case series of infants meeting ROP-screening criteria. In this study, each infant was classified on the basis of serial examinations of both eyes. Images were taken by a pediatric ophthalmologist or ophthalmic photographer, and they were graded by a different masked pediatric ophthalmologist. No cases of prethreshold disease, threshold disease, or plus disease were missed by the reader, and digital photography had a sensitivity of 100% and a specificity of 97% compared with ophthalmoscopic diagnosis.

In a different cohort, Chiang et al²⁵ prospectively collected standardized sets of 3 to 5 wide-angle photographs

of each eye of the infants; these photographs were taken independently by a trained NICU nurse. The infants also received standard ophthalmoscopic examinations by a pediatric ophthalmologist. Examinations were performed at 31 to 33 weeks' postmenstrual age (PMA) and subsequently at 35 to 37 weeks' PMA (248 examinations from 67 infants), and masked photographic readings were performed by 3 pediatric retinal specialists by using a secure Web site. For photographs taken at 31 to 33 weeks' PMA, the average sensitivity for detection of type 2 or worse ROP was 76% and specificity was 96%. At 35 to 37 weeks' PMA, the average sensitivity for detection of type 2 or worse ROP was 100% and specificity was 91%, and the average sensitivity for detection of type 1 or worse ROP was 100% and specificity was 89%. In a separate study based on data from this cohort, Scott et al²⁶ compared ophthalmoscopic examination findings versus digital photographic interpretations in these 67 infants by the same graders. There was absolute agreement of 86% (178 of 206 eyes) and κ values of 0.66 to 0.85 between ophthalmoscopic examinations and digital photographic interpretations. Among the 14% (28 of 206 eyes) with discrepancies, some cases provided photographic documentation that ophthalmoscopy may have missed signs of mild ROP. In other cases, there were discrepancies between the presence of zone I ROP and the presence of plus disease; in these cases, photography may have provided the theoretical advantages of allowing examiners to review their diagnoses, make more exact measurements of anatomic landmarks defining zone I of the retina, and directly compare images with the standard photograph for plus disease.

The prospective, multicenter Photo-ROP (Photographic Screening for Retinopathy of Prematurity) study

(300 examinations from 51 infants) evaluated detection of "clinically significant ROP" at any time during multiple longitudinal inpatient examinations.¹⁰ This outcome measure was defined as follows: (1) zone I, any ROP, without vascular dilation or tortuosity; (2) zone II, stage 2, with up to 1 quadrant of vascular dilation and tortuosity; (3) zone II, stage 3, with up to 1 quadrant of vascular dilation and tortuosity; (4) any vascular dilation and tortuosity noted in eyes for which ridge characteristics were not interpretable (not imaged or poor image quality); or (5) any ROP noted in eyes for which disc features (plus disease) were not interpretable (not imaged or poor image quality). Photographs were taken by an ophthalmologist and graded by consensus of 2 masked ROP specialists. This study found that clinically significant ROP was detected with a sensitivity of 92% and a specificity of 37%.

Dhaliwal et al²⁷ (245 examinations from 81 infants) conducted a masked, prospective longitudinal case series. Two experienced pediatric ophthalmologists were randomized to perform examinations by using either wide-angle retinal photography or standard ophthalmoscopy. Five to 15 images were captured from each eye of infants by the examining ophthalmologist, and almost all examinations were performed between 32 and 36 weeks' PMA. Sensitivity of retinal photography for detection of stage 3 or worse ROP was 57%, and the specificity was 68% compared with ophthalmoscopic examination. Sensitivity for diagnosis of plus disease was 80%, and specificity was 98% compared with ophthalmoscopy. Absolute agreement between ophthalmoscopy and photography was 96% for detection of stage 3 ROP and 97% for detection of plus disease.

Dai et al²⁸ (422 examinations from 108 infants) evaluated the effectiveness of

wide-angle photography in a pilot TM study in which infants received serial digital photographs and concurrent standard ophthalmoscopic examinations by a pediatric ophthalmologist. Photographs were reviewed independently by a masked grader. Using ophthalmoscopic findings as the reference standard, the sensitivity of digital photographic reading for detecting treatment-requiring ROP (ie, type 1 or worse) was 100%, and the specificity was 98%. The positive predictive value of digital photographic reading for detecting treatment-requiring ROP was 85%, and the negative predictive value was 100%.

Quinn et al¹¹ (5520 examinations from 1257 infants) evaluated the validity of digital retinal image grading by trained, masked, nonphysician readers compared with diagnostic examinations by an ophthalmologist. A grading supervisor adjudicated disagreements. Using ophthalmoscopic findings as the reference standard, for remote grading of images when both eyes were considered for the presence of ROP requiring referral (as would routinely be done in a screening examination), sensitivity was 90.0%, with a specificity of 87.0%, a negative predictive value of 97.3%, and a positive predictive value of 62.5%. Remote grading of images of an eye at a single session had a sensitivity of 81.9% and a specificity of 90.1%.

F. Conclusions

There is level I evidence from at least 5 studies demonstrating that digital retinal photography has high accuracy for the detection of clinically significant ROP.⁷ Exceptions are 1 study that showed sensitivity of 77% for detection of type 2 or worse ROP, 1 study that showed sensitivity of 76% for type 2 or worse ROP at 31 to 33 weeks' PMA, and 1 study that showed sensitivity of 57% for detection of stage 3 disease. Of note, the largest of the level 1 studies¹¹

produced a sensitivity of 81.9% for referral-warranted ROP (zone I ROP, stage 3 ROP or worse, or plus disease) when the unit of measure was a grading session per eye, and a sensitivity of 90.0% with a specificity of 87.0% when both eyes of an infant were considered as a pair. When the last session before treatment was analyzed, sensitivity was 98.2% (95% CI: 94.4–99.4), with a specificity of 80.2% (95% CI: 77.0–83.0), a negative predictive value of 99.6%, and a positive predictive value of 44.3% at a 13.8% treatment-requiring ROP rate. Only 3 of 162 infants treated by clinical center ophthalmologists did not have referral-warranted ROP detected on the last image graded before treatment. On diagnostic examination, 1 infant had zone I, stage 3 disease in both eyes and another 2 infants had plus disease in both eyes.

Unfortunately, differences in methods do not permit direct comparison between studies *with respect to sensitivity and specificity*. Level III studies have reported high accuracy, without any known complications, from real-world operational programs intended to detect clinically significant ROP through remote site interpretation of wide-angle retinal photographs.

The accuracy of wide-angle photography for detection of mild levels of ROP, particularly in infants at younger PMAs, is less clear. For example, 1 study found that the sensitivity for detection of mild ROP among infants from 31 to 33 weeks' PMA by 3 expert graders was 73% to 94%, whereas the specificity was 89% to 94%. The reasons for this outcome may be that peripheral retinal findings are more difficult to visualize and that younger infants have smaller eyes with more media opacity, which creates difficulty for photography.

The panel's conclusion is that TM serves as a useful adjunct to but not a replacement of BIO.

Future Research

Further studies are needed to assess RDFI-TM ROP management programs and confirm that they adequately address issues of access to care, clinical efficacy, and cost-effectiveness. These investigations should address protocol and performance standards.

In 1999, Lee proposed a 4-tier framework⁴ for systematically evaluating TM, initially focusing on retinal imaging for diabetic retinopathy, which is a useful framework for ROP TM research. The first and most important concern is to define the purpose of any system against which to judge the success of TM approaches. Second, it is important to evaluate the system's performance against the appropriate criterion standard. Third, research should establish the validity of any new approaches from a technical perspective, including the accuracy rates (sensitivity, specificity, and positive and negative predictive values) for interpretation of the images, relative to the criterion standard. In addition, system technical standards (eg, image resolution, color depth, data compression, display resolution) need further evaluation. It is important that studies in ROP-TM specify the technical standards used to capture, process, and display the image to the reviewers; the criterion standard to compare the new approach; and the methods used for image capture and interpretation.

Finally, there is a need for systematic studies evaluating the implementation of ROP-TM to prospectively evaluate the benefits, costs, and tradeoffs of new approaches from various perspectives: patients, providers, payers, and policy makers. For example, RDFI may make it easier for NICUs to retain infants of higher systemic acuity for whom they are not prepared to provide an appropriate level of medical care,

with attendant impact on morbidity and mortality for infants at risk for ROP. Future research should also include studies to understand how clinical information can best be shared to help educate neonatologists, NICU staff, and patients' families. Infant well-being is the ultimate outcome measure.

IV. PRACTICAL CONSIDERATIONS

The following recommendations are based on the currently available evidence-based literature, as well as experience accumulated by using an RDFI-TM evaluation approach to the management of ROP.

A. Resource Requirements

RDFI for ROP requires the following components:

- A digital fundus camera system
- Image management software
- Trained personnel
- Internet access (see the following section entitled "Information Technology Considerations")
- An ophthalmologist experienced in the full range of manifestations of ROP

The only device currently used is the RetCam (Clarity Medical Systems, Inc) family of cameras. For ROP, the 130 diopter lens is preferred for wide-angle visualization of the fundus. The external lens is used for iris and anterior segment imaging. High-magnification imaging (optic nerve or macular pathology) is performed with either a 30 diopter or an 80 diopter lens. The RetCam Review Software allows for image-processing capability, including manipulation of contrast, brightness, and color saturation. The discussion that follows assumes reference to the RetCam, unless indicated otherwise.

B. Information Technology Considerations

Health information technology standards and regulations should be appropriately addressed when using

TM options to manage ROP. Patient confidentiality requirements and protected health information security regulations are defined in the Health Insurance Portability and Accountability Act of 1996 (HIPAA).²⁹

Digital imaging standards to facilitate and promote interoperability are defined in the Digital Imaging and Communications in Medicine Standard.³⁰ Specific information object definitions applicable for use in ROP-TM have been defined and successfully implemented. These standards facilitate the exchange of patient and clinical information between devices, picture archiving and communications systems, electronic health records (EHRs), and hospital information systems, as well as between different providers' information systems.

Standardized methods of capturing, storing, and transmitting patient demographic and insurance information are defined in the Health Level 7 and the American National Standards Institute X12 standard, including structured data used in electronic claims submission. Clinical data can be documented and captured by using structured clinical terminology, such as the ophthalmology subset of the Systematic Nomenclature of Medicine–Clinical Terms,³¹ facilitating comparability of data between different systems, especially EHR integration.

In the United States, the software controlling a medical device (eg, a retinal camera) may be considered an integral part of the device. If the device is marketed, it can be regulated by the US Food and Drug Administration, including compliance with current Good Manufacturing Process requirements. The Quality System Regulation is contained in Title 21, Part 820, of the Code of Federal Regulations.

To date, image compression has not been adequately evaluated and

validated for use in ROP-TM. If image compression is used, lossless compression should be selected because it allows full reconstruction of the original image data. Uncompressed image data or lossless compression should be used in ROP TM systems (in the case of the RetCam, bitmap images) until techniques involving loss of data (eg, JPEG-2000 images) can be clinically validated.

C. Core Components of an ROP RDFI-TM Evaluation Program

1. Personnel: The TM Team

The health care team behind the RDFI-TM evaluation of infants for ROP consists of ophthalmologists, neonatologists, NICU nurses assuming image acquisition responsibilities, the hospital, information technology personnel, and other caregivers. The ophthalmologist who will perform the bedside BIO, discharge evaluations, and laser procedure is an integral part of the system. The following sections of this core components discussion speak primarily to the other components of an ROP RDFI-TM evaluation program.

The team concept is particularly important in an ROP TM system because the ophthalmologist may no longer act as the on-site face of the evaluation program, or if he or she is, may not be present as frequently. Those who acquire the images (NICU nurses or other trained personnel) are the front line of the evaluation program.

Nonphysician graders were used within the confines of the recent e-ROP clinical trial.¹¹ However, the variability in ROP image grading among even experienced physicians is widely recognized.⁷ In the absence of a formally recognized certification process and oversight construct, uniform training, licensing, and liability considerations preclude the routine use of nonphysician graders at this time.

The hospital's information technology department should be brought in early to facilitate image download/transfer, ensure that the process is compliant with the HIPAA privacy rule³² and hospital rules for the safety of electrical devices, and, wherever possible, to integrate the RDFI system and the data and images produced into the hospital's EHR system.

2. Definition of Roles

A detailed document, preferably in the form of a contract, detailing pertinent duties and responsibilities of all members of the team is critical to the effective execution of RDFI-TM evaluation for ROP management and should be developed within each institution. Protocols should clearly delineate workflow and roles/responsibilities, contain a quality assurance component to detect and correct system failures, and delineate a structured approach to managing "outliers." Outliers include infants with images inadequate for interpretation, patients with clinical fundus findings other than ROP, urgent cases, and infants with atypical findings.

3. Training

Nurse team members and other interested NICU nurses should be trained in RDFI-TM techniques by a certified ophthalmic photographer or someone else familiar with fundus photography in general and the camera/information system to be used in particular. Camera manufacturers offer online training courses.³³ Systematic evaluation/oversight by the ophthalmologist is necessary to provide insight regarding the fine points of imaging and image management. No program currently exists to certify physicians or nonphysicians for ROP diagnosis and management, whether by BIO or interpretation of RDFIs.

Training is particularly important for those personnel who will be responsible for taking the

photographs in the technique necessary to achieve a set of photographs that can be correctly interpreted. A case report in the ophthalmology literature³⁴ clearly illustrates this point: a photograph showing only immature vascularization in zone I was followed by a second photograph of the same field taken 10 minutes later, which showed stage 3 disease present in zone I. The authors hypothesized that the difference in results was attributable to the application of excessive pressure on the photographic contact device when the first photograph was taken. It is suggested that the ophthalmologist who will be performing the BIO examinations within each NICU monitor the progress of the photographic training by carefully comparing the results of the photographs obtained during training with his or her examination results, thus validating these findings. The trainee should not be considered competent in this technique until complete agreement is achieved between the photographs taken by the trainee and those taken by the BIO examiner.

4. Imaging

a. Dilation

The eyes should be well dilated before imaging, which is particularly important in darkly pigmented children. Dilation protocols vary widely, but commonly used regimens include phenylephrine 2.5% and tropicamide 1% to each eye, repeated in 5 minutes, or Cyclomydril (a combination of cyclopentolate 0.2% and phenylephrine 1%; Alcon Laboratories, Fort Worth, TX), 1 drop to each eye, repeated in 5 minutes.

b. Infant Monitoring

Infants should be closely monitored for bradycardia, apnea, and tachycardia after dilation and during the imaging process. There is no evidence to suggest that TM examination is harmful to the infant

or more stressful than BIO.³⁵ Some evidence suggests that it may be less stressful,³⁶ but BIO frequently produces bradycardia and other cardiovascular changes, and contact photography may do the same.

c. Preparing the Eye for Imaging

A drop of topical anesthetic is applied to each eye. A wire speculum (Alfonso or pediatric Barraquer) is used to open the eyelids. Because the RetCam is a corneal contact camera, a methylcellulose coupling agent is applied to the cornea or lens surface.

d. Imaging Protocol

i. Scheduling

Digital fundus imaging should be performed on all infants at risk for ROP damage, as outlined in the joint statement on ROP from the American Academy of Pediatrics (AAP), the American Association for Pediatric Ophthalmology and Strabismus (AAPOS), and the American Academy of Ophthalmology (AAO).³⁷ This imaging should be conducted on a dedicated day once weekly or more frequently if specifically indicated. This timing allows for continuous monitoring of longitudinal changes and limits the possibility that a child will inadvertently be dropped from the evaluation rotation. Morning scheduling of imaging sessions allows problems in image acquisition/transfer to be addressed before any change of shift. In addition, confirmatory BIO examination by the ophthalmologist responsible for oversight of ROP screening can be performed the same day, if warranted.

ii. Image Set and Sequence

Six standard images (shown for a right eye in Fig 1) of each eye are recommended.⁶ After dilation, the iris is imaged first to document the extent of dilation. This image is useful in determining whether poor image quality is due to poor dilation or photographer skill/technique. Once the right eye is imaged, the left eye is imaged as well.

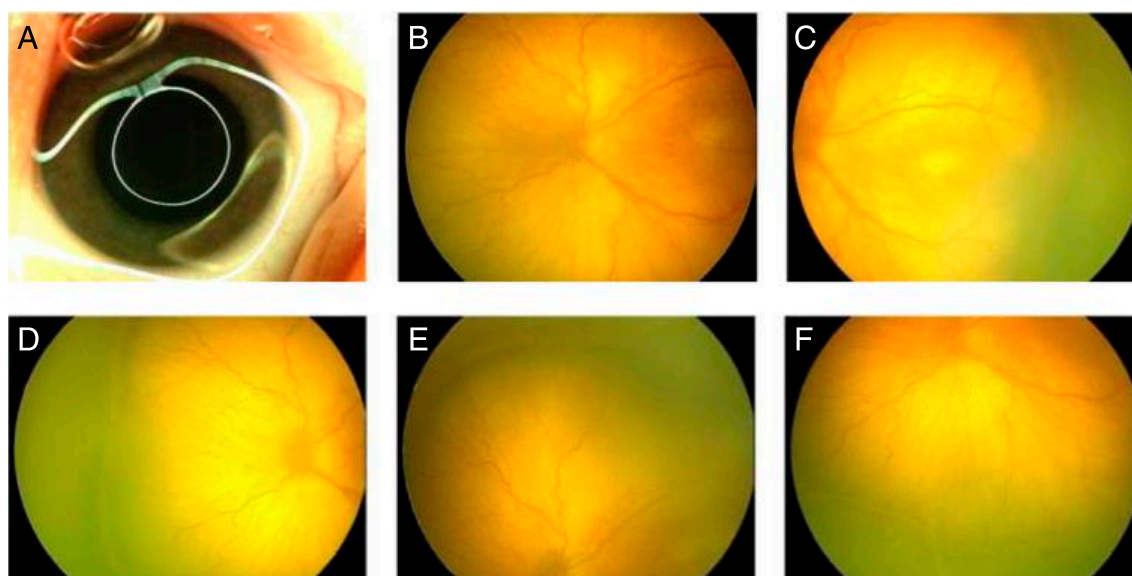


FIGURE 1
ROP standard image set (right eye). A, Right anterior segment-iris; B, right disk; C, right fundus temporal (right); D, right fundus nasal; E, right fundus superior; and F, right fundus inferior.

The image sequence for a complete image set of both eyes is listed in Table 2. Additional images may be acquired, as needed, to encompass all 12 clock-hours of the peripheral fundus. This image sequence should be identical for all visits. Failure to achieve this standard image set may trigger unnecessary repeat fundus imaging or bedside examination.

iii. Image Quality

Images should be of sufficient quality that the interpreting physician could safely determine whether each infant requires BIO or treatment.

iv. Physician Notification

Image transfer should be accompanied by notification (eg, e-mail, fax, telephone call) to the interpreting physician that the images have been sent, with confirmation

of receipt by that ophthalmologist. Failure to receive a report or receipt notification from the interpreting physician within 24 hours should trigger automatic contact by the NICU to investigate whether image transfer was successful and initiate re-transmittal if necessary.

5. Equipment Maintenance

After each patient undergoes imaging, the lens surface is cleaned with an alcohol swab and allowed to air dry before a subsequent examination. To maximize the working life of the light source, the camera should be shut down if not in use for extended periods of time. Software updates from the manufacturer should be installed promptly, and a maintenance contract is recommended. The camera should be checked regularly by the

bioengineering department of the hospital for electrical safety according to each hospital's usual schedule for medical devices.

6. Information Management

a. Data Transmission

i. Network Architecture

The basic framework of the RDFI-TM network is a hub-and-spoke model. The centralized reading center and physician graders are the hub, and each NICU serviced is a spoke. Images are captured locally; transferred via thumb drive, DVD, or hospital-secure intranet to an Internet-based computer, and then sent in a HIPAA-compliant fashion (eg, secure file transfer protocol, secure e-mail, virtual private network) to the reading center. Images are downloaded onto a secure server or a local reading station at the reading center for evaluation and management by the ophthalmologist.

ii. Bandwidth

A set of 12 RetCam images is approximately 10 megabytes. Broadband access (eg, T1 line, cable modem, digital subscriber line) provides a practical means for rapid image transfer.

TABLE 2 ROP-TM Image Sequence

| Image Number | Image Object | Image Number | Image Object |
|--------------|------------------------------|--------------|-----------------------------|
| 1 | Right anterior segment, iris | 7 | Left anterior segment, iris |
| 2 | Right disc | 8 | Left disc |
| 3 | Right fundus, temporal | 9 | Left fundus, temporal |
| 4 | Right fundus, nasal | 10 | Left fundus, nasal |
| 5 | Right fundus, superior | 11 | Left fundus, superior |
| 6 | Right fundus, inferior | 12 | Left fundus, inferior |

iii. Transfer Redundancy

In the event of computer or network failure, an alternative means of transferring the images, such as a commercial courier or delivery service, is necessary. Transfer computer redundancy is desirable.

b. Data Storage, Archives, and Backup

There are no uniform recommendations on how long to store images. Therefore, conservative recommendations are in order. Most states confer medicolegal liability until the infant reaches the age of majority (generally, 18 years of age) plus 1 year. Images should be archived and stored in such a manner that their preservation is guaranteed for at least that long. This task is best assigned to the hospital's information technology team to be performed in concert with their storage of other hospital data.

c. Backup

The hospital information technology team and reading center should each arrange to have their own respective scheduled, automated, off-site, redundant, HIPAA-compliant backup of all data.

d. Security

It is advisable to involve information technology from both the reading center and the NICU/hospital system to address respective HIPAA responsibilities relating to electronic medical information transfer. During image transfer, the onus is on the NICU to remain HIPAA compliant. The burden of HIPAA compliance rests with the reading center for report transfer back to the NICU.

The reading center should maintain both the fidelity and security of the data. This goal can be achieved through firewalls and password-protected access. Security cost is usually bundled into the storage/archival/backup fees.

7. Image Transfer and Interpretation

Secure e-mail is the preferred method of transfer for both images and

reports. The advantage of secure e-mail is that it creates an electronic trail, which can serve as an important component of the ROP safety net (discussed later).

a. Image Transfer Protocol (NICU/Hospital to Reading Center)

Once images are transferred to the reading center, the images should be acknowledged (via e-mail/fax/telephone or some combination [which is to be stipulated by the protocol in advance]) on receipt; if not, the assumption will be that the report was not received. The physician responsible for image interpretation should be notified (via e-mail/fax/telephone or some combination [which is to be stipulated by the protocol in advance]) that images are available for review.

b. Interpretation Report Transfer (Reading Center to NICU/Hospital)

A triage preliminary review of the images should be made as soon as possible after they are received at the reading center to determine whether emergent ophthalmoscopic evaluation and possible treatment is necessary (ie, if threshold ROP could be present on the images). In addition, images that are not of sufficient clarity and quality, or if they are incomplete image sets, should trigger an immediate call to the sending institution to immediately repeat the photographic session. A definitive report should be transmitted in all cases to the NICU within 24 hours. The reports should be acknowledged and documented immediately on receipt, or the assumption will be that the report was not received. If, for whatever reason, the physician grader is unable to review the images within the specified time, it is incumbent on the physician grader to inform the reading center to arrange for an alternative physician grader to ensure adherence to a turnaround interval for interpretation reports of 24 hours or less.

c. Report Components

Standard RDTI-TM reports should include the following components.

i. General Information

- Patient name
- Medical record number
- Date of examination
- Date/time images were received, interpreted, and the report transmitted
- Date of birth
- Birth weight
- Gestational age at birth
- PMA at examination
- Weight at examination
- Medical history/active problem list
- Institution originating the photos and its location

ii. Interpretation

The "Interpretation" section should include the following information:

- The eye(s) for which images are provided
- The number of images provided per eye
- Interpretation of the anterior segment image regarding:
 - Image quality
 - Dilation adequate for imaging
 - Corneal clarity
 - Presence/activity of iris vasculature
- Interpretation of fundus images regarding:
 - Image quality
 - Media clarity
 - Optic nerve status
 - Fovea/foveal reflex
 - Presence/absence of pre-plus or plus disease
 - Zone of imaged/visualized retina
 - Zone of vascularized retina
 - Stage and extent of ROP, if present
 - Other findings (eg, hemorrhage, double demarcation line, masses)

Serial images should be reviewed to relate the findings to those of previous examinations for interval changes.

iii. Impressions

An “Impressions” section should include:

- Summary comment regarding image number, quality, and adequacy for interpretation
- Summary of ROP findings in the traditional lowest zone/highest stage format
- Status compared with previous examinations
- The presence of any non-ROP ocular pathology

iv. Recommendations

A “Recommendations” section should address:

- Whether reimaging is necessary in the event of poor/inadequate image quality
- The timing of follow-up imaging per current AAP/AAPOS/AAO guidelines³⁷
- Whether bedside examination is in order
- Appropriate follow-up for any non-ROP ocular pathology

v. Second Opinions

- A strength of the TM approach is the ability to easily obtain expertise for consultation when interpretation is in doubt.
- Readers should maintain a list of more experienced clinicians to consult as-needed for challenging cases.

d. Outlier Management

i. Inadequate Images

Repeat examination within 24 hours is indicated for incomplete image sets; images characterized by poor focus, contrast, or exposure; and those mislabeled with regard to patient and/or eye are inadequate for interpretation. If a NICU is providing consistently inadequate images, it may be necessary to schedule a repeat training session or replace

personnel or equipment. If images cannot effectively be obtained for a child, urgent BIO is indicated to rule out the possibility that the inadequate images are a consequence of ROP (eg, poor dilation attributable to vascular congestion of the iris), as opposed to operator error.

Infants for whom images adequate for remote management cannot be obtained (eg, consistent poor dilation, very dark fundus, media opacity) require BIO within examination guidelines timing of that examination.

ii. Non-ROP Findings

A. Incidental Findings

If the physician grader notes an incidental, non-ROP ocular abnormality during the course of image interpretation (eg, optic nerve coloboma), the finding is added to the “Impressions” section of the report. A specific comment in the “Recommendations” (eg, consult pediatric ophthalmology within 24 hours) is also included. All verbal communication on an infant’s behalf should be documented as to person contacted, topic, date, time, and resolution. On subsequent examinations, the notation should include updates from the other physician in the “Impressions” and “Recommendations” sections.

B. Request to Evaluate for Non-ROP Fundus Pathology

Occasionally, the NICU physician may send images of a child not at risk for ROP, requesting that the physician grader evaluate for some other phenomenon (eg, infant with candidemia to rule out fungal retinitis). RDFI-TM evaluations have not been rigorously evaluated for such an indication, and a nonphysician grader would not have the expertise to address such queries. In view of this situation, the physician grader could evaluate the images, generate a report recommending BIO within 24 hours by a pediatric ophthalmologist or retinologist, and contact the NICU

staff to reiterate that TM is currently reserved for ROP.

iii. Urgent Cases

A physician reader should be designated as “on call” for the rare circumstance of an infant who must be imaged emergently; that is, for an infant who must be photographically screened before his or her scheduled time. This scenario would include, for example, an infant who is being transferred or discharged sooner than anticipated and who has a scheduled imaging session that cannot be completed at the scheduled time.

e. Termination Criteria

The termination of examination criteria outlined in the AAP/AAPOS/AAO guidelines³⁷ cannot be determined by using RetCam at this time. These criteria include the following findings (Table 3):

- Zone III retinal vascularization attained without previous zone I or II ROP
- Full retinal vascularization
- PMA of 45 weeks and no pre-threshold disease
- Regression of ROP

It is this panel’s recommendation that hospitalized infants undergo BIO to determine the suitability for termination of acute phase evaluation for ROP before discharge from the NICU or within 72 hours of the last RDFI examination, whichever is earlier. If an infant is discharged before meeting termination criteria, the NICU should arrange for outpatient follow-up examinations by a qualified ophthalmologist within a period of time necessary to meet ROP examination guideline requirements (see section IV-9-f. “Risk Management Considerations”).

8. Human Resources

a. Training and Certification

i. Photographers

Training NICU nurses in TM techniques of photography was discussed in section C-3.

TABLE 3 Summary Flowchart for RDFI

| Step | Technical | Personnel | Data | Technical Training Needed |
|---------------------------------------------------------------------|--------------------------------------------------------------|---------------------------------------------------------------------------|-----------------------------------------------------------------------------------------|---------------------------------------------|
| 1. Premature infant to be imaged identified per NICU protocol | Log or computer log | NICU physician and staff | Birth weight + gestational age per protocol; other factors at NICU physician discretion | Not applicable |
| 2. Date of first screening exam established | Log or computer log, protocol | NICU physician and staff | Based on gestational age per NICU protocol, AAP/AAPOS/AAO guidelines | Not applicable |
| 3. RDFI-TM system used | RetCam 120+ improved ROP lens | NICU staff | 6 standard images/eye acquired | Correct image acquisition |
| 4. Image transfer to remote center from NICU | Secure file transfer | NICU staff sends file; remote center staff receives and acknowledges file | Includes 6 standard images/eye + general info | Use of secure information transfer system |
| 5. Remote physician grader notification | Secure e-mail | NICU staff | Secure e-mail | Use of secure information transfer system |
| 6. Confirm receipt of notification | Secure e-mail | Remote physician grader | Secure e-mail | Use of secure information transfer system |
| 7. Image interpretation | Digital interpretation template, computer + imaging software | Remote physician grader | Current diagnostic and recommendation protocol, AAP/AAPOS/AAO guidelines | Supervised apprenticeship then independence |
| 8. Report generation | Digital report template | Remote physician grader | Includes general info + Interpretation | Use of secure information transfer system |
| 9. Report transfer | Secure e-mail | Remote physician grader | Secure e-mail | Use of secure information transfer system |
| 10. Confirm receipt of interpretation | Secure e-mail | NICU staff | Secure e-mail | Use of secure information transfer system |
| 11. Notify NICU physician and family of report findings | Not applicable | NICU staff | Digital report | Not applicable |
| 12. Determine when next examination needed or whether BIO is needed | Not applicable | NICU physician | NICU protocol, AAP/AAPOS/AAO guidelines | Not applicable |

After completion of these steps, subsequent examination is performed per recommendations by the remote physician grader based on the standards published by the AAP/AAPOS/AAO.³⁷ Photos should be taken and transmitted at the same time each week, wherever practicable. Earlier examination or BIO examination are scheduled as needed, on the basis of recommendations of the remote physician grader. If repeat examination is indicated, the sequence should be repeated beginning at step number 3.

ii. Physician Graders (Readers)

Even for experienced ROP screeners, evaluation of digital fundus images has a steep learning curve. New physician graders should spend a few sessions being mentored by a physician grader experienced in TM to become familiar with image quality issues, variability among imagers, report generation, and the technical aspects of receiving images and sending reports. It should be noted that there is no certification program for physician graders.

b. Alternate Physician Graders and On-Call Coverage Continuous Quality Monitoring

No one individual can guarantee universal availability. Backup or alternate experienced physician graders should be designated to

assist with scheduled coverage responsibilities.

c. Continuous Quality Monitoring

Although the photographers are the face of the evaluation program, the telemedical physician grader is the point person. Ongoing interaction by that physician grader with the NICU physicians, the nursing staff, the ROP coordinator, risk management, and hospital administration promotes commitment to the program and its goals of blindness prevention. This interaction should include semiannual assessment of the number of infants monitored, total number of examinations, procedures (anti-vascular endothelial growth factor injection, peripheral retinal ablation, and vitrectomy) performed, and adverse events.

d. Communication

i. Engaging NICU Staff (Neonatologists and NICU Nurses)

The onus is on the physician grader to keep NICU personnel updated on recent advances in understanding ROP pathophysiology and treatment. Changes in patient status are reported as described in section IV-C-7-c.

ii. Patient Family Education

The involvement and responsibilities of caregivers are addressed in detail in the section entitled "The 'ROP Safety Net' Paradigm." The use of RDFI should be integrated into patient parent education, and the availability of their child's retinal pathologic history should be a great help to that program.

The Ophthalmic Mutual Insurance Company (formed by the AAO in

1987 as a professional liability carrier exclusively for ophthalmologists) is an excellent resource for forms and educational material. On its Web site is a form³⁸ intended for the family. This form requires the patient's caregivers to have a family member sign, acknowledging that this member has been informed of the disease severity and that further evaluations are needed. This form can be easily modified for TM evaluation of ROP and sent along with each report for the NICU nurses/physicians to discuss with the family. Telephone or in-person conferences can be arranged if the family desires.

V. RISK MANAGEMENT CONSIDERATIONS FOR RDFI WITH TM FOR ROP

A. Professional Liability Risk

In any medical malpractice lawsuit, the plaintiff (the former patient, usually through a guardian *ad litem*), must prove that the defendant (eg, the ophthalmologist, neonatologist, nurse, hospital) had a duty to care for the patient, was negligent in providing that care (ie, did not meet the standard of care, customarily defined as the care provided by a reasonably prudent physician), and caused harm to the plaintiff as a result. To our knowledge, there has not yet been a lawsuit related to ROP in which the patient was screened by using RDFI-TM. The risks related to TM in situations other than ROP screening and the risks of BIO screening have been tested in many cases, however.

B. Duty

Once a physician-patient relationship is established, physicians owe a duty of ongoing care until the relationship is terminated by one of the parties. Physicians establish relationships with patients in many ways, including by accepting requests for office appointments, providing advice about patients to emergency department physicians, and examining a patient in the hospital. Depending on the

circumstances, courts may or may not recognize the establishment of a relationship through various patient-physician contacts.

Hospitals with NICUs generally have standing agreements with an ophthalmologist to provide ROP screening and/or treatment, and most ophthalmologists screen for ROP on a set day each week (eg, each Tuesday). Using agreed-on clinical guidelines, the neonatologist identifies which infants require screening. Typically, the NICU notifies the ophthalmologist by putting the infant's name on a list of infants to be screened that particular day. The ophthalmologist performs the examination; indicates the follow-up interval in a manner readily received and understood by the relevant NICU personnel, including (but not limited to) neonatologists, staff nurses, and clerks assigned to handle these appointments; and relies on the NICU to ensure that the infant's name again appears on the list on the correct day. The ophthalmologist continues to examine the infant in the hospital until screening/treatment is no longer required or care has been transferred to another ophthalmologist. Depending on the agreement with the hospital, the ophthalmologist may continue to provide care in his or her office and/or in the other hospital.

In the RDFI model for care proposed within the present report, the remote screening ophthalmologist is responsible for the patient after either receipt of the photographs or by the request to examine the infant, whichever comes first. The responsibility would possibly continue until the infant no longer needs screening or treatment or until the ophthalmic care has been transferred to another ophthalmologist. It is less clear when the duty ends, and there are no lawsuits related to interpretation of fundus photos to guide this risk analysis. At times, courts look to what

expectations a "reasonable patient" might have, and those expectations are linked to the characteristics of the condition for which the patient is seeking treatment.

If the ophthalmologist who interprets the photos does so as part of an agreement to provide ROP care to a certain facility or on a regular basis, he or she would most likely be expected to follow up and track the infant until the end of screening or treatment, just as he or she would do for any other patient with ROP. At this stage of implementation of RDFI screening for ROP, this procedure is the predominant model.

The other end of the spectrum of duty is an ophthalmologist who is asked to give a second opinion but who has not agreed to care for a patient for a particular condition or course. For ROP-TM screening, this physician would complete the "second opinion" obligation by interpreting the photo and sending the report. This time-limited consultation model is the expectation for ophthalmologists who interpret fundus photos to screen for diabetic retinopathy. Diabetic retinopathy takes years to develop and progresses differently in each patient depending on a number of factors. Ophthalmologists screening for diabetic retinopathy may not be asked to review a photo ever again or perhaps not for another year. There would, therefore, be no expectation of the screening ophthalmologist to follow up such a patient to try to ensure that the next screening takes place, unless he or she was also the treating physician.

The obligation of an ophthalmologist who interprets photos for a reading center but provides no ROP care at the hospital is less clear-cut. One might argue that this relationship also ends once the report has been sent. There are aspects to ROP that could provide arguments against such a straightforward interpretation of duty, however. The natural history of ROP is well known and relatively

predictable: it is an acute disease that progresses over a short period of time and can lead, without treatment, to permanent bilateral blindness. Courts may find that an ophthalmologist who agrees to interpret ROP photos has agreed to care for the infant during this at-risk period and, thus, has a duty to attempt to ensure that the photos are taken at the appropriate intervals during that time. From a risk management perspective, it would be prudent for interpreting ophthalmologists to review the process of care with the referring facility or physician and to clarify who is tracking the infant until the acute screening and treatment are completed. To protect themselves and the infants, ophthalmologists who provide ROP-TM care would be well advised to create a safety net by maintaining their own tracking system, as this follow-up aspect of care has proved to be risky. Materials to do so are suggested in the section entitled "The 'ROP Safety Net' Paradigm." Technically, the ophthalmologist performing the photo-interpretation under this RDFI-TM model would possibly assume that same duty of care as formerly was assumed by the ophthalmologist performing the BIO examination.

In addition to the duty to provide ongoing care during the duration of the physician-patient relationship, physicians may be required to be responsible for following up with patients who do not return for care as scheduled or do not adhere to recommended treatment. This "follow-up" obligation has proved to be a risky one for ophthalmologists who provide ROP care. Traditionally, the neonatologist and NICU have assumed the responsibility for tracking ROP infants until completion of ROP screening/treatment or discharge and for arranging for ROP care after discharge or on transfer. Problems occur because infants are discharged before the follow-up date, are undergoing surgical procedures, are too ill, or have been transferred to

other facilities at the time of the ophthalmologist's visit. Many times, the ophthalmologists who comprise the ROP screening and treating panel are not notified of the location and status of the infant. It is often the ophthalmologist, however, who becomes the primary target of a lawsuit when ROP-screening protocols break down and an infant loses his or her sight. To protect themselves and their patients, therefore, ophthalmologists are urged to maintain their own tracking system. More information on how to develop this "safety net" is suggested in section VI.

C. Pitfalls in Continuing Care

As in any suit for ROP care, allegations of negligence could include failure to diagnose, treat, and follow up. If no arrangements are made for another ophthalmologist with comparable skills to interpret photos during a planned absence and the infant does not receive the needed screening or treatment, the ophthalmologist could be sued for abandonment. TM has its own known unique risks; the ophthalmologist could also face allegations of negligent supervision of NICU nurses if he or she has responsibility for training and overseeing RDFI-TM ROP care. Other diagnostic allegations related to RDFI-TM could include negligent interpretation of photos (failure to detect technically inadequate photos and failure to recognize referral-warranted ROP) or failure to perform a timely BIO examination or any BIO examination. Given the practicability of ophthalmologists sending photos to another ophthalmologist for advice, plaintiff attorneys may also frequently allege failure to consult. Professional liability insurance policies would normally cover these exposures, provided that RDFI-TM is included within the provisions of the policy or is at least not excluded.

Because physicians must be licensed in the state where care is provided, those practicing TM could face claims

for practicing medicine without a license if the ophthalmologist was not licensed in the states where photos were both taken and interpreted. Physicians who evaluate fundus photographs and provide an interpretation and follow-up recommendations are engaged in the practice of medicine. All states require that physicians have a license issued by the state to practice medicine. Practicing without the appropriate license not only complicates the defense of medical malpractice lawsuits but may also lead to fines and disciplinary action. Ophthalmologists engaged in TM activities that cross state lines should contact the medical board in the state(s) where their practice is physically located as well as each state in which patients present for diagnosis, imaging, or other services, to confirm that they are in compliance with all pertinent laws and regulations. Some states require the physician to obtain full and unrestricted licensure in the state in which the patient presents. Other states issue special licenses to out-of-state practitioners for practicing TM in their state. Still others may permit certain intraspecialty consultations from an out-of-state specialist without requiring in-state licensure but require in-state licensure if a diagnosis is issued. It is the responsibility of the physician grader to ensure that he or she is licensed appropriately at both the transmitting and receiving sites. In addition to a medical license, some states have laws and regulations specific to TM; these statutes address issues such as consent and privacy.

D. Competency and Credentialing

As noted previously, ophthalmologists who provide ROP care "should have sufficient knowledge and experience to enable accurate identification of the location and sequential retinal changes of ROP after pupillary dilation using binocular indirect ophthalmoscopy."³⁷ Those

ophthalmologists participating in TM screening for ROP should have additional knowledge and expertise in reading RDFI. If in doubt about how to interpret photos, they should consider asking more experienced readers for second opinions. These discussions should be documented in writing.

There is no formal mechanism to verify competency in ROP screening, whether by BIO or TM. To promote competency and defensibility, ophthalmologists are encouraged to stay current with ROP research and keep records of verification of fellowship training and mentoring, certificates from continuing medical education courses, and articles on ROP diagnosis and treatment.

E. Consent for TM

TM has been practiced in radiology, pathology, dermatology, and adult ophthalmology for some time. When it consists of “store and forward” technology to review images or slides with no direct patient involvement in a real-time consultation, state law may not require the physician to obtain the patient’s informed consent. Because use of this technology is relatively new in ROP care, it would be prudent, nonetheless, to obtain the consent of the infant’s parents or caregivers, regardless of whether state law requires it. The Telemedicine Information Exchange provides information on how to start a TM program and specific information on state law (<http://tie.telemed.org/professional/state.asp>). The American Telemedicine Association provides sample consent forms on its Web site (www.atmeda.org).

F. Need for BIO Before Discharge

As noted earlier, RetCam images do not allow screeners to confirm that the 3 criteria for termination of the acute phase of screening for ROP³⁷ have been met (see section B-iv) because of the inability of current cameras to image the retinal periphery adequately. A BIO

examination must be conducted to verify that the infant has met the current clinical criteria to end screening, as noted in the ROP examination guidelines. The protocol discusses performing the BIO either before discharge or within 72 hours of the discharge from the NICU or the last RDFI examination, whichever is earlier. It assigns the neonatologist/NICU the responsibility for scheduling the initial outpatient ophthalmologic evaluation.

An analysis of ROP malpractice lawsuits found that discharge is the riskiest moment in the process of care because patients are more likely to be lost to follow-up shortly after hospital discharge when their ROP is still active. In addition, their parents have just been introduced to the stresses of caring for the relatively fragile premature infant in the outpatient setting, and parents/caregivers thus cannot be relied on to keep appointments (see “The ‘ROP Safety Net’ Paradigm” in section VI). From a risk management perspective, therefore, it would be prudent to perform the BIO examination before discharge. This step provides that patients needing additional examination or treatment can obtain it in a timely manner.

G. Outcomes

In any RDFI-TM program established, careful consideration should be given to the inclusion of a protocol for tracking infants having undergone photo screening for ROP and determining long-term visual and ocular structural outcomes. This program should be consistent with and integrated with existing programs in use for tracking infants at risk for ROP who have been screened using BIO.

VI. THE “ROP SAFETY NET” PARADIGM

Information is provided in the following links from the Ophthalmic Mutual Insurance Company regarding responsibility for each task in the

ROP care process, both in the hospital (or other health care facility) and during outpatient care:

- ROP: Creating a Safety Net (2nd Edition) http://www.omic.com/resources/risk_man/recommendDocs/ROP_Safety_Net_2nd_Ed_111610.rtf and <http://www.omic.com/rop-creating-a-safety-net/>
- ROP: Materials for Creating a Hospital Safety Net http://www.omic.com/resources/risk_man/recommendDocs/ROP_Hospital_toolkit_101010.rtf and <http://www.omic.com/rop-creating-a-safety-net/>
- Materials for Creating an Office Safety Net http://www.omic.com/resources/risk_man/recommendDocs/ROP_office_toolkit_101010.rtf

VII. SUMMARY

The development of an RDFI-TM approach has the potential to expand the evaluation and management options available for ROP surveillance. The general consensus of the literature and this panel is that RDFI-TM does not supplant BIO for ROP evaluation. However, evidence of moderate (levels II and III) quality supports the use of RDFI to identify patients with clinically significant or referral-warranted ROP for ophthalmic evaluation and management.

Advantages of an RDFI-TM approach include the potential to integrate it into contemporary EHR initiatives, objectively assess the quality of evaluations, increase the number of infants evaluated, fortify the “ROP safety net” construct of disease surveillance, improve parent and staff education about ROP, and make more widely available the experience of ROP experts. Disadvantages include cost, the fact that RDFI-TM collects considerably less information than required to fully stage the extent of ROP on the basis of the International Classification of Retinopathy of Prematurity consensus statement, and current practical knowledge gaps.

Further analyses are required to confirm the clinical and cost-effectiveness of RDFI-TM for ROP. Future research should also include standardization/validation of protocols and satisfactory performance standards for ROP evaluation programs.

LEAD AUTHORS

Walter M. Fierson, MD, FAAP
Antonio Capone, Jr, MD

EXECUTIVE COMMITTEE – AMERICAN ACADEMY OF PEDIATRICS, SECTION ON OPHTHALMOLOGY, 2013–2014

David B. Granet, MD, FAAP, Chairperson
Richard J. Blocker, MD, FAAP
Geoffrey E. Bradford, MD, FAAP
George S. Ellis, Jr, MD, FAAP – *Section Historian*
Sharon S. Lehman, MD, FAAP
Steven E. Rubin, MD, FAAP
R. Michael Siatkowski, MD, FAAP
James B. Ruben, MD, FAAP, Immediate Past Chairperson

LIAISONS

Kyle A. Arnoldi, CO – *American Association of Certified Orthoptists*
George S. Ellis, Jr, MD, FAAP – *American Academy of Ophthalmology Council*

STAFF

Jennifer G. Riefe, MED

AMERICAN ACADEMY OF OPHTHALMOLOGY AMERICAN ASSOCIATION OF CERTIFIED ORTHOPTISTS

ACKNOWLEDGMENTS

The authors acknowledge the great assistance of the members of the AAO ROP Telemedicine Task Force who contributed materially to this document. They include: William Good, MD, Co-Chair; David Coats, MD; Edward Donovan, MD; Lloyd Hildebrand, MD, PhD; Anne Menke, RN, PhD; and Darius Moshfeghi, MD. Flora Lum, MD, of the AAO, also made significant contributions to the development of the manuscript.

REFERENCES

- Steinkuller PG, Du L, Gilbert C, Foster A, Collins ML, Coats DK. Childhood blindness. *J AAPOS*. 1999;3(1):26–32
- Good WV; Early Treatment for Retinopathy of Prematurity Cooperative Group. Final results of the Early Treatment for Retinopathy of Prematurity (ETROP) randomized trial. *Trans Am Ophthalmol Soc*. 2004;102:233–248, discussion 248–250
- Menke AM. *Retinopathy of Prematurity: Creating a Safety Net*. San Francisco, CA: Ophthalmic Mutual Insurance Company; 2006
- Lee P. Telemedicine: opportunities and challenges for the remote care of diabetic retinopathy. *Arch Ophthalmol*. 1999;117(12):1639–1640
- Ells AL, Holmes JM, Astle WF, et al. Telemedicine approach to screening for severe retinopathy of prematurity: a pilot study. *Ophthalmology*. 2003; 110(11):2113–2117
- Balasubramanian M, Capone A Jr, Hartnett ME, Pignatto S, Trese MT; Photographic Screening for Retinopathy of Prematurity (Photo-ROP) Cooperative Group. The Photographic Screening for Retinopathy of Prematurity Study (Photo-ROP): study design and baseline characteristics of enrolled patients. *Retina*. 2006;26(7 suppl):S4–S10
- Chiang MF, Keenan JD, Starren J, et al. Accuracy and reliability of remote retinopathy of prematurity diagnosis. *Arch Ophthalmol*. 2006;124(3):322–327
- Wu C, Petersen RA, VanderVeen DK. RetCam imaging for retinopathy of prematurity screening. *J AAPOS*. 2006; 10(2):107–111
- Silva RA, Murakami Y, Jain A, Gandhi J, Lad EM, Moshfeghi DM. Stanford University Network for Diagnosis of Retinopathy of Prematurity (SUNDRP): 18-month experience with telemedicine screening. *Graefes Arch Clin Exp Ophthalmol*. 2009;247(1):129–136
- Photographic Screening for Retinopathy of Prematurity (Photo-ROP) Cooperative Group. The photographic screening for retinopathy of prematurity study (photo-ROP). Primary outcomes. *Retina*. 2008;28 (suppl 3):S47–S54
- Quinn GE, Ying GS, Daniel E, et al. e-ROP Cooperative Group. Validity of a telemedicine system for the evaluation of acute-phase retinopathy of prematurity. *JAMA Ophthalmol*. 2014;132(10):1178–1184
- Diabetic Retinopathy Study. Report 7. A modification of the Airlie House classification of diabetic retinopathy. *Invest Ophthalmol Vis Sci*. 1981;21(1 Pt 2):210–226
- Early Treatment Diabetic Retinopathy Study Research Group. Grading diabetic retinopathy from stereoscopic color fundus photographs—an extension of the modified Airlie House classification. ETDRS report number 10. *Ophthalmology*. 1991;98(5 Suppl): 786–806
- Conlin PR, Fisch BM, Orcutt JC, Hetrick BJ, Darkins AW. Framework for a national teleretinal imaging program to screen for diabetic retinopathy in Veterans Health Administration patients. *J Rehabil Res Dev*. 2006;43(6):741–748
- Fransen SR, Leonard-Martin TC, Feuer WJ, Hildebrand PL; Inoveon Health Research Group. Clinical evaluation of patients with diabetic retinopathy: accuracy of the Inoveon diabetic retinopathy-3DT system. *Ophthalmology*. 2002;109(3):595–601
- Zimmer-Galler I, Zeimer R. Results of implementation of the DigiScope for diabetic retinopathy assessment in the primary care environment. *Telemed J E Health*. 2006;12(2):89–98
- Wallace DK, Quinn GE, Freedman SF, Chiang MF. Agreement among pediatric ophthalmologists in diagnosing plus and pre-plus disease in retinopathy of prematurity. *J AAPOS*. 2008;12(4):352–356
- Kemper AR, Wallace DK, Quinn GE. Systematic review of digital imaging screening strategies for retinopathy of prematurity. *Pediatrics*. 2008;122(4): 825–830
- Field M. *Telemedicine: A Guide to Assessing Telecommunications in Health Care*. Washington, DC: National Academies Press; 1996
- Chiang MF, Melia M, Buffenn AN, et al. Detection of clinically significant retinopathy of prematurity using wide-angle digital retinal photography: a report by the American Academy of Ophthalmology. *Ophthalmology*. 2012; 119(6):1272–1280
- Oxford University Centre for Evidence Based Medicine. Levels of Evidence (March 2009). Oxford, United Kingdom: Oxford University Centre for Evidence Based Medicine; 2009. Available at: www.cebm.net/index.aspx?o=1025. Accessed October 9, 2013

22. Schwartz SD, Harrison SA, Ferrone PJ, Trese MT. Telemedical evaluation and management of retinopathy of prematurity using a fiberoptic digital fundus camera. *Ophthalmology*. 2000; 107(1):25–28
23. Lorenz B, Spasovska K, Elflein H, Schneider N. Wide-field digital imaging based telemedicine for screening for acute retinopathy of prematurity (ROP). Six-year results of a multicentre field study. *Graefes Arch Clin Exp Ophthalmol*. 2009;247(9):1251–1262
24. Silva RA, Murakami Y, Lad EM, Moshfeghi DM. Stanford University network for diagnosis of retinopathy of prematurity (SUNDROP): 36-month experience with telemedicine screening. *Ophthalmic Surg Lasers Imaging*. 2011;42(1):12–19
25. Chiang MF, Wang L, Busuioc M, et al. Telemedical retinopathy of prematurity diagnosis: accuracy, reliability, and image quality. *Arch Ophthalmol*. 2007; 125(11):1531–1538
26. Scott KE, Kim DY, Wang L, et al. Telemedical diagnosis of retinopathy of prematurity intraphysician agreement between ophthalmoscopic examination and image-based interpretation. *Ophthalmology*. 2008;115(7):1222.e3–1228.e3
27. Dhaliwal C, Wright E, Graham C, McIntosh N, Fleck BW. Wide-field digital retinal imaging versus binocular indirect ophthalmoscopy for retinopathy of prematurity screening: a two-observer prospective, randomised comparison. *Br J Ophthalmol*. 2009;93(3):355–359
28. Dai S, Chow K, Vincent A. Efficacy of wide-field digital retinal imaging for retinopathy of prematurity screening. *Clin Experiment Ophthalmol*. 2011;39(1):23–29
29. Health Insurance Portability and Accountability Act. Pub L No. 104-191 (1996)
30. The Digital Imaging and Communications in Medicine (DICOM) Standard. Available at: <http://medical.nema.org/standard.html>. Accessed October 9, 2013
31. Systematized Nomenclature for Medicine – Clinical Terms (SNOMED-CT). Available at: www.ihtsdo.org/snomed-ct/. Accessed October 9, 2013
32. US Department of Health and Human Services. Health Information Privacy. Available at: www.hhs.gov/ocr/privacy/. Accessed October 9, 2013
33. Clarity Medical Systems. RetCam Training Modules. Available at: www.claritymsi.com/us/retcamtraining.html. Accessed October 9, 2013
34. Koreen S, Lopez R, Jokl DH, Flynn JT, Chiang MF. Variation in appearance of severe zone 1 retinopathy of prematurity during wide-angle contact photography. *Arch Ophthalmol*. 2008;126(5):736–737
35. Mehta M, Adams GG, Bunce C, Xing W, Hill M. Pilot study of the systemic effects of three different screening methods used for retinopathy of prematurity. *Early Hum Dev*. 2005;81(4):355–360
36. Mukherjee AN, Watts P, Al-Madfai H, Manoj B, Roberts D. Impact of retinopathy of prematurity screening examination on cardiorespiratory indices: a comparison of indirect ophthalmoscopy and retcam imaging. *Ophthalmology*. 2006;113(9):1547–1552
37. Fierston WM; American Academy of Pediatrics Section on Ophthalmology; American Academy of Ophthalmology; American Association for Pediatric Ophthalmology and Strabismus; American Association of Certified Orthoptists. Screening examination of premature infants for retinopathy of prematurity. *Pediatrics*. 2013;131(1):189–195
38. Ophthalmic Mutual Insurance Company. Parents: read this about your premature baby's eyes! Available at: www.omic.com/ropparents-read-this-about-your-premature-babys-eyes/. Accessed October 9, 2013