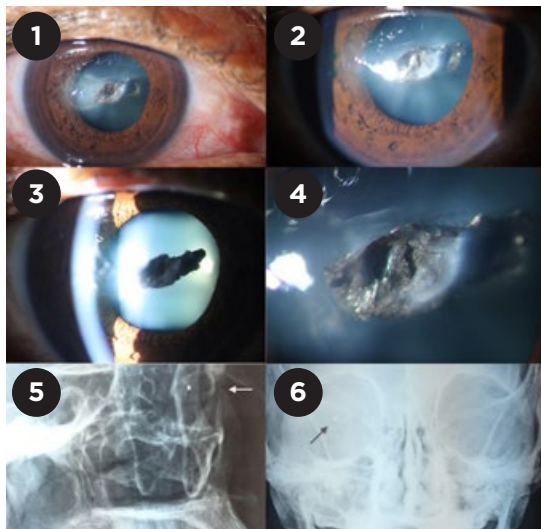


Traumatic Cataract by Foreign Body

A 47-year-old man presented with a chief complaint of blurred vision after a traumatic event. On examination, vision was 20/400 in his right eye and 20/20 in his left. Slit-lamp examination (Figs. 1-4) revealed a corneal wound in the temporal region of the right eye, involving the entire thickness. The patient was diagnosed with a cataract secondary to trauma from a metallic foreign body, the presence of which was confirmed on x-ray (Figs. 5, 6). The Ocular Trauma Score was 56 points.

Traumatic cataract may result from injury to the lens by a foreign body or direct impact to the eyeball by blunt object. Traumatic cataract presents a major challenge for the surgeon, and it is an important cause of monocular blindness in patients under 45 years of age.

In this particular case, the traumatic injury of the anterior segment was compromising the patient's visual acuity. Thus, the foreign



body was removed without delay, and the cataract was removed at the same time without any complications.