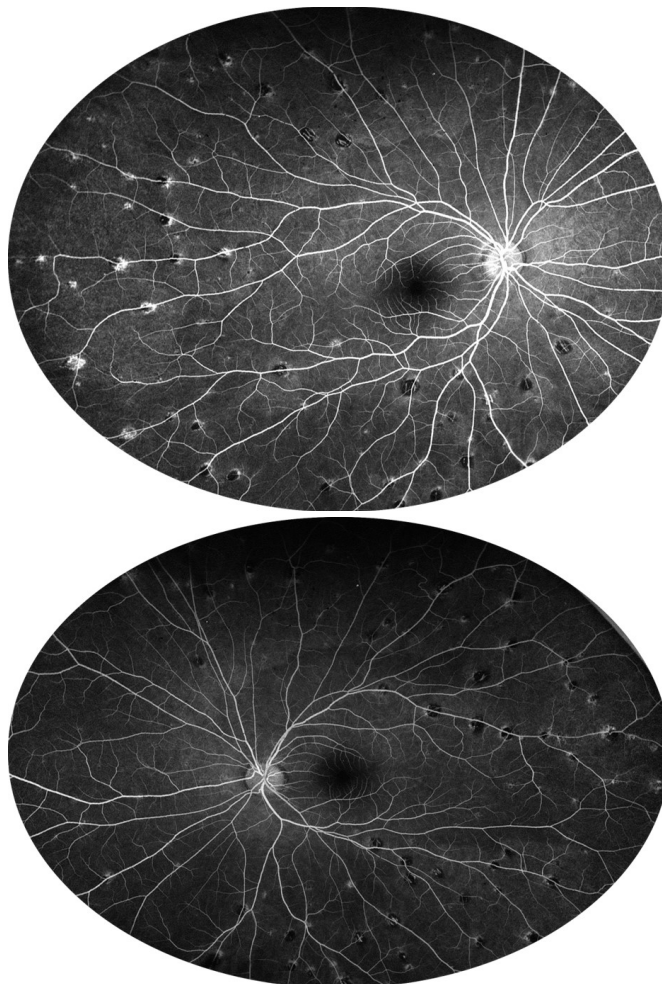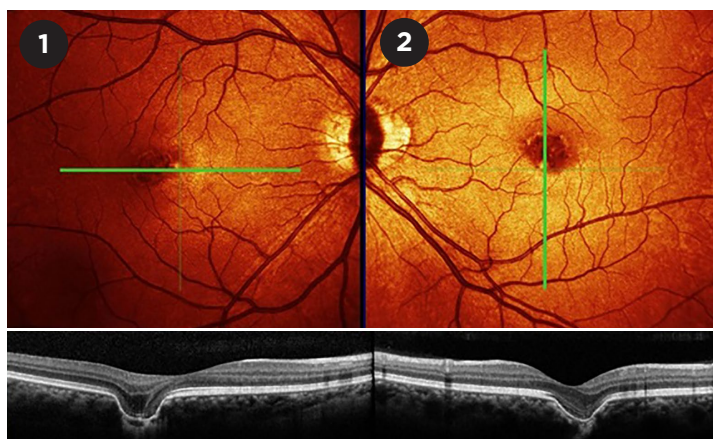


**WHAT IS THIS MONTH'S MYSTERY CONDITION?** Visit [aao.org/eyenet](https://aao.org/eyenet) to make your diagnosis in the comments.

#### LAST MONTH'S BLINK

## Bilateral Focal Choroidal Excavation

**A**fter years of experiencing variable double vision and difficulty with reading fine print, a 38-year-old woman was found to have focal choroidal excavation in both eyes (Figs. 1, 2). VA was 20/20 in the right eye and 20/25 in the left. The patient had been treated by her optometrist with prism lenses, but she had no other ocular disorders. Idiopathic focal choroidal excavation may be a stable congenital condition found on routine examination; however, choroidal excavation may also develop secondary to inflammatory conditions or central serous retinopathy. We recommended that the patient be followed in one year, as the lesions would likely be stable.



WRITTEN BY **MARK J. DAILY, MD**, WHEATON EYE CLINIC, WHEATON, ILL. PHOTO FROM WHEATON EYE CLINIC.