

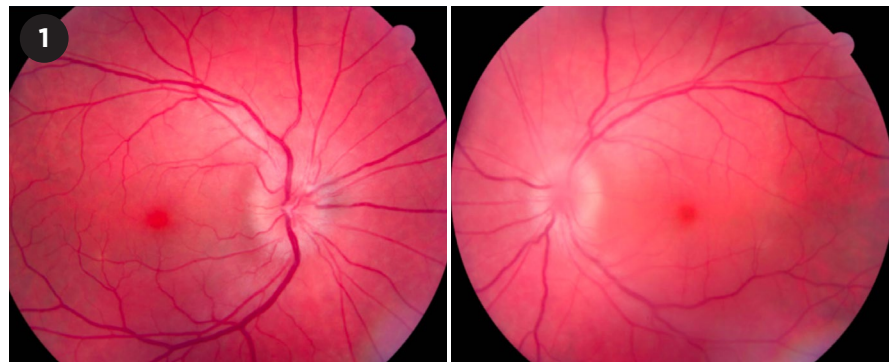
Diagnosis and Management of Ocular Syphilis

Syphilis is a sexually transmitted disease caused by the spirochete *Treponema pallidum*. The incidence of syphilis is increasing throughout the United States irrespective of gender. Syphilis can affect almost any part of the eye and is notorious for mimicking other inflammatory conditions. Moreover, ocular manifestations can occur in the absence of systemic signs making diagnosis challenging. Thus, patients presenting with ocular inflammation are routinely tested for syphilis.

Recommended practice patterns continue to evolve. In particular, a recent update from the CDC indicates that lumbar puncture (LP) is no longer needed in patients with ocular syphilis in the absence of neurologic symptoms or signs.¹ Given that the consequence of a delay in diagnosis of ocular syphilis is potential worsening of clinical outcomes and increased risk of permanent tissue damage,² it is important to recognize and appropriately treat ocular syphilis early in its course.

Prevalence and Geographic Variation

Since reaching a low in the early 2000s, the rate of syphilis in both males and females has risen almost every year, increasing 6.8% during 2019-2020. The growing incidence of syphilis seems to be accompanied by an increasing incidence of ocular syphilis. Although this



OPTIC NERVE INVOLVEMENT. Syphilitic papillitis involving both optic nerve heads in a 47-year-old man.

trend is difficult to ascertain, given the relative rarity of ocular involvement, the CDC issued a clinical advisory in 2015 based on evidence of a likely increase in cases of ocular syphilis.³ Ocular syphilis is commonly associated with HIV coinfection, with estimates of about 50% of ocular syphilis patients also being infected with HIV.

The best insight into the risk of ocular syphilis comes from a 2016 CDC report that looked at rates of ocular syphilis in eight geographic locations across the United States. The overall estimated rate of ocular syphilis among patients with syphilis was .65% in 2015, but the rates ranged from .19% to 3.90% among the different locations.⁴ Another perspective is that syphilis accounts for 1% to 5% of cases of ocular inflammation in tertiary referral centers in the United States.⁵

Pathophysiology, Stages, and Clinical Features

Acquired syphilis. The spirochete that causes syphilis can directly invade the central nervous system through the blood vessels and meninges and can cause a wide variety of neurologic and neuro-ophthalmic findings. Acquired syphilis has primary, secondary, latent, and tertiary stages. Both neurosyphilis and ocular syphilis may occur at any of these stages, although ocular syphilis is most common during the secondary stage. The most frequent manifestation of ocular syphilis in immunocompetent adults is posterior uveitis.

Primary stage. Primary syphilis is due to direct inoculation of the spirochete at a local site, leading to a painless ulcer, called a chancre, at the locus of initial infection (most often in the genital, anal, or oral area). From there, the organism can spread to local lymph nodes. Eye involvement is rare in primary syphilis although there have been case reports of chancres of the eyelid and conjunctiva.^{6,7}

BY MELISSA YUAN, MD, AND JOSEPH F. RIZZO III, MD. EDITED BY JEREMIAH P. TAO, MD, FACS.

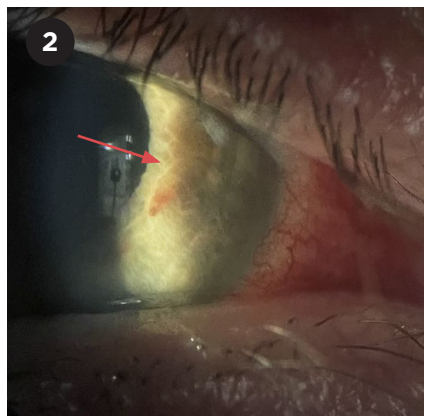
Secondary stage. Secondary syphilis occurs when spirochetes spread hematogenously. If syphilis is not treated during the primary stage, secondary syphilis develops four to 10 weeks after the chancre appears. This phase of infection is characterized by a diffuse maculopapular rash that involves the palms and soles, as well as fever, lymphadenopathy, and headache.

It is this spread via the bloodstream that can inflame ocular tissues. In this phase, spirochetes have been isolated from the intraocular tissues.⁸ In the eye, secondary syphilis may cause anterior uveitis (either granulomatous or non-granulomatous), episcleritis, scleritis, chorioretinitis, vitritis, retinal vasculitis, or papillitis (Fig. 1). One rare but fairly specific exam finding is the iris roseola, or a red iris nodule (Fig. 2). Involvement of the posterior segment of the eye tends to occur later in secondary syphilis. One essentially pathognomonic manifestation of posterior involvement is known as acute posterior placoid chorioretinopathy, which affects the retinal pigment epithelium (Fig. 3, next page).

Secondary syphilis may last as long as two years. If secondary syphilis is left untreated, the manifestations will eventually disappear, but progression to tertiary syphilis may occur.

Latent stage. There is typically a latent phase after the secondary phase, and by definition, there are no systemic or ocular manifestations. This phase can last from a few months to more than 30 years.

Tertiary stage. Many cases of secondary or latent syphilis progress to the tertiary phase. The clinical findings in tertiary syphilis are largely due to an endarteritis caused by chronic inflammation of blood vessel walls as a result of chronic treponemal infection. This stage can cause widespread damage, including cardiovascular complications (notably, aortitis, aortic aneurysms, aortic valve insufficiency, and narrowing of the coronary ostia) and neurologic involvement (especially meningitis, tabes dorsalis, and general paresis). Vascular and tissue damage can occur because the spirochetes incite both innate and adaptive immune responses.



RARE IRIS EFFECT. *Iris roseola in a 48-year-old man with panuveitis.*

Gummas, which are nontender, necrotic granulomatous lesions, may become evident in a variety of tissues during this phase.

In the eye, tertiary syphilis may cause eyelid-involving gummas, anterior and posterior uveitis, retinal vasculitis, keratitis, scleritis, or papillitis. Argyll Robertson pupil can occur in tertiary syphilis and is characterized by bilaterally small pupils that show minimal response to light but respond normally to near stimuli (light-near dissociation). This reaction is believed to be caused by damage to the ciliary nucleus or to the connections between the Edinger-Westphal and the pretectal nuclei.

Congenital syphilis. Congenital syphilis, which is due to transplacental spread of the spirochetes, causes bacteremia with potentially widespread inflammation in tissues throughout the fetus. This dissemination of infection accounts for the protean systemic manifestations of congenital syphilis, including premature births, sensorineural hearing loss, musculoskeletal deformities such as saddle nose deformity, dental abnormalities, and hydrocephalus. In the eye, congenital syphilis most commonly causes interstitial keratitis but may also cause a pigmentary retinopathy.

Diagnosis

Differential diagnosis. The differential diagnosis for ocular syphilis varies depending on the specific presentation. For instance, the differential diagnosis for interstitial keratitis includes auto-

immune keratitis, posttraumatic scar, herpetic disease, and infectious corneal ulcers.

Anterior uveitis, vitritis, or panuveitis may be caused by sarcoidosis, tuberculosis, HLA-B27-related disease, toxoplasmosis, herpes simplex virus or varicella-zoster virus infection, Vogt-Koyanagi-Harada syndrome, sympathetic ophthalmia, inflammatory bowel-associated diseases, and lymphoma or other malignancies.

Chorioretinitis similarly may be caused by tuberculosis, sarcoidosis, toxoplasmosis, and neoplastic infiltration, as well as white dot syndromes, including acute posterior multifocal placoid pigment epitheliopathy or ser-piginous chorioiditis.

The differential for papillitis is broad and includes, among other entities, increased intracranial pressure, demyelinating disease, sarcoidosis, ischemic optic neuropathy, infiltrative disease such as lymphoma, and infection with *Bartonella* or *Borrelia* (e.g., Lyme disease).

Diagnostic testing. Testing for syphilis includes nontreponemal and treponemal-specific tests.

Nontreponemal tests. The nontreponemal tests, which include Venereal Disease Research Laboratory (VDRL) and rapid plasma reagin (RPR) tests, are relatively sensitive but not specific. These tests detect IgG/IgM antibodies to antigens that are released by damaged host cells in response to bacteria. These tests can be affected by the prozone phenomenon, a false negative result that occurs due to high antibody titers. Nontreponemal tests become positive within six weeks of infection. Generally, the titers obtained with nontreponemal tests correlate with disease activity.

Treponemal-specific tests. The treponemal-specific tests include the fluorescent treponemal antibody absorption test (FTA-Abs), microhemagglutination *T. pallidum* test (MHA-TA), and *T. pallidum* particle agglutination assay (TPPA). These tests detect IgG/IgM antibodies against specific *T. pallidum* proteins and become positive within three weeks of infection. Although these tests are much more

specific than the nontreponemal tests, they cannot distinguish active from latent infection.

Considerations for congenital syphilis. The diagnosis of congenital syphilis may be challenging due to confounding by maternal transfer of antibodies. As such, when congenital syphilis is suspected, it is vital to ensure adequate follow-up with the pediatric ophthalmologist and infectious disease specialist for repeated serologic testing and examination as appropriate, especially because the consequences of missing treatment may be devastating.

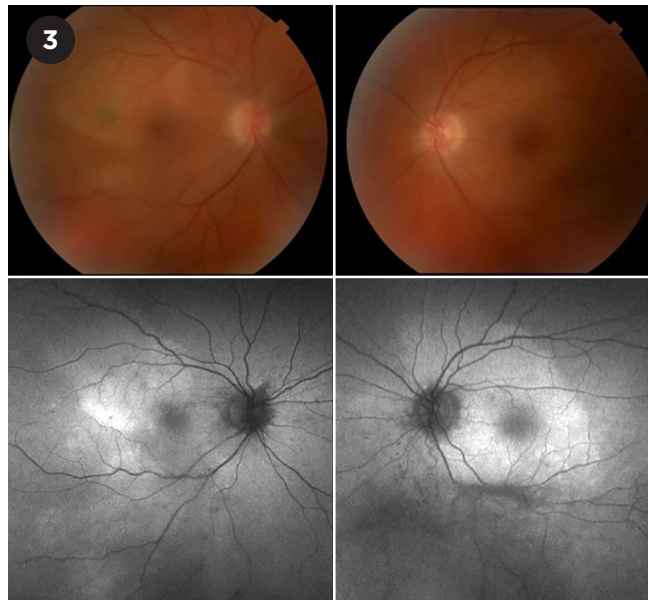
Management

Antibiotics. The treatment for ocular syphilis recommended by the CDC is the same as that for neurosyphilis. In either case, the recommended regimen is IV penicillin G at a dose of 3-4 million units every four hours (or as a continuous infusion of 18-24 million units per day) for 10 to 14 days. The recommended alternative regimen is intramuscular penicillin G given at a dose of 2.4 million units daily together with oral probenecid 500 mg four times daily for 10 to 14 days.

One large study recently completed in France showed comparable efficacy of ceftriaxone 2 g once daily compared with the typical IV penicillin regimen in the treatment of ocular and otic syphilis.⁹ Although this approach is not the standard of care or recommended by the CDC, it is an interesting potential alternative, given that the regimen of daily dosing (compared to every four hours) of the antibiotic could improve patients' quality of life and, possibly, treatment adherence.

Steroids. Topical corticosteroids may be considered for use in cases of interstitial keratitis, which is more likely an immune-mediated response phenomenon than a manifestation of direct infection.

Steroids are also often added as part



FUNDUS FINDINGS. Acute posterior placoid chorioretinopathy in a 56-year-old man. The upper panels show posterior placoid changes on fundus photography. These changes are also apparent (as whitened areas) on the autofluorescence images in the lower panels.

of the treatment regimen for uveitis and scleritis caused by syphilis; however, CDC guidelines note no proven benefit of steroids in the treatment of ocular syphilis, and the agency does not officially recommend them.

Role of lumbar puncture. Even though treatment is the same for ocular and neurosyphilis, as of 2021, LP is no longer recommended for ocular syphilis without neurologic symptoms or signs. Formerly, LP was recommended at the time of syphilis diagnosis. Then, if the LP showed increased white blood cells or if a nontreponemal test was positive, the recommendation was to treat aggressively for presumed neurosyphilis, with the LP repeated six months later to assess the need for additional antibiotic treatment.

Because serum RPR was found to correlate well with positive cerebrospinal fluid findings, LP is no longer recommended for all cases of ocular syphilis.

Presence of coinfection. Management of any patient with syphilis should include testing for HIV infection and other sexually transmitted diseases. HIV coinfection may increase the risk of ocular syphilis in people with syphilis.¹⁰

Conclusion

Ocular syphilis encompasses the many and varied eye manifestations of syphilitic infection. As the incidence of syphilis rises, it is ever more important to be aware of the ways that syphilis can affect the eyes. Syphilis is a treatable cause of eye inflammation, and such treatment can also reduce the risk of complications elsewhere in the body, including the central nervous system.

1 CDC. Sexually Transmitted Infections Treatment Guidelines, 2021. *Neurosyphilis, Ocular Syphilis, and Ootosyphilis.* www.cdc.gov/std/treatment-guidelines/neurosyphilis.htm. Accessed Dec. 21, 2022.

2 Gu X et al. *J Eur Acad Dermatol Venereol.* 2020; 34(7):1569-1578.

3 CDC. Clinical Advisory: Ocular Syphilis in the United States. Updated March 24, 2016. www.cdc.gov/std/syphilis/clinicaladvisory-os2015.htm. Accessed Feb. 9, 2023.

4 Oliver SE et al. *MMWR Morb Mortal Wkly Rep.* 2016;65(43):1185-1188.

5 Moradi A et al. *Am J Ophthalmol.* 2015;159(2):334-343.e1.

6 Cillino S et al. *BMC Infect Dis.* 2012;12:226.

7 Maxey EE. *Am J Ophthalmol.* 1918;1(1):13-17.

8 Khalil S et al. *Open Forum Infect Dis.* 2019; 6(suppl 2):S214.

9 Bettuzzi T et al. *Lancet Infect Dis.* 2021;21(10):1441-1447.

10 Cope AB et al. *Sex Transm Dis.* 2019;46(2):80-85.

Dr. Yuan is a second-year ophthalmology resident at Mass Eye and Ear/Harvard Ophthalmology. **Dr. Rizzo** is director of the neuro-ophthalmology service at Mass Eye and Ear and the Simmons Lessell Professor of Ophthalmology at Harvard Medical School. *Financial disclosures:* None.

PODCAST.

Listen to the recent Experts InSight episode with Drs. Steven Yeh and Chris Conrady about ocular syphilis.

Visit aao.org/podcasts to learn more and subscribe, or find it wherever you access your podcasts.

